

Retrospective Study

Duodenum and ventral pancreas preserving subtotal pancreatectomy for low-grade malignant neoplasms of the pancreas: An alternative procedure to total pancreatectomy for low-grade pancreatic neoplasms

Xing Wang, Chun-Lu Tan, Hai-Yu Song, Qiang Yao, Xu-Bao Liu

Xing Wang, Chun-Lu Tan, Hai-Yu Song, Xu-Bao Liu, Department of Pancreatic Surgery, West China Hospital, Sichuan University, Chengdu 610041, Sichuan Province, China

Qiang Yao, West China School of Public Health, Sichuan University, Chengdu 610041, Sichuan Province, China

ORCID number: Xing Wang (0000-0002-4959-1118); Chun-Lu Tan (0000-0001-5259-3002); Hai-Yu Song (0000-0003-4772-2855); Qiang Yao (0000-0003-4686-961X); Xu-Bao Liu (0000-0002-1288-7089).

Author contributions: Wang X and Liu XB designed the research; Wang X, Tan CL and Yao Q performed the research and analyzed the data; Wang X, Tan CL and Song HY wrote the paper; Liu XB proofread and revised the manuscript; all authors approved the version to be published.

Conflict-of-interest statement: No potential conflicts of interest relevant to this article were reported.

Data sharing statement: No additional data are available.

Open-Access: This article is an open-access article which was selected by an in-house editor and fully peer-reviewed by external reviewers. It is distributed in accordance with the Creative Commons Attribution Non Commercial (CC BY-NC 4.0) license, which permits others to distribute, remix, adapt, build upon this work non-commercially, and license their derivative works on different terms, provided the original work is properly cited and the use is non-commercial. See: <http://creativecommons.org/licenses/by-nc/4.0/>

Manuscript source: Unsolicited manuscript

Correspondence to: Xu-Bao Liu, MD, PhD, Department of Pancreatic Surgery, West China Hospital, Sichuan University, No. 37, Guo Xue Alley, Chengdu 610041, Sichuan Province, China. xbliu@medmail.com.cn
Telephone: +86-28-85422477

Fax: +86-28-85422474

Received: June 13, 2017

Peer-review started: June 16, 2017

First decision: July 17, 2017

Revised: July 27, 2017

Accepted: August 15, 2017

Article in press: August 15, 2017

Published online: September 21, 2017

Abstract

AIM

To describe the indications, technique and outcomes of the novel surgical procedure of duodenum and ventral pancreas preserving subtotal pancreatectomy (DVPPSP).

METHODS

Data collected retrospectively from 43 patients who underwent DVPPSP and TP between 2009 and 2015 in our single centre were analysed. For enrolment, only patients with low-grade pancreatic neoplasms, such as pancreatic neuroendocrine tumors, intraductal papillary mucinous neoplasms (IPMNs), and solid pseudo-papillary tumors, were included. Ten DVPPSP (group 1) and 13 TP (group 2) patients were selected in this study.

RESULTS

There were no significant differences in age, gender, comorbidities, preoperative symptoms, American Society of Anesthesiologists score or indications for surgery between the two groups. The most common indication was IPMN for DVPPSP and TP (60% vs 85%, $P = 0.411$). Compared with the TP group, the DVPPSP group had

comparable postoperative morbidities ($P = 0.405$) and mortalities (both nil), but significantly shorter operative time (232 ± 19.6 min *vs* 335 ± 32.3 min, $P < 0.001$). DVPPSP preserved better long-term pancreatic function with less supplementary therapy ($P < 0.001$) and better quality of life (QoL) after surgery, including better scores in social ($P = 0.042$) and global health ($P = 0.047$) on functional scales and less appetite loss ($P = 0.049$) on the symptom scale.

CONCLUSION

DVPPSP is a feasible and safe procedure that could be an alternative to TP for low-grade neoplasms arising from the body and tail region but across the neck region of the pancreas; DVPPSP had better metabolic function and QoL after surgery.

Key words: Low-grade malignant neoplasm; Ventral pancreas preserving; Subtotal pancreatectomy; Quality of life

© The Author(s) 2017. Published by Baishideng Publishing Group Inc. All rights reserved.

Core tip: Although total pancreatectomy (TP) can be performed safely, the long-term metabolic complications prevent its application. Herein, we report our experience of duodenum and ventral pancreas preserving subtotal pancreatectomy (DVPPSP), which could be an alternative procedure to TP for low-grade pancreatic neoplasms, with a focus on the surgical indications, techniques and outcomes. Our results indicate that DVPPSP is a feasible and safe procedure that could be an alternative to TP for low-grade neoplasms arising from the body and tail region but across the neck region of the pancreas, with a better metabolic function and quality of life after surgery.

Wang X, Tan CL, Song HY, Yao Q, Liu XB. Duodenum and ventral pancreas preserving subtotal pancreatectomy for low-grade malignant neoplasms of the pancreas: An alternative procedure to total pancreatectomy for low-grade pancreatic neoplasms. *World J Gastroenterol* 2017; 23(35): 6457-6466 Available from: URL: <http://www.wjgnet.com/1007-9327/full/v23/i35/6457.htm> DOI: <http://dx.doi.org/10.3748/wjg.v23.i35.6457>

INTRODUCTION

Parenchyma-sparing procedures are increasingly performed for low-grade pancreatic neoplasms, such as intraductal papillary mucinous neoplasms (IPMNs), neuroendocrine tumors (NETs), and pseudo-papillary tumors (SPTs)^[1,2]. These procedures preserve the pancreatic parenchyma and decrease the risk of long-term endocrine and exocrine dysfunction^[3,4]. However, according to different reports, in these low-grade

diseases, the percentages of total pancreatectomy (TP) range from 5% to 28% because these diseases frequently involve the entire gland^[5-7]. The indications for primary elective TP are typically these pancreatic diseases. Although TP could be performed safely in many centres, the long-term metabolic complications that include brittle diabetes and unmanageable steatorrhea prevent its application. Additionally, wide resection of the total pancreas and duodenum after TP could lead to a reduced quality of life (QoL), which makes patients anguished. The conventional parenchyma-sparing procedures, such as enucleation and central pancreatectomy, are unable to substitute TP for lesions involving the head, body and tail of the pancreas.

As a function preserving procedure, Thayer *et al*^[8] reported a complete dorsal pancreatectomy with preservation of the ventral pancreas (the proximal duodenum was resected for ischemia) in 2002. Duodenum-preserving pancreatic head resection was introduced into surgical practice in 1972. This surgical method has been well developed by Doctor Beger *et al*^[9] in past decades. The rationale to apply a duodenum-preserving pancreatic resection is to avoid resection of the gastric antrum, to preserve the duodenum and the extrahepatic biliary duct for low-grade lesions. This procedure has low short-term postoperative morbidity and mortality, and maintenance of the endocrine and exocrine functions in the long-term after surgery. A significant superiority of the duodenum-preserving procedure regarding overall improvement of QoL was reported^[10]. Herein, we report our experience of duodenum and ventral pancreas preserving subtotal pancreatectomy (DVPPSP), which could be an alternative procedure to TP for selected patients with low-grade pancreatic neoplasms. The aim of our present study was mainly to describe the indications, operative technique and outcomes of the novel surgical procedure compared with TP.

MATERIALS AND METHODS

From January 2009 to January 2015, patients who underwent DVPPSP for low-grade pancreatic neoplasms (such as NETs, IPMNs and SPTs) were identified in our institution. To evaluate the outcomes of DVPPSP compared with TP, patients who underwent TP for low-grade pancreatic neoplasms were also identified during this period. Surgeries for pancreatic ductal adenocarcinoma and chronic pancreatitis determined on postoperative pathology were excluded. The selected patients were divided into two groups as follows: DVPPSP group (group 1) and TP group (group 2). The groups were analysed regarding age, gender, type of comorbidities, body mass index (BMI), American Society of Anesthesiologists score (ASA), operative time, blood transfusion and postoperative data (histology of pancreatic disease, postoperative

mortality and morbidity, postoperative length of hospital stay). The postoperative mortality rate included all deaths within 30 d after surgery. The morbidity rate included all complications following surgery until discharge. Major postoperative morbidities were defined and graded using the criteria recommended by the International Study Group of Pancreatic Surgery, including postoperative pancreatic fistula, delayed gastric emptying, and postpancreatectomy haemorrhage^[11-13]. Biliary leak was defined as drainage of any volume of fluid from percutaneous drains or a wound consistent with bile, which was defined by a bilirubin concentration greater than the serum concentration. Enteric leaks were identified using radiographic contrast imaging. Fluid collection in the intra-abdominal or pleural regions was determined via radiographic imaging, which was differentiated from abscess by positive microbial cultures. Pneumonia was diagnosed based on chest X-ray changes following antibiotic therapy.

Follow-up examinations were collected from the store of medical information centre in the hospital and from the results of follow-up by letters and telephone at the time of this study. The endocrine and exocrine controls were assessed by episodes of hyperglycaemia/day, daily dosage of insulin, pancreatic enzyme replacement. The QoL of patients were evaluated with the European Organization for Research and Treatment of Cancer Quality of life Questionnaire (EORTC QLQ-C30) version 3.0. The questionnaires were requested to be filled in by the patients themselves via mailing or completing in the clinic. The patients who had been dead or had tumor recurrence during the study were excluded from the analysis of QoL. This study was approved by the Ethics Committee of Sichuan University.

Surgical indication

DVPPSP was an alternative operative technique to TP of low-grade pancreatic tumor arising from the body and tail region but across the neck region of the pancreas (Figure 1). Contrast-enhanced computed tomography (CT), magnetic resonance imaging (MRI), or/and endoscopic ultrasound (EUS) were routinely performed to evaluate the lesions. Furthermore, DVPPSP was finally considered after intraoperative evaluation of the lesion, which confirmed negative for neoplasm of ventral pancreas based on palpation and intraoperative ultrasonography. Frozen sectioning was routinely performed to achieve negative margins in the present study. If invasive carcinoma was found in the frozen section of the stump, the DVPPSP was immediately converted to TP with formal lymphadenectomy.

Surgical technique

The surgical procedures were performed by one group of experienced surgeons in our department of pancreatic surgery. We performed a complete Kocher

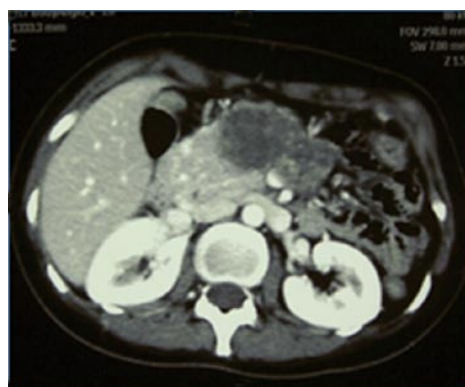

Figure 1 Preoperative computed tomography view of a 26-year-old female patient with a diagnosis of pseudo-papillary tumors. The figure shows that the lesion occupied the body and neck region with necrosis of the tail on preoperative computed tomography imaging. Normal pancreatic tissue is observed in the ventral pancreas region.

manoeuvre to mobilize the duodenum, the pancreatic head and uncinate process from the posterior connective tissue membrane. There was a call for intraoperative ultrasound to confirm that the ventral pancreas was negative for neoplasm. Then, the neck and body of the pancreas was freed from the common hepatic artery, portal vein, and superior mesenteric vein. The gastroduodenal trunk was divided and ligated at its confluence. Then, we dissected and taped the gastroduodenal artery (GDA). The anterior superior pancreaticoduodenal artery (ASPD) and other small branches of GDA in front of the cephalic pancreas could be resected to expose the common bile duct (CBD) at the upper edge of the pancreas and to completely resect the neoplasm. We preserved the GDA and the posterior superior pancreaticoduodenal artery (PSPD) (Figure 2). The transection of the cephalic side of the pancreas was begun at the edge of the neoplasm and was continued caudally. The posterior transection plane was along the anterior side of the CBD (Figure 2). Inferiorly, we dissected and exposed the CBD from the resecting pancreas toward the major papilla to achieve complete resection of the neoplasm.

If the neoplasm involved the entire dorsal pancreas, such as IPMN that involved the whole dorsal duct (including the Santorini duct) but ventral duct (Figure 3), a complete dorsal pancreatectomy was needed to achieve radical resection of the tumor. The embryological fusion plane between the ventral and the dorsal pancreas was confirmed by autopsy^[14] and was described as a clear fibrous septum^[8]. These anatomical characteristics made the complete dorsal pancreatectomy procedure theoretically feasible. However, the plane was difficult to identify in our study during surgery. Instead, we continued pancreatic transection and exposed the whole distal CBD (except its last centimetre) to achieve a complete dorsal pancreatectomy and we the confluence of the CBD with the ventral duct. The dorsal pancreatic duct was

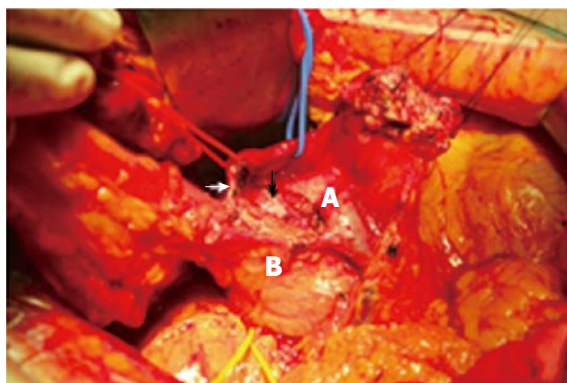


Figure 2 Intraoperative view of duodenum and ventral pancreas preserving subtotal pancreatectomy. A: Superior mesenteric vein; B: Ventral pancreas. Black arrow: intrapancreatic bile duct; White arrow: gastroduodenal artery.

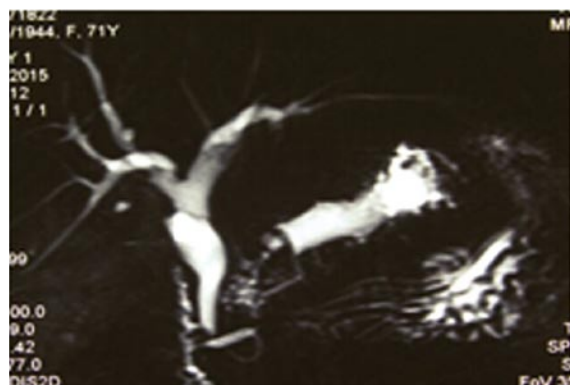


Figure 3 Preoperative magnetic resonance imaging view of a 71-year-old female patient with diagnosis of MD-IPMN. The figure shows that the lesion involves the whole dorsal duct (including Santorini duct). The diameter of ventral pancreatic duct is normal on the MRCP image.

divided and ligated 3 mm away from the duodenal lumen and was free of neoplasia on frozen section examination. The anterior inferior pancreaticoduodenal artery (AIPD) could be included in the resection site if necessary. Then, we identified the main pancreatic duct (Wirsung duct) in the stump of the residual pancreas and ligated this duct. The stump was negative for tumor on frozen sectioning, which was routinely performed in the present study.

Parenchyma sutures and tissue sealant were used in selected cases. Bipolar cautery, ultrasound scalpel and the suture technique using 4-0 absorbable sutures (Ethicon, Inc) were used for haemostasis and pancreatostasis. It was worth noting that bipolar cautery was not performed in the deep areas near the Wirsung duct or other important structures (CBD or major vessels) due to presumed heat injury. Parenchymal sutures and tissue sealant were used for cases in which haemostasis and pancreatostasis were not satisfied exclusively using bipolar cautery and ultrasound scalpel. Finally, we routinely placed at least one drain adjacent to the cut surface.

Drain amylase analysis was performed from postoperative day one to three and then every other day. For patients without a fistula, we progressively withdrew drainage starting on postoperative day three and finally removed the drain on postoperative day five. Postoperative octreotide was routinely used for seven days to decrease the secretion of the pancreas. We routinely performed abdominal EUS before finally removing the drain. The long-term follow-up should be performed after DVPPSP, even if the stump is negative.

Statistical analysis

The Pearson χ^2 test was used for categorical variables. Fisher's exact test was used in cases with a variable count < 5. For continuous variables, Student's *t* test was used for normally distributed variables and the Wilcoxon rank-sum test was used for non-normally distributed variables. *P* < 0.05 was considered statistically significant. All analyses were performed using SPSS version 18.0 software on a personal computer (SPSS Inc., Chicago, IL, United States).

RESULTS

DVPPSP was performed for 10 patients, and TP was performed for 33 patients between January 2009 and January 2015 in our department. Patients with chronic pancreatitis, pancreatic cancers (PC) and pancreatic metastases were excluded in this study. Of these, twenty patients who underwent TP, including 2 with chronic pancreatitis, 16 with PC, and 2 with pancreatic metastases from renal cell cancer, were excluded in our present study. Finally, ten DVPPSP (group 1) and 13 TP (group 2) patients were selected in this study.

The preoperative characteristics of the patients undergoing DVPPSP and TP are summarized in Table 1. There were no significant differences in age, gender, comorbidities, preoperative symptoms, ASA score or indications for surgery between the two groups. The median age was 49 in the DVPPSP group and 56 in the TP group. Four male patients (40%) were in the DVPPSP group, and 7 males (54%) were in the TP group. In the DVPPSP and TP groups, the majority of patients were symptomatic (100% vs 85%), and abdominal pain (40% vs 55%) was the most common symptom. The ASA III was given to 3 patients in DVPPSP and TP group. The pathologic features of the lesions in the DVPPSP and TP groups are shown in Table 1. The most common indication for DVPPSP or TP was IPMN (6/10, 60% vs 11/13, 85%). All the 6 IPMNs who underwent DVPPSP were main duct type (MD-IPMN). The 11 IPMNs in the TP group comprised 9 MD-IPMN, 1 mixed-type (MT-IPMN) and 1 multifocal type. According to the 2010 WHO classification, one out of 6 IPMN in the DVPPSP group and 5 out of 11 IPMN in the TP group were detected as invasive carcinoma (16.7% vs 45.5%, *P* = 0.333). The 2 NETs in the DVPPSP group and the 1 NET in the TP group

Table 1 Preoperative characteristics and final pathologic features of 23 patients in the duodenum and ventral pancreas preserving subtotal pancreatectomy and total pancreatectomy groups *n* (%)

Patient characteristics	DVPPST (<i>n</i> = 10)	TP (<i>n</i> = 13)	<i>P</i> value
Age (range, yr)	49 ± 16.9 (24-71)	56 ± 10.1 (40-70)	0.256
Gender (%)			0.680
Male	4 (40)	7 (54)	
Female	6 (60)	6 (46)	
Major comorbidity			
CAD	0	1	1.000
COPD	1	2	1.000
DM	2	3	1.000
Hypertension	3	3	1.000
Preoperative symptoms			
Incidental	0	2 (15)	0.486
Symptomatic (%)	10 (100)	11 (85)	
Abdominal pain	4 (40)	6 (55)	1.000
Pancreatitis	1	4	0.339
Weight loss	1	4	0.339
Gastrointestinal	4	3	0.65
symptoms			
ASA score			1.000
I / II	7	10	
III	3	3	
Pathology (%)			0.411
IPMN	6 (60)	11 (85)	
Low-grade	2	1	0.515
moderate-grade dysplasia			
High-grade	3	4	0.644
dysplasia			
Invasive carcinoma	1 (16.7)	5 (45.5)	0.333
Neuroendocrine	2	1	
tumor			
G 2	2	1	1.000
SPT	2	1	
Total invasive	1 (10)	5 (38.5)	0.179
malignancy			

CAD: Coronary artery disease; COPD: Chronic obstructive pulmonary disease; DM: Diabetes mellitus; IPMN: Intraductal papillary mucinous neoplasm; SPT: Pseudo-papillary tumor; DVPPSP: Duodenum and ventral pancreas preserving subtotal pancreatectomy.

were classified as G2.

The intra-operative and postoperative short-term outcomes of the two groups are summarized in Table 2. None of the parameters listed were significantly different between the two groups except the operative time, which was significantly shorter in the DVPPSP group compared with the TP group (232 min vs 335 min, $P < 0.001$). The total morbidities were 20% (2/10) and 38% (5/13) in the DVPPSP and TP group, respectively. There was no significant difference in the post-operative morbidity between the two groups, including delay gastric emptying (DGE) and biliary fistula. Clinical pancreatic fistula (grade B or C) was not found in either group. There were no reoperations or readmissions in either group. The mortalities were nil in both groups. Although there was no significant difference, the post-operative hospital stay days (LOS)

Table 2 Intraoperative and postoperative outcomes of 23 patients after duodenum and ventral pancreas preserving subtotal pancreatectomy and total pancreatectomy

Operative characteristics	DVPPSP (<i>n</i> = 10)	TP (<i>n</i> = 13)	<i>P</i> value
Intraoperative transfusion (U)	0.20 ± 0.63 (0-2)	0.54 ± 1.05 (0-3)	0.379
Operative time (min)	232 ± 19.6 (215-255)	335 ± 32.3 (280-400)	< 0.001
Postoperative characteristics			
DGE	0	1	1.000
Biliary fistula	0	1	1.000
Pancreatic fistula (B and C)	0	0	—
Overall morbidity	2	5	0.405
Major morbidity (≥ grade 3)	1	2	1
Reoperation	0	0	—
Readmission (30 d)	0	0	—
LOS	9.7 ± 3.8 (7-20)	11.7 ± 5.2 (8-26)	0.318
Mortality	0	0	—
Recurrence ¹ (%)	2 (20%)	5 (38.5%)	0.405
IPMN	2/6	5/11	1.000

¹The recurrences of 2 patients in the DVPPSP group and 5 patients in the TP group occurred after surgery for IPMN. DGE: Delayed gastric emptying; LOS: Length of postoperative stay; DVPPSP: Duodenum and ventral pancreas preserving subtotal pancreatectomy.

appeared to be slightly shorter in the DVPPSP group (9.7 d vs 11.7 d, $P = 0.318$). The mean follow-up lengths were 26.6 and 33.9 months in the DVPPSP and TP groups, respectively. There were 2 out of 10 patients in the DVPPSP group and 5 out of 13 patients in the TP group proven to have recurrences (20% vs 38.5%, $P = 0.405$) (Table 2). Two out of 6 IPMNs in the DVPPSP group were shown to have recurrence at 28 and 36 mo after surgery separately, although negative margins were detected by intra-operative frozen sections. A total of 5 out of 11 IPMNs in the TP group were shown to have recurrence at 16, 26, 30, 34, 50 mo after surgery separately (2/6, 33.3% vs 5/11, 45.5%, $P = 1.000$).

The differences in replacement therapy are summarized in Table 3. The mean follow-up lengths were 26.6 and 33.9 mo in the DVPPSP and TP groups, respectively. There were significant differences in replacement therapy between the two groups. The mean enzyme replacements were 0.9 cps/d vs 9.2 cps/d ($P < 0.001$) in the DVPPSP and TP groups, respectively. The total insulin doses were 6.4 U/d vs 29.7 U/d ($P < 0.001$). No patients had hyperglycaemia after insulin treatment in the DVPPSP group, whereas five patients (38%) in the TP group still had hyperglycaemia occasionally ($P = 0.046$). There were still 2 patients (20%) having diarrhea and steatorrhea occasionally after replacement treatment in the DVPPSP group, compared with 4 patients (31%) in the TP group ($P = 0.660$). The long term

Table 3 Postoperative condition of supplementary therapy of 23 patients after duodenum and ventral pancreas preserving subtotal pancreatectomy and total pancreatectomy

Parameters	DVPPSP (n = 10)	TP (n = 13)	P value
Enzymes replacement (cps/d)	0.9 ± 2.0	9.2 ± 2.2	< 0.001
Total insulin dose (U/d)	6.4 ± 14.0	29.7 ± 9.3	< 0.001
Diarrhea or steatorrhea	2	4	0.660
Hyperglycemia	0	5	0.046

TP: Total pancreatectomy; DVPPSP: Duodenum and ventral pancreas preserving subtotal pancreatectomy.

Table 4 Postoperative condition of diabetes of 10 patients in the duodenum and ventral pancreas preserving subtotal pancreatectomy group

Parameters	DVPPSP (n = 10)
New-onset diabetes	0 / 7
Worsen diabetes ¹	1/3
Diet to oral medication	—
Diet to insulin	—
Oral medication to insulin ¹	1/3

¹There was 3 out of 10 patients in DVPPSP group who had diabetes before surgery and were treated by oral medicine. DVPPSP: Duodenum and ventral pancreas preserving subtotal pancreatectomy.

results regarding pancreatic endocrine function after DVPPSP are summarized in Table 4. Of the 10 patients who had DVPPSP, seven patients had no diabetes before surgery. There were no patients with new-onset diabetes. Of the 3 patients who had diabetes before surgery in the DVPPSP group, only one patient (1/3, 33%) had the diabetes worsen after surgery. This patient changed treatment with oral medication to treatment with insulin. The quality of life (QoL) according the EORTC QLQ-C30 is summarized in Table 5.

A total 16 patients were qualified to complete questions about the EORTC QLQ-C30 at the time of this study. Each group included 8 patients. Due to the recurrence of IPMNs, two patients in the DVPPSP group and 5 patients in the TP group mentioned above were excluded from the inquiry. As presented in Table 5, patients in the DVPPSP group could have a higher quality of life status after surgery compared with the TP group. A high scale score in the global health, physical, working ability, emotional, cognitive and social functioning represented a high quality of life status. Regarding the symptoms and financial impact of the disease, the low scale score indicated no important problems. There were significant differences existing in social ($P = 0.042$) and global health ($P = 0.047$) on functional scale. There was a significant difference existing in appetite loss ($P = 0.049$) on the

Table 5 Quality of lives after duodenum and ventral pancreas preserving subtotal pancreatectomy and total pancreatectomy

Parameters	DVPPSP (n = 8)	TP (n = 8)	P value
Functional scale			
Physical	95.0 ± 9.3 (80-100)	97.5 ± 7.1 (80-100)	0.554
Working ability	100	100	—
Cognitive	100	100	—
Emotional	98.4 ± 2.9 (93.8-100)	92.2 ± 8.0 (75-100)	0.057
Social	95.8 ± 7.7 (83.3-100)	85.4 ± 10.7 (66.7-100)	0.042
Global QoL	96.9 ± 6.2 (83.3-100)	88.5 ± 8.9 (75-100)	0.047
Symptom scale			
Fatigue	4.2 ± 8.3 (0-22.2)	11.1 ± 11.7 (0-33.3)	0.196
Nausea and vomiting	0	6.3 ± 12.4 (0-33.3)	0.197
Pain	0	0	—
Appetite loss	0	20.8 ± 24.8 (0-66.7)	0.049
Dyspnea	0	0	—
Sleep disturbance	4.2 ± 11.8 (0-33.3)	12.5 ± 17.2 (0-33.3)	0.281
Constipation	0	4.2 ± 11.8 (0-33.3)	0.351
Diarrhea	4.2 ± 11.8 (0-33.3)	12.5 ± 24.8 (0-66.7)	0.405
Financial strain	0	8.3 ± 15.4 (0-33.3)	0.170

TP: Total pancreatectomy; QoL: Quality of life; DVPPSP: Duodenum and ventral pancreas preserving subtotal pancreatectomy.

symptom scale.

DISCUSSION

Although TP could be performed safely as reported by different authors in the literature, patients would suffer from the pain of replacement therapy throughout their lives^[15-17]. When faced with benign or low-grade malignant disease with long life expectancy such as pNETs, IPMNs and SPTs, the need for a proper treatment has to be balanced with the risk of long term impairment of exocrine/endocrine function of the gland. Herein, we described the outcomes after 10 DVPPSPs performed for low-grade malignant disease compared with 13 TPs performed for the same spectrum of disease, showing that DVPPSP is safe and effective for preserving the exocrine/endocrine function of the gland. This procedure could be an alternative to TP for low-grade neoplasms arising from the body and tail region but across the neck region of the pancreas.

It is a difficult question when we find the low-grade malignant neoplasm originating from the distal pancreas across the pancreatic neck. TP might bring negative margins but be accompanied by a loss of exocrine/endocrine function. When choosing distal pancreatectomy, positive margins might be inevitable. We used to choose primary or complete TP for this type of neoplasm in our department 8 years ago. After the first DVPPSP was performed successfully, this procedure

became our first choice when negative margins could be achieved at the pancreatic head. Intraoperative EUS and frozen sectioning are indispensable to decide where to perform limited pancreatic resection and to achieve negative margins. It is worth noting that only patients with benign or low-grade pancreatic neoplasms are selected as candidates for DVPPSP. The patients with such neoplasms could obtain long disease-free life expectancy if negative margins are achieved^[18-20]. If invasive features or any doubts about the low-grade character of the stump were found in the frozen section, DVPPSP was immediately converted to TP with formal lymphadenectomy.

Moreover, diseases such as IPMN might predispose the entire gland, especially for the type of main duct, so detailed examination (such as endoscopic ultrasonography) could be needed before DVPPSP to detect the condition of the main duct^[21]. DVPPSP is suitable for disease with a normal Wirsung duct in the ventral pancreas. If the entire duct is involved, the ventral pancreas should not be preserved. In this case, duodenum preserving total/subtotal pancreatic resection might be the best choice^[22].

Due to the biological features of low-grade malignant neoplasms, normal interstitial space exists between the neoplasm and the peri-pancreatic tissue. This space is the key prerequisite to perform DVPPSP successfully. According to Yoshihiro's research^[14] based on autopsy specimens, the dorsal pancreas makes up the pancreatic neck, body, and tail, as well as the anterior segment of the head, whereas the ventral pancreas comprises the posterior segment of the head and uncinate process. Moreover, Thayer *et al.*^[8] described the embryonic fusion plane of the two segments as a clear fibrous septum. These anatomic features make the duodenum and ventral pancreas preserving subtotal pancreatectomy (DVPPSP) a theoretically feasible procedure. As this plane was difficult to identify by some researchers^[23] and by us in practice, we performed the pancreatic transection along the anterior side of the CBD and exposed the entire distal CBD (except 1-2 cm from the major papilla) to achieve negative margins. The confluence of the CBD with the ventral duct and ventral pancreas was carefully preserved.

A case of complete dorsal pancreatectomy was presented previously^[8], with the first part of the duodenum resected due to ischemic damage. The gastroduodenal artery (GDA) was ligated in that procedure, while both the gastroduodenal artery and the posterior pancreaticoduodenal arterial arcade were preserved in our series. Additionally, the Kocher manoeuvre was suggested to increase the risk of duodenal ischemia in another previous case report^[23]. However, we performed a complete Kocher manoeuvre to make the potential haemorrhage easier to control and to make the surgical procedure smoother during resection of

the cephalic side of the pancreas. The duodenum was not found to be cyanotic in our present study with 10 DVPPSP cases. Careful dissection and reservation of the GDA and the posterior pancreaticoduodenal arterial arcade appeared to be essential for preservation of the duodenum in DVPPSP. The successful preservation of the duodenum prevents reconstruction in the upper digestive tract.

Our results (Table 2) also demonstrated that, compared with the TP group, DVPPSP had comparable short-term postoperative morbidities. Postoperative pancreatic fistula (POPF) is the most common complication after pancreatectomy^[24,25]. However, clinical POPF (Grade B or C) was not detected in the 10 patients who underwent DVPPSP according to the revised definition by the International Study Group on Pancreatic Fistula (ISGPF)^[26]. DVPPSP appears to be a safe and feasible procedure for selected low-grade pancreatic neoplasms based on our results. As shown in Table 2, 33.3% IPMN in the DVPPSP group and 45.5% IPMN in the TP group were shown to have recurrences ($P = 1.000$). The rate of postoperative recurrence of IPMN appeared slightly high compared with previous reports (0%-30%)^[27-29]. The malignant component was suggested to be associated with tumor recurrence^[29,30]. The high rate of malignancy (high-grade dysplasia or invasive carcinoma, 13/17, 76.5%; Table 1) of IPMN in our study might play a role in this recurrence, which was reported by others^[29,31,32] to range from 35.7% to 68%. Furthermore, the small number of patients prevented us from making strong conclusions.

Given the long life expectancy after surgery for these diseases, the postoperative long-term pancreatic function and QoL become a major concern. Compared with the TP group, we found that DVPPSP did preserve better long-term pancreatic function with less supplementary therapy and resulted in better QoL after surgery in the follow-up of our study. No new-onset diabetes occurred in the DVPPSP group in the follow-up. Only one out of three patients had diabetes worsen, as shown in Table 4. This reservation could be attributed to less loss of the pancreatic parenchyma in DVPPSP.

In recent years, several investigators have advocated that postoperative QoL is as significant a clinical outcome as morbidity and mortality. The QoL of DVPPSP compared with TP in this study appeared to be better no matter replacement therapy or survey of quality of life. The high dependence of pancreatic enzyme replacement and insulin mainly negatively impacted the social and global quality of life in TP patients. The diabetes after TP could cause a negative impact on QoL^[33]. More patients in the TP group felt a loss of appetite compared with patients in the DVPPSP group, perhaps because of manual changes of the digestive tract. The enterogastric reflux was considered an

unavoidable consequence after reconstruction in the upper digestive tract^[34]. The great advantage of DVPPSP is preservation of the natural digestive channel. Other reports have demonstrated better QoL in duodenum preserving pancreatic surgery^[35-37].

Our study is limited by the small number of cases because of the infrequent indications for DVPPSP. Some questions need to be researched further. A major limitation of the present study was its retrospective nature, which prevented us from making strong conclusions. Quality of life metrics were administered only once and were not compared with preoperative baseline measurements.

In conclusion, DVPPSP is a feasible and safe procedure that could be an alternative to TP for low-grade neoplasms arising from the body and tail region but across the neck region of the pancreas, with a better metabolic function and QoL after surgery.

COMMENTS

Background

Parenchyma-sparing procedures are increasingly performed for low-grade pancreatic neoplasms, such as intraductal papillary mucinous neoplasms (IPMNs), neuroendocrine tumors, and pseudo-papillary tumors. These procedures preserve the pancreatic parenchyma and decrease the risk of long-term endocrine and exocrine dysfunction. The conventional parenchyma-sparing procedures, such as enucleation and central pancreatectomy, are unable to substitute for total pancreatectomy (TP) for lesions involving the head, body and tail of the pancreas. Herein, we report our experience of duodenum and ventral pancreas preserving subtotal pancreatectomy (DVPPSP), which could be an alternative procedure to TP for low-grade pancreatic neoplasms.

Research frontiers

Although TP could be performed safely as reported by different authors in studies, patients would suffer from the pain of replacement therapy throughout their lives. These results showed that DVPPSP is safe and effective for preserving the exocrine/endocrine function of the gland, with a better metabolic function and QoL after surgery. DVPPSP could be an alternative to TP for low-grade neoplasms arising from the body and tail region but across the neck region of the pancreas.

Innovations and breakthroughs

This study described the indications, operative technique and outcomes of the novel surgical procedure DVPPSP. Furthermore, comparisons between DVPPSP with TP were presented in the present study. The findings indicate that DVPPSP is a feasible and safe procedure and could be an alternative to TP for low-grade neoplasms arising from the body and tail region but across the neck region of the pancreas, with a better metabolic function and QoL after surgery.

Applications

DVPPSP is a feasible and safe procedure. It could be an alternative to TP for low-grade neoplasms arising from the body and tail region but across the neck region of the pancreas, with a better metabolic function and QoL after surgery.

Terminology

The DVPPSP is a parenchyma-sparing procedure and could be an alternative to TP for low-grade neoplasms arising from the body and tail region but across the neck region of the pancreas.

Peer-review

The present study explored a new surgical technique so called "duodenum and

ventral pancreas preserving subtotal pancreatectomy" as a choice of treatment for low-grade pancreatic neoplasms, such as IPMN, neuroendocrine tumors and pseudo-papillary tumors. The results showed DVPPSP was superior to total pancreatectomy by shorter operative time, better postoperative pancreatic function and better quality of life. But there was no detail pathological examination information of surgical specimens and follow-up data about tumor recurrence in the study. AS mentioned in the result of this article, why the rate of postoperative recurrence of IPMN was so high, 2 out of 6 for DVPPSP and 5 out of 11.

REFERENCES

- 1 **Faitot F**, Gaujoux S, Barbier L, Novaes M, Dokmak S, Aussilhou B, Couvelard A, Rebours V, Ruszniewski P, Belghiti J, Sauvanet A. Reappraisal of pancreatic enucleations: A single-center experience of 126 procedures. *Surgery* 2015; **158**: 201-210 [PMID: 25956743 DOI: 10.1016/j.surg.2015.03.023]
- 2 **Briggs CD**, Mann CD, Irving GR, Neal CP, Peterson M, Cameron IC, Berry DP. Systematic review of minimally invasive pancreatic resection. *J Gastrointest Surg* 2009; **13**: 1129-1137 [PMID: 19130151 DOI: 10.1007/s11605-008-0797-z]
- 3 **Hüttner FJ**, Koessler-Ebs J, Hackert T, Ulrich A, Büchler MW, Diener MK. Meta-analysis of surgical outcome after enucleation versus standard resection for pancreatic neoplasms. *Br J Surg* 2015; **102**: 1026-1036 [PMID: 26041666 DOI: 10.1002/bjs.9819]
- 4 **Chua TC**, Yang TX, Gill AJ, Samra JS. Systematic Review and Meta-Analysis of Enucleation Versus Standardized Resection for Small Pancreatic Lesions. *Ann Surg Oncol* 2016; **23**: 592-599 [PMID: 26307231 DOI: 10.1245/s10434-015-4826-3]
- 5 **Bilimoria KY**, Talamonti MS, Tomlinson JS, Stewart AK, Winchester DP, Ko CY, Bentrem DJ. Prognostic score predicting survival after resection of pancreatic neuroendocrine tumors: analysis of 3851 patients. *Ann Surg* 2008; **247**: 490-500 [PMID: 18376195 DOI: 10.1097/SLA.0b013e31815b9cae]
- 6 **Sauvanet A**. Intraductal papillary mucinous neoplasms of the pancreas: indication, extent, and results of surgery. *Surg Oncol Clin N Am* 2008; **17**: 587-606, ix [PMID: 18486885 DOI: 10.1016/j.soc.2008.03.002]
- 7 **Benhaim R**, Oussoultzoglou E, Saeedi Y, Mouracade P, Bachellier P, Lang H. Pancreatic metastasis from clear cell renal cell carcinoma: outcome of an aggressive approach. *Urology* 2015; **85**: 135-140 [PMID: 25530375 DOI: 10.1016/j.urology.2014.09.034]
- 8 **Thayer SP**, Fernández-del Castillo C, Balcom JH, Warshaw AL. Complete dorsal pancreatectomy with preservation of the ventral pancreas: a new surgical technique. *Surgery* 2002; **131**: 577-580 [PMID: 12019413]
- 9 **Beger HG**, Rau BM, Gansauge F, Poch B. Duodenum-preserving subtotal and total pancreatic head resections for inflammatory and cystic neoplastic lesions of the pancreas. *J Gastrointest Surg* 2008; **12**: 1127-1132 [PMID: 18299945 DOI: 10.1007/s11605-008-0472-4]
- 10 **Klempa I**, Spatny M, Menzel J, Baca I, Nustede R, Stöckmann F, Arnold W. [Pancreatic function and quality of life after resection of the head of the pancreas in chronic pancreatitis. A prospective, randomized comparative study after duodenum preserving resection of the head of the pancreas versus Whipple's operation]. *Chirurg* 1995; **66**: 350-359 [PMID: 7634946]
- 11 **Bassi C**, Dervenis C, Butturini G, Fingerhut A, Yeo C, Izbicki J, Neoptolemos J, Sarr M, Traverso W, Buchler M; International Study Group on Pancreatic Fistula Definition. Postoperative pancreatic fistula: an international study group (ISGPF) definition. *Surgery* 2005; **138**: 8-13 [PMID: 16003309 DOI: 10.1016/j.surg.2005.05.001]
- 12 **Wente MN**, Bassi C, Dervenis C, Fingerhut A, Gouma DJ, Izbicki JR, Neoptolemos JP, Padbury RT, Sarr MG, Traverso LW, Yeo CJ, Büchler MW. Delayed gastric emptying (DGE) after pancreatic surgery: a suggested definition by the International Study Group of Pancreatic Surgery (ISGPS). *Surgery* 2007; **142**: 761-768 [PMID:

- 17981197 DOI: 10.1016/j.surg.2007.05.005]
- 13 **Wente MN**, Veit JA, Bassi C, Dervenis C, Fingerhut A, Gouma DJ, Izbicki JR, Neoptolemos JP, Padbury RT, Sarr MG, Yeo CJ, Büchler MW. Postpancreatectomy hemorrhage (PPH): an International Study Group of Pancreatic Surgery (ISGPS) definition. *Surgery* 2007; **142**: 20-25 [PMID: 17629996 DOI: 10.1016/j.surg.2007.02.001]
 - 14 **Sakamoto Y**, Nagai M, Tanaka N, Nobori M, Tsukamoto T, Nokubi M, Suzuki Y, Makuuchi M. Anatomical segmentectomy of the head of the pancreas along the embryological fusion plane: a feasible procedure? *Surgery* 2000; **128**: 822-831 [PMID: 11056446 DOI: 10.1067/msy.2000.109611]
 - 15 **Heidt DG**, Burant C, Simeone DM. Total pancreatectomy: indications, operative technique, and postoperative sequelae. *J Gastrointest Surg* 2007; **11**: 209-216 [PMID: 17390175 DOI: 10.1007/s11605-006-0025-7]
 - 16 **Schmidt CM**, Glant J, Winter JM, Kennard J, Dixon J, Zhao Q, Howard TJ, Madura JA, Nakeeb A, Pitt HA, Cameron JL, Yeo CJ, Lillemoe KD. Total pancreatectomy (R0 resection) improves survival over subtotal pancreatectomy in isolated neck margin positive pancreatic adenocarcinoma. *Surgery* 2007; **142**: 572-578; discussion 578-580 [PMID: 17950350 DOI: 10.1016/j.surg.2007.07.016]
 - 17 **Watanabe Y**, Ohtsuka T, Matsunaga T, Kimura H, Tamura K, Ideno N, Aso T, Miyasaka Y, Ueda J, Takahata S, Igarashi H, Inoguchi T, Ito T, Tanaka M. Long-term outcomes after total pancreatectomy: special reference to survivors' living conditions and quality of life. *World J Surg* 2015; **39**: 1231-1239 [PMID: 25582768 DOI: 10.1007/s00268-015-2948-1]
 - 18 **Sahora K**, Fernández-del Castillo C, Dong F, Marchegiani G, Thayer SP, Ferrone CR, Sahani DV, Brugge WR, Warshaw AL, Lillemoe KD, Mino-Kenudson M. Not all mixed-type intraductal papillary mucinous neoplasms behave like main-duct lesions: implications of minimal involvement of the main pancreatic duct. *Surgery* 2014; **156**: 611-621 [PMID: 25081232 DOI: 10.1016/j.surg.2014.04.023]
 - 19 **Yang M**, Zeng L, Zhang Y, Su AP, Yue PJ, Tian BL. Surgical treatment and clinical outcome of nonfunctional pancreatic neuroendocrine tumors: a 14-year experience from one single center. *Medicine* (Baltimore) 2014; **93**: e94 [PMID: 25396335 DOI: 10.1097/MD.0000000000000094]
 - 20 **Yu P**, Cheng X, Du Y, Yang L, Xu Z, Yin W, Zhong Z, Wang X, Xu H, Hu C. Solid Pseudopapillary Neoplasms of the Pancreas: a 19-Year Multicenter Experience in China. *J Gastrointest Surg* 2015; **19**: 1433-1440 [PMID: 26001371 DOI: 10.1007/s11605-015-2862-8]
 - 21 **Uehara H**, Ishikawa O, Ikezawa K, Kawada N, Inoue T, Takakura R, Takano Y, Tanaka S, Takenaka A. A natural course of main duct intraductal papillary mucinous neoplasm of the pancreas with lower likelihood of malignancy. *Pancreas* 2010; **39**: 653-657 [PMID: 20173670 DOI: 10.1097/MPA.0b013e3181c81b52]
 - 22 **Takada T**, Yasuda H, Uchiyama K, Hasegawa H. Duodenum-preserving pancreatoduodenostomy. A new technique for complete excision of the head of the pancreas with preservation of biliary and alimentary integrity. *Hepatogastroenterology* 1993; **40**: 356-359 [PMID: 8406305]
 - 23 **Scatton O**, Sauvanet A, Cazals-Hatem D, Vullierme MP, Ruszniewski P, Belghiti J. Dorsal pancreatectomy: an embryology-based resection. *J Gastrointest Surg* 2006; **10**: 434-438 [PMID: 16504892 DOI: 10.1016/j.gassur.2005.06.014]
 - 24 **Correa-Galleo C**, Brennan MF, D'Angelica M, Fong Y, Dematteo RP, Kingham TP, Jarnagin WR, Allen PJ. Operative drainage following pancreatic resection: analysis of 1122 patients resected over 5 years at a single institution. *Ann Surg* 2013; **258**: 1051-1058 [PMID: 23360918 DOI: 10.1097/SLA.0b013e3182813806]
 - 25 **Strobel O**, Cherrez A, Hinz U, Mayer P, Kaiser J, Fritz S, Schneider L, Klauss M, Büchler MW, Hackert T. Risk of pancreatic fistula after enucleation of pancreatic tumours. *Br J Surg* 2015; **102**: 1258-1266 [PMID: 26109380 DOI: 10.1002/bjs.9843]
 - 26 **Bassi C**, Marchegiani G, Dervenis C, Sarr M, Abu Hilal M, Adham M, Allen P, Andersson R, Asbun HJ, Besselink MG, Conlon K, Del Chiaro M, Falconi M, Fernandez-Cruz L, Fernandez-Del Castillo C, Fingerhut A, Friess H, Gouma DJ, Hackert T, Izbicki J, Lillemoe KD, Neoptolemos JP, Olah A, Schulick R, Shrikhande SV, Takada T, Takaori K, Traverso W, Vollmer CR, Wolfgang CL, Yeo CJ, Salvia R, Buchler M; International Study Group on Pancreatic Surgery (ISGPS). The 2016 update of the International Study Group (ISGPS) definition and grading of postoperative pancreatic fistula: 11 Years After. *Surgery* 2017; **161**: 584-591 [PMID: 28040257 DOI: 10.1016/j.surg.2016.11.014]
 - 27 **White R**, D'Angelica M, Katabi N, Tang L, Klimstra D, Fong Y, Brennan M, Allen P. Fate of the remnant pancreas after resection of noninvasive intraductal papillary mucinous neoplasm. *J Am Coll Surg* 2007; **204**: 987-993; discussion 993-995 [PMID: 17481526 DOI: 10.1016/j.jamcollsurg.2006.12.040]
 - 28 **Chari ST**, Yadav D, Smyrk TC, DiMaggio EP, Miller LJ, Raimondo M, Clain JE, Norton IA, Pearson RK, Petersen BT, Wiersema MJ, Farnell MB, Sarr MG. Study of recurrence after surgical resection of intraductal papillary mucinous neoplasm of the pancreas. *Gastroenterology* 2002; **123**: 1500-1507 [PMID: 12404225 DOI: 10.1053/gast.2002.36552]
 - 29 **Tanaka M**, Fernández-del Castillo C, Adsay V, Chari S, Falconi M, Jang JY, Kimura W, Levy P, Pittman MB, Schmidt CM, Shimizu M, Wolfgang CL, Yamaguchi K, Yamao K; International Association of Pancreatology. International consensus guidelines 2012 for the management of IPMN and MCN of the pancreas. *Pancreatology* 2012; **12**: 183-197 [PMID: 22687371 DOI: 10.1016/j.pan.2012.04.004]
 - 30 **Marchegiani G**, Mino-Kenudson M, Ferrone CR, Morales-Oyarvide V, Warshaw AL, Lillemoe KD, Castillo CF. Patterns of Recurrence After Resection of IPMN: Who, When, and How? *Ann Surg* 2015; **262**: 1108-1114 [PMID: 25793719 DOI: 10.1097/SLA.0000000000001008]
 - 31 **Kim SC**, Park KT, Lee YJ, Lee SS, Seo DW, Lee SK, Kim MH, Jang SJ, Byun JH, Han DJ. Intraductal papillary mucinous neoplasm of the pancreas: clinical characteristics and treatment outcomes of 118 consecutive patients from a single center. *J Hepatobiliary Pancreat Surg* 2008; **15**: 183-188 [PMID: 18392712 DOI: 10.1007/s00534-007-1231-8]
 - 32 **Emerson RE**, Randolph ML, Cramer HM. Endoscopic ultrasound-guided fine-needle aspiration cytology diagnosis of intraductal papillary mucinous neoplasm of the pancreas is highly predictive of pancreatic neoplasia. *Diagn Cytopathol* 2006; **34**: 457-462 [PMID: 16783773 DOI: 10.1002/dc.20446]
 - 33 **Epelboym I**, Winner M, DiNorcia J, Lee MK, Lee JA, Schroppe B, Chabot JA, Allendorf JD. Quality of life in patients after total pancreatectomy is comparable with quality of life in patients who undergo a partial pancreatic resection. *J Surg Res* 2014; **187**: 189-196 [PMID: 24411300 DOI: 10.1016/j.jss.2013.10.004]
 - 34 **Chan DC**, Fan YM, Lin CK, Chen CJ, Chen CY, Chao YC. Roux-en-Y reconstruction after distal gastrectomy to reduce enterogastric reflux and Helicobacter pylori infection. *J Gastrointest Surg* 2007; **11**: 1732-1740 [PMID: 17876675 DOI: 10.1007/s11605-007-0302-0]
 - 35 **Keck T**, Adam U, Makowiec F, Riediger H, Wellner U, Tittelbach-Helmrich D, Hopt UT. Short- and long-term results of duodenum preservation versus resection for the management of chronic pancreatitis: a prospective, randomized study. *Surgery* 2012; **152**: S95-S102 [PMID: 22906892 DOI: 10.1016/j.surg.2012.05.016]
 - 36 **Zheng Z**, Xiang G, Tan C, Zhang H, Liu B, Gong J, Mai G, Liu X. Pancreaticoduodenectomy versus duodenum-preserving

pancreatic head resection for the treatment of chronic pancreatitis. *Pancreas* 2012; **41**: 147-152 [PMID: 21775913 DOI: 10.1097/MPA.0b013e318221c91b]

37 **Lü WP**, Shi Q, Zhang WZ, Cai SW, Jiang K, Dong JH. A meta-

analysis of the long-term effects of chronic pancreatitis surgical treatments: duodenum-preserving pancreatic head resection versus pancreatoduodenectomy. *Chin Med J (Engl)* 2013; **126**: 147-153 [PMID: 23286494]

P- Reviewer: Zhang CW **S- Editor:** Qi Y **L- Editor:** A
E- Editor: Ma YJ

