

World Journal of *Gastroenterology*

World J Gastroenterol 2018 February 14; 24(6): 657-766



ORIGINAL ARTICLE

Basic Study

- 657** Role of *PTPN22* polymorphisms in pathophysiology of Crohn's disease
Sharp RC, Beg SA, Naser SA
- 671** Health-related quality of life, anxiety, depression and impulsivity in patients with advanced gastroenteropancreatic neuroendocrine tumours
Lewis AR, Wang X, Magdalani L, D'Arienzo P, Bashir C, Mansoor W, Hubner R, Valle JW, McNamara MG
- 680** Analysis of hepatitis B virus preS1 variability and prevalence of the rs2296651 polymorphism in a Spanish population
Casillas R, Tabernero D, Gregori J, Belmonte I, Cortese MF, González C, Riveiro-Barciela M, López RM, Quer J, Esteban R, Buti M, Rodríguez-Frías F
- 693** Inhibitory effects of patchouli alcohol on stress-induced diarrhea-predominant irritable bowel syndrome
Zhou TR, Huang JJ, Huang ZT, Cao HY, Tan B
- 706** Recombinant expressed vasoactive intestinal peptide analogue ameliorates TNBS-induced colitis in rats
Xu CL, Guo Y, Qiao L, Ma L, Cheng YY

Retrospective Study

- 716** Split-dose bowel preparation improves adequacy of bowel preparation and gastroenterologists' adherence to National Colorectal Cancer Screening and Surveillance Guidelines
Menees SB, Kim HM, Schoenfeld P
- 725** Clinical utility of hepatitis B surface antigen kinetics in treatment-naïve chronic hepatitis B patients during long-term entecavir therapy
Lin TC, Chiu YC, Chiu HC, Liu WC, Cheng PN, Chen CY, Chang TT, Wu IC
- 737** Performance of transient elastography in assessing liver fibrosis in patients with autoimmune hepatitis-primary biliary cholangitis overlap syndrome
Wu HM, Sheng L, Wang Q, Bao H, Miao Q, Xiao X, Guo CJ, Li H, Ma X, Qiu DK, Hua J

Clinical Practice Study

- 744 Value of contrast-enhanced ultrasound in the differential diagnosis of gallbladder lesion

Zhang HP, Bai M, Gu JY, He YQ, Qiao XH, Du LF

Observational Study

- 752 High prevalence of hepatitis B-antibody loss and a case report of *de novo* hepatitis B virus infection in a child after living-donor liver transplantation

Sintusek P, Posuwan N, Wanawongsawad P, Jitraruch S, Poovorawan Y, Chongsrisawat V

CASE REPORT

- 763 Gastroenteritis in an adult female revealing hemolytic uremic syndrome: Case report

Chinchilla-López P, Cruz-Ramón V, Ramírez-Pérez O, Méndez-Sánchez N

ABOUT COVER

Editorial board member of *World Journal of Gastroenterology*, Yoshiaki Iwasaki, MD, PhD, Professor, Health Service Center, Okayama University, Okayama 700-8530, Japan

AIMS AND SCOPE

World Journal of Gastroenterology (*World J Gastroenterol*, *WJG*, print ISSN 1007-9327, online ISSN 2219-2840, DOI: 10.3748) is a peer-reviewed open access journal. *WJG* was established on October 1, 1995. It is published weekly on the 7th, 14th, 21st, and 28th each month. The *WJG* Editorial Board consists of 642 experts in gastroenterology and hepatology from 59 countries.

The primary task of *WJG* is to rapidly publish high-quality original articles, reviews, and commentaries in the fields of gastroenterology, hepatology, gastrointestinal endoscopy, gastrointestinal surgery, hepatobiliary surgery, gastrointestinal oncology, gastrointestinal radiation oncology, gastrointestinal imaging, gastrointestinal interventional therapy, gastrointestinal infectious diseases, gastrointestinal pharmacology, gastrointestinal pathophysiology, gastrointestinal pathology, evidence-based medicine in gastroenterology, pancreatology, gastrointestinal laboratory medicine, gastrointestinal molecular biology, gastrointestinal immunology, gastrointestinal microbiology, gastrointestinal genetics, gastrointestinal translational medicine, gastrointestinal diagnostics, and gastrointestinal therapeutics. *WJG* is dedicated to become an influential and prestigious journal in gastroenterology and hepatology, to promote the development of above disciplines, and to improve the diagnostic and therapeutic skill and expertise of clinicians.

INDEXING/ABSTRACTING

World Journal of Gastroenterology (*WJG*) is now indexed in Current Contents[®]/Clinical Medicine, Science Citation Index Expanded (also known as SciSearch[®]), Journal Citation Reports[®], Index Medicus, MEDLINE, PubMed, PubMed Central and Directory of Open Access Journals. The 2018 edition of Journal Citation Reports[®] cites the 2016 impact factor for *WJG* as 3.365 (5-year impact factor: 3.176), ranking *WJG* as 29th among 79 journals in gastroenterology and hepatology (quartile in category Q2).

EDITORS FOR THIS ISSUE

Responsible Assistant Editor: *Xiang Li*
Responsible Electronic Editor: *Yu-Jie Ma*
Proofing Editor-in-Chief: *Lian-Sheng Ma*

Responsible Science Editor: *Xue-Jiao Wang*
Proofing Editorial Office Director: *Ze-Mao Gong*

NAME OF JOURNAL
World Journal of Gastroenterology

ISSN
ISSN 1007-9327 (print)
ISSN 2219-2840 (online)

LAUNCH DATE
October 1, 1995

FREQUENCY
Weekly

EDITORS-IN-CHIEF
Damian Garcia-Olmo, MD, PhD, Doctor, Professor, Surgeon, Department of Surgery, Universidad Autonoma de Madrid; Department of General Surgery, Fundacion Jimenez Diaz University Hospital, Madrid 28040, Spain

Stephen C Strom, PhD, Professor, Department of Laboratory Medicine, Division of Pathology, Karolinska Institutet, Stockholm 141-86, Sweden

Andrzej S Tarnawski, MD, PhD, DSc (Med), Professor of Medicine, Chief Gastroenterology, VA Long Beach Health Care System, University of California, Irvine, CA, 5901 E. Seventh Str., Long Beach,

CA 90822, United States

EDITORIAL BOARD MEMBERS
All editorial board members resources online at <http://www.wjgnet.com/1007-9327/editorialboard.htm>

EDITORIAL OFFICE
Ze-Mao Gong, Director
World Journal of Gastroenterology
Baishideng Publishing Group Inc
7901 Stoneridge Drive, Suite 501,
Pleasanton, CA 94588, USA
Telephone: +1-925-2238242
Fax: +1-925-2238243
E-mail: editorialoffice@wjgnet.com
Help Desk: <http://www.f0publishing.com/helpdesk>
<http://www.wjgnet.com>

PUBLISHER
Baishideng Publishing Group Inc
7901 Stoneridge Drive, Suite 501,
Pleasanton, CA 94588, USA
Telephone: +1-925-2238242
Fax: +1-925-2238243
E-mail: bpoffice@wjgnet.com
Help Desk: <http://www.f0publishing.com/helpdesk>
<http://www.wjgnet.com>

PUBLICATION DATE
February 14, 2018

COPYRIGHT
© 2018 Baishideng Publishing Group Inc. Articles published by this Open-Access journal are distributed under the terms of the Creative Commons Attribution Non-commercial License, which permits use, distribution, and reproduction in any medium, provided the original work is properly cited, the use is non commercial and is otherwise in compliance with the license.

SPECIAL STATEMENT
All articles published in journals owned by the Baishideng Publishing Group (BPG) represent the views and opinions of their authors, and not the views, opinions or policies of the BPG, except where otherwise explicitly indicated.

INSTRUCTIONS TO AUTHORS
Full instructions are available online at <http://www.wjgnet.com/bpg/gerinfo/204>

ONLINE SUBMISSION
<http://www.f0publishing.com>

Clinical Practice Study

Value of contrast-enhanced ultrasound in the differential diagnosis of gallbladder lesion

Hui-Ping Zhang, Min Bai, Ji-Ying Gu, Ying-Qian He, Xiao-Hui Qiao, Lian-Fang Du

Hui-Ping Zhang, Min Bai, Ji-Ying Gu, Ying-Qian He, Xiao-Hui Qiao, Lian-Fang Du, Department of Ultrasound, Shanghai General Hospital, Shanghai Jiao Tong University School of Medicine, Shanghai 200080, China

ORCID number: Hui-Ping Zhang (0000-0002-3890-6436); Min Bai (0000-0002-3513-3458); Ji-Ying Gu (0000-0002-0664-5753); Ying-Qian He (0000-0002-9758-0499); Xiao-Hui Qiao (0000-0003-2515-6477); Lian-Fang Du (0000-0001-5952-4368).

Author contributions: Zhang HP and Du LF design the research; Bai M, Gu JY and He YQ performed the research; Qiao XH analyzed the data; Zhang HP wrote the paper.

Supported by the National Natural Science Foundation of China, No. 81301232.

Institutional review board statement: This study was reviewed and approved by the Ethics Committee of Shanghai General Hospital (No. 2013-094).

Informed consent statement: All study participants provided written informed consent prior to study enrollment.

Conflict-of-interest statement: None of the authors have any conflict of interest disclosures to make.

Data sharing statement: No additional data are available.

Open-Access: This article is an open-access article which was selected by an in-house editor and fully peer-reviewed by external reviewers. It is distributed in accordance with the Creative Commons Attribution Non Commercial (CC BY-NC 4.0) license, which permits others to distribute, remix, adapt, build upon this work non-commercially, and license their derivative works on different terms, provided the original work is properly cited and the use is non-commercial. See: <http://creativecommons.org/licenses/by-nc/4.0/>

Manuscript source: Unsolicited manuscript

Correspondence to: Lian-Fang Du, MD, Chief Doctor, Full Professor, Department of Ultrasound, Shanghai General Hospital, Shanghai Jiao Tong University School of Medicine, 100

Haining Road, Shanghai 200080, China. du_lf@163.com
Telephone: +86-21-63240090

Received: December 8, 2017

Peer-review started: December 8, 2017

First decision: December 21, 2017

Revised: January 3, 2018

Accepted: January 16, 2018

Article in press: January 16, 2018

Published online: February 14, 2018

Abstract

AIM

To describe contrast-enhanced ultrasound (CEUS) features and evaluate differential diagnosis value of CEUS and conventional ultrasound for patients with benign and malignant gallbladder lesions.

METHODS

This study included 105 gallbladder lesions. Before surgical resection and pathological examination, conventional ultrasound and CEUS were performed to examine for lesions. Then, all the lesions were diagnosed as (1) benign, (2) probably benign, (3) probably malignant or (4) malignant using both conventional ultrasound and CEUS. The CEUS features of these gallbladder lesions were analyzed and diagnostic efficiency between conventional ultrasound and CEUS was compared.

RESULTS

There were total 17 cases of gallbladder cancer and 88 cases of benign lesion. Some gallbladder lesions had typical characteristics on CEUS (*e.g.*, gallbladder adenomyomatosis had typical characteristics of small nonenhanced areas on CEUS). The sensitivity, specificity, positive predictive value, negative predictive value and accuracy of CEUS were 94.1%, 95.5%, 80.0%, 98.8%

and 95.2%, respectively. These were significantly higher than conventional ultrasound (82.4%, 89.8%, 60.9%, 96.3% and 88.6%, respectively). CEUS had an accuracy of 100% for gallbladder sludge and CEUS helped in differential diagnosis among gallbladder polyps, gallbladder adenoma and gallbladder cancer.

CONCLUSION

CEUS may provide more useful information and improve the diagnosis efficiency for the diagnosis of gallbladder lesions than conventional ultrasound.

Key words: Contrast enhanced ultrasound; Conventional ultrasound; Gallbladder carcinoma; Gallbladder adenomyomatosis

© The Author(s) 2018. Published by Baishideng Publishing Group Inc. All rights reserved.

Core tip: With the advent of ultrasound contrast agents, contrast-enhanced ultrasound (CEUS) is playing a more and more important role clinically. However, the value of CEUS in gallbladder lesions has not been widely accepted yet. In this study, we evaluated the differential diagnosis value of CEUS and conventional ultrasound for patients with benign and malignant gallbladder lesions. Our results showed that CEUS may provide more useful information and improve diagnosis efficiency for the diagnosis of gallbladder lesions than conventional ultrasound.

Zhang HP, Bai M, Gu JY, He YQ, Qiao XH, Du LF. Value of contrast-enhanced ultrasound in the differential diagnosis of gallbladder lesion. *World J Gastroenterol* 2018; 24(6): 744-751 Available from: URL: <http://www.wjgnet.com/1007-9327/full/v24/i6/744.htm> DOI: <http://dx.doi.org/10.3748/wjg.v24.i6.744>

INTRODUCTION

Conventional ultrasound is the primary and most important imaging modality for gallbladder diseases. The excellent image contrast between anechoic bile and gallbladder wall or gallbladder diseases, and the increasingly improved ultrasound spatial resolution ensure conventional ultrasound to have a high detection rate of gallbladder diseases^[1]. With the advantages of real-time imaging, safety with no radiation, great cost effectiveness and great spatial resolution, conventional ultrasound makes itself more suitable than computed tomography (CT) and magnetic resonance imaging (MRI) for the detection of gallbladder diseases^[2].

Despite the above-mentioned advantages of conventional ultrasound, the sensitivity and accuracy are not satisfactory, especially when stones or some other gallbladder lesions fill the gallbladder lumen^[3,4]. With no information of microvasculature, it is very hard to differentiate some benign diseases, such as benign

gallbladder wall thickening or motionless sludge, from malignant ones using conventional ultrasound. The application of microbubbles could help in the differential diagnosis by providing useful perfusion information in the lesions^[5].

Contrast-enhanced ultrasound (CEUS) has been widely used in liver disease, with an excellent diagnostic efficiency comparable to contrast-enhanced CT^[6-8]. The value of CEUS in other organs, such as kidney, breast, etc., has also been well established and identified^[9,10]. Although the value in gallbladder has not been recognized and accepted by the European Federation of Societies for Ultrasound in Medicine and Biology^[11], there have been some studies which have shown the usefulness of CEUS in the differential diagnosis between benign and malignant gallbladder lesions^[5,12].

In this study, we described CEUS features and evaluated differential diagnosis value of CEUS and conventional ultrasound for patients with benign and malignant gallbladder lesions.

MATERIALS AND METHODS

Study design

The Ethics Committee of our hospital approved this study. Before the sonographic examination, we obtained all patients' written informed consent. The features of gallbladder lesions in CEUS were analyzed and described retrospectively. The study and comparison of the diagnostic efficiency between CEUS and conventional ultrasound was designed prospectively.

Patients

Between December 2012 and October 2016, 136 gallbladder lesions in 133 patients were imaged using both conventional ultrasound and CEUS in our hospital. Of these, 31 lesions were excluded from this study because the patients did not undergo cholecystectomy and were without pathological diagnosis. Therefore, 105 gallbladder lesions in 103 patients (47 males and 56 females; mean age \pm standard deviation, 42.5 \pm 10.6 years) were included in this study.

Conventional ultrasound and CEUS

All the conventional ultrasound and CEUS examinations were performed by an ultrasound physician with thirteen years' experience in conventional ultrasound and five years' experience in CEUS. An Acuson S2000 diagnostic ultrasound system or an Acuson Sequoia 512 diagnostic ultrasound system (Siemens Medical Solutions, Mountain View, CA, United States) equipped with a transabdominal curvilinear transducer running on Cadence™ Contrast pulse sequence (CPS) software were used for all the ultrasound examinations. All the patients fasted at least for 8 h before the examinations.

Conventional ultrasound examinations were first performed to detect the gallbladder lesions.

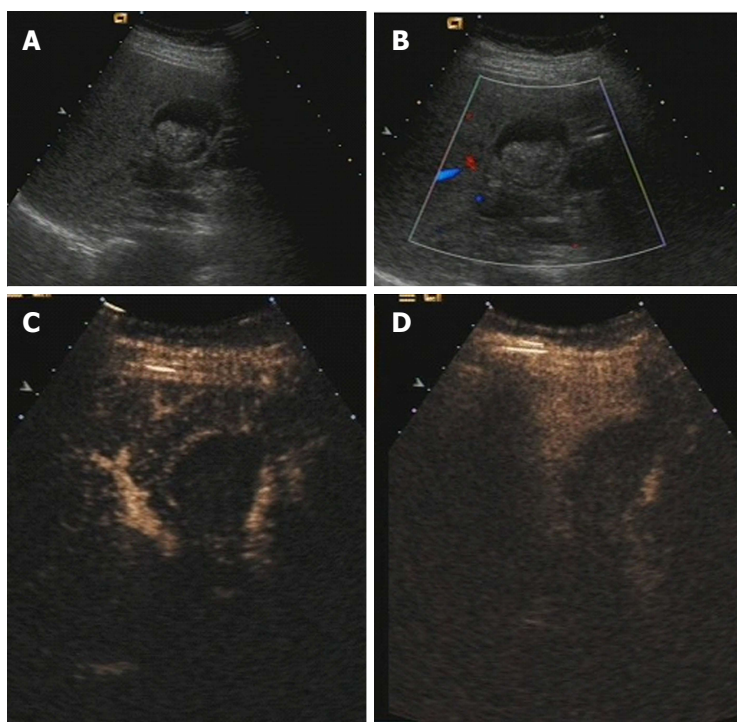


Figure 1 Gallbladder sludge in a 54-year-old female patient. A: B-mode sonography showed a hypoechoic, well-defined mass in the gallbladder, with an intact gallbladder wall; B: Color Doppler ultrasound showed no color Doppler signal in the lesion. According to A and B, a diagnosis of probably benign was made; C: CEUS showed complete nonenhancement on arterial phase; D: CEUS showed complete nonenhancement on venous phase. According to C and D, a diagnosis of benign gallbladder sludge was made. CEUS: Contrast-enhanced ultrasound.

Table 1 Diagnostic results of conventional ultrasound *n* (%)

	Benign		Malignant	
	definitely	probably	probably	definitely
Benign, <i>n</i> = 88	61 (69.3)	18 (20.5)	8 (9.1)	1 (1.1)
Malignant, <i>n</i> = 17	0 (0)	3 (17.6)	5 (29.4)	9 (52.9)

The lesion's size, location, shape, stalk, boundary, echogenicity and wall destruction were analyzed and recorded. Then, Doppler vascularity was observed using color Doppler ultrasound. A diagnosis of benign, probably benign, probably malignant or malignant was made according to conventional ultrasound features, by two radiologists with at least ten years' experience in both conventional ultrasound and CEUS. If they concluded different diagnosis, a third radiologist (with twenty-five years' experience in conventional ultrasound and twelve years' experience in CEUS) discussed together with them and decided on a final diagnosis.

For CEUS examinations, the same ultrasound machines were used. SonoVue (Bracco, Italy), the only microbubbles permitted for clinical use in China, was used in this study and was prepared following the appropriate guidelines before examinations. Every patient was instructed to take gentle and steady breaths to minimize the influence by respiratory movement. When the target lesion was shown clearly using conventional ultrasound, the CPS mode (MI: 0.21) was activated. A dose of 1.6 mL of SonoVue was

administered through the antecubital vein as a bolus immediately followed by 5 mL 0.9% saline solution. A stopwatch was started at the same time. The image was observed and recorded for 2 min and then the whole gallbladder and the liver were scanned to find other lesions and liver infiltration. After that, CEUS features of the lesion were analyzed and a diagnosis of benign, probably benign, probably malignant or malignant was made according to CEUS features by the above-mentioned radiologists.

After the resection of gallbladder lesions and the final pathological diagnosis was made, CEUS images were reviewed and the features of each kind of gallbladder lesions in CEUS were analyzed and summarized.

Statistical analysis

SPSS version 13.0 software (IBM Corporation, Chicago, IL, United States) was used for statistical analysis. $P < 0.05$ was considered a statistically significant difference. The diagnostic efficiency of conventional ultrasound and CEUS was assessed in terms of sensitivity, specificity, positive predictive value, negative predictive value and accuracy and was compared using chi-square test and Fisher's exact test.

RESULTS

Pathological results

There were 17 malignant and 88 benign gallbladder lesions in total in this study according to the histo-

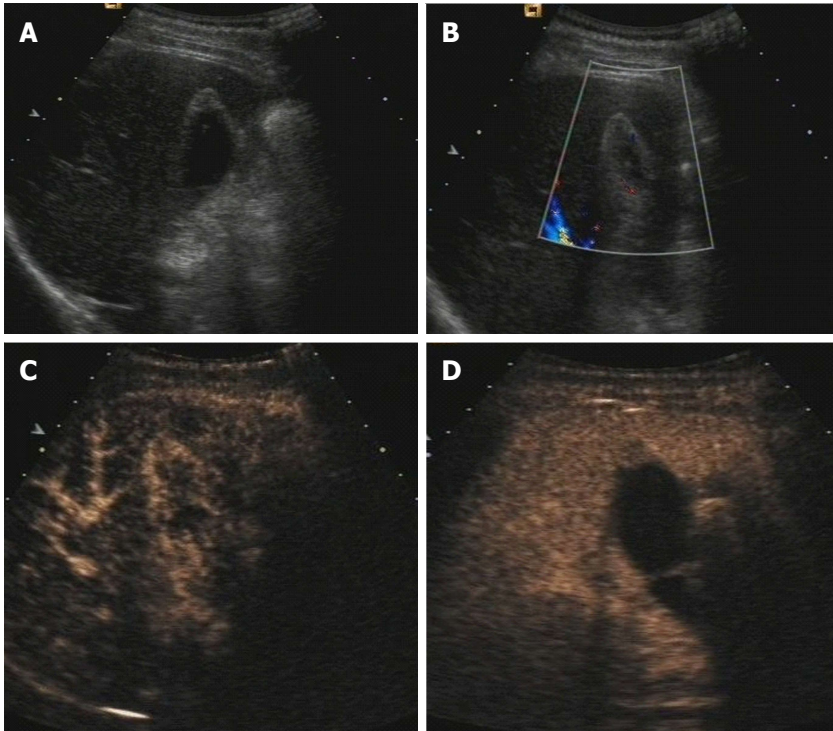


Figure 2 Gallbladder adenomyomatosis in a 62-year-old male patient. A: B-mode sonography showed a heterogeneously hypoechoic lesion on the gallbladder wall, with an intact gallbladder wall; B: Color Doppler ultrasound showed no color Doppler signal in the lesion. According to A and B, a diagnosis of probably benign was made. C: CEUS showed heterogeneously enhanced, with some small nonenhanced areas, on arterial phase; D: CEUS showed heterogeneously enhanced, with some small nonenhanced areas, on venous phase. According to C and D, a diagnosis of benign gallbladder adenomyomatosis was made. CEUS: Contrast-enhanced ultrasound.

Table 2 Diagnostic efficiency of conventional ultrasound and contrast-enhanced ultrasound between benign and malignant gallbladder lesions *n* (%)

Features of lesions	Sensitivity	Specificity	Positive predictive value	Negative predictive value	Accuracy
Conventional ultrasound	82.4	89.8	60.9	96.3	88.6
Contrast-enhanced ultrasound	94.1	95.5	80.0	98.8	95.2
<i>P</i> value	0.301	0.124	0.152	0.297	0.064

pathological diagnosis after cholecystectomy, including 17 cases of gallbladder cancer, 11 case of gallbladder sludge, 28 cases of gallbladder adenomyomatosis, 36 cases of gallbladder polyps and 13 cases of gallbladder adenoma.

Sonographic features on CEUS

All the cases of gallbladder sludge were shown as completely nonenhanced on CEUS, and the diagnostic accuracy was 100% (Figure 1).

Gallbladder adenomyomatosis was mostly shown as heterogeneously enhanced, with some small nonenhanced areas (represented as Rokitansky-Aschoff sinuses) on both arterial phase and venous phase (Figure 2). Some of them were together with echogenic foci and tail sign.

Gallbladder polyps and gallbladder adenoma were mostly shown as homogeneously hyperenhanced on arterial phase and isoenhanced on venous phase. The

gallbladder wall was intact and the surrounding tissue was normal, with no invasion (Figure 3).

The appearances of gallbladder cancer on CEUS were various. It could be a mass in gallbladder which was heterogeneously hyperenhanced on arterial phase and washed out quickly (Figure 4). Or, the irregular thickness of gallbladder, which was also heterogeneously hyperenhanced on arterial phase and washed out quickly, could be a sign of malignancy. In some cases, the intact gallbladder wall was destroyed or the surrounding liver tissue was invaded.

Besides providing microvascular information, CEUS makes the contour of a lesion much clearer and the evaluation of a lesion's shape, size and boundary much more accurate.

Diagnostic efficiency of conventional ultrasound

The diagnostic results of conventional ultrasound are shown in Table 1. There were 3 malignant lesions

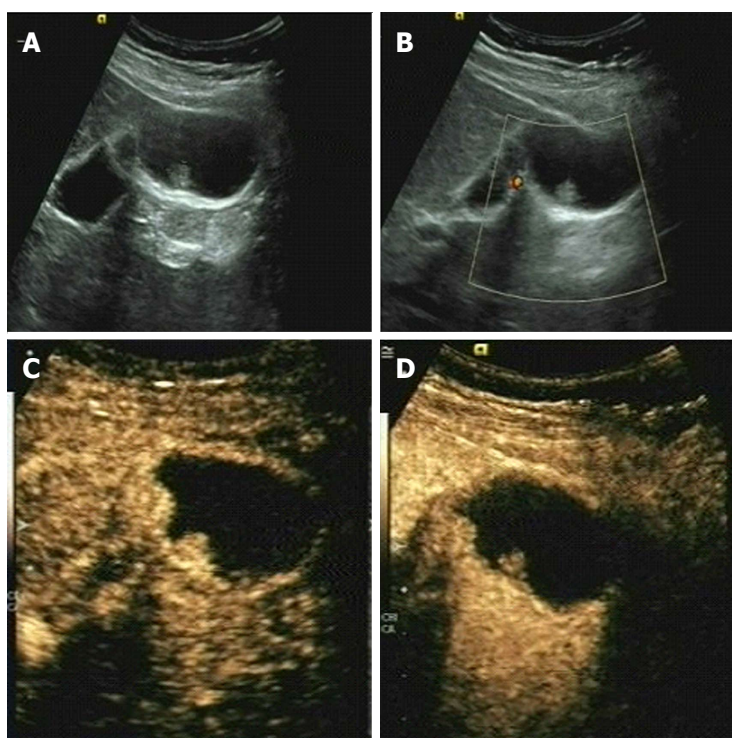


Figure 3 Gallbladder polyps in a 38-year-old male patient. A: B-mode sonography showed a homogeneously isoechoic lesion in the gallbladder, with an intact gallbladder wall; B: Color Doppler ultrasound showed no color Doppler signal in the lesion. According to A and B, a diagnosis of probably benign was made. C: CEUS showed a homogeneous and a little hyperenhanced lesion in the gallbladder on arterial phase; D: CEUS showed the enhancement of the lesion is similar to the surrounding gallbladder wall on venous phase. According to C and D, a diagnosis of benign lesion was made. CEUS: Contrast-enhanced ultrasound.

Table 3 The Diagnostic results of contrast-enhanced ultrasound *n* (%)

	Benign		Malignant	
	Definitely	Probably	Probably	Definitely
Benign, <i>n</i> = 88	78 (88.6)	6 (6.8)	4 (4.5)	0 (0)
Malignant, <i>n</i> = 17	0 (0)	1 (5.9)	6 (35.3)	10 (58.8)

misdiagnosed as probably benign and 5 diagnosed as probably malignant. There were 8 benign lesions (2 cases of sludge, 3 cases of adenomyomatosis, 2 cases of polyps and 1 case of gallbladder adenoma) misdiagnosed as probably malignant, and one benign lesion misdiagnosed as definitely malignant (1 case of adenoma). A total of 18 benign lesions (3 cases of sludge, 5 cases of adenomyomatosis, 5 cases of polyps and 5 cases of gallbladder adenoma) were diagnosed as probably benign.

The sensitivity, specificity, positive predictive value, negative predictive value and accuracy of conventional ultrasound were shown in Table 2.

Diagnostic efficiency of CEUS

The diagnostic results of CEUS are shown in Table 3. Two malignant lesions which were misdiagnosed as probably benign by conventional ultrasound were correctly diagnosed as probably malignant by CEUS, and one malignant lesion which was diagnosed as probably malignant by conventional ultrasound was

confirmed as malignant by CEUS. For benign lesions, all the cases of sludge were confirmed as benign. All cases of adenomyomatosis but 3 (1 diagnosed as probably malignant and 2 as probably benign) and all cases of polyps but 3 (1 diagnosed as probably malignant and 2 as probably benign) were confirmed as benign. Two cases of adenoma were misdiagnosed as probably malignant and another two cases of adenoma were diagnosed as probably benign. The rest 9 of the cases of adenoma were confirmed as benign.

The sensitivity, specificity, positive predictive value, negative predictive value and accuracy of CEUS are shown in Table 2. The diagnostic efficiencies of CEUS were all significantly higher than those of conventional ultrasound, though the differences were not statistically significant.

DISCUSSION

In this study, we compared the value of CEUS in the differential diagnosis of benign and malignant gallbladder lesions with conventional ultrasound. Our results showed that the diagnostic efficiencies of CEUS were much higher than those of conventional ultrasound, though the differences were not statistically significant. With all the advantages and information of conventional ultrasound, CEUS provides more information about the important microvasculature in lesions. Also, with the application of microbubbles, the contour, the boundary and the shape of a lesion, the

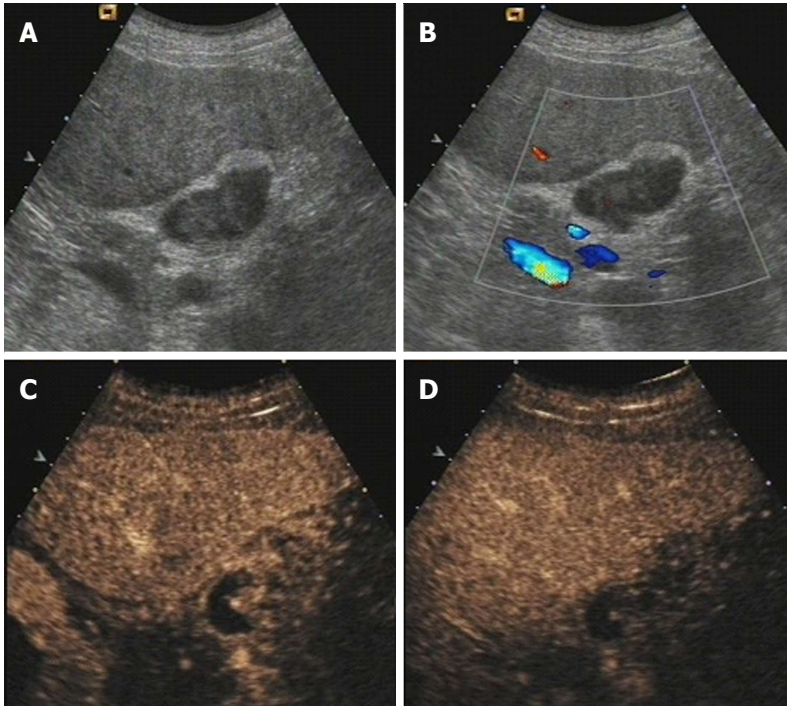


Figure 4 Gallbladder cancer in a 46-year-old male patient. A: B-mode sonography showed a heterogeneously hypoechoic mass in the gallbladder, and the posterior wall of the gallbladder was not very clear; B: Color Doppler ultrasound showed no color Doppler signal in the lesion. According to A and B, a diagnosis of probably malignant was made. C: CEUS showed a heterogeneously hyperenhanced mass with tortuous-type tumor vessel on arterial phase and the boundary of the mass was not clear; D: CEUS showed the enhancement of the lesion is much lower than that of the surrounding gallbladder wall on venous phase. According to C and D, a diagnosis of malignant mass was made. CEUS: Contrast-enhanced ultrasound.

intactness of gallbladder wall and the invasion of the surrounding tissue could be revealed more clearly. So, the diagnostic efficiencies were highly improved, though the differences between the diagnostic efficiencies were not statistically significant.

Although the clinical significance of gallbladder sludge has not been confirmed yet, the accurate diagnosis is still of importance to avoid unnecessary examination and treatment^[13]. Gallbladder sludge is usually shown on ultrasound as movable, echogenic matter, which could be easily diagnosed. However, sometimes gallbladder sludge could be shown as an intraluminal mass and imitates tumors such as gallbladder cancer or adenoma^[14]. Then, the differential diagnosis is very difficult using conventional ultrasound. CEUS is very useful at such a time. As sludge has no blood supply inside it, it shows a complete nonenhancement on both arterial phase and venous phase. The diagnostic accuracy was 100% in our study, and the result was similar with some previous studies^[11,15].

Gallbladder adenomyomatosis is a noninfectious and nontumorous disease of gallbladder which is usually found accidentally, with no malignant potential and which needs no specific treatment^[16]. It has some typical characteristics on CEUS, too. With the small nonenhanced areas on arterial phase and venous phase (represented as Rokitsky-Aschoff sinuses), together with echogenic foci and tail sign or not, the correct diagnosis would be easily made^[17,18]. The study by Tang

et al.^[17] showed that small anechoic spaces or intramural echogenic foci were 100% detected using CEUS, which made the diagnostic accuracy much higher than conventional ultrasound. In this study, besides one case with no small anechoic spaces that was misdiagnosed as probably malignant, the rest of the cases were all diagnosed correctly as gallbladder adenomyomatosis.

The differential diagnosis among gallbladder polyps, gallbladder adenoma and gallbladder cancer was not easy on CEUS. However, some studies showed that some CEUS features were useful and significant for differentiating malignancy from benignity. The study of Xu *et al.*^[19] showed that focal gallbladder wall thickening, inner layer discontinuity and outer layer discontinuity were associated with gallbladder malignancy. Branched or linear intralesional vessels, tortuous-type tumor vessel, enhanced heterogeneously in the artery phase and washed out quickly in the late phase were usually considered as signs for malignancy^[20-22]. On the contrary, gallbladder polyps or gallbladder adenoma was usually enhanced homogeneously and the microbubbles inside the lesions washed out together with normal gallbladder wall. Recently, the study of the differential diagnosis of localized gallbladder lesions using contrast-enhanced harmonic endoscopic ultrasonography also confirmed the value of CEUS for the evaluation and differentiation of localized gallbladder lesions^[23]. Although CEUS provides the microvascular information, conventional ultrasound is still very important and is the foundation of CEUS. The size, shape and boundary

of a lesion, the intactness of gallbladder wall and the invasion of surrounding tissue are very important for the differential diagnosis. Besides providing microvascular information, CEUS makes the contour of a lesion much clearer and the evaluation of a lesion's shape, size and boundary much more accurate. That is an important reason for the improvement of CEUS diagnostic efficiency, compared with conventional ultrasound.

Our study has some limitations. First, the sample was not large enough, especially for the malignant lesions. The pathological types of the lesions were not enough in number, either. For example, all the gallbladder adenomyomatosis in our study were of localized type, and no segmental or diffuse types were included. And, there were only a few early-stage cancers in this study, making it hard to compare the difference between benign lesions and early-stage cancers on CEUS. Second, the CEUS features were not analyzed using quantitative analysis software, but by naked eyes. No quantitative parameters were acquired and analyzed. Furthermore, the interobserver agreement in CEUS and conventional ultrasound was not compared in this study.

In conclusion, gallbladder sludge and gallbladder adenomyomatosis had special features on CEUS and the diagnostic accuracy was very high. CEUS helped the differential diagnosis among gallbladder polyps, gallbladder adenoma and gallbladder cancer. The diagnostic efficiency of CEUS was highly improved compared to conventional ultrasound.

ARTICLE HIGHLIGHTS

Research background

With the advent of ultrasound contrast agents, contrast-enhanced ultrasound (CEUS) is playing a more and more important role clinically. CEUS is a safe, convenient and repeatable imaging method, with no risk of serious allergy and radiation. CEUS has an excellent diagnostic efficiency for hepatic focal lesions, which is comparable with contrast-enhanced computed tomography. However, the value of CEUS in gallbladder lesions was not widely accepted yet.

Research motivation

The European Federation of Societies for Ultrasound in Medicine and Biology guidelines 2011 did not recognize the value of CEUS for the differential diagnosis of gallbladder lesions. However, there were still some studies published which showed the usefulness of CEUS in the differential diagnosis between benign and malignant gallbladder diseases. So, the value of CEUS for gallbladder is still unclear.

Research objectives

We aim to describe CEUS features and evaluate differential diagnosis value of CEUS and conventional ultrasound for patients with benign and malignant gallbladder lesions.

Research methods

This study included 105 gallbladder lesions, which were examined using conventional ultrasound and CEUS before surgical resection and pathological examination in our hospital between December 2012 and October 2016. Each lesion was diagnosed as (1) benign, (2) probably benign, (3) probably malignant or (4) malignant using both conventional ultrasound and CEUS by two radiologists with at least ten years' experience in both conventional ultrasound

and CEUS. CEUS features of these gallbladder lesions were analyzed. The sensitivity, specificity, positive predictive value, negative predictive value and accuracy of conventional ultrasound and CEUS was calculated and compared.

Research results

Gallbladder sludge was completely nonenhanced on CEUS. Gallbladder adenomyomatosis had typical characteristics of small nonenhanced areas on CEUS, together with echogenic foci and tail sign sometimes. Gallbladder cancer on CEUS was usually heterogeneously hyperenhanced on arterial phase and washed out quickly. Besides providing microvascular information, CEUS makes the contour of a lesion much clearer and the evaluation of a lesion's shape, size and boundary much more accurate.

The sensitivity, specificity, positive predictive value, negative predictive value and accuracy of CEUS were 94.1%, 95.5%, 80.0%, 98.8% and 95.2%, respectively; these values were significantly higher than conventional ultrasound (82.4%, 89.8%, 60.9%, 96.3% and 88.6%, respectively).

Research conclusions

CEUS helped in the differential diagnosis between among different kinds of gallbladder lesions. The diagnostic efficiency of CEUS was highly improved compared with conventional ultrasound. According to our results, for a gallbladder lesion, when a definite diagnosis could not be made using conventional ultrasound, CEUS examination could be used as a further diagnostic method.

Research perspectives

In this study, we demonstrated the value of CEUS for gallbladder lesions. Prospective study with large numbers of patients and different kinds of gallbladder lesions will be needed to confirm the results. The application of endoscopic CEUS may provide more useful information for differentiating between benign and malignant gallbladder lesions.

REFERENCES

- 1 **Gore RM**, Yaghamai V, Newmark GM, Berlin JW, Miller FH. Imaging benign and malignant disease of the gallbladder. *Radiol Clin North Am* 2002; **40**: 1307-1323, vi [PMID: 12479713 DOI: 10.1016/S0033-8389(02)00042-8]
- 2 **Lee TY**, Ko SF, Huang CC, Ng SH, Liang JL, Huang HY, Chen MC, Sheen-Chen SM. Intraluminal versus infiltrating gallbladder carcinoma: clinical presentation, ultrasound and computed tomography. *World J Gastroenterol* 2009; **15**: 5662-5668 [PMID: 19960562 DOI: 10.3748/wjg.15.5662]
- 3 **Badea R**, Zaro R, Opincariu I, Chiorean L. Ultrasound in the examination of the gallbladder - a holistic approach: grey scale, Doppler, CEUS, elastography, and 3D. *Med Ultrason* 2014; **16**: 345-355 [PMID: 25463889 DOI: 10.11152/mu.2013.2066.164.rbrz]
- 4 **Charalel RA**, Jeffrey RB, Shin LK. Complicated cholecystitis: the complementary roles of sonography and computed tomography. *Ultrasound Q* 2011; **27**: 161-170 [PMID: 21873853 DOI: 10.1097/RUQ.0b013e31822a33e8]
- 5 **Sun LP**, Guo LH, Xu HX, Liu LN, Xu JM, Zhang YF, Liu C, Bo XW, Xu XH. Value of contrast-enhanced ultrasound in the differential diagnosis between gallbladder adenoma and gallbladder adenoma canceration. *Int J Clin Exp Med* 2015; **8**: 1115-1121 [PMID: 25785101]
- 6 **Wang W**, Liu JY, Yang Z, Wang YF, Shen SL, Yi FL, Huang Y, Xu EJ, Xie XY, Lu MD, Wang Z, Chen LD. Hepatocellular adenoma: comparison between real-time contrast-enhanced ultrasound and dynamic computed tomography. *Springerplus* 2016; **5**: 951 [PMID: 27386395 DOI: 10.1186/s40064-016-2406-z]
- 7 **Zhang H**, He Y, Du L, Wu Y. Shorter hepatic transit time can suggest coming metastases: through-monitoring by contrast-enhanced ultrasonography? *J Ultrasound Med* 2010; **29**: 719-726 [PMID: 20427783 DOI: 10.7863/jum.2010.29.5.719]
- 8 **Sato K**, Tanaka S, Mitsunori Y, Mogushi K, Yasen M, Aihara A, Ban D, Ochiai T, Irie T, Kudo A, Nakamura N, Tanaka H, Arai S.

- Contrast-enhanced intraoperative ultrasonography for vascular imaging of hepatocellular carcinoma: clinical and biological significance. *Hepatology* 2013; **57**: 1436-1447 [PMID: 23150500 DOI: 10.1002/hep.26122]
- 9 **Rübenhaller J**, Paprottka K, Marcon J, Hameister E, Hoffmann K, Joiko N, Reiser M, Clevert DA. Comparison of magnetic resonance imaging (MRI) and contrast-enhanced ultrasound (CEUS) in the evaluation of unclear solid renal lesions. *Clin Hemorheol Microcirc* 2016; **64**: 757-763 [PMID: 27767985 DOI: 10.3233/CH-168034]
 - 10 **Sridharan A**, Eisenbrey JR, Dave JK, Forsberg F. Quantitative Nonlinear Contrast-Enhanced Ultrasound of the Breast. *AJR Am J Roentgenol* 2016; **207**: 274-281 [PMID: 27223688 DOI: 10.2214/AJR.16.16315]
 - 11 **Piscaglia F**, Nolsøe C, Dietrich CF, Cosgrove DO, Gilja OH, Bachmann Nielsen M, Albrecht T, Barozzi L, Bertolotto M, Catalano O, Claudon M, Clevert DA, Correia JM, D'Onofrio M, Drudi FM, Eyding J, Giovannini M, Hocke M, Ignee A, Jung EM, Klauser AS, Lassau N, Leen E, Mathis G, Saftoiu A, Seidel G, Sidhu PS, ter Haar G, Timmerman D, Weskott HP. The EFSUMB Guidelines and Recommendations on the Clinical Practice of Contrast Enhanced Ultrasound (CEUS): update 2011 on non-hepatic applications. *Ultraschall Med* 2012; **33**: 33-59 [PMID: 21874631 DOI: 10.1055/s-0031-1281676]
 - 12 **Xu HX**. Contrast-enhanced ultrasound in the biliary system: Potential uses and indications. *World J Radiol* 2009; **1**: 37-44 [PMID: 21160719 DOI: 10.4329/wjr.v1.i1.37]
 - 13 **Lee YS**, Kang BK, Hwang IK, Kim J, Hwang JH. Long-term Outcomes of Symptomatic Gallbladder Sludge. *J Clin Gastroenterol* 2015; **49**: 594-598 [PMID: 25127114 DOI: 10.1097/MCG.0000000000000202]
 - 14 **Zerem E**, Lincender-Cvijetić L, Kurtćehajić A, Samardžić J, Zerem O. Symptomatic Gallbladder Sludge and its Relationship to Subsequent Biliary Events. *J Clin Gastroenterol* 2015; **49**: 795-796 [PMID: 26053167 DOI: 10.1097/MCG.0000000000000361]
 - 15 **Gerstenmaier JF**, Hoang KN, Gibson RN. Contrast-enhanced ultrasound in gallbladder disease: a pictorial review. *Abdom Radiol (NY)* 2016; **41**: 1640-1652 [PMID: 27056746 DOI: 10.1007/s00261-016-0729-4]
 - 16 **Pellino G**, Sciaudone G, Candilio G, Perna G, Santoriello A, Canonico S, Selvaggi F. Stepwise approach and surgery for gallbladder adenomyomatosis: a mini-review. *Hepatobiliary Pancreat Dis Int* 2013; **12**: 136-142 [PMID: 23558066 DOI: 10.1016/S1499-3872(13)60022-3]
 - 17 **Tang S**, Huang L, Wang Y, Wang Y. Contrast-enhanced ultrasonography diagnosis of fundal localized type of gallbladder adenomyomatosis. *BMC Gastroenterol* 2015; **15**: 99 [PMID: 26239485 DOI: 10.1186/s12876-015-0326-y]
 - 18 **Meacock LM**, Sellars ME, Sidhu PS. Evaluation of gallbladder and biliary duct disease using microbubble contrast-enhanced ultrasound. *Br J Radiol* 2010; **83**: 615-627 [PMID: 20603412 DOI: 10.1259/bjr/60619911]
 - 19 **Xu JM**, Guo LH, Xu HX, Zheng SG, Liu LN, Sun LP, Lu MD, Wang WP, Hu B, Yan K, Hong D, Tang SS, Qian LX, Luo BM. Differential diagnosis of gallbladder wall thickening: the usefulness of contrast-enhanced ultrasound. *Ultrasound Med Biol* 2014; **40**: 2794-2804 [PMID: 25438861 DOI: 10.1016/j.ultrasmedbio.2014.06.015]
 - 20 **Liu LN**, Xu HX, Lu MD, Xie XY, Wang WP, Hu B, Yan K, Ding H, Tang SS, Qian LX, Luo BM, Wen YL. Contrast-enhanced ultrasound in the diagnosis of gallbladder diseases: a multi-center experience. *PLoS One* 2012; **7**: e48371 [PMID: 23118996 DOI: 10.1371/journal.pone.0048371]
 - 21 **Zhuang B**, Li W, Wang W, Lin M, Xu M, Xie X, Lu M, Xie X. Contrast-enhanced ultrasonography improves the diagnostic specificity for gallbladder-confined focal tumors. *Abdom Radiol (NY)* 2017; [PMID: 28765975 DOI: 10.1007/s00261-017-1268-3]
 - 22 **Numata K**, Oka H, Morimoto M, Sugimori K, Kunisaki R, Nihonmatsu H, Matsuo K, Nagano Y, Nozawa A, Tanaka K. Differential diagnosis of gallbladder diseases with contrast-enhanced harmonic gray scale ultrasonography. *J Ultrasound Med* 2007; **26**: 763-774 [PMID: 17526608 DOI: 10.7863/jum.2007.26.6.763]
 - 23 **Kamata K**, Takenaka M, Kitano M, Omoto S, Miyata T, Minaga K, Yamao K, Imai H, Sakurai T, Nishida N, Kashida H, Chikugo T, Chiba Y, Nakai T, Takeyama Y, Lisotti A, Fusaroli P, Kudo M. Contrast-enhanced harmonic endoscopic ultrasonography for differential diagnosis of localized gallbladder lesions. *Dig Endosc* 2018; **30**: 98-106 [PMID: 28632914 DOI: 10.1111/den.12900.]

P- Reviewer: Parakkal D, Shentova R **S- Editor:** Gong ZM
L- Editor: Filipodia **E- Editor:** Ma YJ





Published by **Baishideng Publishing Group Inc**
7901 Stoneridge Drive, Suite 501, Pleasanton, CA 94588, USA
Telephone: +1-925-223-8242
Fax: +1-925-223-8243
E-mail: bpgoffice@wjgnet.com
Help Desk: <http://www.f6publishing.com/helpdesk>
<http://www.wjgnet.com>



ISSN 1007-9327



9 771007 932045