

World Journal of *Gastroenterology*

World J Gastroenterol 2018 March 21; 24(11): 1181-1284



**REVIEW**

- 1181 Functional macrophages and gastrointestinal disorders

Liu YH, Ding Y, Gao CC, Li LS, Wang YX, Xu JD

ORIGINAL ARTICLE**Basic Study**

- 1196 *NOD2*- and disease-specific gene expression profiles of peripheral blood mononuclear cells from Crohn's disease patients

Schäffler H, Rohde M, Rohde S, Huth A, Gittel N, Hollborn H, Koczan D, Glass A, Lamprecht G, Jaster R

- 1206 Three-microRNA signature identified by bioinformatics analysis predicts prognosis of gastric cancer patients

Zhang C, Zhang CD, Ma MH, Dai DQ

Retrospective Cohort Study

- 1216 Differing profiles of people diagnosed with acute and chronic hepatitis B virus infection in British Columbia, Canada

Binka M, Butt ZA, Wong S, Chong M, Buxton JA, Chapinal N, Yu A, Alvarez M, Darvishian M, Wong J, McGowan G, Torban M, Gilbert M, Tyndall M, Krajden M, Janjua NZ

- 1228 Role of relevant immune-modulators and cytokines in hepatocellular carcinoma and premalignant hepatic lesions

Zekri AN, El Deeb S, Bahnassy AA, Badr AM, Abdellateif MS, Esmat G, Salama H, Mohanad M, El-dien AE, Rabah S, Abd Elkader A

Retrospective Study

- 1239 Serum autotaxin levels are correlated with hepatic fibrosis and ballooning in patients with non-alcoholic fatty liver disease

Fujimori N, Umemura T, Kimura T, Tanaka N, Sugiura A, Yamazaki T, Joshita S, Komatsu M, Usami Y, Sano K, Igarashi K, Matsumoto A, Tanaka E

- 1250 Epidemiological features of chronic hepatitis C infection caused by remunerated blood donors: A nearly 27-year period survey

Tan YW, Tao Y, Liu LG, Ye Y, Zhou XB, Chen L, He C

Clinical Trials Study

- 1259 Low-FODMAP vs regular rye bread in irritable bowel syndrome: Randomized SmartPill® study

Pirkola L, Laatikainen R, Lopenon J, Hongisto SM, Hillilä M, Nuora A, Yang B, Linderborg KM, Freese R

Prospective Study

- 1269** Fatty liver in hepatitis C patients post-sustained virological response with direct-acting antivirals

Noureddin M, Wong MM, Todo T, Lu SC, Sanyal AJ, Mena EA

- 1278** Low-pressure pneumoperitoneum with abdominal wall lift in laparoscopic total mesorectal excision for rectal cancer: Initial experience

Xia PT, Yusofu M, Han HF, Hu CX, Hu SY, Yu WB, Liu SZ

ABOUT COVER

Editorial board member of *World Journal of Gastroenterology*, Chang Moo Kang, MD, PhD, Associate Professor, Division of Hepatobiliary and Pancreatic Surgery, Department of Surgery, Yonsei University, Pancreaticobiliary Cancer Clinic, Yonsei Cancer Center, Severance Hospital, Seoul 120-752, South Korea

AIMS AND SCOPE

World Journal of Gastroenterology (*World J Gastroenterol*, *WJG*, print ISSN 1007-9327, online ISSN 2219-2840, DOI: 10.3748) is a peer-reviewed open access journal. *WJG* was established on October 1, 1995. It is published weekly on the 7th, 14th, 21st, and 28th each month. The *WJG* Editorial Board consists of 642 experts in gastroenterology and hepatology from 59 countries.

The primary task of *WJG* is to rapidly publish high-quality original articles, reviews, and commentaries in the fields of gastroenterology, hepatology, gastrointestinal endoscopy, gastrointestinal surgery, hepatobiliary surgery, gastrointestinal oncology, gastrointestinal radiation oncology, gastrointestinal imaging, gastrointestinal interventional therapy, gastrointestinal infectious diseases, gastrointestinal pharmacology, gastrointestinal pathophysiology, gastrointestinal pathology, evidence-based medicine in gastroenterology, pancreatology, gastrointestinal laboratory medicine, gastrointestinal molecular biology, gastrointestinal immunology, gastrointestinal microbiology, gastrointestinal genetics, gastrointestinal translational medicine, gastrointestinal diagnostics, and gastrointestinal therapeutics. *WJG* is dedicated to become an influential and prestigious journal in gastroenterology and hepatology, to promote the development of above disciplines, and to improve the diagnostic and therapeutic skill and expertise of clinicians.

INDEXING/ABSTRACTING

World Journal of Gastroenterology (*WJG*) is now indexed in Current Contents[®]/Clinical Medicine, Science Citation Index Expanded (also known as SciSearch[®]), Journal Citation Reports[®], Index Medicus, MEDLINE, PubMed, PubMed Central and Directory of Open Access Journals. The 2017 edition of Journal Citation Reports[®] cites the 2016 impact factor for *WJG* as 3.365 (5-year impact factor: 3.176), ranking *WJG* as 29th among 79 journals in gastroenterology and hepatology (quartile in category Q2).

EDITORS FOR THIS ISSUE

Responsible Assistant Editor: *Xiang Li*
Responsible Electronic Editor: *Yan Huang*
Proofing Editor-in-Chief: *Lian-Sheng Ma*

Responsible Science Editor: *Ze-Mao Gong*
Proofing Editorial Office Director: *Jin-Lei Wang*

NAME OF JOURNAL
World Journal of Gastroenterology

ISSN
ISSN 1007-9327 (print)
ISSN 2219-2840 (online)

LAUNCH DATE
October 1, 1995

FREQUENCY
Weekly

EDITORS-IN-CHIEF
Damian Garcia-Olmo, MD, PhD, Doctor, Professor, Surgeon, Department of Surgery, Universidad Autonoma de Madrid; Department of General Surgery, Fundacion Jimenez Diaz University Hospital, Madrid 28040, Spain

Stephen C Strom, PhD, Professor, Department of Laboratory Medicine, Division of Pathology, Karolinska Institutet, Stockholm 141-86, Sweden

Andrzej S Tarnawski, MD, PhD, DSc (Med), Professor of Medicine, Chief Gastroenterology, VA Long Beach Health Care System, University of California, Irvine, CA, 5901 E. Seventh Str., Long Beach,

CA 90822, United States

EDITORIAL BOARD MEMBERS
All editorial board members resources online at <http://www.wjgnet.com/1007-9327/editorialboard.htm>

EDITORIAL OFFICE
Ze-Mao Gong, Director
World Journal of Gastroenterology
Baishideng Publishing Group Inc
7901 Stoneridge Drive, Suite 501,
Pleasanton, CA 94588, USA
Telephone: +1-925-2238242
Fax: +1-925-2238243
E-mail: editorialoffice@wjgnet.com
Help Desk: <http://www.f6publishing.com/helpdesk>
<http://www.wjgnet.com>

PUBLISHER
Baishideng Publishing Group Inc
7901 Stoneridge Drive, Suite 501,
Pleasanton, CA 94588, USA
Telephone: +1-925-2238242
Fax: +1-925-2238243
E-mail: bpgoffice@wjgnet.com
Help Desk: <http://www.f6publishing.com/helpdesk>
<http://www.wjgnet.com>

PUBLICATION DATE
March 21, 2018

COPYRIGHT
© 2018 Baishideng Publishing Group Inc. Articles published by this Open-Access journal are distributed under the terms of the Creative Commons Attribution Non-commercial License, which permits use, distribution, and reproduction in any medium, provided the original work is properly cited, the use is non commercial and is otherwise in compliance with the license.

SPECIAL STATEMENT
All articles published in journals owned by the Baishideng Publishing Group (BPG) represent the views and opinions of their authors, and not the views, opinions or policies of the BPG, except where otherwise explicitly indicated.

INSTRUCTIONS TO AUTHORS
Full instructions are available online at <http://www.wjgnet.com/bpg/gerinfo/204>

ONLINE SUBMISSION
<http://www.f6publishing.com>

Prospective Study

Low-pressure pneumoperitoneum with abdominal wall lift in laparoscopic total mesorectal excision for rectal cancer: Initial experience

Ping-Tian Xia, Maimaiti Yusofu, Hai-Feng Han, Chun-Xiao Hu, San-Yuan Hu, Wen-Bin Yu, Shao-Zhuang Liu

Ping-Tian Xia, Maimaiti Yusofu, Hai-Feng Han, Chun-Xiao Hu, San-Yuan Hu, Wen-Bin Yu, Shao-Zhuang Liu, Department of General Surgery, Qilu Hospital of Shandong University, Jinan 250012, Shandong Province, China

ORCID number: Ping-Tian Xia (0000-0001-8032-8871); Maimaiti Yusofu (0000-0001-8762-5924); Hai-Feng Han (0000-0002-1417-9350); Chun-Xiao Hu (0000-0002-8015-4549); San-Yuan Hu (0000-0002-0546-9778); Wen-Bin Yu (0000-0002-9410-7188); Shao-Zhuang Liu (0000-0003-2052-0516).

Author contributions: Xia PT, Hu SY, Yu WB and Liu SZ designed the study, analyzed the data and wrote the paper; Yusofu M, Yu WB and Liu SZ performed the surgery and treated the patients; Han HF and Hu CX collected and analyzed the patient data; Hu SY and Liu SZ approved the final manuscript.

Supported by the Special Found for Taishan Scholar Project of Shandong Province, China.

Institutional review board statement: The study was reviewed and approved by the Ethics Committee of Scientific Research of Shandong University Qilu Hospital.

Informed consent statement: In this study, all involved participants or their legal guardian provided informed written consent before surgery.

Conflict-of-interest statement: No authors of this paper have conflicting interests.

Data sharing statement: No additional data are available.

CONSORT 2010 statement: The guidelines of the CONSORT 2010 Statement have been adopted.

Open-Access: This article is an open-access article which was selected by an in-house editor and fully peer-reviewed by external reviewers. It is distributed in accordance with the Creative Commons Attribution Non Commercial (CC BY-NC 4.0) license, which permits others to distribute, remix, adapt, build upon this

work non-commercially, and license their derivative works on different terms, provided the original work is properly cited and the use is non-commercial. See: <http://creativecommons.org/licenses/by-nc/4.0/>

Manuscript source: Unsolicited manuscript

Correspondence to: Shao-Zhuang Liu, MD, PhD, Attending Doctor, Postdoc, Department of General Surgery, Qilu Hospital of Shandong University, 107#, Wenhua Xi Road, Jinan 250012, Shandong Province, China. liushaozhuang@sdu.edu.cn
Telephone: +86-531-86920598
Fax: +86-531-86920598

Received: January 11, 2018
Peer-review started: January 11, 2018
First decision: January 25, 2018
Revised: January 30, 2018
Accepted: February 9, 2018
Article in press: February 9, 2018
Published online: March 21, 2018

Abstract

AIM

To evaluate the safety and feasibility of a new technology combining low-pressure pneumoperitoneum (LPP) and abdominal wall lift (AWL) in laparoscopic total mesorectal excision (TME) for rectal cancer.

METHODS

From November 2015 to July 2017, 26 patients underwent laparoscopic TME for rectal cancer using LPP (6-8 mmHg) with subcutaneous AWL in Qilu Hospital of Shandong University, Jinan, China. Clinical data regarding patients' demographics, intraoperative monitoring indices, operation-related indices and

pathological outcomes were prospectively collected.

RESULTS

Laparoscopic TME was performed in 26 cases (14 anterior resection and 12 abdominoperineal resection) successfully, without conversion to open or laparoscopic surgery with standard-pressure pneumoperitoneum. Intraoperative monitoring showed stable heart rate, blood pressure and paw airway pressure. The mean operative time was 194.29 ± 41.27 min (range: 125-270 min) and 200.41 ± 20.56 min (range: 170-230 min) for anterior resection and abdominoperineal resection, respectively. The mean number of lymph nodes harvested was 16.71 ± 5.06 (range: 7-27). There was no positive circumferential or distal resection margin. No local recurrence was observed during a median follow-up period of 11.96 ± 5.55 mo (range: 5-23 mo).

CONCLUSION

LPP combined with AWL is safe and feasible for laparoscopic TME. The technique can provide satisfactory exposure of the operative field and stable operative monitoring indices.

Key words: Laparoscopic surgery; Abdominal wall lift; Low-pressure pneumoperitoneum; Rectal cancer; Total mesorectal excision

© The Author(s) 2018. Published by Baishideng Publishing Group Inc. All rights reserved.

Core tip: Low-pressure pneumoperitoneum (LPP) and abdominal wall lift (AWL) have been proposed as alternative approaches to standard-pressure pneumoperitoneum to avoid adverse cardiorespiratory effects. However, the operative field under these approaches is less optimal and accompanied by increased technical difficulties. We developed a new technique combining LPP and AWL, which improved exposure of the operative field that was compromised with LPP or AWL alone. We evaluated the safety and feasibility of this new technique in 26 cases of laparoscopic total mesorectal excision for rectal cancer. This technique can provide satisfactory exposure of the operative field and stable operative monitoring indices.

Xia PT, Yusofu M, Han HF, Hu CX, Hu SY, Yu WB, Liu SZ. Low-pressure pneumoperitoneum with abdominal wall lift in laparoscopic total mesorectal excision for rectal cancer: Initial experience. *World J Gastroenterol* 2018; 24(11): 1278-1284 Available from: URL: <http://www.wjgnet.com/1007-9327/full/v24/i11/1278.htm> DOI: <http://dx.doi.org/10.3748/wjg.v24.i11.1278>

INTRODUCTION

Pneumoperitoneum with carbon dioxide (CO₂) is

the conventional method of creating a workspace in laparoscopic surgery. The application of pneumoperitoneum results in a variety of physiologic alterations, due to the systemic absorption of CO₂ and increased intra-abdominal pressure. CO₂ absorption across the peritoneum into the circulation can lead to hypercarbia and changes in blood gas parameters. Appropriate ventilator adjustment is usually required to eliminate the increased CO₂ load. Increased intraabdominal pressure by standard-pressure pneumoperitoneum (SPP; 12-15 mmHg) has been reported to result in lower respiratory compliance, increased paw airway pressure, enhanced venous stasis, reduced portal venous pressure and impaired cardiac function^[1-5]. These alterations may be detrimental in high-risk patients with poor cardiopulmonary reserve, such as older and morbidly obese patients with American Society of Anesthesiologists (ASA) status III and IV^[6].

Low-pressure pneumoperitoneum (LPP), defined as 5-7 mmHg^[7], has been proposed to reduce the adverse consequences of SPP, and is recommended in older and compromised patients. It was reported that LPP reduced the adverse effects on cardiopulmonary function without affecting laparoscopic feasibility^[5,8]. It has also proved feasible and safe in cholecystectomy^[5,9], Nissen fundoplication^[10], hysterectomy^[11], adrenalectomy^[12] and donor nephrectomy^[13]. Abdominal wall lift (AWL) is another alternative technique to SPP which avoids the destructive changes associated with CO₂ absorption and increased intraabdominal pressure. A variety of AWL systems have been developed and applied in a wide range of surgical procedures^[14]. Compared with SPP, AWL results in more stable cardiopulmonary, hemodynamic and renal functions during laparoscopic procedures^[15-17].

A frequent disadvantage during laparoscopic surgery with LPP or AWL is that the operative field is less optimal, which increases technical difficulties. In order to obtain adequate visualization, we combined LPP with AWL and initially used this technique in a case of laparoscopic single-site cholecystectomy^[18]. In the present prospective pilot study, we aimed to evaluate the safety and feasibility of LPP with AWL in laparoscopic total mesorectal excision (TME) for rectal cancer.

MATERIALS AND METHODS

Clinical data

This was a prospective study, and the protocol was approved by the Ethics Committee of Scientific Research of Shandong University Qilu Hospital, Jinan, China. From November 2015 to May 2017, 26 patients underwent laparoscopic TME using LPP with AWL in Qilu Hospital of Shandong University, Jinan, China. Written informed consent was obtained from all patients. Rectal adenocarcinoma was diagnosed by colonoscopy and biopsy. Computed tomography scans of the abdomen and pelvis were used to determine tumor stage. Patients

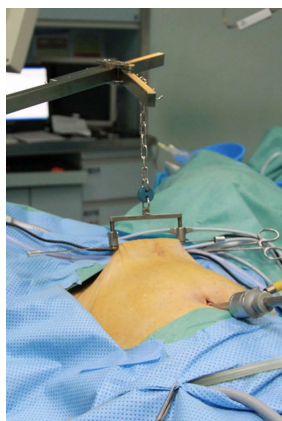

Figure 1 The subcutaneous abdominal wall lift system. The steel scaffold was fixed to the operating table. A sterilized needle was inserted through the subcutaneous tissue and drafted by a retractor to lift the abdominal wall.

without distant metastasis were eligible for enrollment in the study. All operations were performed by the same surgical group with considerable experience in advanced laparoscopic gastroenterological surgery.

Clinical data regarding patients' demographics [age, sex, body mass index (BMI)], ASA status, intraoperative monitoring indices (heart rate, blood pressure and paw airway pressure), operative time, blood loss, complications and pathological outcomes (tumor size, differentiation, depth of invasion, lymph nodes harvested, Dukes stage, completeness of TME, circumferential and distal margins) were obtained.

Instruments

The subcutaneous AWL system (Mizuho Medical Inc., Tokyo, Japan) was used in this study. It consisted of a sterilized steel scaffold with a lifting arm, retractors and steel needles. Other instruments included a harmonic scalpel (Ultracision; Ethicon Endosurgery, Cincinnati, OH, United States) and conventional laparoscopic instruments, such as a coagulation hook, dissector and grasper (Yida Medical Device Co., Ltd., Hangzhou, China). Hem-O-Lock clips (Weck Closure Systems, Triangle Park, NC, United States) were used to ligate vessels.

Surgical technique

The patients were placed in the lithotomy position under general anesthesia with a laryngeal mask airway. A 10-mm supraumbilical arc incision was made, and then a Veress needle was inserted to create the CO₂ pneumoperitoneum. The pressure was maintained at 6 mmHg with an insufflation rate of 10 L/min. The steel scaffold was fixed to the operating table. A sterilized needle was inserted through the subcutaneous tissue at 5 cm above the pubic level, then drafted by a retractor and the abdominal wall was slightly elevated to obtain additional exposure of the operative area (Figure 1).

The procedures were performed using 5 trocars. A careful exploration was performed to detect possible

liver, peritoneal or pelvis metastases. The patient was then adjusted to the head-down position, which was about 20°-30° inclined to help move the small intestine for better exposure of the inferior mesenteric artery (IMA). The dissection began from the sigmoid mesocolon at the level of the sacral promontory, up to the origin of the IMA. The ascending left colic artery was preserved after a thorough clearance of the lymphatic and adipose tissues at the base of the IMA. The IMA was then ligated, and the inferior mesenteric vein was dissected and ligated at the level of the ligament of Treitz. The splenic flexure was mobilized routinely to achieve a tension-free anastomosis.

Exposure seemed inadequate during the above procedures, and an effort was made to achieve the optimal operative field. We developed and tested three methods. The first was to add a second needle in the supraumbilical area. This was abandoned due to frequent collisions of the instruments with the scaffold and lifting arms. We then tried the method reported by Park *et al.*^[19], where anchoring sutures were placed around the camera port and lifted up by an assistant to retract the abdominal wall for additional exposure. This method was successful and the workspace was improved. However, the view obtained from manual work was not stable. Therefore, we increased the pressure of the pneumoperitoneum to 8 mmHg. This method provided an adequate operative field for dissection of the IMA and inferior mesenteric vein and mobilization of the splenic flexure. These procedures were completed within approximately 20-30 min, and the pressure was then reduced to 6 mmHg.

TME was then started posteriorly after identification of the Holy Plane. Dissection was performed laterally and anteriorly down to the pelvic floor, until circumferential rectal mobilization was complete. The hypogastric nerves, inferior hypogastric plexuses, presacral nerves and ureters were carefully identified and preserved. For patients undergoing anterior resection, an endoscopic linear stapler was used to divide the rectum. The specimen was extracted through a protected incision at the left lower trocar site. After division of the proximal colon and introduction of the anvil of a circular stapler were complete, an intracorporeal end-to-end colorectal anastomosis was performed. A rectal decompression tube was placed and no diverting ileostomy was constructed. An abdominoperineal resection was performed if the tumor was located less than 5 cm from the anal verge, and perforation of the specimen was avoided with careful operation.

RESULTS

All 26 laparoscopic TME procedures, including 14 cases of anterior resection and 12 cases of abdominoperineal resection, were successfully completed without intraoperative complications. The patients' demographics, perioperative data and pathologic

Table 1 Patients' demographics and clinical characteristics

Variable	n/mean \pm SD (range)
Age in yr	62.71 \pm 8.71 (41- 82)
Sex	
Male	17
Female	9
BMI in kg/m ²	24.39 \pm 2.68 (21.11-30.12)
ASA grade	
I	1
II	22
III	3
IV	0
Procedure	
AR	14
APR	12
Operative time in min	
AR	194.29 \pm 41.27 (125-270)
APR	200.41 \pm 20.56 (170-230)
Estimated blood loss in mL	
AR	35.71 \pm 16.35 (20-80)
APR	85.00 \pm 26.61 (50-140)
Postoperative complications	
Shoulder pain	1
Pulmonary infection	1
Calf muscular venous thrombosis	2
Dysuria	4
Tumor size in cm	
Length	4.29 \pm 1.19 (2-6.5)
Thickness	1.12 \pm 0.45 (0.5-2)
Distal resection margin in cm	
AR	3.14 \pm 1.34 (2-5)
APR	-
Differentiation	
Poorly	2
Moderate	19
Highly	5
Depth of invasion	
T1	1
T2	7
T3	1
T4	17
Lymph nodes harvested	16.71 \pm 5.06 (7-27)
Dukes stage	
A	6
B	5
C	15
Follow-up in mo	11.96 \pm 5.55 (5-23)

Data are number of cases (*n*) or mean \pm SD. AR: Anterior resection; APR: Abdominoperineal resection; BMI: Body mass index; SD: Standard deviation.

outcomes are summarized in Table 1. LPP combined with AWL provided adequate exposure of the operating area. There were no conversions to open or laparoscopic surgery with SPP. Intraoperative monitoring resulted in stable curves of heart rate and blood pressure during surgery (Figure 2A). Peak and mean paw airway pressure increased when the pneumoperitoneum was created at the beginning of surgery, was stable throughout the laparoscopic stage, and then decreased after CO₂ was discharged at approximately 150-180 min (Figure 2B).

One patient had shoulder pain and pulmonary infection postoperatively. Dysuria occurred in 4 male

patients after urethral catheters were removed. All 4 patients were diagnosed with benign prostatic hyperplasia preoperatively and the catheters were re-indwelt. All patients resumed free liquid diet 24 h after surgery. The rectal decompression tube was removed 3 d after surgery. There were no cases of adverse cardiovascular events, bleeding or anastomotic leakage observed after surgery.

The rectal specimens were thoroughly examined by the same group of colorectal pathologists. No positive circumferential or distal resection margins were found. No local recurrences were observed during a mean follow-up period of 11.96 mo (range: 5-23 mo).

DISCUSSION

LPP combined with AWL has been proposed as an alternative approach to SPP by the European Association for Endoscopic Surgery^[7]. We initially used this method in a case of laparoscopic transumbilical single-site cholecystectomy which was converted from a gasless laparoscopic single-site procedure with AWL^[18]. Due to the high BMI of the patient, a 6 mmHg pneumoperitoneum was created for better exposure of the operative field. In the present study, this technique was applied in laparoscopic TME for the first time.

Our preliminary experience indicated that LPP with AWL was safe and provided a satisfactory workspace for TME. The number of lymph nodes retrieved, the completeness of TME, the circumferential and mean distance to the distal margin were comparable with those reported in studies using SPP^[20-23]. Another LPP (8 mmHg) and AWL technique was designed by Park *et al*^[19] and proved feasible in laparoscopic colorectal surgery. In their study, anchoring sutures were placed around the camera port and lifted up by an assistant to retract the abdominal wall for additional exposure. Unlike this technique, we used the subcutaneous AWL system introduced by Nagai *et al*^[24] and Hashimoto *et al*^[25], in which a needle was inserted to retract the inferior abdominal wall rather than the periumbilical area. This technique provided a stable and superior operative field, although no strict comparison was performed between the two techniques.

The present study indicated that LPP combined with AWL resulted in stable heart rate, blood pressure and paw airway pressure monitored during laparoscopic TME. For rectal surgery which requires exposure of the lower abdomen, a head-down or Trendelenburg position is necessary. Pneumoperitoneum combined with this position contributes to pushing abdominal organs towards the chest for sufficient exposure of the IMA and mesocolon before dissection in TME. However, SPP combined with head-down or Trendelenburg position significantly reduces pulmonary compliance by more than 30% and leads to ventilation perfusion mismatch^[7]. This should be avoided in patients with impaired cardiopulmonary function. Therefore, gasless

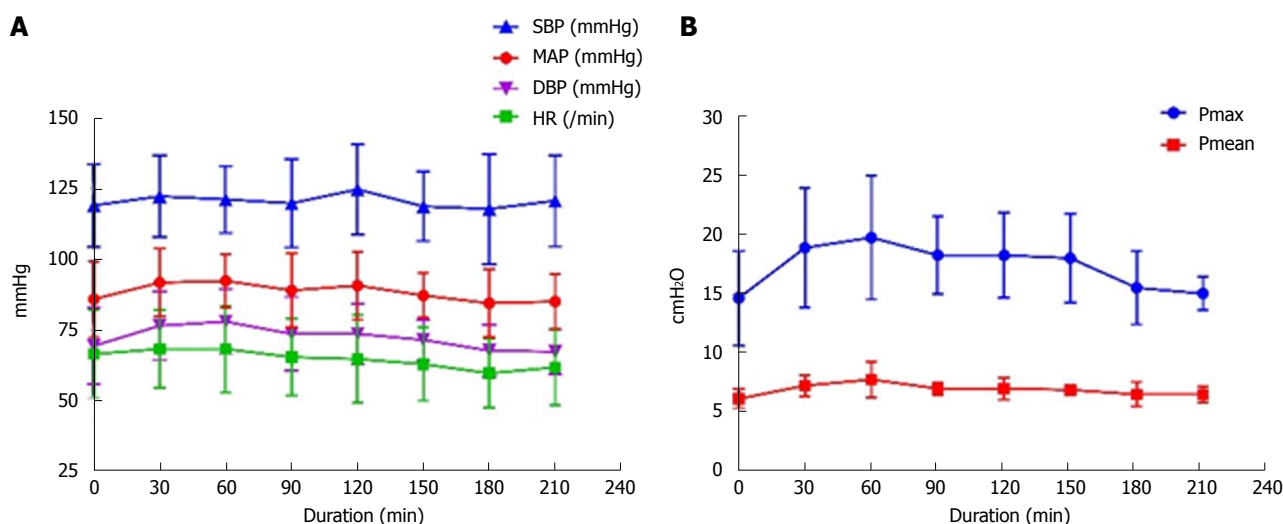


Figure 2 Intraoperative monitoring indexes. A: Heart rate (HR), systolic blood pressure (SBP), diastolic blood pressure (DBP) and mean arterial pressure (MAP); B: Peak and mean paw airway pressure (P_{\max} and P_{mean}).

or LPP techniques should be recommended in these patients.

Gasless laparoscopic colorectal surgery was reported to be feasible in several studies^[26,27]. However, studies of laparoscopic colorectal surgery with LPP are scant, which is possibly due to the restricted operative field. Compared with LPP or AWL alone, the combination of LPP and AWL may be a more appropriate technique with less adverse hemodynamic and respiratory alterations for laparoscopic TME. This was proved by the stable intraoperative monitoring indices, even in patients with ASA III status, although the number of patients was small. In the present study, most of the patients were in ASA I and II status. Further studies are expected to confirm the superiority of this approach in patients with ASA III and IV status.

The most obvious disadvantage of LPP and gasless techniques is limited exposure in the operative field. Based on our experience, the operative field provided by LPP combined with AWL was less optimal than that with SPP, but acceptable for laparoscopic TME in most patients. However, there were some difficulties in exposing and dissecting the IMA with a pneumoperitoneum of 6 mmHg, especially in obese patients. We increased the pressure to 8–10 mmHg and obtained better exposure of the IMA, and then decreased the pressure back to 6 mmHg after dissection.

Two alternative methods were used to improve exposure of the operative field in obese patients. A second needle was inserted 3 cm above the umbilical level. A better operative field was obtained, but surgery was more difficult due to frequent collisions of the laparoscopic instruments with the scaffold and lifting arms. We also used the method reported by Park *et al.*^[19], which was feasible, and exposure was improved when the camera port was lifted up. However, the operative field provided by the assistant was unstable. Therefore, we recommend that the pressure should

be increased to 8–10 mmHg when there is difficulty in exposing and dissecting the IMA. No obvious changes in heart rate, blood pressure and paw airway pressure were observed during the short operating time.

Another major concern of LPP with AWL was the prolonged operative time and the accompanying increase in CO₂ absorption. Installation of the AWL device and inferior exposure of the operative field may result in longer operative time. During surgery, only approximately 5 min was needed to assemble the AWL system. The mean operative time was comparable to surgery with SPP^[21,22]. The operative time may be longer for less skillful surgeons. However, CO₂ absorption will not increase due to slow absorption in the case of low pressure. It is possible that postoperative pain may increase due to the subcutaneous insertion of steel needles. However, our patients did not complain of pain at the insertion site, which may have been masked by pain from ports and the assisted incisions.

The major limitation of this study was that it was an observational study and restricted to a small number of patients. A large, well-controlled comparative study with open or standard-pressure laparoscopic TME would be helpful in providing stronger evidence. Another obvious limitation was that most patients in the present study were in ASA I and II status. Patients with compromised cardiopulmonary reserve should be enrolled in further studies to draw more convincing conclusions.

ARTICLE HIGHLIGHTS

Research background

Pneumoperitoneum with carbon dioxide (CO₂) is the conventional method of creating a workspace in laparoscopic surgery. Standard-pressure pneumoperitoneum (SPP; 12–15 mmHg) has been reported to result in lower respiratory compliance, increased paw airway pressure, enhanced venous stasis, reduced portal venous pressure and impaired cardiac function.

Low-pressure pneumoperitoneum (LPP) and abdominal wall lift (AWL)

have been proposed as alternative approaches to SPP to avoid adverse cardiopulmonary effects. However, the operative field with these techniques is less optimal with increased technical difficulties.

Research motivation

In order to obtain adequate visualization, we combined LPP with AWL and initially used this technique in a case of laparoscopic single-site cholecystectomy, and the surgery was performed successfully. For laparoscopic colorectal surgery which requires sufficient exposure of the lower abdomen, a head-down or Trendelenburg position is necessary. SPP combined with this kind of position significantly influences patients' cardiopulmonary function. Therefore, we decided to find out whether LPP with AWL technique can take the place of SPP in laparoscopic total mesorectal excision (TME) for rectal cancer.

Research objectives

In this study we designed and performed laparoscopic TME for rectal cancer using LPP with AWL, and evaluated the safety and feasibility. The outcomes of this study will guide the application of the new technique in laparoscopic TME and other surgeries in the future.

Research methods

From November 2015 to July 2017, 26 patients underwent laparoscopic TME for rectal cancer using LPP (6–8 mmHg) with subcutaneous AWL in Qilu Hospital of Shandong University, Jinan, China. Clinical data regarding patients' demographics, intraoperative monitoring indices, operation-related indices and pathological outcomes were prospectively collected and analyzed.

Research results

Laparoscopic TME was performed in 26 cases (14 anterior resection and 12 abdominoperineal resection) successfully without conversion to open or laparoscopic surgery with SPP. Intraoperative monitoring showed stable heart rate, blood pressure and paw airway pressure. The number of lymph nodes retrieved, the completeness of TME, and the circumferential and mean distance to the distal margin were comparable with those reported in studies using SPP. There was no positive circumferential or distal resection margin. No local recurrence was observed during a median follow-up period of 11.96 ± 5.55 mo (range: 5–23 mo). Our preliminary experience indicated that LPP with AWL was safe and provided a satisfactory workspace for TME.

Research conclusions

LPP combined with AWL is safe and feasible for laparoscopic TME. The technique can provide satisfactory exposure of the operative field and result in stable operative monitoring indexes. It should be considered as an alternative approach to SPP in patients undergoing laparoscopic TME.

Research perspectives

Further studies are required to confirm the superiority of LPP with AWL over SPP in preservation of cardiopulmonary function, especially in patients with American Society of Anesthesiologists III and IV status. A prospective clinical trial study should be the best method for the future research.

REFERENCES

- 1 Wirth S, Biesemann A, Spaeth J, Schumann S. Pneumoperitoneum deteriorates intratidal respiratory system mechanics: an observational study in lung-healthy patients. *Surg Endosc* 2017; **31**: 753–760 [PMID: 27324326 DOI: 10.1007/s00464-016-5029-0]
- 2 Nguyen NT, Cronan M, Braley S, Rivers R, Wolfe BM. Duplex ultrasound assessment of femoral venous flow during laparoscopic and open gastric bypass. *Surg Endosc* 2003; **17**: 285–290 [PMID: 12364988 DOI: 10.1007/s00464-002-8812-z]
- 3 Jakimowicz J, Stultiens G, Smulders F. Laparoscopic insufflation of the abdomen reduces portal venous flow. *Surg Endosc* 1998; **12**: 129–132 [PMID: 9479726]
- 4 Meininger D, Byhahn C, Bueck M, Binder J, Kramer W, Kessler P, Westphal K. Effects of prolonged pneumoperitoneum on hemodynamics and acid-base balance during totally endoscopic robot-assisted radical prostatectomies. *World J Surg* 2002; **26**: 1423–1427 [PMID: 12297911 DOI: 10.1007/s00268-002-6404-7]
- 5 Dexter SP, Vucevic M, Gibson J, McMahon MJ. Hemodynamic consequences of high- and low-pressure capnoperitoneum during laparoscopic cholecystectomy. *Surg Endosc* 1999; **13**: 376–381 [PMID: 10094751]
- 6 Nguyen NT, Wolfe BM. The physiologic effects of pneumoperitoneum in the morbidly obese. *Ann Surg* 2005; **241**: 219–226 [PMID: 15650630]
- 7 Neudecker J, Sauerland S, Neugebauer E, Bergamaschi R, Bonjer HJ, Cuschieri A, Fuchs KH, Jacobi Ch, Jansen FW, Koivusalo AM, Lacy A, McMahon MJ, Millat B, Schwenk W. The European Association for Endoscopic Surgery clinical practice guideline on the pneumoperitoneum for laparoscopic surgery. *Surg Endosc* 2002; **16**: 1121–1143 [PMID: 12015619 DOI: 10.1007/s00464-001-9166-7]
- 8 Sroussi J, Elies A, Rigouzzo A, Louvet N, Mezzadri M, Fazel A, Benifla JL. Low pressure gynecological laparoscopy (7mmHg) with AirSeal® System versus a standard insufflation (15mmHg): A pilot study in 60 patients. *J Gynecol Obstet Hum Reprod* 2017; **46**: 155–158 [PMID: 28403972 DOI: 10.1016/j.jogoh.2016.09.003]
- 9 Sandhu T, Yamada S, Ariyakachon V, Chakrabandhu T, Chongrutsut W, Ko-iam W. Low-pressure pneumoperitoneum versus standard pneumoperitoneum in laparoscopic cholecystectomy, a prospective randomized clinical trial. *Surg Endosc* 2009; **23**: 1044–1047 [PMID: 18810547 DOI: 10.1007/s00464-008-0119-2]
- 10 Schietroma M, Carlei F, Cecilia EM, Piccione F, Sista F, De Vita F, Amicucci G. A prospective randomized study of systemic inflammation and immune response after laparoscopic nissen fundoplication performed with standard and low-pressure pneumoperitoneum. *Surg Laparosc Endosc Percutan Tech* 2013; **23**: 189–196 [PMID: 23579517 DOI: 10.1097/SLE.0b013e3182827e51]
- 11 Madsen MV, Istre O, Staehr-Rye AK, Springborg HH, Rosenberg J, Lund J, Gätke MR. Postoperative shoulder pain after laparoscopic hysterectomy with deep neuromuscular blockade and low-pressure pneumoperitoneum: A randomised controlled trial. *Eur J Anaesthesiol* 2016; **33**: 341–347 [PMID: 26479510 DOI: 10.1097/EJA.0000000000000360]
- 12 Schietroma M, Pessia B, Stifini D, Lancione L, Carlei F, Cecilia EM, Amicucci G. Effects of low and standard intra-abdominal pressure on systemic inflammation and immune response in laparoscopic adrenalectomy: A prospective randomised study. *J Minim Access Surg* 2016; **12**: 109–117 [PMID: 27073301 DOI: 10.4103/0972-9941.178513]
- 13 Özdemir-van Brunschot DMD, Scheffer GJ, van der Jagt M, Langenhuijsen H, Dahan A, Mulder JEEA, Willems S, Hilbrands LB, Donders R, van Laarhoven CJHM, d'Ancona FA, Warlé MC. Quality of Recovery After Low-Pressure Laparoscopic Donor Nephrectomy Facilitated by Deep Neuromuscular Blockade: A Randomized Controlled Study. *World J Surg* 2017; **41**: 2950–2958 [PMID: 28608013 DOI: 10.1007/s00268-017-4080-x]
- 14 Alijani A, Cuschieri A. Abdominal wall lift systems in laparoscopic surgery: gasless and low-pressure systems. *Semin Laparosc Surg* 2001; **8**: 53–62 [PMID: 11337737]
- 15 Uemura N, Nomura M, Inoue S, Endo J, Kishi S, Saito K, Ito S, Nakaya Y. Changes in hemodynamics and autonomic nervous activity in patients undergoing laparoscopic cholecystectomy: differences between the pneumoperitoneum and abdominal wall-lifting method. *Endoscopy* 2002; **34**: 643–650 [PMID: 12173086 DOI: 10.1055/s-2002-33252]
- 16 Galizia G, Prizio G, Lieto E, Castellano P, Pelosio L, Imperatore V, Ferrara A, Pignatelli C. Hemodynamic and pulmonary changes during open, carbon dioxide pneumoperitoneum and abdominal wall-lifting cholecystectomy. A prospective, randomized study. *Surg Endosc* 2001; **15**: 477–483 [PMID: 11353965 DOI: 10.1007/s004640000343]
- 17 Chiu AW, Chang LS, Birkett DH, Babayan RK. The impact of pneumoperitoneum, pneumoretroperitoneum, and gasless laparoscopy on the systemic and renal hemodynamics. *J Am Coll*

- Surg* 1995; **181**: 397-406 [PMID: 7582206]
- 18 **Zhang G**, Liu S, Yu W, Wang L, Liu N, Li F, Hu S. Gasless laparoendoscopic single-site surgery with abdominal wall lift in general surgery: initial experience. *Surg Endosc* 2011; **25**: 298-304 [PMID: 20607566 DOI: 10.1007/s00464-010-1177-9]
- 19 **Park IJ**, Kim SH, Joh YG, Hahn KY. Laparoscopic colorectal surgery using low-pressure pneumoperitoneum combined with abdominal wall lift by placement of anchoring sutures around the camera port. *Surg Endosc* 2006; **20**: 956-959 [PMID: 16738990 DOI: 10.1007/s00464-005-0459-0]
- 20 **Denost Q**, Adam JP, Pontallier A, Celerier B, Laurent C, Rullier E. Laparoscopic total mesorectal excision with coloanal anastomosis for rectal cancer. *Ann Surg* 2015; **261**: 138-143 [PMID: 25185482 DOI: 10.1097/SLA.0000000000000855]
- 21 **Liang JT**, Cheng JC, Huang KC, Lai HS, Sun CT. Comparison of tumor recurrence between laparoscopic total mesorectal excision with sphincter preservation and laparoscopic abdominoperineal resection for low rectal cancer. *Surg Endosc* 2013; **27**: 3452-3464 [PMID: 23508815 DOI: 10.1007/s00464-013-2898-3]
- 22 **Kim MJ**, Park SC, Park JW, Chang HJ, Kim DY, Nam BH, Sohn DK, Oh JH. Robot-assisted Versus Laparoscopic Surgery for Rectal Cancer: A Phase II Open Label Prospective Randomized Controlled Trial. *Ann Surg* 2018; **267**: 243-251 [PMID: 28549014 DOI: 10.1097/SLA.0000000000002321]
- 23 **Martínez-Pérez A**, Carra MC, Brunetti F, de'Angelis N. Pathologic Outcomes of Laparoscopic vs Open Mesorectal Excision for Rectal Cancer: A Systematic Review and Meta-analysis. *JAMA Surg* 2017; **152**: e165665 [PMID: 28196217 DOI: 10.1001/jamasurg.2016.5665]
- 24 **Nagai H**, Kondo Y, Yasuda T, Kasahara K, Kanazawa K. An abdominal wall-lift method of laparoscopic cholecystectomy without peritoneal insufflation. *Surg Laparosc Endosc* 1993; **3**: 175-179 [PMID: 8111552]
- 25 **Hashimoto D**, Nayeem SA, Kajiura S, Hoshino T. Laparoscopic cholecystectomy: an approach without pneumoperitoneum. *Surg Endosc* 1993; **7**: 54-56 [PMID: 8424236]
- 26 **Jiang JK**, Chen WS, Yang SH, Lin TC, Lin JK. Gasless laparoscopy-assisted colorectal surgery. *Surg Endosc* 2001; **15**: 1093-1097 [PMID: 11727077 DOI: 10.1007/s004640080148]
- 27 **Kawamura YJ**, Sawada T, Sunami E, Saito Y, Watanabe T, Masaki T, Muto T. Gasless laparoscopically assisted colonic surgery. *Am J Surg* 1999; **177**: 515-517 [PMID: 10414705]

P- Reviewer: Goldaracena N, Snowdon VK, Yukihiro T

S- Editor: Wang XJ **L- Editor:** Filipodia **E- Editor:** Huang Y





Published by **Baishideng Publishing Group Inc**
7901 Stoneridge Drive, Suite 501, Pleasanton, CA 94588, USA
Telephone: +1-925-223-8242
Fax: +1-925-223-8243
E-mail: bpgoffice@wjgnet.com
Help Desk: <http://www.f6publishing.com/helpdesk>
<http://www.wjgnet.com>



ISSN 1007-9327

