


World Journal of *Clinical Cases*

World J Clin Cases 2018 June 16; 6(6): 99-142





ORIGINAL ARTICLE

Retrospective Cohort Study

- 99 Comparison of simplified and traditional pericardial devascularisation combined with splenectomy for the treatment of portal hypertension

Zhang YF, Ji H, Lu HW, Lu L, Wang L, Wang JL, Li YM

Retrospective Study

- 110 Prognostic role of alpha-fetoprotein response after hepatocellular carcinoma resection

Rungsakulkij N, Suragul W, Mingphruedhi S, Tangtawee P, Muangkaew P, Aeesoa S

CASE REPORT

- 121 T-cell/histiocyte-rich large B-cell lymphoma in a child: A case report and review of literature

Wei C, Wei C, Alhalabi O, Chen L

- 127 Elusive left ventricular thrombus: Diagnostic role of cardiac magnetic resonance imaging-A case report and review of the literature

Siddiqui I, Nguyen T, Movahed A, Kabirdas D

- 132 Intestinal pseudo-obstruction caused by herpes zoster: Case report and pathophysiology

Anaya-Prado R, Pérez-Navarro JV, Corona-Nakamura A, Anaya-Fernández MM, Anaya-Fernández R, Izaguirre-Pérez ME

- 139 Posterobasal left ventricular aneurysm after myocardial infarction with normal coronary arteries: Case-report

Kalinin RE, Suchkov IA, Mzhavanadze ND, Ncheye AF

ABOUT COVER

Editorial Board Member of *World Journal of Clinical Cases*, Xi Jin, PhD, Associate Professor, Doctor, Department of Gastroenterology, Institution of Gastroenterology, the First Affiliated Hospital, School of Medicine Zhejiang University, Zhejiang Province, Hangzhou 310003, China

AIM AND SCOPE

World Journal of Clinical Cases (*World J Clin Cases*, *WJCC*, online ISSN 2307-8960, DOI: 10.12998) is a peer-reviewed open access academic journal that aims to guide clinical practice and improve diagnostic and therapeutic skills of clinicians.

The primary task of *WJCC* is to rapidly publish high-quality Autobiography, Case Report, Clinical Case Conference (Clinicopathological Conference), Clinical Management, Diagnostic Advances, Editorial, Field of Vision, Frontier, Medical Ethics, Original Articles, Clinical Practice, Meta-Analysis, Minireviews, Review, Therapeutics Advances, and Topic Highlight, in the fields of allergy, anesthesiology, cardiac medicine, clinical genetics, clinical neurology, critical care, dentistry, dermatology, emergency medicine, endocrinology, family medicine, gastroenterology and hepatology, geriatrics and gerontology, hematology, immunology, infectious diseases, internal medicine, obstetrics and gynecology, oncology, ophthalmology, orthopedics, otolaryngology, pathology, pediatrics, peripheral vascular disease, psychiatry, radiology, rehabilitation, respiratory medicine, rheumatology, surgery, toxicology, transplantation, and urology and nephrology.

INDEXING/ABSTRACTING

World Journal of Clinical Cases is now indexed in PubMed, PubMed Central, Science Citation Index Expanded (also known as SciSearch®), and Journal Citation Reports/Science Edition.

EDITORS FOR THIS ISSUE

Responsible Assistant Editor: *Xiang Li*
Responsible Electronic Editor: *Wen-Wen Tan*
Proofing Editor-in-Chief: *Lian-Sheng Ma*

Responsible Science Editor: *Fang-Fang Ji*
Proofing Editorial Office Director: *Jin-Lei Wang*

NAME OF JOURNAL
World Journal of Clinical Cases

ISSN
ISSN 2307-8960 (online)

LAUNCH DATE
April 16, 2013

FREQUENCY
Monthly

EDITORS-IN-CHIEF
Sandro Vento, MD, Department of Internal Medicine, University of Botswana, Private Bag 00713, Gaborone, Botswana

EDITORIAL BOARD MEMBERS
All editorial board members resources online at <http://www.wjgnet.com/2307-8960/editorialboard.htm>

EDITORIAL OFFICE
Jin-Lei Wang, Director

World Journal of Clinical Cases
Baishideng Publishing Group Inc
7901 Stoneridge Drive, Suite 501, Pleasanton, CA 94588, USA
Telephone: +1-925-2238242
Fax: +1-925-2238243
E-mail: editorialoffice@wjgnet.com
Help Desk: <http://www.f6publishing.com/helpdesk>
<http://www.wjgnet.com>

PUBLISHER
Baishideng Publishing Group Inc
7901 Stoneridge Drive, Suite 501, Pleasanton, CA 94588, USA
Telephone: +1-925-2238242
Fax: +1-925-2238243
E-mail: bpgoffice@wjgnet.com
Help Desk: <http://www.f6publishing.com/helpdesk>
<http://www.wjgnet.com>

PUBLICATION DATE
June 16, 2018

COPYRIGHT

© 2018 Baishideng Publishing Group Inc. Articles published by this Open Access journal are distributed under the terms of the Creative Commons Attribution Non-commercial License, which permits use, distribution, and reproduction in any medium, provided the original work is properly cited, the use is non commercial and is otherwise in compliance with the license.

SPECIAL STATEMENT

All articles published in journals owned by the Baishideng Publishing Group (BPG) represent the views and opinions of their authors, and not the views, opinions or policies of the BPG, except where otherwise explicitly indicated.

INSTRUCTIONS TO AUTHORS

<http://www.wjgnet.com/bpg/gerinfo/204>

ONLINE SUBMISSION

<http://www.f6publishing.com>

Intestinal pseudo-obstruction caused by herpes zoster: Case report and pathophysiology

Roberto Anaya-Prado, José V Pérez-Navarro, Ana Corona-Nakamura, Michelle M Anaya-Fernández,
Roberto Anaya-Fernández, Marian Eliza Izaguirre-Pérez

Roberto Anaya-Prado, José V Pérez-Navarro, Department of Surgery at Western Medical Center, the Mexican Institute of Social Security, Guadalajara, JAL 44340, México

Roberto Anaya-Prado, Michelle M Anaya-Fernández, Marian Eliza Izaguirre-Pérez, Division of Research at Autonomous University of Guadalajara, Guadalajara, JAL 45200, México

Ana Corona-Nakamura, Department of Infectious Diseases at Western Medical Center, the Mexican Institute of Social Security, Guadalajara, JAL 44340, México

Roberto Anaya-Fernández, Division of Research at University of Guadalajara, Guadalajara, JAL 44340, México

ORCID number: Roberto Anaya-Prado (0000-0001-7097-2540); José V Pérez-Navarro (0000-0002-0279-9456); Ana Corona-Nakamura (0000-0002-0989-478X); Michelle Marie Anaya-Fernández (0000-0002-0781-3579); Roberto Anaya-Fernández (0000-0002-1551-697X); Marian Eliza Izaguirre-Pérez (0000-0003-2675-4161).

Author contributions: Anaya-Prado R and Pérez-Navarro JV designed the report; Anaya-Fernández MM and Anaya-Fernández R collected the patient's clinical data; Corona-Nakamura A and Izaguirre-Pérez ME analysed the data and wrote the paper.

Informed consent statement: The patient involved in this study gave his written informed consent authorizing use and disclosure of his protected health information.

Conflict-of-interest statement: The authors declare no conflict of interest.

CARE Checklist (2013) statement: Guidelines of the CARE Checklist (2013) have been adopted.

Open-Access: This article is an open-access article which was selected by an in-house editor and fully peer-reviewed by external reviewers. It is distributed in accordance with the Creative Commons Attribution Non Commercial (CC BY-NC 4.0) license, which permits others to distribute, remix, adapt, build upon this work non-commercially, and license their derivative works on

different terms, provided the original work is properly cited and the use is non-commercial. See: <http://creativecommons.org/licenses/by-nc/4.0/>

Manuscript source: Unsolicited manuscript

Correspondence to: Roberto Anaya-Prado, MD, PhD, FACS, Director, Division of Research at Autonomous University of Guadalajara, Blvd, Puerta de Hierro No 5150, Edificio B, Segundo Piso, Despacho 201-B. Fraccionamiento Corporativo Zapopan, CP. 45110. Zapopan, Guadalajara, JAL 45200 México. robana@prodigy.net.mx
Telephone: +52-33-38485410

Received: February 7, 2018

Peer-review started: February 8, 2018

First decision: April 13, 2018

Revised: April 27, 2018

Accepted: May 15, 2018

Article in press: May 15, 2018

Published online: June 16, 2018

Abstract

Herpes zoster (HZ) infection occurs in approximately 10% to 30% of individuals. Visceral neuropathies secondary to HZ can cause cystitis and urinary retention. But colonic pseudo-obstruction can also occur. Peripheral neuropathy may reveal segmental motor paresis of either upper or lower limbs, the abdominal muscles or the diaphragm. We report the case of a 62-year-old male patient who presented with abdominal distention and cutaneous vesicular eruption on the left side of the abdominal wall. Plain X-rays and computed tomography scan showed distended small bowel. A diagnosis of intestinal pseudo-obstruction was made secondary to segmental paresis of the small intestine and visceral neuropathy. Conservative management was successful and the patient was discharged uneventfully. Intestinal pseudo-obstruction ought to be considered

when dealing with non-obstructive (adynamic) conditions of the digestive tract associated with HZ infection; since early recognition may help to avoid unnecessary surgery.

Key words: Ogilvie's syndrome; Herpes zoster virus; Neuropathies; Intestinal pseudo-obstruction

© **The Author(s) 2018.** Published by Baishideng Publishing Group Inc. All rights reserved.

Core tip: Ogilvie's syndrome secondary to herpes zoster has been reported as a rare non-surgical complication; but paralytic ileus has received little attention after varicella-zoster reactivation. We report the case of intestinal pseudo-obstruction secondary to small bowel paresis. Possible mechanisms for small bowel involvement and pathophysiology are deeply analysed.

Anaya-Prado R, Pérez-Navarro JV, Corona-Nakamura A, Anaya-Fernández MM, Anaya-Fernández R, Izaguirre-Pérez ME. Intestinal pseudo-obstruction caused by herpes zoster: Case report and pathophysiology. *World J Clin Cases* 2018; 6(6): 132-138 Available from: URL: <http://www.wjgnet.com/2307-8960/full/v6/i6/132.htm> DOI: <http://dx.doi.org/10.12998/wjcc.v6.i6.132>

INTRODUCTION

Herpes zoster (HZ) infection occurs in approximately 10% to 30% of individuals. And, it has been reported that 95% of the complications are sensory^[1-3]. These include acute pain syndromes and post-herpetic neuralgia. Although motor injuries are less frequent, they have a more extensive presentation and can be either visceral or somatic. The somatic motor nerves can be divided into cranial and peripheral. Peripheral neuropathies develop in almost 12% of HZ cases that appear on the head with paralysis of either the fascial or oculomotor areas as the most common clinical features. Peripheral neuropathy can also reveal segmental motor paresis of either the upper and the lower limb muscles, the trunk, the bladder, the gut, or the diaphragm; depending upon the level at which the lesion is located^[2]. The diaphragm becomes affected because of phrenic nerve damage. Visceral neuropathies may involve the bladder and cause cystitis and/or urinary retention. But they can also lead to acute colonic pseudo-obstruction; namely, Ogilvie's syndrome^[1-3]. Predisposing factors for varicella-zoster virus (VZV) reactivation from latency are old age, stress, malnutrition, menstruation, and immunosuppression such as malignancy, post-transplant, and chemotherapy^[3-7].

Bowel obstruction is normally treated with surgery. However, non-mechanical causes of bowel obstruction need to be carefully investigated before considering surgical intervention. This will avoid unnecessary morbidity and mortality associated to the procedure^[2,4]. The

diagnosis of VZV-induced bowel pseudo-obstruction requires a high index of suspicion, because visceral symptomatology may appear before the characteristic skin eruption^[8-12]. Though, the association of HZ and intestinal pseudo-obstruction is not common and has received insufficient attention in the literature^[13-16]. In this paper we describe a patient with intestinal pseudo-obstruction caused by HZ. Its pathophysiology and possible mechanisms for bowel involvement are also addressed.

CASE REPORT

A 62-year-old male patient was admitted with a three-day history of abdominal distention along with abdominal pain, bloating, constipation and concomitant itching and burning skin eruption on the left side of the abdominal wall; which appeared 48 h before admission. Though, there were no complaints of nausea, vomiting or fever. The patient was not taking any medications. On admission, the patient was afebrile and hemodynamically stable. Physical examination revealed abdominal distention and cutaneous vesicular eruption on the left abdomen, extending to the back, not crossing the midline and involving the T7-T10 dermatomes (Figure 1). The abdomen was tense, with tympanitic percussion note all over, with decreased bowel sounds and no signs of peritoneal irritation.

Hamatologic and biochemical tests were all within normal range. Plain X-rays and abdominal computed tomography scan demonstrated distended small bowel loops and air-fluid levels (Figure 2). The diagnosis of intestinal pseudo-obstruction (paralytic Ileus) was made secondary to segmental paresis and visceral neuropathy caused by VZV infection (HZ). Conservative management was then established with nasogastric tube decompression, fasting, intravenous (IV) resuscitation and IV Acyclovir. The patient's abdominal distention gradually resolved over the next 7 d and pain subsided. The patient was discharged on oral vancyclovir and gabapentin, 8 d after admission. On follow-up, fifteen days later, cutaneous vesicles dried up, changed to scabs and dropped off. The patient showed a full and uneventful recovery.

DISCUSSION

Primary infection with VZV usually takes place in early childhood with fever and diffuse maculopapular rash as common clinical features (chickenpox -varicella-). Then, the virus goes dormant (life-long latency period) in the nerves, including the cranial nerve ganglia, dorsal root ganglia, and autonomic ganglia (Figure 3)^[3,6,9]. Of particular importance is the enteric nervous system (ENS) ganglia^[13-17]. Many years after the symptomatic primary infection (chickenpox); endogenous viral reactivation may lead to viral replication and inflammation in the ganglion^[6,7]. Thus, progeny virus migrates along the axons of neurones and is released in the skin, where it causes

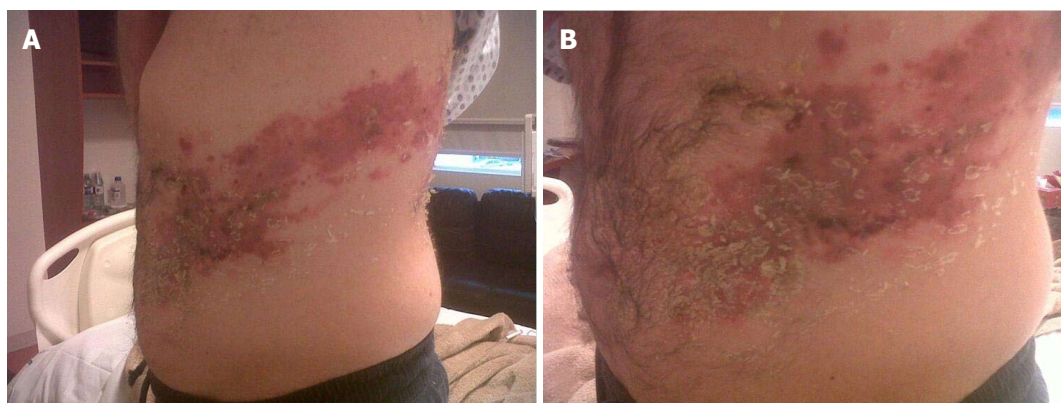

Figure 1 Distended abdomen with vesicular eruption involving the left T7-T10 dermatomes (A and B).

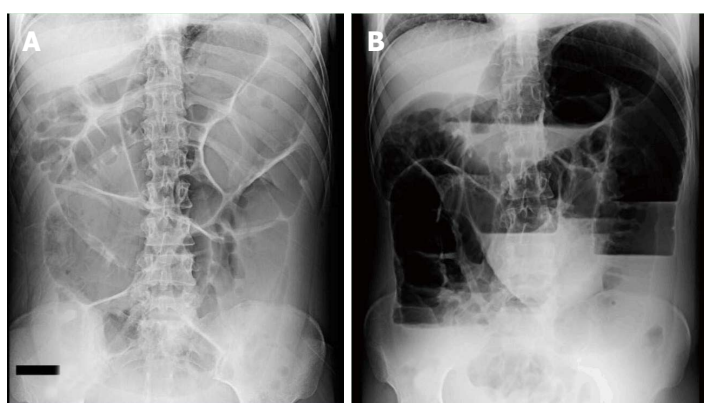


Figure 2 Plain abdominal radiograph revealing diffuse dilatation of the small bowel and air-fluid levels. A: Supine view; B: Upright view.

HZ (shingles)^[6,7,16-18].

With a 5% incidence, peripheral motor neuropathies are the most common neurological complications caused by HZ. They can be either somatic or visceral^[8,18,19]. As far as the abdomen is concerned, VZV has been detected in only four locations: Dorsal root ganglion, spinal cord, adrenal gland and the small bowel^[5-7]. Our case demonstrated clear involvement of the small intestine; as revealed by distended small bowel. Although vesicular eruption and paralytic ileus were both present on admission; we are aware that this is rather an uncommon presentation for patients with HZ and concomitant intestinal pseudo-obstruction. Because dermal eruption has been reported to appear days to weeks after bowel involvement^[3,9,20].

Herpes zoster occurring in the abdomen can lead to paralysis of either the diaphragm or the bladder^[3,9,20-22]. But, gastrointestinal symptomatology is extremely rare. Although the coexistence of HZ and Ogilvie's syndrome has been reported in 30 patients; this presentation is still considered very uncommon^[23-27]. In most of these cases, colonic pseudo-obstruction started days to weeks before skin eruptions appeared. This type of presentation poses a significant diagnostic challenge that may result in unnecessary surgery^[28-32]. On the other hand, diaphragmatic paralysis has also been reported in 30 patients since 1940^[33-37]. These cases were mostly

women (60%) aged 32 to 83 years, with skin vesicles and ipsilateral paralysis^[38-42]. Nevertheless, colonic pseudo-obstruction due to herpes zoster is still considered the most common gastrointestinal complication since the first case reported back in 1950^[43-47]. Interestingly enough, in a letter sent to the editor, an anonymous author already reported HZ involvement of the spinal nerves along with the sympathetic innervation of the transverse colon^[48,49]. So far, this association has been published in 22 studies that include 30 patients^[3,9]. These reports cover 23 men and 7 women aged 32 to 87 years, with significant comorbidities and neoplasms in 45% and 28% of the cases, respectively. Conservative management was therapeutic in most of the cases (83%). Although 2 patients died^[3,9,50-52].

Paralytic ileus (PI) is a less frequently reported gastrointestinal complication following HZ infection. Actually, PI was first described in 1959 by Cane and later by Johnson in 1977^[8,11,53,54]. These authors acknowledged a temporary involvement of the sympathetic innervation of the large intestine as the cause of PI. Actually, these are the only two cases published in the western literature with a satisfactory response to conservative management^[53,54]. This therapy has been demonstrated to be effective for bowel symptoms to subside in an average of 8 d^[11,55,56]. Our case was not the exception and intestinal pseudo-obstruction had an adequate res-

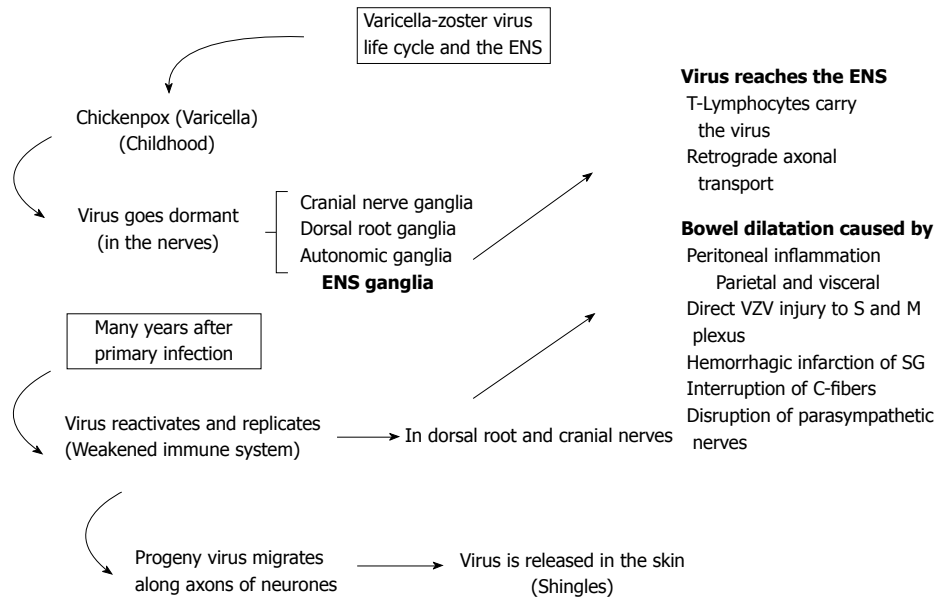


Figure 3 The varicella-zoster virus life cycle. VZV first contact usually takes place early in childhood. Then, the virus goes dormant in the nerves. Years after, endogenous virus reactivation occurs in the ganglion. Virus replicates and migrates to the skin or the ENS, causing either shingles or paralytic ileus, respectively. ENS: Enteric nervous system; S and M: Submucosal and myenteric; SG: Sympathetic ganglia; VZV: Varicella-zoster virus.

ponse to conservative measures. That is, surgery was not necessary^[57].

Many theories have been proposed as possible causes for bowel motor injuries after VZV infection. First, VZV reaches the ENS by means of two possible mechanisms (Figure 4). Either T Lymphocytes carry the virus which gets lodged in the enteric ganglia; or there is a retrograde axonal transport from dorsal-root ganglion neurones infected through their epidermal projections^[2-6]. The fact of the matter is that whatever prompts VZV reactivation is likely to result in the same effect in the ENS neurones^[7-9]. Therefore, bowel dilatation (paralysis) has been suggested to be caused by a series of different actions: (1) parietal and visceral peritoneal inflammation; (2) extrinsic autonomic nervous system viral involvement; (3) direct VZV injury of both the enteric submucosal and myenteric plexus, as well as the muscularis propria; (4) possible hemorrhagic infarction of the abdominal sympathetic ganglia; (5) viral interruption of afferent C-fibers that cause intestinal hypomotility and subsequent pseudo-obstruction; and (6) viral injury of the thoracolumbar or sacral lateral columns resulting in disruption of parasympathetic nerves and subsequent intestinal hypomotility^[3,5-7,9]. Enteric Nervous System involvement was recently demonstrated in two immunocompromised patients. Small intestine biopsies tested positive for VZV DNA. Thus, myenteric plexus and muscularis propria injury were considered responsible for the paralytic Ileus developing in these two patients^[3,9].

We believe that our case followed a similar pattern after HZ infection; that is, paralytic Ileus secondary to myenteric plexus and muscularis propria injury. Lessons learned from postoperative ileus studies support a role for an enhanced release of nitric oxide (NO) after mechanical stimulation of the gut^[41,58]. Though, the

exact source of increased NO production is not clear. However, NO is generally accepted as one of the main neurotransmitters of the inhibitory non-adrenergic non-cholinergic (NANC) nerves in different organ systems, including the gastrointestinal tract. In general, evidence has shown that, by releasing NO, adrenergic and non-adrenergic nerves are involved in the pathogenesis of ileus. The proposed mechanism is that hyperactivity of adrenergic pathways leads to the activation of α_2 -adrenoceptors on the intrinsic cholinergic neurones and to a decreased release of acetylcholine; thereby inhibiting gastrointestinal motility. Furthermore, since NO is an important inhibitory neurotransmitter in the gut; it has been proposed that, in addition to adrenergic pathways, an inhibitory nitrergic NANC pathway is activated, contributing to the genesis of ileus. It has also been proposed that NO release triggers vasoactive intestinal polypeptides as well as the mu or kappa-opioid receptors^[58-60]. These mediators, in turn, trigger macrophages that release proinflammatory cytokines. It has been suggested that activation of the muscularis macrophages is an initial step in the post-surgical inflammatory cascade. These inflammatory reactions depend largely on the expression of Interleukins (IL), especially IL-6; which are known to be prototypic proinflammatory cytokines. And, they have been shown to be involved in the local inflammatory reaction within the intestinal muscularis after surgical insult^[61]. The issue is that the activated inflammatory cascade results in leukocyte and mast cell extravasation into the intestinal muscle. Subsequent to this local muscularis inflammatory response, gastrointestinal motility is diminished, resulting in paralytic ileus^[56,58-61].

Since the number of published studies reporting the combination of HZ and paralytic ileus is very lim-

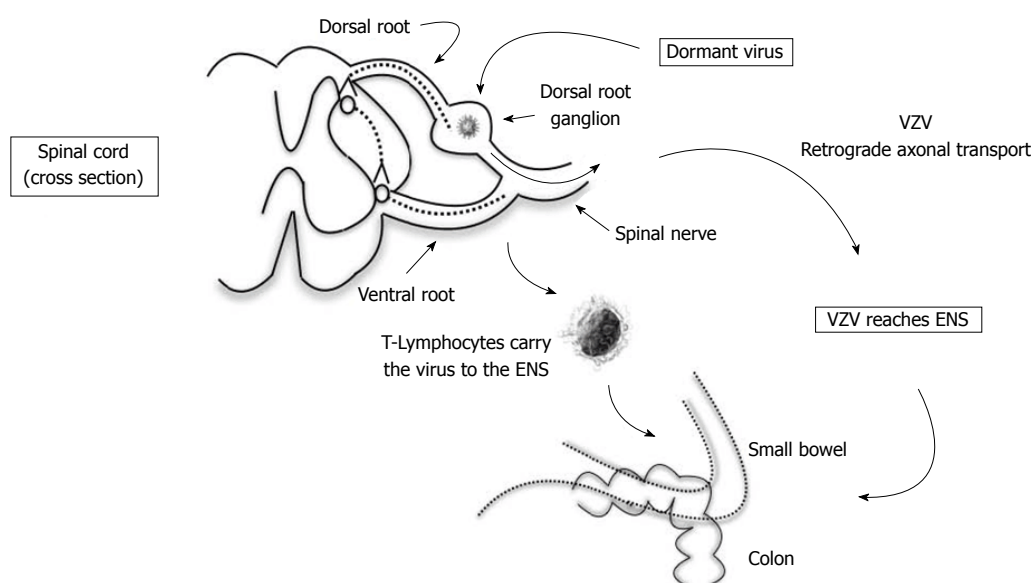


Figure 4 Possible theory explains how varicella-zoster virus reaches the enteric nervous system, causing direct injury to submucosal and myenteric plexus. Either T-Lymphocytes carry the virus from dorsal root ganglion or progeny virus migrates along the axons of neurones in a retrograde fashion. ENS: Enteric nervous system; VZV: Varicella-zoster virus.

ited; study subjects tend to be both insufficient and heterogeneous. In fact, only two studies have reported the presence of VZV in the intestinal muscle (see above)^[3,9]. Additionally, most reported cases involve colonic pseudo-obstruction; that is, Ogilvie's syndrome and HZ. In our case, VZV reactivation took place in the small bowel; thus, paralytic ileus ensued^[11]. Although we have discussed the proposed pathophysiology of postoperative paralytic ileus as well as the possible causes for bowel motor injuries after VZV infection; the bimolecular basis of ENS injury is yet to be clarified^[11,53-56]. However, we believe that VZV triggers an inflammatory cascade similar to that reported in postoperative paralytic ileus^[57-61].

Clinical presentation of paralytic ileus secondary to HZ infection is difficult to differentiate from other causes of mechanical bowel obstruction; abdominal distention included. Furthermore, HZ cutaneous vesicles may or may not appear; which makes diagnosis even more difficult. Although skin lesions have been reported to appear days after acute colonic pseudo-obstruction (Ogilvie's syndrome), therefore, a definitive diagnosis is usually made after non-mechanical conditions (as well as electrolyte disturbances) have been considered and discarded; otherwise, unnecessary surgery will be performed^[11,53-56]. Once diagnosis has been established, conservative management is the treatment of choice of paralytic ileus caused by HZ infection. Thus, supportive measures are initiated with fasting, nasogastric tube decompression (if necessary), intravenous rehydration, correction of electrolyte abnormalities (if any) and treatment of other contributing disorders. On the other hand, antivirals are usually indicated for herpes zoster conditions. However, there is very limited evidence

evaluating their role in the atypical gastrointestinal complications secondary to HZ. So, their efficacy, under these circumstances, is yet to be determined^[11,53,56,62]. In our case, other than the supportive measures, IV Acyclovir was indicated as treatment for the basic contributing disorder (HZ). Evidently, skin rash and intestinal pseudo-obstruction (abdominal distention) improved in a matter of days; however, we cannot conclude that antiviral therapy had a role in intestinal improvement. Still, conservative measures along with antiviral therapy have proven to be effective when dealing with cases of intestinal pseudo-obstruction secondary to HZ infection^[63]. From the surgical perspective, intestinal pseudo-obstruction ought to be considered when dealing with non-obstructive (adynamic) conditions of the digestive tract associated with HZ infection; since early recognition may help to avoid unnecessary surgery.

ARTICLE HIGHLIGHTS

Case characteristics

A 62-year-old male patient presented with abdominal distention and cutaneous vesicular eruption on the left side of the abdominal wall.

Clinical diagnosis

The diagnosis of intestinal pseudo-obstruction (paralytic ileus) was made secondary to segmental paresis and visceral neuropathy caused by varicella-zoster virus (VZV) infection [herpes zoster (HZ)].

Differential diagnosis

Mechanical bowel obstruction ought to be discarded.

Imaging diagnosis

Plain X-rays and computed tomography imaging demonstrated distended small bowel loops suggestive of paralytic ileus.

Treatment

Conservative management was established with nasogastric tube decompression, fasting, intravenous (IV) resuscitation and IV Acyclovir.

Related reports

Most reported cases of intestinal pseudo-obstruction caused by HZ involve the colon. In our case, VZV reactivation took place in the small bowel; which is still considered a very rare gastrointestinal complication.

Term explanation

VZV causes chickenpox (varicella) and HZ.

Experiences and lessons

Intestinal pseudo-obstruction ought to be considered when dealing with non-obstructive (adynamic) conditions of the digestive tract associated with HZ infection; since early recognition may help to avoid unnecessary surgery.

REFERENCES

1. Tribble DR, Church P, Frame JN. Gastrointestinal visceral motor complications of dermatomal herpes zoster: report of two cases and review. *Clin Infect Dis* 1993; **17**: 431-436 [PMID: 8218686 DOI: 10.1093/clinids/17.3.431]
2. Masood I, Majid Z, Rind W, Zia A, Riaz H, Raza S. Herpes Zoster-Induced Ogilvie's Syndrome. *Case Rep Surg* 2015; **2015**: 563659 [PMID: 26664758 DOI: 10.1155/2015/563659]
3. Carrascosa MF, Salcines-Caviedes JR, Román JG, Cano-Hoz M, Fernández-Ayala M, Casuso-Sáenz E, Abascal-Carrera I, Campo-Ruiz A, Martín MC, Díaz-Pérez A, González-Gutiérrez P, Aguado JM. Varicella-zoster virus (VZV) infection as a possible cause of Ogilvie's syndrome in an immunocompromised host. *J Clin Microbiol* 2014; **52**: 2718-2721 [PMID: 24808241 DOI: 10.1128/JCM.00379-14]
4. Tanida E, Izumi M, Abe T, Tsuchiya I, Okuma K, Uchida E, Hidaka A, Hayashi E, Noguchi M, Masui Y, Yoshizawa K, Shirahama K, Kanezaki A. [Disseminated varicella-zoster virus infection complicated with severe abdominal pain and colonic pseudo-obstruction]. *Nihon Shokakibyo Gakkai Zasshi* 2013; **110**: 839-845 [PMID: 23648540 DOI: 10.11405/nisshoshi.110.839]
5. Cohen JL. The varicella-zoster virus genome. *Curr Top Microbiol Immunol* 2010; **342**: 1-14 [PMID: 20225013 DOI: 10.1007/82_2010_10]
6. Chen T, Hudnall SD. Anatomical mapping of human herpesvirus reservoirs of infection. *Mod Pathol* 2006; **19**: 726-737 [PMID: 16528368 DOI: 10.1038/modpathol.3800584]
7. Nikkels AF, Delvenne P, Sadzot-Delvaux C, Debrus S, Piette J, Rentier B, Lipcei G, Quatresooz P, Piérard GE. Distribution of varicella zoster virus and herpes simplex virus in disseminated fatal infections. *J Clin Pathol* 1996; **49**: 243-248 [PMID: 8675738 DOI: 10.1136/jcp.49.3.243]
8. Jucgla A, Badell A, Ballesta C, Arbizu T. Colonic pseudo-obstruction: a complication of herpes zoster. *Br J Dermatol* 1996; **134**: 788-790 [PMID: 8733394 DOI: 10.1046/j.1365-2133.1996.98811.x]
9. Pui JC, Furth EE, Minda J, Montone KT. Demonstration of varicella-zoster virus infection in the muscularis propria and myenteric plexi of the colon in an HIV-positive patient with herpes zoster and small bowel pseudo-obstruction (Ogilvie's syndrome). *Am J Gastroenterol* 2001; **96**: 1627-1630 [PMID: 11374712 DOI: 10.1111/j.1572-0241.2001.03808.x]
10. Rexinger EL. Herpes zoster presenting as soft abdominal mass with obstipation. *Cutis* 1983; **31**: 489 [PMID: 6851642]
11. Johnson JN, Sells RA. Herpes zoster and paralytic ileus: a case report. *Br J Surg* 1977; **64**: 143-144 [PMID: 578122 DOI: 10.1002/bjs.1800640215]
12. Batke M, Cappell MS. Adynamic ileus and acute colonic pseudo-obstruction. *Med Clin North Am* 2008; **92**: 649-670, ix [PMID: 18387380 DOI: 10.1016/j.mcna.2008.01.002]
13. Wyburn-Mason R. Visceral lesions in herpes zoster. *Br Med J* 1957; **1**: 678-681 [PMID: 13404270 DOI: 10.1136/bmj.1.5020.678]
14. Menuck LS, Brahme F, Amberg J, Sherr HP. Colonic changes of herpes zoster. *AJR Am J Roentgenol* 1976; **127**: 273-276 [PMID: 182006 DOI: 10.2214/ajr.127.2.273]
15. Kesner KM, Bar-Maor JA. Herpes zoster causing apparent low colonic obstruction. *Dis Colon Rectum* 1979; **22**: 503-504 [PMID: 583331 DOI: 10.1007/BF02586944]
16. Walsh TN, Lane D. Pseudo obstruction of the colon associated with varicella-zoster infection. *Ir J Med Sci* 1982; **151**: 318-319 [PMID: 6897397 DOI: 10.1007/BF02940213]
17. Zhou SR, Liu CY. A case report of abdominal distention caused by herpes zoster. *World J Gastroenterol* 2012; **18**: 4627-4628 [PMID: 22969239 DOI: 10.3748/wjg.v18.i33.4627]
18. Maeda K, Furukawa K, Sanada M, Kawai H, Yasuda H. Constipation and segmental abdominal paresis followed by herpes zoster. *Intern Med* 2007; **46**: 1487-1488 [PMID: 17827858 DOI: 10.2169/internalmedicine.46.0328]
19. Zell R, Taudien S, Pfaff F, Wutzler P, Platzer M, Sauerbrei A. Sequencing of 21 varicella-zoster virus genomes reveals two novel genotypes and evidence of recombination. *J Virol* 2012; **86**: 1608-1622 [PMID: 22130537 DOI: 10.1128/JVI.06233-11]
20. Edelman DA, Antaki F, Basson MD, Salwen WA, Gruber SA, Losanoff JE. Ogilvie syndrome and herpes zoster: case report and review of the literature. *J Emerg Med* 2010; **39**: 696-700 [PMID: 19327938 DOI: 10.1016/j.jemermed.2009.02.010]
21. Ingraham IE Jr, Estes NA, Bern MM, DeGirolami PC. Disseminated varicella-zoster virus infection with the syndrome of inappropriate antidiuretic hormone. *Arch Intern Med* 1983; **143**: 1270-1271 [PMID: 6305297 DOI: 10.1001/archinte.143.6.1270]
22. Caccese WJ, Bronzo RL, Wadler G, McKinley MJ. Ogilvie's syndrome associated with herpes zoster infection. *J Clin Gastroenterol* 1985; **7**: 309-313 [PMID: 3840187 DOI: 10.1097/00004836-198508000-00008]
23. Pai NB, Murthy RS, Kumar HT, Gerst PH. Association of acute colonic pseudo-obstruction (Ogilvie's syndrome) with herpes zoster. *Am Surg* 1990; **56**: 691-694 [PMID: 2240863]
24. Alpay K, Yandt M. Herpes zoster and Ogilvie's syndrome. *Dermatology* 1994; **189**: 312 [PMID: 7949493 DOI: 10.1159/000246870]
25. Nomdedéu JF, Nomdedéu J, Martino R, Bordes R, Portorreal R, Sureda A, Domingo-Albós A, Rutllant M, Soler J. Ogilvie's syndrome from disseminated varicella-zoster infection and infarcted celiac ganglia. *J Clin Gastroenterol* 1995; **20**: 157-159 [PMID: 7769201 DOI: 10.1097/00004836-199503000-00020]
26. Halpern SL, Covner AH. Motor manifestations of herpes zoster; report of a case of associated permanent paralysis of the phrenic nerve. *Arch Intern Med (Chic)* 1949; **84**: 907-916 [PMID: 15408090 DOI: 10.1001/archinte.1949.00230060064005]
27. Cervia T. [Paralysis of hemidiaphragm by herpes zoster]. *Rev Clin Esp* 1953; **49**: 397-399 [PMID: 13100878]
28. Parker GW, Ramos ED. Paralysis of the phrenic nerve following herpes zoster. *J Am Med Assoc* 1962; **180**: 408-410 [DOI: 10.1001/jama.1962.03050180054016]
29. Spiers AS. Herpes zoster and its motor lesions, with a report of a case of phrenic nerve paralysis. *Med J Aust* 1963; **50**(1): 850-853 [PMID: 13990116]
30. Beard HW. Phrenic paralysis due to herpes zoster. A case report. *Med Bull US Army Eur* 1963; **20**: 106 [PMID: 13969945]
31. Donald TC. Paralysis of the diaphragm secondary to herpes zoster. *J Med Assoc State Ala* 1964; **33**: 306-308 [PMID: 14141884]
32. Brostoff J. Diaphragmatic paralysis after herpes zoster. *Br Med J* 1966; **2**: 1571-1572 [PMID: 5926264 DOI: 10.1136/bmj.2.5529.1571]
33. Pratt JH. Diaphragmatic paralysis after herpes. *Br Med J* 1967; **1**: 234-235 [DOI: 10.1136/bmj.1.5534.234-d]
34. Anderson JP, Keal EE. Cervical herpes zoster and diaphragmatic paralysis. *Br J Dis Chest* 1969; **63**: 222-226 [PMID: 5346817 DOI: 10.1016/S0007-0971(69)80022-7]
35. Dutt AK. Diaphragmatic paralysis caused by herpes zoster. *Am Rev Respir Dis* 1970; **101**: 755-758 [PMID: 5444742]
36. Shivalingappa G. Diaphragmatic paralysis following herpes

- zoster. *Gerontol Clin* (Basel) 1970; **12**: 283-287 [PMID: 4918559 DOI: 10.1159/000245290]
- 37 **Derveaux L**, Lacquet LM. Hemidiaphragmatic paresis after cervical herpes zoster. *Thorax* 1982; **37**: 870-871 [PMID: 6298966 DOI: 10.1136/thx.37.11.870]
- 38 **Hayashi S**, Ichikawa Y, Shoji H, Kaji M. A case of diaphragmatic paralysis and neuralgic amyotrophy-like symptoms following cervical zoster. *Shinkeinaika* 1984; **21**: 484-487
- 39 **Stowasser M**, Cameron J, Oliver WA. Diaphragmatic paralysis following cervical herpes zoster. *Med J Aust* 1990; **153**: 555-556 [PMID: 2233481]
- 40 **Melcher WL**, Dietrich RA, Whitlock WL. Herpes zoster phrenic neuritis with respiratory failure. *West J Med* 1990; **152**: 192-194 [PMID: 2154900]
- 41 **Soler JJ**, Perpiña M, Alfaro A. Hemidiaphragmatic paralysis caused by cervical herpes zoster. *Respiration* 1996; **63**: 403-406 [PMID: 8933664 DOI: 10.1159/000196587]
- 42 **Fujimoto S**, Matsuno O, Matsumoto T, Kumamoto T, Tsuda T. [A case of diaphragmatic paralysis following herpes zoster]. *Rinsho Shinkeigaku* 1996; **36**: 345-347 [PMID: 8752692]
- 43 **Paudyal BP**, Karki A, Zimmerman M, Kayastha G, Acharya P. Hemidiaphragmatic paralysis: a rare complication of cervical herpes zoster. *Kathmandu Univ Med J (KUMJ)* 2006; **4**: 246-248 [PMID: 18603908]
- 44 **Manabe Y**, Higa K, Kawamura M, Hirata K, Hirota K. Ipsilateral diaphragmatic paralysis after cervical herpes zoster. *Pain Clinic* 2007; **53**: 1036-1039
- 45 **Morinaga R**, Matsunaga N, Iwata A, Kishi K, Tokimatsu I, Nagai H, Kadota J. [A case of diaphragmatic paralysis caused by herpes zoster after anticancer chemotherapy]. *Nihon Kokyuki Gakkai Zasshi* 2007; **45**: 166-169 [PMID: 17352174]
- 46 **Hoque R**, Schwendimann RN, Liendo C, Chesson AL Jr. Brachial neuritis with bilateral diaphragmatic paralysis following herpes zoster: a case report. *J Clin Neuromuscul Dis* 2008; **9**: 402-406 [PMID: 18525424 DOI: 10.1097/CND.0b013e318175a5ca]
- 47 **Bahadir C**, Kalpakcioglu AB, Kurtulus D. Unilateral diaphragmatic paralysis and segmental motor paresis following herpes zoster. *Muscle Nerve* 2008; **38**: 1070-1073 [PMID: 18724399 DOI: 10.1002/mus.21042]
- 48 **Oike M**, Naito T, Tsukada M, Kikuchi Y, Sakamoto N, Otsuki Y, Ohshima H, Yokokawa H, Isonuma H, Dambara T. A case of diaphragmatic paralysis complicated by herpes-zoster virus infection. *Intern Med* 2012; **51**: 1259-1263 [PMID: 22687801 DOI: 10.2169/internalmedicine.51.6935]
- 49 Herpes zoster and varicella complicated by paralysis of the transverse colon. *Lancet* 1950; **2**: 822 [DOI: 10.1016/S0140-6736(50)91756-9]
- 50 **Herath P**, Gunawardana SA. Acute colonic pseudo-obstruction associated with varicella zoster infection and acyclovir therapy. *Ceylon Med J* 1997; **42**: 36-37 [PMID: 9164030]
- 51 **Healy C**, McGreal G, Lenehan B, McDermott EW, Murphy JJ. Self-limiting abdominal wall herniation and constipation following herpes zoster infection. *QJM* 1998; **91**: 788-789 [PMID: 10024942 DOI: 10.1093/qjmed/91.11.788]
- 52 **Giunta R**, Marfella MA, Maffei A, Lucivero G. Herpes zoster infection and Ogilvie's syndrome in non-Hodgkin's lymphoma with hypogammaglobulinemia. *Ann Ital Med Int* 2001; **16**: 50-53 [PMID: 11688352]
- 53 **Cane H**. Herpes Zoster and Paralytic Ileus. *Br Med J* 1959; **2**: 887 [DOI: 10.1136/bmj.2.5156.887-b]
- 54 **Hiramatsu S**, Nebiki H, Ueno A, Wakahara Y, Maruyama H, Suekane T, Yamasaki T, Sasaki E, Sano K, Sato H, Nakai T, Kawasaki Y, Kioka K. [A case of paralytic ileus associated with varicella zoster virus infection]. *Nihon Shokakibyo Gakkai Zasshi* 2013; **110**: 1007-1013 [PMID: 23739733 DOI: 10.11405/nissshoshi.110.1007]
- 55 **FIGIEL SJ**, FIGIEL LS. Herpes zoster with ileus simulating intestinal obstruction. *Am J Med* 1957; **23**: 999-1002 [PMID: 13487618 DOI: 10.1016/0002-9343(57)90310-8]
- 56 **Bauer AJ**, Schwarz NT, Moore BA, Türler A, Kalff JC. Ileus in critical illness: mechanisms and management. *Curr Opin Crit Care* 2002; **8**: 152-157 [PMID: 12386517 DOI: 10.1097/00075198-200204000-00011]
- 57 **Braude MR**, Trubiano JA, Heriot A, Dickinson M, Carney D, Seymour JF, Tam CS. Disseminated visceral varicella zoster virus presenting with the constellation of colonic pseudo-obstruction, acalculous cholecystitis and syndrome of inappropriate ADH secretion. *Intern Med J* 2016; **46**: 238-239 [PMID: 26899893 DOI: 10.1111/imj.12977]
- 58 **De Winter BY**, Boeckxstaens GE, De Man JG, Moreels TG, Herman AG, Pelckmans PA. Effect of adrenergic and nitergic blockade on experimental ileus in rats. *Br J Pharmacol* 1997; **120**: 464-468 [PMID: 9031750 DOI: 10.1038/sj.bjp.0700913]
- 59 **Schwarz NT**, Kalff JC, Türler A, Speidel N, Grandis JR, Billiar TR, Bauer AJ. Selective jejunal manipulation causes postoperative pan-enteric inflammation and dysmotility. *Gastroenterology* 2004; **126**: 159-169 [PMID: 14699497 DOI: 10.1053/j.gastro.2003.10.060]
- 60 **De Winter BY**, Boeckxstaens GE, De Man JG, Moreels TG, Herman AG, Pelckmans PA. Effects of mu- and kappa-opioid receptors on postoperative ileus in rats. *Eur J Pharmacol* 1997; **339**: 63-67 [PMID: 9450617 DOI: 10.1016/S0014-2999(97)01345-9]
- 61 **Wehner S**, Behrendt FF, Lyutenski BN, Lysson M, Bauer AJ, Hirner A, Kalff JC. Inhibition of macrophage function prevents intestinal inflammation and postoperative ileus in rodents. *Gut* 2007; **56**: 176-185 [PMID: 16809419 DOI: 10.1136/gut.2005.089615]
- 62 **Hong JJ**, Elgart ML. Gastrointestinal complications of dermatomal herpes zoster successfully treated with famciclovir and lactulose. *J Am Acad Dermatol* 1998; **38**: 279-280 [PMID: 9486692 DOI: 10.1016/S0190-9622(98)70252-X]
- 63 **Rodrigues G**, Kannaiyan L, Gopasetty M, Rao S, Shenoy R. Colonic pseudo-obstruction due to herpes zoster. *Indian J Gastroenterol* 2002; **21**: 203-204 [PMID: 12416757]

P- Reviewer: Sugimoto M, Surani S **S- Editor:** Ji FF

L- Editor: Filipodia **E- Editor:** Tan WW





Published by **Baishideng Publishing Group Inc**
7901 Stoneridge Drive, Suite 501, Pleasanton, CA 94588, USA
Telephone: +1-925-223-8242
Fax: +1-925-223-8243
E-mail: bpgoffice@wjgnet.com
Help Desk: <http://www.f6publishing.com/helpdesk>
<http://www.wjgnet.com>

