

# World Journal of *Gastroenterology*

*World J Gastroenterol* 2018 May 21; 24(19): 2047-2136



**REVIEW**

- 2047** Challenges in diagnosis of pancreatic cancer

*Zhang L, Sanagapalli S, Stoita A*

- 2061** Biliary strictures complicating living donor liver transplantation: Problems, novel insights and solutions

*Rao HB, Prakash A, Sudhindran S, Venu RP*

**MINIREVIEWS**

- 2073** Role of osteoprotegerin/receptor activator of nuclear factor kappa B/receptor activator of nuclear factor kappa B ligand axis in nonalcoholic fatty liver disease

*Pacifico L, Andreoli GM, D'Avanzo M, De Mitri D, Pierimarchi P*

- 2083** Mediterranean diet and nonalcoholic fatty liver disease

*Anania C, Perla FM, Olivero F, Pacifico L, Chiesa C*

**ORIGINAL ARTICLE****Basic Study**

- 2095** Detection of hyper-conserved regions in hepatitis B virus X gene potentially useful for gene therapy

*González C, Tabernero D, Cortese MF, Gregori J, Casillas R, Riveiro-Barciela M, Godoy C, Sopena S, Rando A, Yll M, Lopez-Martinez R, Quer J, Esteban R, Buti M, Rodríguez-Frías F*

**Prospective Study**

- 2108** Decreasing recurrent bowel obstructions, improving quality of life with physiotherapy: Controlled study

*Rice AD, Patterson K, Reed ED, Wurn BF, Robles K, Klingenberg B, Weinstock LB, Pratt JS, King CR, Wurn LJ*

**META-ANALYSIS**

- 2120** Prognostic impact of the red cell distribution width in esophageal cancer patients: A systematic review and meta-analysis

*Xu WY, Yang XB, Wang WQ, Bai Y, Long JY, Lin JZ, Xiong JP, Zheng YC, He XD, Zhao HT, Sang XT*

**CASE REPORT**

- 2130** Pressurized intraperitoneal aerosol chemotherapy after misdiagnosed gastric cancer: Case report and review of the literature

*Nowacki M, Grzanka D, Zegarski W*

## ABOUT COVER

Editorial board member of *World Journal of Gastroenterology*, Pilar Codoñer-Franch, PhD, Professor, Department of Pediatrics, Dr. Peset University Hospital, Valencia 46017, Spain

## AIMS AND SCOPE

*World Journal of Gastroenterology* (*World J Gastroenterol*, *WJG*, print ISSN 1007-9327, online ISSN 2219-2840, DOI: 10.3748) is a peer-reviewed open access journal. *WJG* was established on October 1, 1995. It is published weekly on the 7<sup>th</sup>, 14<sup>th</sup>, 21<sup>st</sup>, and 28<sup>th</sup> each month. The *WJG* Editorial Board consists of 642 experts in gastroenterology and hepatology from 59 countries.

The primary task of *WJG* is to rapidly publish high-quality original articles, reviews, and commentaries in the fields of gastroenterology, hepatology, gastrointestinal endoscopy, gastrointestinal surgery, hepatobiliary surgery, gastrointestinal oncology, gastrointestinal radiation oncology, gastrointestinal imaging, gastrointestinal interventional therapy, gastrointestinal infectious diseases, gastrointestinal pharmacology, gastrointestinal pathophysiology, gastrointestinal pathology, evidence-based medicine in gastroenterology, pancreatology, gastrointestinal laboratory medicine, gastrointestinal molecular biology, gastrointestinal immunology, gastrointestinal microbiology, gastrointestinal genetics, gastrointestinal translational medicine, gastrointestinal diagnostics, and gastrointestinal therapeutics. *WJG* is dedicated to become an influential and prestigious journal in gastroenterology and hepatology, to promote the development of above disciplines, and to improve the diagnostic and therapeutic skill and expertise of clinicians.

## INDEXING/ABSTRACTING

*World Journal of Gastroenterology* (*WJG*) is now indexed in Current Contents<sup>®</sup>/Clinical Medicine, Science Citation Index Expanded (also known as SciSearch<sup>®</sup>), Journal Citation Reports<sup>®</sup>, Index Medicus, MEDLINE, PubMed, PubMed Central and Directory of Open Access Journals. The 2017 edition of Journal Citation Reports<sup>®</sup> cites the 2016 impact factor for *WJG* as 3.365 (5-year impact factor: 3.176), ranking *WJG* as 29<sup>th</sup> among 79 journals in gastroenterology and hepatology (quartile in category Q2).

## EDITORS FOR THIS ISSUE

Responsible Assistant Editor: *Xiang Li*  
Responsible Electronic Editor: *Yan Huang*  
Proofing Editor-in-Chief: *Lian-Sheng Ma*

Responsible Science Editor: *Xue-Jiao Wang*  
Proofing Editorial Office Director: *Ze-Mao Gong*

NAME OF JOURNAL  
*World Journal of Gastroenterology*

ISSN  
ISSN 1007-9327 (print)  
ISSN 2219-2840 (online)

LAUNCH DATE  
October 1, 1995

FREQUENCY  
Weekly

EDITORS-IN-CHIEF  
**Damian Garcia-Olmo, MD, PhD, Doctor, Professor, Surgeon**, Department of Surgery, Universidad Autonoma de Madrid; Department of General Surgery, Fundacion Jimenez Diaz University Hospital, Madrid 28040, Spain

**Stephen C Strom, PhD, Professor**, Department of Laboratory Medicine, Division of Pathology, Karolinska Institutet, Stockholm 141-86, Sweden

**Andrzej S Tarnawski, MD, PhD, DSc (Med), Professor of Medicine, Chief Gastroenterology**, VA Long Beach Health Care System, University of California, Irvine, CA, 5901 E. Seventh Str., Long Beach,

CA 90822, United States

EDITORIAL BOARD MEMBERS  
All editorial board members resources online at <http://www.wjgnet.com/1007-9327/editorialboard.htm>

EDITORIAL OFFICE  
**Ze-Mao Gong, Director**  
*World Journal of Gastroenterology*  
Baishideng Publishing Group Inc  
7901 Stoneridge Drive, Suite 501,  
Pleasanton, CA 94588, USA  
Telephone: +1-925-2238242  
Fax: +1-925-2238243  
E-mail: [editorialoffice@wjgnet.com](mailto:editorialoffice@wjgnet.com)  
Help Desk: <http://www.f6publishing.com/helpdesk>  
<http://www.wjgnet.com>

PUBLISHER  
Baishideng Publishing Group Inc  
7901 Stoneridge Drive, Suite 501,  
Pleasanton, CA 94588, USA  
Telephone: +1-925-2238242  
Fax: +1-925-2238243  
E-mail: [bpgoffice@wjgnet.com](mailto:bpgoffice@wjgnet.com)  
Help Desk: <http://www.f6publishing.com/helpdesk>  
<http://www.wjgnet.com>

PUBLICATION DATE  
May 21, 2018

COPYRIGHT  
© 2018 Baishideng Publishing Group Inc. Articles published by this Open-Access journal are distributed under the terms of the Creative Commons Attribution Non-commercial License, which permits use, distribution, and reproduction in any medium, provided the original work is properly cited, the use is non commercial and is otherwise in compliance with the license.

SPECIAL STATEMENT  
All articles published in journals owned by the Baishideng Publishing Group (BPG) represent the views and opinions of their authors, and not the views, opinions or policies of the BPG, except where otherwise explicitly indicated.

INSTRUCTIONS TO AUTHORS  
Full instructions are available online at <http://www.wjgnet.com/bpg/gerinfo/204>

ONLINE SUBMISSION  
<http://www.f6publishing.com>

## Biliary strictures complicating living donor liver transplantation: Problems, novel insights and solutions

Harshavardhan B Rao, Arjun Prakash, Surendran Sudhindran, Rama P Venu

Harshavardhan B Rao, Arjun Prakash, Rama P Venu, Department of Gastroenterology, Amrita Institute of Medical Sciences, Amrita University, Kochi 682041, India

Surendran Sudhindran, Department of Transplant and Vascular Surgery, Amrita Institute of Medical Sciences, Amrita University, Kochi 682041, India

ORCID number: Harshavardhan B Rao (0000-0002-6472-4396); Arjun Prakash (0000-0002-5706-2507); Surendran Sudhindran (0000-0002-3973-7697); Rama P Venu (0000-0003-2251-3942).

**Author contributions:** All authors contributed equally to this paper in conception and design of the study, literature review and analysis, and drafting, critical revision, editing and approval of the final version.

**Conflict-of-interest statement:** All authors declare no potential conflicts of interest in regards to this manuscript.

**Open-Access:** This article is an open-access article which was selected by an in-house editor and fully peer-reviewed by external reviewers. It is distributed in accordance with the Creative Commons Attribution Non Commercial (CC BY-NC 4.0) license, which permits others to distribute, remix, adapt, build upon this work non-commercially, and license their derivative works on different terms, provided the original work is properly cited and the use is non-commercial. See: <http://creativecommons.org/licenses/by-nc/4.0/>

**Manuscript source:** Invited manuscript

**Correspondence to:** Rama P Venu, FACP, FASGE, MD, Professor and Head, Department of Gastroenterology, Amrita Institute of Medical Sciences, Ponekkara AIMS PO, Kochi, Kerala 682041, India. [ramapvenu@yahoo.com](mailto:ramapvenu@yahoo.com)  
Telephone: +91-974-4314704  
Fax: +91-484-2802120

Received: March 28, 2018

Peer-review started: March 29, 2018

First decision: April 19, 2018

Revised: April 28, 2018

Accepted: May 11, 2018

Article in press: May 11, 2018

Published online: May 21, 2018

### Abstract

Biliary stricture complicating living donor liver transplantation (LDLT) is a relatively common complication, occurring in most transplant centres across the world. Cases of biliary strictures are more common in LDLT than in deceased donor liver transplantation. Endoscopic management is the mainstay for biliary strictures complicating LDLT and includes endoscopic retrograde cholangiography, sphincterotomy and stent placement (with or without balloon dilatation). The efficacy and safety profiles as well as outcomes of endoscopic management of biliary strictures complicating LDLT is an area that needs to be viewed in isolation, owing to its unique set of problems and attending complications; as such, it merits a tailored approach, which is yet to be well established. The diagnostic criteria applied to these strictures are not uniform and are over-reliant on imaging studies showing an anastomotic narrowing. It has to be kept in mind that in the setting of LDLT, a subjective anastomotic narrowing is present in most cases due to a mismatch in ductal diameters. However, whether this narrowing results in a functionally significant narrowing is a question that needs further study. In addition, wide variation in the endotherapy protocols practised in most centres makes it difficult to interpret the results and hampers our understanding of this topic. The outcome definition for endotherapy is also heterogenous and needs to be standardised to allow for comparison of data in this regard and establish a clinical practice guideline. There have been multiple studies in this area in the last 2 years, with novel findings that have provided solutions to some of these issues. This review endeavours to incorporate these new findings into the wider understanding of endotherapy for biliary strictures complicating LDLT, with specific emphasis on diagnosis of strictures in the LDLT



setting, endotherapy protocols and outcome definitions. An attempt is made to present the best management options currently available as well as directions for future research in the area.

**Key words:** Biliary strictures; Endoscopic management; Stenting; Self-expanding metal stents; Living donor liver transplantation

© **The Author(s) 2018.** Published by Baishideng Publishing Group Inc. All rights reserved.

**Core tip:** Multiple lacunae exist in our current understanding of biliary strictures complicating living donor liver transplantation (LDLT). Although endoscopic management is regarded the mainstay of treatment, results are variable with multiple determinants of success. The definition of these strictures itself may need to be re-examined, from a mere narrowing on imaging studies to a more comprehensive approach which can signify functional impedance to bile flow. This review outlines the current practices of management and endeavours to incorporate novel concepts, such as functionally significant obstructions, endoscopic protocols and outcome definitions, into the wider understanding of endoscopic management for biliary strictures complicating LDLT.

Rao HB, Prakash A, Sudhindran S, Venu RP. Biliary strictures complicating living donor liver transplantation: Problems, novel insights and solutions. *World J Gastroenterol* 2018; 24(19): 2061-2072 Available from: URL: <http://www.wjgnet.com/1007-9327/full/v24/i19/2061.htm> DOI: <http://dx.doi.org/10.3748/wjg.v24.i19.2061>

## INTRODUCTION

Biliary stricture complicating living donor liver transplantation (LDLT) is a relatively common complication, occurring in most transplant centres across the world. Improvements in technique, better postoperative care, surgical expertise and immunosuppressive medications have resulted in a decreased incidence of biliary complications over the years<sup>[1-3]</sup>. The Roux en Y hepaticojejunostomy has given way to duct-to-duct anastomosis (DD) which is the preferred mode of biliary reconstruction in most cases<sup>[4-8]</sup>. DD is technically easy, enables rapid gastrointestinal recovery, has a lower risk of cholangitis and maintains physiological choledochoenteric continuity<sup>[2]</sup>. Moreover, DD allows an easy endoscopic access to the anastomosis, enabling endotherapy in most cases. Thus, surgical management of biliary strictures following LDLT has slowly been replaced by endoscopic retrograde cholangiography (ERC) with stent placement, which emerged as the first-line therapy during the last few decades<sup>[1-3,9-11]</sup>.

Compared to deceased donor liver transplantation

(DDLT), the biliary anastomosis in LDLT is more peripheral, smaller and complex<sup>[12,13]</sup>, resulting in tortuous and angulated strictures, especially due to hypertrophy of the transplanted liver<sup>[14]</sup>. As a result, the efficacy and safety profiles as well as the outcomes of endoscopic management of biliary strictures complicating LDLT represents an area that needs to be viewed in isolation, owing to its unique set of problems and attending complications; it merits a tailored approach, which is yet to be well established.

This review focuses on the pathogenesis, morphology and diagnosis of the endoscopic management of biliary strictures complicating LDLT, as well as some unique problems associated with it. An attempt is made to present the best current management options available as well as rational perspectives on future research in the area.

## BILE DUCT STRICTURES: LDLT vs DDLT

LDLT as a treatment for end-stage liver disease is especially popular in most Asian countries, owing to a difficulty in organ procurement from deceased donors<sup>[15-17]</sup>. However, DDLT constitutes the majority of transplants in the West, being performed within the framework of a uniform, systematic organ allocation programme along with better organ procurement from deceased donors, that ensures shorter waiting periods and allows for the use of DDLT as a standard-of-care for end-stage liver disease. As is apparent, this is predicated on a higher number of deceased donors, early referral for liver transplantation, requisite infrastructure and specialised man-power for fair and efficient organ allotment; a lack thereof is palpable in Asia, paving the way for robust LDLT programmes, especially in far eastern countries like those in Japan, Hong Kong, China and Korea<sup>[17-19]</sup>.

While the principles of endoscopic therapy for biliary strictures complicating DDLT are similar to those that occur with LDLT, there seems to be some differences in the incidence, morphology and type of strictures, which can be summarised as follows.

### Incidence

Bile duct strictures are the most common biliary complication after liver transplantation, accounting for approximately 40% of all biliary complications<sup>[7,12,20-23]</sup>. In general, biliary strictures have been reported to occur in up to 5% of DDLT cases<sup>[24,25]</sup>. On the other hand, those of LDLT have been reported to occur more frequently: 7.3%-60.0% in right-lobe grafts<sup>[4,12,26-28]</sup> and 24% in left lateral segment grafts<sup>[29]</sup>. In a study by Gomez *et al*<sup>[30]</sup>, biliary strictures occurred more frequently following LDLT than in DDLT [10/30 (33.3%) vs 27/357 (7.6%), respectively].

### Morphology

Owing to the use of a smaller graft in LDLT (as compared

**Table 1** Incidence of biliary strictures with median time of onset after living donor liver transplantation

Study	Year	Total number, <i>n</i>	Biliary strictures, %	Median time of onset after LT in mo
Yazumi <i>et al</i> <sup>[13]</sup>	2006	273	27	6.2
Seo <i>et al</i> <sup>[43]</sup>	2009	239	12	8.6
Chang <i>et al</i> <sup>[22]</sup>	2010	353	32	-
Hsieh <i>et al</i> <sup>[11]</sup>	2013	110	37	2.1
Wadhawan <i>et al</i> <sup>[93]</sup>	2013	338	10	3
Ranjan <i>et al</i> <sup>[94]</sup>	2016	305	3	12
Rao <i>et al</i> <sup>[31]</sup>	2017	458	10	-

LT: Liver transplantation.

to the whole liver in DDLT), the calibre of the bile ducts used for the anastomosis is smaller, often having a disparity between the recipient and donor ducts. Surgical anastomosis in these cases demand technical expertise and experience in working with small ducts in order to create an anastomosis that is free of tension and has an adequate luminal diameter to enable free flow of bile. As a result, strictures developing in this situation will have a unique morphology and sometimes bizarre configurations. Attempts have been made to classify these strictures based on cholangiographic appearance, size and number of ducts, all of which may have bearing on the outcome of endoscopic management<sup>[31]</sup>.

### Aetiology and type of stricture

Posttransplant biliary strictures can be classified as anastomotic strictures (AS) and nonanastomotic strictures (NAS). AS is more common in LDLT patients than in DDLT patients. This system of classification as AS or NAS is extremely useful as clinical outcomes and treatment modalities of the two types are somewhat different<sup>[1]</sup>. AS account for about 80% of biliary strictures after LDLT<sup>[32]</sup>. Factors contributing to the development of AS include technical problems of the biliary anastomosis, ischemia or bile leaks<sup>[33]</sup>. Although the effect of ischemia is far more pronounced in NAS, it might also play a significant role in AS. AS usually present later in the course of the posttransplant recovery<sup>[34]</sup>, with a median interval of 5-8 mo after the liver transplantation<sup>[20,35,36]</sup>. It usually is a single, sometimes tortuous stricture, at or within 5 mm of the anastomotic site<sup>[33]</sup>.

NAS, on the other hand, usually results from hepatic artery injury or thrombosis, causing irreversible biliary fibrosis due to ischemia<sup>[1]</sup>. Other causes which have been implicated include long cold ischemia time or ABO type incompatibility<sup>[33,37]</sup>. Of all biliary strictures after liver transplantations, NAS accounts for only 10%-25%<sup>[11,13,22]</sup>. In a Japanese study, NAS accounted for only 6% of all biliary strictures and occurred in 5 of the 273 LDLT patients (2%)<sup>[13]</sup>. In another study with 339 patients undergoing right lobe LDLT, only 11 patients (10%) developed NAS, while 121 patients (36%) developed AS, accounting for more than 90% of the biliary strictures in that patient cohort<sup>[22]</sup>. The Mayo Clinic Hospital in Arizona reported only 3 of 110 LDLT patients (3%) developing ischemic-type strictures<sup>[11]</sup>.

## BILIARY STRICTURES COMPLICATING LDLT

### Incidence and pathophysiology

Biliary complications continue to be the most common complication after LDLT, having a reported incidence of 20%-43%, with biliary strictures accounting for 3%-40% of cases. Most biliary strictures present in the first year following the liver transplantation<sup>[9,22,36,38,39]</sup> (Table 1).

With increasing experience in LDLT, in most Asian countries there has been a decrease in overall incidence of biliary complications, from 30% in the initial years to around 15%-25% in recent years<sup>[3,6,20,25,31,40]</sup>. High-volume LDLT centres in Tokyo and Hong Kong, having extensive experience in management of biliary strictures, report a relatively steady rate of biliary strictures, of 20%-25%<sup>[8,41]</sup>. In an elegant study by Morioka *et al*<sup>[21]</sup> from the Kyoto University, LDLT recipients were divided into three time cohorts which differed with regard to case experience. They found that while the rate of bile leak significantly decreased with experience, there were no differences in the development of biliary strictures among the three groups (19%, 28% and 26% in the three groups; *P* = 0.290). In a similar study from the University of Toronto, Shah and colleagues<sup>[20]</sup> did not find any difference in the rate of biliary strictures after chronological stratification of their patient cohort into the first 65 cases and the next 65 cases. However, a recent study by Kim *et al*<sup>[36]</sup> did show that patients who underwent more recent procedures were less likely to have biliary strictures, suggesting a small but important role of surgical expertise on the risk of biliary strictures.

There seems to be several possible factors other than poor surgical expertise that result in bile duct injury and subsequent strictures. Among these, an important cause of strictures is postoperative bile leak that causes local inflammation and fibrosis<sup>[23,38,42,43]</sup>. Other factors identified include older donor age<sup>[20]</sup>, preoperative model of end-stage liver disease score<sup>[40,43]</sup>, multiple biliary ducts<sup>[43]</sup>, graft cold ischemia time<sup>[41,44]</sup>, bile duct diameter<sup>[44,45]</sup>, acute cellular rejection<sup>[41]</sup> and hepatic artery thrombosis (HAT). As evident, most of these factors lead to ischemic injury of the bile duct, eventually culminating in strictures. While ischemia is a major factor in NAS, it also plays a major role in the development of

AS. This is because the bile duct epithelium is particularly vulnerable to ischemia, as compared to hepatocytes or vascular endothelium<sup>[46-48]</sup>. Local ischemic insults can also arise from devascularisation at the time of hilar dissection. Moreover, oxygen supply to the biliary tract is solely supplied by the hepatic artery. Therefore, HAT can lead to severe ischemic stress on the bile duct, resulting in fibrosis and strictures. HAT is a major determinant of NAS<sup>[49]</sup> and complex, long AS<sup>[46]</sup> that are usually difficult to manage endoscopically. In addition, technical factors like the number of biliary anastomosis, discrepancy in ductal diameters, unavailability of biliary microsurgical modalities, and aberrant biliary anatomy have been found to be significant risk factors for the development of biliary strictures<sup>[1,46,50,51]</sup>. Moreover, endoscopic management is particularly affected in patients with multiple biliary anastomoses<sup>[31]</sup>.

Multiple causative factors with intersecting and often overlapping pathophysiological pathways make it impossible to implicate a single factor that can predictably lead to stricture formation. A useful approach would be to aggregate individual factors as a composite score for prognostication, early diagnosis and treatment.

### Diagnostic challenges

The most common clinical presentation of biliary strictures complicating LDLT is a cholestatic pattern of liver function test results, with or without symptoms of obstructive jaundice, such as icterus or pruritus. However, other causes of cholestatic jaundice, such as graft rejection (acute or chronic), recurrence of primary disease (hepatitis B/C), fibrosing cholestatic hepatitis C, sepsis or drug-induced cholestasis<sup>[46]</sup>, make the diagnosis of biliary strictures particularly challenging<sup>[52]</sup>. A high index of suspicion is warranted in such patients, especially since they rarely have abdominal pain due to hepatic denervation and immunosuppressants<sup>[53-55]</sup>. The diagnostic protocol practised in most centres involves a composite approach with clinical features, laboratory evaluation, imaging studies and liver biopsy.

Among the factors detected by laboratory tests, bilirubin, alkaline phosphatase, gamma-glutamyl transferase and the transaminases are assessed initially. However, these tests are nonspecific, with limited diagnostic role for differentiating a biliary cause from a hepatocellular aetiology for the symptoms. Liver biopsy is extremely valuable to differentiate biliary strictures from acute cellular rejection, but since it is an invasive procedure with possible complications, it should be reserved for cases with a high degree of suspicion for rejection.

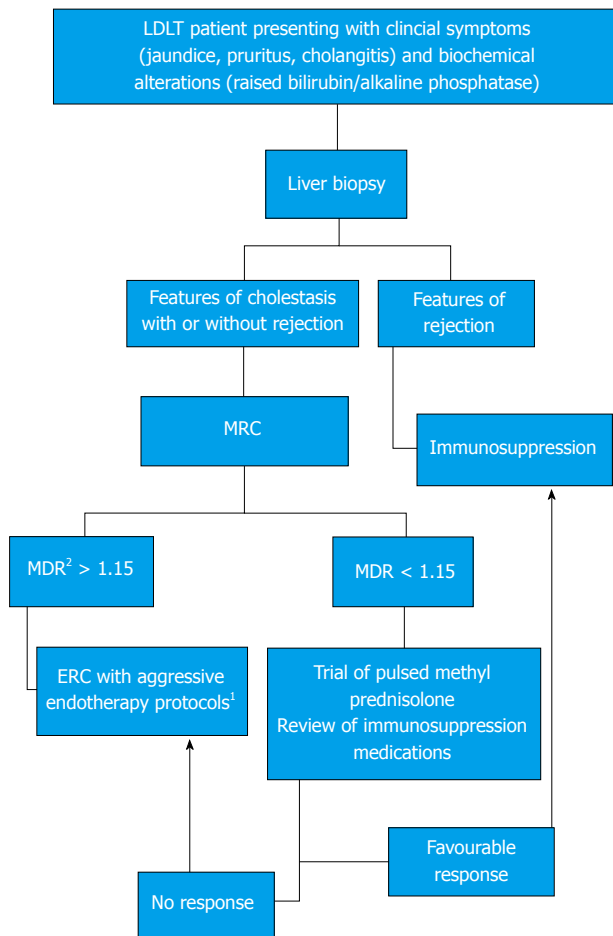
### Imaging studies

Currently, the diagnosis of biliary strictures depends heavily on cross-sectional imaging, which classically demonstrates an anastomotic narrowing. Initial imaging with ultrasonography of the abdomen with Doppler study is carried out to examine the intrahepatic biliary

radicles, along with vascular patency. However, the sensitivity of ultrasonography to detect biliary dilatation in the posttransplant patient is as low as 38%-66%, thereby rendering it unreliable as a sole screening modality for the diagnosis of biliary strictures<sup>[56-58]</sup>. A scan by hepatobiliary iminodiacetic acid scintigraphy is excellent for detecting bile leaks<sup>[59]</sup>; however, its role in detecting biliary strictures is poor, with a sensitivity of around 60%<sup>[59,60]</sup>. Computed tomography is useful for detection of fluid collections and non-biliary lesions, having a higher spatial resolution than magnetic resonance imaging<sup>[61]</sup>. However, it is grossly inadequate for the diagnosis of biliary strictures, unless used in conjunction with the injection of biliary contrast agents, like iodipamide meglumine. These contrast agents have been found to be unsafe, with higher incidence of allergic reactions; as such, the use of computed tomography for biliary strictures has fallen out of favour in most centres.

Magnetic resonance cholangiography (MRC) has emerged as a reliable noninvasive tool to detect biliary strictures complicating LDLT. The presence of bile within the ducts allows for accurate delineation of the biliary tree, which can highlight the anastomotic stricture with diagnostic sensitivity and specificity in excess of 90%<sup>[62-64]</sup>. MRC can provide detailed imaging of the entire biliary tract and is especially useful for complex and intrahepatic strictures. Moreover, it can provide a roadmap for therapeutic interventions. MRC has a high negative predictive value that prevents unnecessary procedures<sup>[65,66]</sup>. The limitations of MRC include lack of interventional capability and high cost as a routine diagnostic modality. It has also been found to have a high rate of false positives.

Most LDLT recipients with DD can show a narrowing of the anastomotic site in the absence of a 'functionally significant obstruction' (FSO). Here, FSO is defined as a critical obstruction at the anastomotic site that results in a clinically significant impedance to bile flow, evidenced by clinical symptoms and biochemical alterations of cholestasis. In our centre, a unique set of metrics are applied in the MRC to indicate FSO. While most literature alludes to a dilated proximal duct and a narrowing as pathognomonic of a stricture<sup>[3]</sup>, we have found it useful to use the ratio of the proximal duct diameter to the recipient ductal diameter to signify FSO. This approach is based on the hypothesis that a FSO should cause impedance of bile flow that will result in the hold-up of bile above the stricture, causing dilatation and higher diameter on MRC, along with collapse of the recipient bile duct below the anastomosis, due to lack of bile flow across the stricture resulting in a smaller ductal diameter on the MRC. The resultant ratio may provide valuable clues as to the severity of obstruction at the anastomosis and enable a singular, reproducible definition of biliary strictures that can potentially dictate further treatment with better outcomes. The management approach practised in our centre using



**Figure 1** Management algorithm used in our centre for the treatment of biliary strictures. <sup>1</sup>Aggressive endotherapy protocols: Multiple ERC with stricture dilatation and gradual upsizing of stents done every 3 mo for a minimum period of 1 yr; <sup>2</sup>MDR = MRC ductal ratio calculated as maximum diameter of the recipient hepatic duct divided by the maximum diameter of the donor bile duct as seen on an MRC done at the time of presentation with clinical symptoms and biochemical alterations. The cut-off of 1.15 was computed after an internal review of our patient data showed a sensitivity and specificity of > 90% for the diagnosis of a functionally significant stricture (unpublished data). ERC: Endoscopic retrograde cholangiography; LDLT: Living donor liver transplant; MRC: Magnetic resonance cholangiography.

this method of diagnosing biliary strictures complicating LDLT is shown in Figure 1. However, prospective trials in multicentric populations are required before widespread application of this definition in the management protocol for biliary strictures.

### Endoscopic management (endotherapy)

Endoscopic management (endotherapy) is usually the first line of treatment for biliary strictures complicating LDLT and includes ERC with biliary sphincterotomy, balloon dilatation and stent placement<sup>[11,30,31]</sup>. Endotherapy is the mainstay of treatment and is usually the only avenue outside of surgery used in a majority of patients. However, endotherapy in LDLT recipients may be difficult because of complex strictures with multiple ductal anastomoses in bizarre configurations<sup>[1]</sup>. It is a point of contention whether balloon dilatation in isolation or

balloon dilatation with stent placement is superior for the treatment of biliary strictures. A higher complication rate notwithstanding, stent placement after balloon dilatation should be the standard of care in these patients<sup>[67,68]</sup>. Moreover, endotherapy has the advantage over percutaneous transhepatic cholangiography because it enables the placement of multiple large-calibre stents, and is more physiological and less invasive.

### Who will benefit from endotherapy?

Various studies have tried to identify factors influencing the outcome of endoscopic management in postLDLT biliary strictures (Table 2). The detection of these factors would help in streamlining the decision-making process and ideal patient selection for endotherapy. Donor characteristics, and pretransplant and posttransplant factors have been found to influence the endoscopic outcomes<sup>[9,22,31,43,69]</sup>. Chang *et al.*<sup>[22]</sup> reported an overall success rate of only 48%, especially for patients with NAS ( $P = 0.016$ ) and strictures associated with posttransplant hepatic artery stenosis/thrombosis ( $P = 0.016$ ). Kim *et al.*<sup>[70]</sup> reported that only the interval between LDLT and the first ERC had an effect on the outcome with endotherapy and, contrary to other reports, that longer stricture duration had a better outcome ( $P = 0.041$ ). Swan neck deformity in right-lobe LDLT was also seen as a risk factor for difficult endoscopic procedure as well as poorer outcomes. Finally, bile leaks were found to be one of the most important risk factors for stricture formation as well as poorer stricture resolution with endotherapy<sup>[70]</sup>. Kato *et al.*<sup>[31]</sup> reported a 51% overall rate of stricture resolution in postLDLT biliary strictures with DD and noted bile leaks as the major cause of stent failure<sup>[9]</sup>. Our previous study showed HAT, multiple biliary anastomosis and older donor age to be significant predictors of poor outcome to endotherapy.

A paucity of conclusive evidence in the background of heterogenous patient populations and endoscopic management protocols make it difficult to identify a subgroup of patients who will respond to endotherapy in a predictable fashion. In this regard, uniform criteria for diagnosis of biliary strictures as FSO may aid in identifying patients with a significant stricture amenable to endotherapy, an approach that needs further validation.

### When to intervene?

The timing of intervention has been an area that has lacked adequate validation. Usually, ERC in the first few weeks after LT is considered dangerous, due to the risk of damage to the anastomosis. This, however, is more applicable for bile leaks, as opposed to strictures since the development of strictures usually takes a long time. It is important to note that strictures that develop in the first 6 mo are more likely to respond to endotherapy than strictures that present late<sup>[20,69]</sup>.

A subgroup of patients that merit further study in-



cludes those who present with asymptomatic biochemical alterations, liver biopsy inconclusive of rejection and imaging studies showing an anastomotic narrowing. The question of whether to wait it out or subject the patient to aggressive endotherapy protocols is a particularly harrowing one. On the one hand, there is considerable data which have demonstrated that a delay in treatment may be a significant determinant of poor response to endotherapy<sup>[71,72]</sup>. In a study by Buxbaum *et al*<sup>[69]</sup> it was noted that a longer waiting time for ERCP was related with a greater likelihood of failure with endotherapy. However, the quantitative finding did not reach statistical significance. In our previous report, we found a similar inverse relationship between time to ERC and endoscopic success, but again the finding was not statistically significant<sup>[69]</sup>. However, in the study by Shah *et al*<sup>[20]</sup>, a similar patient subgroup was kept under follow-up with close observation and most were found to be stricture-free during the long-term follow-up.

It would seem plausible that a delay in ERC with stent placement should lead to a suboptimal success owing to establishment and organisation of the fibrosis; however, the identification of strictures that merit treatment, as opposed to those that can be managed conservatively, warrants further study. Again, in this regard, the concept of FSO alluded to earlier may provide some valuable insights. Yet, larger studies exploring the accurate definition of FSO are needed before any recommendations are made, and current practice of early ERC with stent placement after balloon dilation should be continued until proven otherwise.

### **Protocol for endoscopic management of strictures**

Ideal endoscopic management protocols include ERC with endoscopic sphincterotomy, balloon dilatation and stent placement. Repeated ERC at 2- to 3-mo intervals with up-sizing of the stent or the use of multiple stents with or without repeated balloon dilation for at least 1 year is the most preferred protocol across transplant centres globally<sup>[2,3]</sup>. However, the need for balloon dilation of the strictures prior to the placement of endoprosthesis is not universally accepted, with some endoscopists opting for stent placement alone in the first ERC, followed by balloon dilations in subsequent ERC. Yet, there is no data that suggests superiority of this method over both balloon dilation and stent placement at the first ERC.

In 2003, Park *et al*<sup>[73]</sup> described an alternate protocol wherein patients without a significant narrowing on ERC are dilated with a balloon after sphincterotomy and a 5F nasobiliary catheter is placed above the stricture. This has many theoretical advantages in that it is easy to perform a cholangiogram to assess improvement of the stricture and obtain bile samples for culture; thus, occlusion of the drain is readily diagnosed and does not necessitate a repeat endoscopy to remove the catheter<sup>[73]</sup>. However, it is not a widespread endoscopic protocol because of reduced patient acceptance

with no uniform data on therapeutic superiority. An ideal approach to this decision should involve careful consideration of the time interval between the ERC and liver transplantation, the ductal diameters and length of the stricture before coming to a decision on the use of both balloon dilation and stent therapy.

The need for endoscopic sphincterotomy has also been examined, with a few authors proposing stent placement across an intact sphincter of Oddi to reduce the incidence of cholangitis and pancreatitis<sup>[13,74]</sup>. However, there is no data corroborating this perceived risk of cholangitis. Moreover, we have found that the incidence of postERC pancreatitis is lower in liver transplantation patients than in the general patient population - a finding that was also observed in a multicentric study by Law and colleagues<sup>[75]</sup>. This can be due to as yet unidentified effects of immunosuppressants on the inflammatory cascade that drives post ERC pancreatitis, representing an area that needs further study.

The major disadvantage of endoscopic therapy is the necessity for frequent procedures required for stent exchanges, which may increase complications in addition to increased cost of care. Stent exchanges are usually performed every 2-3 mo to avoid stent occlusion and cholangitis. Most of the studies in this regard have been on DDLT patients, but it seems reasonable to apply the same protocol in LDLT patients. Few studies<sup>[76]</sup> have performed stent exchanges and dilation every 2 wk and shown a superior success rate. Tabibian *et al*<sup>[77]</sup> showed that a stent therapy protocol wherein stent exchanges are performed only once the patient is symptomatic is superior to protocol-driven procedures. However, it would seem pragmatic to exchange the stents every 3 mo for a minimum of four exchanges over a 1 year period and give a stent-free trial provided the last cholangiogram shows stricture resolution.

Some Japanese groups advocate the placement of 'inside stents', whereby the plastic stent is completely in the bile duct with an intact sphincter, reducing the duodenobiliary reflux and consequently preventing cholangitis<sup>[13,14,74,78]</sup>. This is postulated to improve stent patency rates, with fewer ERC requirements and lower incidence of cholangitis as it prevents duodenobiliary reflux. The University of Kyoto reported use of a similar strategy, with modified Amsterdam stents placed inside the bile duct in 94/118 LDLT patients (80%) and yielding a stricture resolution rate of 68%<sup>[74]</sup>. Tsujino and colleagues<sup>[2]</sup> at the University of Tokyo, in as-yet unpublished data, have alluded to their experience in the area with 63 LDLT recipients who underwent inside stent placement. The median interval for stent exchange was as high as 161 d, with cumulative risk of stent dysfunction being 12.3% at 6 mo and 18.1% at 12 mo<sup>[2]</sup>.

Another promising approach is the use of the self-expanding metal stent (SEMS). SEMS was introduced to overcome the need for repeated procedures in

**Table 2** Therapeutic efficacy and factors affecting outcome of endotherapy in biliary strictures complicating living donor liver transplantation

Study	Year	Biliary strictures, <i>n</i> (%)	Median duration of stent therapy	Overall stricture resolution, %	Factors that affected endoscopic outcome
Zoepef <i>et al</i> <sup>[68]</sup>	2005	7 (7.78)	4 mo	100	NAS, HAT, Pretransplant TACE
Yazumi <i>et al</i> <sup>[13]</sup>	2006	75 (27.5)	8.9 mo	33	
Gomez <i>et al</i> <sup>[30]</sup>	2009	10 (33.34)		20	
Seo <i>et al</i> <sup>[43]</sup>	2009	29 (12.1)	24.1 ± 12.7 wk	65	
Chang <i>et al</i> <sup>[22]</sup>	2010	113 (32)		48	
Hsieh <i>et al</i> <sup>[11]</sup>	2013	41 (37.3)	5.3 mo	79	Donor age, multiple biliary anastomoses, duration of stent therapy
Wadhawan <i>et al</i> <sup>[93]</sup>	2013	35 (10.4)		91	
Ranjan <i>et al</i> <sup>[94]</sup>	2016	10 (3.28)	4 mo	70	
Rao <i>et al</i> <sup>[31]</sup>	2017	41 (10.2)	6 mo	48	
Kato <i>et al</i> <sup>[9]</sup>	2009	41 (42.7)	14.5 mo	85	

HAT: Hepatic artery thrombosis; NAS: Nonanastomotic strictures; TACE: Transarterial chemoembolization.

**Table 3** Role of self-expanding metal stent in the management of post living donor liver transplantation biliary strictures

Study	Year	Patients who underwent cSEMS, <i>n</i>	Duration of stent therapy	Stricture resolution, %	Complications, %
Kaffes <i>et al</i> <sup>[87]</sup>	2014	10	12 wk	100	10
Jang <i>et al</i> <sup>[89]</sup>	2017	35	3.2 ± 1.4 mo	82.9	14.3
Kao <i>et al</i> <sup>[88]</sup> <sup>1</sup>	2013	200	3 mo	80-95	16
Rao <i>et al</i> <sup>2</sup>	2018	4	8 mo		75

<sup>1</sup>This was a meta-analysis comparing SEMS with multiple plastic stent, and both DDLT and LDLT patients were included; <sup>2</sup>Unpublished data. cSEMS: Covered Self-expanding metal stent; DDLT: Dead donor liver transplantation; SEMS: Self-expanding metal stent.

conjunction with providing better and faster stricture resolution in these patients, owing to the larger diameter (30F) of the stents. The initial use of uncovered SEMS proved to be a disaster because of high rates of complications due to stent ingrowth and over-growth causing stent occlusion, formation of biliary sludge and stones within the stents, and more importantly vascular complications in the long term<sup>[79-82]</sup>. Covered (c)SEMS was subsequently introduced and seemed to counter most of the disadvantages of the uncovered SEMS (Table 3). The ease of endoscopic removal of cSEMS makes them an ideal treatment modality for benign biliary strictures.

Randomised controlled trials in DDLT patients comparing SEMS with multiple plastic stents have shown they are similar with respect to stricture resolution, but SEMS required fewer interventions compared to plastic stents<sup>[83,84]</sup>. A recent meta-analysis also showed no superiority of SEMS over multiple plastic stenting, but supported the use of SEMS owing to shorter treatment time and fewer procedures<sup>[85]</sup>. Very few reports have explored the role of SEMS in LDLT patients<sup>[86-88]</sup>. In an elegant study by Jang *et al*<sup>[89]</sup>, a short fully-covered SEMS with a waist in the centre to prevent migration (Kaffes stent by Taewoong Medical, Seoul, South Korea) (Figure 2) was used in 35 LDLT patients with refractory strictures. The cases showed an excellent response rate, with 83% stricture resolution and 6% migration<sup>[89]</sup>. However, the safety and efficacy of SEMS in LDLT is yet

to be understood. At our centre, cSEMS was deployed in 4 LDLT recipients with refractory biliary strictures. However, stent occlusion due to sludge and stones was seen in 3/4 patients (75%) (unpublished data), necessitating additional plastic stent placement inside the cSEMS.

The placement of cSEMS in high anastomotic strictures may also lead to blockage of secondary branches of the bile duct and subsequent biliary stasis in those segments. Tsujino and colleagues<sup>[71]</sup> at the University of Tokyo advocate the placement of inside stents along with covered SEMS to counter this problem, and this approach seems to hold promise pending future studies. A particularly distressing complication of cSEMS is stent migration, which is reported in 16%-33% of cases<sup>[83,88]</sup>. The rate of stent migration seems to be higher in LDLT patients than other patients with benign biliary strictures<sup>[90]</sup>. Finally, the placement of cSEMS may aid duodenobiliary reflux due to disruption of the sphincter mechanism and possibly result in ascending cholangitis.

### Endoscopic management: Outcome

In order to discuss therapeutic efficacy, a uniform definition of biliary strictures has to be established. Most studies have used multiple criteria for endoscopic success, and these include symptomatic and/or biochemical improvement, imaging studies showing resolution of stricture, and absence of recurrence of cholestasis requi-



**Figure 2** Fully-covered modified self-expanding metal stent used in the management of biliary strictures complicating Living donor liver transplantation. The Kaffes stent (Taewoong Medical, Seoul, South Korea) is shown.

ring endoscopic/percutaneous interventions<sup>[9,14,31,69,91]</sup>. It would seem beneficial to study these patients at two time points - one assessing the response after a protocol-based endotherapy practice for a minimum of 1 year, and a more long-term evaluation to assess rate of recurrence and need for repeat interventions. Both these treatment endpoint scans provide valuable insights on the course of AS and will help in establishing a uniform treatment protocol and follow-up.

In the study by Buxbaum *et al*<sup>[69]</sup>, long-term success was evaluated as a treatment goal and a 68% success rate was found. In our previous report, stricture resolution at the end of 1 year was only 48%<sup>[31]</sup>. This low rate of stricture resolution may be due to a larger proportion of patients who had multiple biliary anastomoses, older donor age and/or a nonuniform endoscopy protocol applied for management. Future studies likely need to look at a composite outcome, combined with better patient selection criteria, which can yield uniform and predictable results of therapeutic efficacy for endotherapy.

In the event of technical failure of ERC, which is defined as inability to cross the stricture with a guidewire, a percutaneous transhepatic cholangiography with biliary drainage *via* a percutaneous catheter can be performed<sup>[70,73]</sup>. It is usually successful, especially in patients with cholangitis who need urgent biliary drainage. Percutaneous transhepatic cholangiography with drainage is still a second-line therapy, as it is invasive and carries risk of complications like bleeding, pseudoaneurysm of the hepatic artery, bile leaks, infection, arterioportal fistula and portal vein thrombosis<sup>[45,92]</sup>. Patient compliance is also poor, and it is usually combined with an ERC in a rendezvous procedure at our centre. Using this technique, we have been able to get across the stricture in most patients. All our patients who have undergone the rendezvous procedure had subsequent successful ERC with stent exchanges, and documented resolution of stricture. We found that it is safe and precludes surgery in most patients with a primary endoscopic failure.

## NOVEL INSIGHTS AND AREAS OF FUTURE RESEARCH

As in any scientific work, the formulation of the problem

is paramount for the development of a solution which more often than not is obvious to a trained clinician. To that end, the definition of biliary strictures in most studies is not uniform and needs to be re-examined. In the study by Buxbaum and colleagues<sup>[69]</sup>, cholangiographic appearance of narrowing in a patient with altered liver functions were treated with endoscopy. In the study conducted at the University of Toronto, however, only symptomatic alterations of liver function tests in conjunction with a narrowing on imaging were considered for endoscopic management<sup>[20]</sup>. In our study on LDLT recipients, we also included asymptomatic patients with biochemical and imaging features of biliary obstruction<sup>[31]</sup>. This nonuniform definition is reflected in the varying success rates of endotherapy reported from these three studies (68%, 81% and 48% respectively).

A stricture that responds to endoscopic therapy should be regarded as a 'true' stricture, or more appropriately a FSO. This may provide a multidimensional definition of biliary strictures that has the potential to streamline patients into mutually exclusive treatment pathways and ensure therapeutic efficacy. The ratio between donor duct diameter and the recipient ductal diameter on the MRC in conjunction with a subjective assessment of contrast drainage across the stricture during the ERC to indirectly signify the functional impedance to bile flow of the stricture has been found to be useful in our centre, having a superior therapeutic efficacy of 83% in preliminary findings (unpublished data). This approach to seek out an obstruction that is functionally significant in a symptomatic patient may yield a patient group who will be predictably responsive to endotherapy.

However, it is important to understand that endotherapy may not be the answer for all strictures across the board. As Abraham H Maslow remarked - 'If the only tool you have is a hammer, it is tempting to treat everything as if it were a nail'; it is important to realise that certain patients with biliary strictures of an unfavourable morphology will not respond as well to endotherapy. The correct identification of the patients who will respond to endotherapy is the need of the hour. The development of innovative modalities, newer stent designs and endoscopic accessories needs to propel future work in this area, especially for those patients who are refractory to stent therapy.

## REFERENCES

- 1 **Koneru B**, Sterling MJ, Bahramipour PF. Bile duct strictures after liver transplantation: a changing landscape of the Achilles' heel. *Liver Transpl* 2006; **12**: 702-704 [PMID: 16628684 DOI: 10.1002/lt.20753]
- 2 **Tsujino T**, Isayama H, Kogure H, Sato T, Nakai Y, Koike K. Endoscopic management of biliary strictures after living donor liver transplantation. *Clin J Gastroenterol* 2017; **10**: 297-311 [PMID: 28600688 DOI: 10.1007/s12328-017-0754-z]
- 3 **Wadhawan M**, Kumar A. Management issues in post living donor liver transplant biliary strictures. *World J Hepatol* 2016; **8**: 461-470 [PMID: 27057304 DOI: 10.4254/wjh.v8.i10.461]
- 4 **Ishiko T**, Egawa H, Kasahara M, Nakamura T, Oike F, Kaihara S, Kiuchi T, Uemoto S, Inomata Y, Tanaka K. Duct-to-duct biliary reconstruction in living donor liver transplantation utilizing right lobe graft. *Ann Surg* 2002; **236**: 235-240 [PMID: 12170029 DOI: 10.1097/00000658-200208000-00012]
- 5 **Dulundu E**, Sugawara Y, Sano K, Kishi Y, Akamatsu N, Kaneko J, Imamura H, Kokudo N, Makuuchi M. Duct-to-duct biliary reconstruction in adult living-donor liver transplantation. *Transplantation* 2004; **78**: 574-579 [PMID: 15446317]
- 6 **Sugawara Y**, Makuuchi M. Advances in adult living donor liver transplantation: a review based on reports from the 10th anniversary of the adult-to-adult living donor liver transplantation meeting in Tokyo. *Liver Transpl* 2004; **10**: 715-720 [PMID: 15162463 DOI: 10.1002/lt.20179]
- 7 **Hwang S**, Lee SG, Sung KB, Park KM, Kim KH, Ahn CS, Lee YJ, Lee SK, Hwang GS, Moon DB, Ha TY, Kim DS, Jung JP, Song GW. Long-term incidence, risk factors, and management of biliary complications after adult living donor liver transplantation. *Liver Transpl* 2006; **12**: 831-838 [PMID: 16528711 DOI: 10.1002/lt.20693]
- 8 **Kyoden Y**, Tamura S, Sugawara Y, Matsui Y, Togashi J, Kaneko J, Kokudo N, Makuuchi M. Incidence and management of biliary complications after adult-to-adult living donor liver transplantation. *Clin Transplant* 2010; **24**: 535-542 [PMID: 19849703 DOI: 10.1111/j.1399-0012.2009.01124.x]
- 9 **Kato H**, Kawamoto H, Tsutsumi K, Harada R, Fujii M, Hirao K, Kurihara N, Mizuno O, Ishida E, Ogawa T, Fukatsu H, Yamamoto K, Yagi T. Long-term outcomes of endoscopic management for biliary strictures after living donor liver transplantation with duct-to-duct reconstruction. *Transpl Int* 2009; **22**: 914-921 [PMID: 19497069 DOI: 10.1111/j.1432-2277.2009.00895.x]
- 10 **Chang JH**, Lee I, Choi MG, Han SW. Current diagnosis and treatment of benign biliary strictures after living donor liver transplantation. *World J Gastroenterol* 2016; **22**: 1593-1606 [PMID: 26819525 DOI: 10.3748/wjg.v22.i4.1593]
- 11 **Hsieh TH**, Mekeel KL, Crowell MD, Nguyen CC, Das A, Aqel BA, Carey EJ, Byrne TJ, Vargas HE, Douglas DD, Mulligan DC, Harrison ME. Endoscopic treatment of anastomotic biliary strictures after living donor liver transplantation: outcomes after maximal stent therapy. *Gastrointest Endosc* 2013; **77**: 47-54 [PMID: 23062758 DOI: 10.1016/j.gie.2012.08.034]
- 12 **Gondolesi GE**, Varotti G, Florman SS, Muñoz L, Fishbein TM, Emre SH, Schwartz ME, Miller C. Biliary complications in 96 consecutive right lobe living donor transplant recipients. *Transplantation* 2004; **77**: 1842-1848 [PMID: 15223901]
- 13 **Yazumi S**, Yoshimoto T, Hisatsune H, Hasegawa K, Kida M, Tada S, Uenoyama Y, Yamauchi J, Shio S, Kasahara M, Ogawa K, Egawa H, Tanaka K, Chiba T. Endoscopic treatment of biliary complications after right-lobe living-donor liver transplantation with duct-to-duct biliary anastomosis. *J Hepatobiliary Pancreat Surg* 2006; **13**: 502-510 [PMID: 17139423 DOI: 10.1007/s00534-005-1084-y]
- 14 **Tsujino T**, Isayama H, Sugawara Y, Sasaki T, Kogure H, Nakai Y, Yamamoto N, Sasahira N, Yamashiki N, Tada M, Yoshida H, Kokudo N, Kawabe T, Makuuchi M, Omata M. Endoscopic management of biliary complications after adult living donor liver transplantation. *Am J Gastroenterol* 2006; **101**: 2230-2236 [PMID: 16952286 DOI: 10.1111/j.1572-0241.2006.00797.x]
- 15 **Lee SG**. Asian contribution to living donor liver transplantation. *J Gastroenterol Hepatol* 2006; **21**: 572-574 [PMID: 16638101 DOI: 10.1111/j.1440-1746.2006.04283.x]
- 16 **Lo CM**. Deceased donation in Asia: challenges and opportunities. *Liver Transpl* 2012; **18** Suppl 2: S5-S7 [PMID: 22961949 DOI: 10.1002/lt.23545]
- 17 **Rela M**, Reddy MS. Living donor liver transplant (LDLT) is the way forward in Asia. *Hepatol Int* 2017; **11**: 148-151 [PMID: 28097531 DOI: 10.1007/s12072-016-9780-z]
- 18 **Chen CL**, Kabilig CS, Concejero AM. Why does living donor liver transplantation flourish in Asia? *Nat Rev Gastroenterol Hepatol* 2013; **10**: 746-751 [PMID: 24100300 DOI: 10.1038/nrgastro.2013.194]
- 19 **Ng KK**, Lo CM. Liver transplantation in Asia: past, present and future. *Ann Acad Med Singapore* 2009; **38**: 322-310 [PMID: 19434335 DOI: 10.1055/s-2008-1071097]
- 20 **Shah SA**, Grant DR, McGilvray ID, Greig PD, Selzner M, Lilly LB, Girgrah N, Levy GA, Cattral MS. Biliary strictures in 130 consecutive right lobe living donor liver transplant recipients: results of a Western center. *Am J Transplant* 2007; **7**: 161-167 [PMID: 17227565 DOI: 10.1111/j.1600-6143.2006.01601.x]
- 21 **Morioka D**, Egawa H, Kasahara M, Ito T, Haga H, Takada Y, Shimada H, Tanaka K. Outcomes of adult-to-adult living donor liver transplantation: a single institution's experience with 335 consecutive cases. *Ann Surg* 2007; **245**: 315-325 [PMID: 17245187 DOI: 10.1097/01.sla.0000236600.24667.a4]
- 22 **Chang JH**, Lee IS, Choi JY, Yoon SK, Kim DG, You YK, Chun HJ, Lee DK, Choi MG, Chung IS. Biliary Stricture after Adult Right-Lobe Living-Donor Liver Transplantation with Duct-to-Duct Anastomosis: Long-Term Outcome and Its Related Factors after Endoscopic Treatment. *Gut Liver* 2010; **4**: 226-233 [PMID: 20559526 DOI: 10.5009/gnl.2010.4.2.226]
- 23 **Zimmerman MA**, Baker T, Goodrich NP, Freise C, Hong JC, Kumer S, Abt P, Cotterell AH, Samstein B, Everhart JE, Merion RM. Development, management, and resolution of biliary complications after living and deceased donor liver transplantation: a report from the adult-to-adult living donor liver transplantation cohort study consortium. *Liver Transpl* 2013; **19**: 259-267 [PMID: 23495079 DOI: 10.1002/lt.23595]
- 24 **Colonna JO 2nd**, Shaked A, Gomes AS, Colquhoun SD, Jurim O, McDiarmid SV, Millis JM, Goldstein LI, Busuttil RW. Biliary strictures complicating liver transplantation. Incidence, pathogenesis, management, and outcome. *Ann Surg* 1992; **216**: 344-350; discussion 350-352 [PMID: 1417184 DOI: 10.1097/00000658-199209000-00014]
- 25 **Soejima Y**, Taketomi A, Yoshizumi T, Uchiyama H, Harada N, Ijichi H, Yonemura Y, Ikeda T, Shimada M, Maehara Y. Biliary strictures in living donor liver transplantation: incidence, management, and technical evolution. *Liver Transpl* 2006; **12**: 979-986 [PMID: 16721777 DOI: 10.1002/lt.20740]
- 26 **Testa G**, Malagó M, Valentin-Gamazo C, Lindell G, Broelsch CE. Biliary anastomosis in living related liver transplantation using the right liver lobe: techniques and complications. *Liver Transpl* 2000; **6**: 710-714 [PMID: 11084056 DOI: 10.1053/jlts.2000.18706]
- 27 **Bak T**, Wachs M, Trotter J, Everson G, Trouillot T, Kugelmas M, Steinberg T, Kam I. Adult-to-adult living donor liver transplantation using right-lobe grafts: results and lessons learned from a single-center experience. *Liver Transpl* 2001; **7**: 680-686 [PMID: 11510011 DOI: 10.1053/jlts.2001.26509]
- 28 **Kawachi S**, Shimazu M, Wakabayashi G, Hoshino K, Tanabe M, Yoshida M, Morikawa Y, Kitajima M. Biliary complications in adult living donor liver transplantation with duct-to-duct hepaticocholedochostomy or Roux-en-Y hepaticojejunostomy biliary reconstruction. *Surgery* 2002; **132**: 48-56 [PMID: 12110795]
- 29 **Azoulay D**, Marin-Hargreaves G, Castaing D, RenéAdam, Bismuth H. Duct-to-duct biliary anastomosis in living related liver transplantation: the Paul Brousse technique. *Arch Surg* 2001; **136**: 1197-1200 [PMID: 11585515 DOI: 10.1001/archsurg.136.10.1197]
- 30 **Gómez CM**, Dumonceau JM, Marcolongo M, de Santibañes



- E, Ciardullo M, Pekolj J, Palavecino M, Gadano A, Dávalos J. Endoscopic management of biliary complications after adult living-donor versus deceased-donor liver transplantation. *Transplantation* 2009; **88**: 1280-1285 [PMID: 19996927 DOI: 10.1097/TP.0b013e3181bb48c2]
- 31 **Rao HB**, Ahamed H, Panicker S, Sudhindran S, Venu RP. Endoscopic therapy for biliary strictures complicating living donor liver transplantation: Factors predicting better outcome. *World J Gastrointest Pathophysiol* 2017; **8**: 77-86 [PMID: 28573070 DOI: 10.4291/wjgp.v8.i2.77]
- 32 **Thethy S**, Thomson BNj, Pleass H, Wigmore SJ, Madhavan K, Akyol M, Forsythe JL, James Garden O. Management of biliary tract complications after orthotopic liver transplantation. *Clin Transplant* 2004; **18**: 647-653 [PMID: 15516238 DOI: 10.1111/j.1399-0012.2004.00254.x]
- 33 **Balderramo D**, Navasa M, Cardenas A. Current management of biliary complications after liver transplantation: emphasis on endoscopic therapy. *Gastroenterol Hepatol* 2011; **34**: 107-115 [PMID: 20692731 DOI: 10.1016/j.gastrohep.2010.05.008]
- 34 **Simoes P**, Kesar V, Ahmad J. Spectrum of biliary complications following live donor liver transplantation. *World J Hepatol* 2015; **7**: 1856-1865 [PMID: 26207167 DOI: 10.4254/wjh.v7.i14.1856]
- 35 **Olthoff KM**, Merion RM, Ghobrial RM, Abecassis MM, Fair JH, Fisher RA, Freise CE, Kam I, Pruett TL, Everhart JE, Hulbert-Shearon TE, Gillespie BW, Emond JC; A2ALL Study Group. Outcomes of 385 adult-to-adult living donor liver transplant recipients: a report from the A2ALL Consortium. *Ann Surg* 2005; **242**: 314-323, discussion 323-discussion 325 [PMID: 16135918]
- 36 **Kim PT**, Marquez M, Jung J, Cavallucci D, Renner EL, Cattral M, Greig PD, McGilvray ID, Selzner M, Ghanekar A, Grant DR. Long-term follow-up of biliary complications after adult right-lobe living donor liver transplantation. *Clin Transplant* 2015; **29**: 465-474 [PMID: 25740227 DOI: 10.1111/ctr.12538]
- 37 **Ryu CH**, Lee SK. Biliary strictures after liver transplantation. *Gut Liver* 2011; **5**: 133-142 [PMID: 21814591 DOI: 10.5009/gnl.2011.5.2.133]
- 38 **Melcher ML**, Pomposelli JJ, Verbesey JE, McTaggart RA, Freise CE, Ascher NL, Roberts JP, Pomfret EA. Comparison of biliary complications in adult living-donor liver transplants performed at two busy transplant centers. *Clin Transplant* 2010; **24**: E137-E144 [PMID: 20047615 DOI: 10.1111/j.1399-0012.2009.01189.x]
- 39 **Duffy JP**, Kao K, Ko CY, Farmer DG, McDiarmid SV, Hong JC, Venick RS, Feist S, Goldstein L, Saab S, Hiatt JR, Busuttil RW. Long-term patient outcome and quality of life after liver transplantation: analysis of 20-year survivors. *Ann Surg* 2010; **252**: 652-661 [PMID: 20881772 DOI: 10.1097/SLA.0b013e3181f5f23a]
- 40 **Liu CL**, Fan ST, Lo CM, Wei WI, Chan SC, Yong BH, Wong J. Operative outcomes of adult-to-adult right lobe live donor liver transplantation: a comparative study with cadaveric whole-graft liver transplantation in a single center. *Ann Surg* 2006; **243**: 404-410 [PMID: 16495707 DOI: 10.1097/01.sla.0000201544.36473.a2]
- 41 **Chok KS**, Chan SC, Cheung TT, Sharr WW, Chan AC, Lo CM, Fan ST. Bile duct anastomotic stricture after adult-to-adult right lobe living donor liver transplantation. *Liver Transpl* 2011; **17**: 47-52 [PMID: 21254344 DOI: 10.1002/lt.22188]
- 42 **Chan SC**, Fan ST. Biliary complications in liver transplantation. *Hepatol Int* 2008; **2**: 399-404 [PMID: 19669315 DOI: 10.1007/s12072-008-9092-z]
- 43 **Seo JK**, Ryu JK, Lee SH, Park JK, Yang KY, Kim Y-T, Yoon YB, Lee HW, Yi N-J, Suh KS. Endoscopic treatment for biliary stricture after adult living donor liver transplantation. *Liver Transpl* 2009; **15**: 369-380. [DOI: 10.1002/lt.21700]
- 44 **Park JB**, Kwon CH, Choi GS, Chun JM, Jung GO, Kim SJ, Joh JW, Lee SK. Prolonged cold ischemic time is a risk factor for biliary strictures in duct-to-duct biliary reconstruction in living donor liver transplantation. *Transplantation* 2008; **86**: 1536-1542 [PMID: 19077886 DOI: 10.1097/TP.0b013e31818b2316]
- 45 **Sharma S**, Gurakar A, Jabbour N. Biliary strictures following liver transplantation: past, present and preventive strategies. *Liver Transpl* 2008; **14**: 759-769 [PMID: 18508368 DOI: 10.1002/lt.21509]
- 46 **Krok KL**, Cárdenas A, Thuluvath PJ. Endoscopic management of biliary complications after liver transplantation. *Clin Liver Dis* 2010; **14**: 359-371 [PMID: 20682241 DOI: 10.1016/j.cld.2010.03.008]
- 47 **Noack K**, Bronk SF, Kato A, Gores GJ. The greater vulnerability of bile duct cells to reoxygenation injury than to anoxia. Implications for the pathogenesis of biliary strictures after liver transplantation. *Transplantation* 1993; **56**: 495-500 [PMID: 8212138 DOI: 10.1097/00007890-199309000-00001]
- 48 **Morell CM**, Fabris L, Strazzabosco M. Vascular biology of the biliary epithelium. *J Gastroenterol Hepatol* 2013; **28** Suppl 1: 26-32 [PMID: 23855292 DOI: 10.1111/jgh.12022]
- 49 **Dacha S**, Barad A, Martin J, Levitsky J. Association of hepatic artery stenosis and biliary strictures in liver transplant recipients. *Liver Transpl* 2011; **17**: 849-854 [PMID: 21455929 DOI: 10.1002/lt.22298]
- 50 **Williams ED**, Draganov PV. Endoscopic management of biliary strictures after liver transplantation. *World J Gastroenterol* 2009; **15**: 3725-3733 [PMID: 19673012 DOI: 10.3748/wjg.15.3725]
- 51 **Marubashi S**, Dono K, Nagano H, Kobayashi S, Takeda Y, Umeshita K, Monden M, Doki Y, Mori M. Biliary reconstruction in living donor liver transplantation: technical invention and risk factor analysis for anastomotic stricture. *Transplantation* 2009; **88**: 1123-1130 [PMID: 19898209 DOI: 10.1097/TP.0b013e3181ba184a]
- 52 **Arain MA**, Attam R, Freeman ML. Advances in endoscopic management of biliary tract complications after liver transplantation. *Liver Transpl* 2013; **19**: 482-498 [PMID: 23417867 DOI: 10.1002/lt.23624]
- 53 **Pascher A**, Gerlach U, Neuhaus P. Bile duct strictures after liver transplantation. *Curr Opin Gastroenterol* 2014; **30**: 320-325 [PMID: 24686435 DOI: 10.1097/MOG.0000000000000061]
- 54 **Thuluvath PJ**, Pfau PR, Kimmey MB, Ginsberg GG. Biliary complications after liver transplantation: the role of endoscopy. *Endoscopy* 2005; **37**: 857-863 [PMID: 16116539 DOI: 10.1055/s-2005-870192]
- 55 **Verdonk RC**, Buis CI, Porte RJ, Haagsma EB. Biliary complications after liver transplantation: a review. *Scand J Gastroenterol Suppl* 2006; **243**: 89-101 [PMID: 16782628 DOI: 10.1080/00365520600664375]
- 56 **Singh AK**, Nachiappan AC, Verma HA, Uppot RN, Blake MA, Saini S, Boland GW. Postoperative imaging in liver transplantation: what radiologists should know. *Radiographics* 2010; **30**: 339-351 [PMID: 20228321 DOI: 10.1148/rg.302095124]
- 57 **Singh A**, Gelrud A, Agarwal B. Biliary strictures: diagnostic considerations and approach. *Gastroenterol Rep (Oxf)* 2015; **3**: 22-31 [PMID: 25355800 DOI: 10.1093/gastro/gou072]
- 58 **Chang JH**, Lee IS, Chun HJ, Choi JY, Yoon SK, Kim DG, You YK, Choi MG, Han SW. Comparative study of rendezvous techniques in post-liver transplant biliary stricture. *World J Gastroenterol* 2012; **18**: 5957-5964 [PMID: 23139613 DOI: 10.3748/wjg.v18.i41.5957]
- 59 **Kurzawinski TR**, Selves L, Farouk M, Dooley J, Hilson A, Buscombe JR, Burroughs A, Rolles K, Davidson BR. Prospective study of hepatobiliary scintigraphy and endoscopic cholangiography for the detection of early biliary complications after orthotopic liver transplantation. *Br J Surg* 1997; **84**: 620-623 [PMID: 9171746 DOI: 10.1002/bjs.1800840511]
- 60 **Kim YJ**, Lee KT, Jo YC, Lee KH, Lee JK, Joh JW, Kwon CH. Hepatobiliary scintigraphy for detecting biliary strictures after living donor liver transplantation. *World J Gastroenterol* 2011; **17**: 2626-2631 [PMID: 21677831 DOI: 10.3748/wjg.v17.i21.2626]
- 61 **Wang SF**, Huang ZY, Chen XP. Biliary complications after living donor liver transplantation. *Liver Transpl* 2011; **17**: 1127-1136 [PMID: 21761548 DOI: 10.1002/lt.22381]
- 62 **Katz LH**, Benjaminov O, Belinki A, Geler A, Braun M, Knizhnik M, Aizner S, Shaharabani E, Sulkes J, Shabtai E, Pappo O, Atar E, Tur-Kaspa R, Mor E, Ben-Ari Z. Magnetic

- resonance cholangiopancreatography for the accurate diagnosis of biliary complications after liver transplantation: comparison with endoscopic retrograde cholangiography and percutaneous transhepatic cholangiography - long-term follow-up. *Clin Transplant* 2010; **24**: E163-E169 [PMID: 21039885 DOI: 10.1111/j.1399-0012.2010.01300.x]
- 63 **Cereser L**, Girometti R, Como G, Molinari C, Toniutto P, Bitetto D, Zuiani C, Bazzocchi M. Impact of magnetic resonance cholangiography in managing liver-transplanted patients: preliminary results of a clinical decision-making study. *Radiol Med* 2011; **116**: 1250-1266 [PMID: 21744253 DOI: 10.1007/s11547-011-0707-4]
- 64 **Jorgensen JE**, Waljee AK, Volk ML, Sonnenday CJ, Elta GH, Al-Hawary MM, Singal AG, Taylor JR, Elmunzer BJ. Is MRCP equivalent to ERCP for diagnosing biliary obstruction in orthotopic liver transplant recipients? A meta-analysis. *Gastrointest Endosc* 2011; **73**: 955-962 [PMID: 21316670 DOI: 10.1016/j.gie.2010.12.014]
- 65 **Girometti R**, Como G, Bazzocchi M, Zuiani C. Post-operative imaging in liver transplantation: state-of-the-art and future perspectives. *World J Gastroenterol* 2014; **20**: 6180-6200 [PMID: 24876739 DOI: 10.3748/wjg.v20.i20.6180]
- 66 **Xu YB**, Min ZG, Jiang HX, Qin SY, Hu BL. Diagnostic value of magnetic resonance cholangiopancreatography for biliary complications in orthotopic liver transplantation: A meta-analysis. *Transplant Proc* 2013; **45**: 2341-2346 [DOI: 10.1016/j.transproceed.2013.03.031]
- 67 **Kulaksiz H**, Weiss KH, Gotthardt D, Adler G, Stremmel W, Schaible A, Dogan A, Stiehl A, Sauer P. Is stenting necessary after balloon dilation of post-transplantation biliary strictures? Results of a prospective comparative study. *Endoscopy* 2008; **40**: 746-751 [PMID: 18702031 DOI: 10.1055/s-2008-1077489]
- 68 **Zoepl T**, Maldonado-Lopez EJ, Hilgard P, Malago M, Broelsch CE, Treichel U, Gerken G. Balloon dilatation vs. balloon dilatation plus bile duct endoprosthesis for treatment of anastomotic biliary strictures after liver transplantation. *Liver Transpl* 2006; **12**: 88-94 [PMID: 16382450 DOI: 10.1002/lt.20548]
- 69 **Buxbaum JL**, Biggins SW, Bagatelos KC, Ostroff JW. Predictors of endoscopic treatment outcomes in the management of biliary problems after liver transplantation at a high-volume academic center. *Gastrointest Endosc* 2011; **73**: 37-44 [PMID: 21074761 DOI: 10.1016/j.gie.2010.09.007]
- 70 **Kim ES**, Lee BJ, Won JY, Choi JY, Lee DK. Percutaneous transhepatic biliary drainage may serve as a successful rescue procedure in failed cases of endoscopic therapy for a post-living donor liver transplantation biliary stricture. *Gastrointest Endosc* 2009; **69**: 38-46 [PMID: 18635177 DOI: 10.1016/j.gie.2008.03.1113]
- 71 **Tsujino T**, Sugawara Y, Omata M. Management of biliary strictures after living donor liver transplantation. *Gastrointest Endosc* 2009; **70**: 599-600; author reply 600-601 [PMID: 19699984 DOI: 10.1016/j.gie.2009.01.033]
- 72 **Lee YY**, Gwak GY, Lee KH, Lee JK, Lee KT, Kwon CH, Joh JW, Lee SK. Predictors of the feasibility of primary endoscopic management of biliary strictures after adult living donor liver transplantation. *Liver Transpl* 2011; **17**: 1467-1473 [PMID: 21898773 DOI: 10.1002/lt.22432]
- 73 **Park JS**, Kim MH, Lee SK, Seo DW, Lee SS, Han J, Min YI, Hwang S, Park KM, Lee YJ, Lee SG, Sung KB. Efficacy of endoscopic and percutaneous treatments for biliary complications after cadaveric and living donor liver transplantation. *Gastrointest Endosc* 2003; **57**: 78-85 [PMID: 12518136 DOI: 10.1067/mge.2003.11]
- 74 **Kurita A**, Kodama Y, Minami R, Sakuma Y, Kuriyama K, Tanabe W, Ohta Y, Maruno T, Shiokawa M, Sawai Y, Uza N, Yazumi S, Yoshizawa A, Uemoto S, Chiba T. Endoscopic stent placement above the intact sphincter of Oddi for biliary strictures after living donor liver transplantation. *J Gastroenterol* 2013; **48**: 1097-1104 [PMID: 23325164 DOI: 10.1007/s00535-012-0705-x]
- 75 **Law R**, Leal C, Dayyeh BA, Leise MD, Balderramo D, Baron TH, Cardenas A. Role of immunosuppression in post-endoscopic retrograde cholangiopancreatography pancreatitis after liver transplantation: a retrospective analysis. *Liver Transpl* 2013; **19**: 1354-1360 [PMID: 24115362 DOI: 10.1002/lt.23758]
- 76 **Morelli G**, Fazel A, Judah J, Pan JJ, Forsmark C, Draganov P. Rapid-sequence endoscopic management of posttransplant anastomotic biliary strictures. *Gastrointest Endosc* 2008; **67**: 879-885 [PMID: 18178206 DOI: 10.1016/j.gie.2007.08.046]
- 77 **Tabibian JH**, Asham EH, Han S, Saab S, Tong MJ, Goldstein L, Busuttil RW, Durazo FA. Endoscopic treatment of postorthotopic liver transplantation anastomotic biliary strictures with maximal stent therapy (with video). *Gastrointest Endosc* 2010; **71**: 505-512 [PMID: 20189508 DOI: 10.1016/j.gie.2009.10.023]
- 78 **Hisatsune H**, Yazumi S, Egawa H, Asada M, Hasegawa K, Kodama Y, Okazaki K, Itoh K, Takakuwa H, Tanaka K, Chiba T. Endoscopic management of biliary strictures after duct-to-duct biliary reconstruction in right-lobe living-donor liver transplantation. *Transplantation* 2003; **76**: 810-815 [PMID: 14501859 DOI: 10.1097/01.TP.0000083224.00756.8F]
- 79 **Culp WC**, McCowan TC, Lieberman RP, Goertzen TC, LeVeen RF, Heffron TG. Biliary strictures in liver transplant recipients: treatment with metal stents. *Radiology* 1996; **199**: 339-346 [PMID: 8668775 DOI: 10.1148/radiology.199.2.8668775]
- 80 **Dumonceau JM**, Devière J, Delhay M, Baize M, Cremer M. Plastic and metal stents for postoperative benign bile duct strictures: the best and the worst. *Gastrointest Endosc* 1998; **47**: 8-17 [PMID: 9468417 DOI: 10.1016/S0016-5107(98)70292-5]
- 81 **Harada N**, Shirabe K, Soejima Y, Taketomi A, Yoshizumi T, Asonuma K, Inomata Y, Maehara Y. Intrahepatic artery pseudoaneurysm associated with a metallic biliary stent after living donor liver transplantation: report of a case. *Surg Today* 2013; **43**: 678-681 [PMID: 22914885 DOI: 10.1007/s00595-012-0302-x]
- 82 **Siriwardana HP**, Siriwardana AK. Systematic appraisal of the role of metallic endobiliary stents in the treatment of benign bile duct stricture. *Ann Surg* 2005; **242**: 10-19 [PMID: 15973096 DOI: 10.1097/01.sla.0000167761.70021.4d]
- 83 **Tal AO**, Finkelmeier F, Filmann N, Kylänpää L, Udd M, Parzanese I, Cantù P, Dechêne A, Penndorf V, Schmitzbauer A, Friedrich-Rust M, Zeuzem S, Albert JG. Multiple plastic stents versus covered metal stent for treatment of anastomotic biliary strictures after liver transplantation: a prospective, randomized, multicenter trial. *Gastrointest Endosc* 2017; **86**: 1038-1045 [PMID: 28302527 DOI: 10.1016/j.gie.2017.03.009]
- 84 **Martins FP**, De Paulo GA, Contini MLC, Ferrari AP. Metal versus plastic stents for anastomotic biliary strictures after liver transplantation: a randomized controlled trial. *Gastrointest Endosc* 2018; **87**: 131.e1-131.e13 [PMID: 28455159 DOI: 10.1016/j.gie.2017.04.013]
- 85 **Landi F**, de'Angelis N, Sepulveda A, Martínez-Pérez A, Sobhani I, Laurent A, Soubrane O. Endoscopic treatment of anastomotic biliary stricture after adult deceased donor liver transplantation with multiple plastic stents versus self-expandable metal stents: a systematic review and meta-analysis. *Transpl Int* 2018; **31**: 131-151 [PMID: 29090502 DOI: 10.1111/tri.13089]
- 86 **Curcio G**, Traina M, Miraglia R, Tarantino I, Barresi L, Granata A. Treatment of a refractory biliary stricture after living donor liver transplantation, with a short fully covered metal stent with a long string. *Endoscopy* 2012; **44** Suppl 2 UCTN: E74-E75 [PMID: 22396289 DOI: 10.1055/s-0031-1291600]
- 87 **Kaffes A**, Griffin S, Vaughan R, James M, Chua T, Tee H, Dinesen L, Corte C, Gill R. A randomized trial of a fully covered self-expandable metallic stent versus plastic stents in anastomotic biliary strictures after liver transplantation. *Therap Adv Gastroenterol* 2014; **7**: 64-71 [PMID: 24587819 DOI: 10.1177/1756283X13503614]
- 88 **Kao D**, Zepeda-Gomez S, Tandon P, Bain VG. Managing the post-liver transplantation anastomotic biliary stricture: multiple plastic versus metal stents: a systematic review. *Gastrointest Endosc* 2013; **77**: 679-691 [PMID: 23473000 DOI: 10.1016/j.gie.2013.01.015]
- 89 **Jang SI**, Sung SY, Park H, Lee KH, Joo SM, Lee DK. Salvage

- therapy using self-expandable metal stents for recalcitrant anastomotic strictures after living-donor liver transplantation. *Therap Adv Gastroenterol* 2017; **10**: 297-309 [PMID: 28246547 DOI: 10.1177/1756283X16685059]
- 90 **Coté GA**, Slivka A, Tarnasky P, Mullady DK, Elmunzer BJ, Elta G, Fogel E, Lehman G, McHenry L, Romagnuolo J, Menon S, Siddiqui UD, Watkins J, Lynch S, Denski C, Xu H, Sherman S. Effect of Covered Metallic Stents Compared With Plastic Stents on Benign Biliary Stricture Resolution: A Randomized Clinical Trial. *JAMA* 2016; **315**: 1250-1257 [PMID: 27002446 DOI: 10.1001/jama.2016.2619]
- 91 **Na GH**, Kim DG, Choi HJ, Han JH, Hong TH, You YK. Interventional treatment of a biliary stricture after adult right-lobe living-donor liver transplantation with duct-to-duct anastomosis. *HPB (Oxford)* 2014; **16**: 312-319 [PMID: 23981034 DOI: 10.1111/hpb.12151]
- 92 **Sung RS**, Campbell DA Jr, Rudich SM, Punch JD, Shieck VL, Armstrong JM, Ford E, Sullivan P, Dasika NL, Magee JC. Long-term follow-up of percutaneous transhepatic balloon cholangioplasty in the management of biliary strictures after liver transplantation. *Transplantation* 2004; **77**: 110-115 [PMID: 14724444 DOI: 10.1097/01.TP.0000101518.19849.C8]
- 93 **Wadhawan M**, Kumar A, Gupta S, Goyal N, Shandil R, Taneja S, Sibal A. Post-transplant biliary complications: an analysis from a predominantly living donor liver transplant center. *J Gastroenterol Hepatol* 2013; **28**: 1056-1060 [PMID: 23432435 DOI: 10.1111/jgh.12169]
- 94 **Ranjan P**, Bansal RK, Mehta N, Lalwani S, Kumaran V, Sachdeva MK, Kumar M, Nundy S. Endoscopic management of post-liver transplant biliary complications: A prospective study from tertiary centre in India. *Indian J Gastroenterol* 2016; **35**: 48-54 [PMID: 26873087 DOI: 10.1007/s12664-016-0625-4]

**P- Reviewer:** Sonzogni A, Therapondos G, Uchiyama H

**S- Editor:** Gong ZM **L- Editor:** A **E- Editor:** Huang Y





Published by **Baishideng Publishing Group Inc**  
7901 Stoneridge Drive, Suite 501, Pleasanton, CA 94588, USA  
Telephone: +1-925-223-8242  
Fax: +1-925-223-8243  
E-mail: [bpgoffice@wjgnet.com](mailto:bpgoffice@wjgnet.com)  
Help Desk: <http://www.f6publishing.com/helpdesk>  
<http://www.wjgnet.com>



ISSN 1007-9327

