

World Journal of *Clinical Cases*

World J Clin Cases 2018 October 6; 6(11): 406-482





EDITORIAL

- 406 Defensive medicine: It is time to finally slow down an epidemic
Vento S, Cainelli F, Vallone A

MINIREVIEWS

- 410 Web-based learning in inflammatory bowel diseases: General truths and current specifics
Zezos P, Panisko D
- 418 Dual HER2 inhibition strategies in the management of treatment-refractory metastatic colorectal cancer: History and status
Kanat O, Ertas H, Caner B

ORIGINAL ARTICLE

Basic Study

- 426 Isolation and characterization of a new candidate human inactivated rotavirus vaccine strain from hospitalized children in Yunnan, China: 2010-2013
Wu JY, Zhou Y, Zhang GM, Mu GF, Yi S, Yin N, Xie YP, Lin XC, Li HJ, Sun MS

Retrospective Cohort Study

- 441 Diagnostic value of elevated serum carbohydrate antigen 199 level in acute cholangitis secondary to choledocholithiasis
Mei Y, Chen L, Peng CJ, Wang J, Zeng PF, Wang GX, Li WP, Luo YQ, Du C, Liu K, Xiong K, Leng K, Feng CL, Jia JH

CASE REPORT

- 447 Balo's concentric sclerosis in a patient with spontaneous remission based on magnetic resonance imaging: A case report and review of literature
Ertuğrul Ö, Çiçekçi E, Tuncer MC, Aluçlu MU
- 455 Neurofibroma discharged from the anus with stool: A case report and review of literature
Miao Y, Wang JJ, Chen ZM, Zhu JL, Wang MB, Cai SQ
- 459 Balloon dilator controls massive bleeding during endoscopic ultrasound-guided drainage for pancreatic pseudocyst: A case report and review of literature
Wang BH, Xie LT, Zhao QY, Ying HJ, Jiang TA



- 466 Twin pregnancy with triple parathyroid adenoma: A case report and review of literature
Zhang Y, Ding JW, Yu LY, Luo DC, Sun JL, Lei ZK, Wang ZH
- 472 Unusual cause of lesions in the descending duodenum and liver: A case report and review of literature
Xiao ZL, Xu KS, Song YH
- 477 Isolated myeloid sarcoma in the pancreas and orbit: A case report and review of literature
Zhu T, Xi XY, Dong HJ

ABOUT COVER

Editorial Board Member of *World Journal of Clinical Cases*, Kassem A Barada, MD, Professor, Department of Internal Medicine, American University of Beirut Medical Center, Beirut 110 72020, Lebanon

AIM AND SCOPE

World Journal of Clinical Cases (*World J Clin Cases*, *WJCC*, online ISSN 2307-8960, DOI: 10.12998) is a peer-reviewed open access academic journal that aims to guide clinical practice and improve diagnostic and therapeutic skills of clinicians.

The primary task of *WJCC* is to rapidly publish high-quality Autobiography, Case Report, Clinical Case Conference (Clinicopathological Conference), Clinical Management, Diagnostic Advances, Editorial, Field of Vision, Frontier, Medical Ethics, Original Articles, Clinical Practice, Meta-Analysis, Minireviews, Review, Therapeutics Advances, and Topic Highlight, in the fields of allergy, anesthesiology, cardiac medicine, clinical genetics, clinical neurology, critical care, dentistry, dermatology, emergency medicine, endocrinology, family medicine, gastroenterology and hepatology, geriatrics and gerontology, hematology, immunology, infectious diseases, internal medicine, obstetrics and gynecology, oncology, ophthalmology, orthopedics, otolaryngology, pathology, pediatrics, peripheral vascular disease, psychiatry, radiology, rehabilitation, respiratory medicine, rheumatology, surgery, toxicology, transplantation, and urology and nephrology.

INDEXING/ABSTRACTING

World Journal of Clinical Cases (*WJCC*) is now indexed in PubMed, PubMed Central, Science Citation Index Expanded (also known as SciSearch®), and Journal Citation Reports/Science Edition. The 2018 Edition of Journal Citation Reports cites the 2017 impact factor for *WJCC* as 1.931 (5-year impact factor: N/A), ranking *WJCC* as 60 among 154 journals in Medicine, General and Internal (quartile in category Q2).

EDITORS FOR THIS ISSUE

Responsible Assistant Editor: *Xiang Li*
Responsible Electronic Editor: *Han Song*
Proofing Editor-in-Chief: *Lian-Sheng Ma*

Responsible Science Editor: *Ying Dou*
Proofing Editorial Office Director: *Jin-Lei Wang*

NAME OF JOURNAL
World Journal of Clinical Cases

ISSN
ISSN 2307-8960 (online)

LAUNCH DATE
April 16, 2013

FREQUENCY
Semimonthly

EDITORS-IN-CHIEF
Sandro Vento, MD, Department of Internal Medicine, University of Botswana, Private Bag 00713, Gaborone, Botswana

EDITORIAL BOARD MEMBERS
All editorial board members resources online at <http://www.wjgnet.com/2307-8960/editorialboard.htm>

EDITORIAL OFFICE
Jin-Lei Wang, Director

World Journal of Clinical Cases
Baishideng Publishing Group Inc
7901 Stoneridge Drive, Suite 501, Pleasanton, CA 94588, USA
Telephone: +1-925-2238242
Fax: +1-925-2238243
E-mail: editorialoffice@wjgnet.com
Help Desk: <http://www.f6publishing.com/helpdesk>
<http://www.wjgnet.com>

PUBLISHER
Baishideng Publishing Group Inc
7901 Stoneridge Drive, Suite 501, Pleasanton, CA 94588, USA
Telephone: +1-925-2238242
Fax: +1-925-2238243
E-mail: bpgoffice@wjgnet.com
Help Desk: <http://www.f6publishing.com/helpdesk>
<http://www.wjgnet.com>

PUBLICATION DATE
October 6, 2018

COPYRIGHT

© 2018 Baishideng Publishing Group Inc. Articles published by this Open Access journal are distributed under the terms of the Creative Commons Attribution Non-commercial License, which permits use, distribution, and reproduction in any medium, provided the original work is properly cited, the use is non commercial and is otherwise in compliance with the license.

SPECIAL STATEMENT

All articles published in journals owned by the Baishideng Publishing Group (BPG) represent the views and opinions of their authors, and not the views, opinions or policies of the BPG, except where otherwise explicitly indicated.

INSTRUCTIONS TO AUTHORS

<http://www.wjgnet.com/bpg/gerinfo/204>

ONLINE SUBMISSION

<http://www.f6publishing.com>

Dual HER2 inhibition strategies in the management of treatment-refractory metastatic colorectal cancer: History and status

Ozkan Kanat, Hulya Ertas, Burcu Caner

Ozkan Kanat, Hulya Ertas, Burcu Caner, Department of Medical Oncology, Faculty of Medicine, Uludag University, Bursa 16059, Turkey

ORCID number: Ozkan Kanat (0000-0001-6973-6540); Hulya Ertas (0000-0001-8306-4349); Burcu Caner (0000-0003-1591-3323).

Author contributions: Kanat O assigned the issue, collected relevant literature data, and wrote the manuscript; Ertas H and Caner B performed literature research and contributed to the final version of the manuscript.

Conflict-of-interest statement: No potential conflicts of interest relevant to this article were reported.

Open-Access: This article is an open-access article which was selected by an in-house editor and fully peer-reviewed by external reviewers. It is distributed in accordance with the Creative Commons Attribution Non Commercial (CC BY-NC 4.0) license, which permits others to distribute, remix, adapt, build upon this work non-commercially, and license their derivative works on different terms, provided the original work is properly cited and the use is non-commercial. See: <http://creativecommons.org/licenses/by-nc/4.0/>

Manuscript Source: Invited Manuscript

Correspondence to: Ozkan Kanat, MD, PhD, Professor, Department of Medical Oncology, Faculty of Medicine, Uludag University, Gorukle, Bursa 16059, Turkey. ozkanat@uludag.edu.tr
Telephone: +90-224-2951321
Fax: +90-224-2951341

Received: April 10, 2018

Peer-review started: April 10, 2018

First decision: April 27, 2018

Revised: May 15, 2018

Accepted: June 8, 2018

Article in press: June 8, 2018

Published online: October 6, 2018

Abstract

Human epidermal growth factor receptor 2 (HER2) signaling pathway activation has been identified as a contributor to de novo or acquired resistance to epidermal growth factor receptor (EGFR) inhibitors in a small subset of patients with metastatic colorectal cancer (mCRC). Dual anti-HER2-targeted treatment exhibits strong antitumor activity in preclinical models of HER2-positive mCRC, supporting its testing in clinical trials. The HERACLES trial at four Italian academic cancer centers has confirmed the effectiveness of dual blockage of HER2 with trastuzumab plus lapatinib in patients with heavily pretreated HER2-positive mCRC, refractory to the anti-EGFR antibodies cetuximab or panitumumab. Here, we reviewed the preclinical studies exploring the role of HER2 signaling in the development of anti-EGFR therapy resistance and discussed the status of clinical trials assessing the activity of HER2 inhibitors in this setting.

Key words: Epidermal growth factor receptor; Cetuximab; Panitumumab; Human epidermal growth factor receptor 2; Anti-epidermal growth factor receptor resistance; Trastuzumab; Dual inhibition

© **The Author(s) 2018.** Published by Baishideng Publishing Group Inc. All rights reserved.

Core tip: We reviewed the preclinical studies exploring the role of human epidermal growth factor receptor 2 (HER2) signaling in the development of anti-epidermal growth factor receptor therapy resistance in metastatic colorectal cancer and discussed the status of clinical trials assessing the activity of HER2 inhibitors in this setting.

Kanat O, Ertas H, Caner B. Dual HER2 inhibition strategies in the

management of treatment-refractory metastatic colorectal cancer: History and status. *World J Clin Cases* 2018; 6(11): 418-425 Available from: URL: <http://www.wjgnet.com/2307-8960/full/v6/i11/418.htm> DOI: <http://dx.doi.org/10.12998/wjcc.v6.i11.418>

INTRODUCTION

The occurrence of distant metastases is an unfortunate but common event during the clinical course of colorectal cancer (CRC). Approximately three-quarters of patients with CRC present with unresectable stage IV disease at initial diagnosis or at follow up^[1]. These patients usually benefit from modern systemic therapies, including chemotherapy alone or in combination with targeted therapy. However, in the treatment decision-making process, clinicians should consider various patient (age, performance status, comorbidity, and life expectancy) and tumor characteristics [location (*i.e.*, right-sided vs left-sided), mutation profile (*i.e.*, RAS mutated vs RAS wild-type), disease extent, and possibility of secondary resection] that may influence the treatment effectiveness and morbidity outcomes.

Patients with metastatic CRC (mCRC) who have poor performance status and very extensive disease are mostly managed by a palliative care approach. Expectedly, the administration of chemotherapy may create tolerability issues in elderly patients. Therefore, single-agent chemotherapy (fluoropyrimidine or irinotecan) is generally preferred to classical combination regimens in elderly patients. Otherwise, all physically fit patients with mCRC, particularly those who have a greater chance for salvage surgical resection following systemic therapy, should be aggressively treated to obtain better clinical outcomes. In the modern clinical practice, epidermal growth factor receptor (EGFR, also known as HER1) pathway inhibition in CRC cells using EGFR-targeting monoclonal antibodies (cetuximab and panitumumab) is an important component of this aggressive approach to treatment^[2].

Because of their mechanism of action, anti-EGFR antibodies should be administered only in patients with CRC whose tumors do not contain activating mutations in one of their RAS genes (K-, N-, and H-RAS)^[3,4]. Briefly, these drugs specifically bind to the extracellular portion of EGFRs in cancer cells to prevent triggering their activation by endogenous ligands, such as epidermal growth factor and transforming growth factor alpha^[5] (Figure 1). Therefore, anti-EGFR antibodies successfully inhibit ligand-induced dimerization of EGFR with itself and with another HER family member (HER2, HER3, and HER4). This causes deactivation of intracellular mitogenic signaling pathways including the RAS-RAF-MEK-ERK and PI3K-AKT-mTOR cascades, leading to G1 phase cell cycle arrest and apoptosis in cancer cells^[5,6].

Conversely, in tumors harboring RAS mutations, the RAS-RAF-MEK-ERK pathway remains consecutively

active, independent of the canonical EGFR signaling^[7]. In this case, anti-EGFR antibodies are completely inactive and sometimes detrimental^[8].

EGFR inhibitors are preferentially administered together with oxaliplatin-based (*i.e.*, 5-fluorouracil, leucovorin, and oxaliplatin) and irinotecan-based (*i.e.*, 5-fluorouracil, leucovorin, and irinotecan) doublet chemotherapy regimens, or intensified chemotherapy regimens such as FOLFOXIRI (5-fluorouracil, leucovorin, oxaliplatin, and irinotecan). Recent retrospective evidence revealed the relatively impaired antitumor activity of cetuximab in the frontline treatment of patients with mCRC whose tumors arise from the right side of the colon. Despite this finding, EGFR inhibitors are still important in both chemo-naïve and carefully selected chemo-refractory cases^[9-13]. Notably, a recent phase 2 study comparing panitumumab plus modified fluorouracil, leucovorin, and oxaliplatin (mFOLFOX6) with the antiangiogenic drug bevacizumab plus mFOLFOX6 in patients with previously untreated RAS wild-type mCRC reported a median survival time exceeding 40 mo for patients receiving panitumumab^[14].

Wild-type RAS status does not guarantee a response to anti-EGFR drugs, and these drugs cannot induce any tumor shrinkage in a significant proportion of patients (30%–50%) with RAS wild-type mCRC. Numerous studies have elucidated the underlying mechanisms of anti-EGFR treatment refractoriness (*de novo* or primary resistance) in these patients. These studies consistently revealed that the presence of other genetic alterations in tumor cells potentiating the RAS-RAF-MEK-ERK and PI3K-AKT-mTOR signaling, such as BRAF (V600E) mutation, PI3KCA (exon 20) mutation, and PTEN loss, can at least partially account for unresponsiveness^[15-19]. In patients with these mutations, the use of angiogenesis inhibitors instead of EGFR inhibitors or the administration of intensified chemotherapy backbone such as FOLFOXIRI along with anti-EGFR agents are reasonable treatment strategies^[20].

Additionally, almost all patients with mCRC who initially respond to EGFR inhibitors become resistant to the treatment over time (secondary or acquired resistance). The identification of compensatory cellular mechanisms leading to treatment failure is crucial to determine effective salvage pharmacological interventions that can re-induce tumor regression.

Over the last few years, studies have shown that despite its rarity, HER2 signaling pathway activation in cancer cells, primarily due to HER2 overexpression and gene amplification may play an important role in the development of primary and secondary resistance to anti-EGFR therapies in patients with mCRC^[21,22].

HER2-POSITIVE COLORECTAL CANCER AS A NEW CLINICAL ENTITY

In contrast to other proteins in the HER family, HER2 has no endogenous ligand and is considered an example of an orphan receptor that is functionally incomplete^[23]. It has

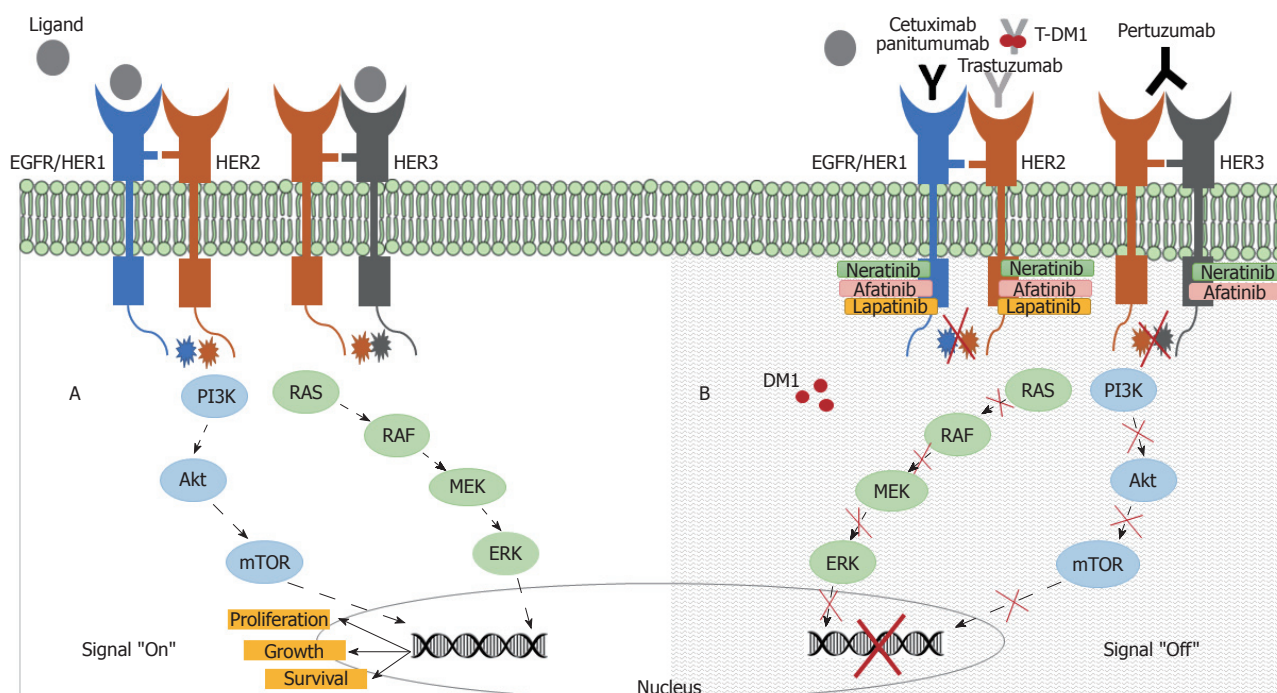


Figure 1 Epidermal growth factor receptor-related signaling pathways and anti-epidermal growth factor receptor and anti-human epidermal growth factor receptor 2 targeted drugs in colorectal cancer. A: Following ligand binding, the epidermal growth factor receptor (EGFR) (HER1) forms active homo- or heterodimers, resulting in the autophosphorylation of tyrosine residues within the cytoplasmic domain of the receptors. This triggers the RAS/RAF/MEK/ERK and PI3K/AKT/mTOR pathways that transmit mitogenic signals to the nucleus; B: Dimerization of the receptors can be inhibited by EGFR-targeted (cetuximab or panitumumab) or HER2-targeted antibodies (trastuzumab or pertuzumab). Small molecule tyrosine kinase inhibitors (neratinib, afatinib, or lapatinib) can block EGFR and HER2 signaling by preventing adenosine triphosphate binding to the catalytic domain of protein kinases.

the strongest catalytic tyrosine kinase activity; therefore, it is a preferable dimerization partner, particularly for EGFR and HER3^[23,24]. HER2 overexpression leads to increased EGFR membrane expression and activity^[25]. HER2 overexpressing cells have significantly prolonged the activation of mitogen-activated protein kinase (originally called extracellular signal-regulated kinase, ERK) and c-Jun N-terminal kinase downstream signaling pathways following stimulation with EGFR or HER3 ligands compared with HER2-low expressing cells^[26]. HER3 is considered an obligate dimerization partner in HER2-induced tumor cell proliferation^[27,28]. HER2 overexpression is associated with enhanced HER3 phosphorylation and increased PI3K/Akt pathway activation^[27,28].

The clinical and biological significance of HER2 signal activation in CRC has become an important research topic after the identification of *HER* gene amplification as a potential mechanism of anti-EGFR treatment resistance in patient-derived xenograft models and cell lines^[21,22]. Bertotti *et al.*^[21] produced a large patient-derived xenograft platform using tumor samples from patients with CRC undergoing liver metastasectomy. They found that only a small portion (2%–3%) of genetically unselected xenopatient showed *HER2* gene amplification. However, in xenopatient whose tumors were KRAS wild-type and cetuximab-resistant, the frequency of *HER2* gene amplification increased to 13.6%. Furthermore, in a subset of xenopatient with cetuximab-refractory KRAS/NRAS/BRAF/PIK3CA wild-type CRC,

its frequency increased to 36%. This suggested that HER2 amplification could be a key driver of anti-EGFR resistance in CRC, and anti-HER2 therapy could be an option in selected patients. Therefore, the effects of anti-EGFR and anti-HER2 therapies in cetuximab-resistant, HER2-amplified mCRC xenopatient were investigated. Dual EGFR/HER2 inhibition with pertuzumab (an anti-HER2 monoclonal antibody that blocks HER2/HER3 dimerization) plus lapatinib (a small molecule dual inhibitor of EGFR and HER2 receptor tyrosine kinases) caused significant tumor regression. A combination of lapatinib and cetuximab also significantly reduced tumor volume, but to a lesser extent than pertuzumab plus lapatinib.

Yonesaka *et al.*^[22] found that the activation of HER2 signaling either by *HER2* gene amplification or HER3-activating heregulin ligand overproduction led to de novo or acquired resistance to cetuximab in human CRC cell lines by increasing activation of ERK 1/2 signal pathway. Treatment of these cetuximab-resistant cell lines with HER2 small interfering RNA (siRNA) and inhibition of HER2/HER3 dimerization using lapatinib and pertuzumab could restore cetuximab sensitivity both in vitro and in vivo. These preclinical findings were further confirmed by the authors in a cohort of patients with mCRC exhibiting de novo or acquired resistance to cetuximab-based therapy. In these patients, *HER2* gene amplification in tumor specimens or high levels of circulating heregulin in patient plasma samples was detected.

Using HER2-amplified patient-derived tumor grafts,

Leto *et al.*^[29] confirmed the necessity of dual HER2 inhibition to induce effective tumor shrinkage in patients with CRC. They indicated that trastuzumab plus lapatinib or irreversible pan-HER inhibitor afatinib alone have higher antitumor activity than lapatinib monotherapy in HER2-amplified patient-derived CRC and gastric cancer cell-line xenografts. Delayed reactivation of HER3 and EGFR during lapatinib treatment has been proposed as a reason for its reduced effectiveness.

Kavuri *et al.*^[30] revealed that HER2 somatic mutations (S310F, L755S, V77L, V842I, and L866M) can activate the HER2 signaling pathway and cause panitumumab and cetuximab resistance in CRC cell lines, irrespective of the presence of HER2 amplification or overexpression. In addition, the *HER2* gene was sequenced in 48 CRC PDX samples that were cetuximab-resistant and wild-type for KRAS, NRAS, BRAF, and PIK3CA. Only four (8.3%) PDXs were found to have HER2-activating mutations. Treatment of mice carrying these HER2 mutant xenografts with dual HER2-targeted therapy with either trastuzumab plus neratinib (an irreversible pan-HER tyrosine kinase inhibitor) or trastuzumab plus lapatinib led to sustained tumor regression. These data suggest that a small number of patients with anti-EGFR therapy-refractory mCRC can have HER2 activating mutations, and these patients may benefit from dual HER2 blockage.

CLINICAL RELEVANCE OF HER2 EXPRESSION IN METASTATIC COLORECTAL CANCER

Studies have shown that HER2 overexpression seems to have no prognostic value in CRC. Richman *et al.*^[31] investigated the relationship between HER2 overexpression and survival in 1342 patients with mCRC who were previously enrolled in the FOCUS and PICCOLO cancer therapy trials. Among them, HER2 overexpression by fluorescence in situ hybridization (FISH) and/or immunohistochemistry (IHC) was identified in 29 (2.2%) patients but was not predictive of disease-free and overall survival (OS). Seo *et al.*^[32] found that *HER2* gene amplification was associated with tumor location and was more frequently detected in tumors originating in the rectum than those originating in the right and left colon. However, they did not see a relationship between HER2 overexpression and several aggressive clinicopathological features of CRC, including infiltrative tumor border, invasion depth, perineural invasion, lymph node metastasis, and distant metastasis.

Tu *et al.*^[33] reported HER2 overexpression in 102 (11.6%) of 878 Chinese patients with CRC. HER2 overexpression was more frequent in patients with early-stage CRC compared to patients with advanced stage CRC. HER2 overexpression was associated with gender, age, histological type, tumor location, and other prognostic indicators such as tumor grade, depth of invasion, lymph node metastases, and distant metastases. Again, it was

not a significant predictor of survival. All these findings were confirmed by a meta-analysis of 18 studies comprising 2867 patients with CRC^[34].

Conversely, several studies found that HER2 overexpression or amplification was predictive of resistance to EGFR inhibitors in patients with mCRC. Jeong *et al.*^[35] identified HER2 amplification in seven (4.9%) of 142 patients with mCRC with RAS and BRAF wild-type tumors. These 142 patients were treated with cetuximab after failure of oxaliplatin, irinotecan, and fluoropyrimidine. The patients with HER amplification had significantly shorter progression-free survival (PFS) than did those without HER2 amplification [median, 3.1 mo vs 5.6 mo; hazard ratio (HR) 2.73, $P = 0.019$]. In addition, there was a trend for poor OS in patients with HER2-amplified tumors (10.1 mo vs 13.5 mo, HR 1.31; $P = 0.488$).

Martin *et al.*^[36] evaluated the *HER2* gene status by FISH in 170 patients with KRAS wild-type mCRC receiving cetuximab or panitumumab alone or in combination with chemotherapy for first- or second-line treatment. Among these patients, seven (4%) had *HER2* gene amplification in 90% of tumor cells and were classified as HER2-all-A patients. Sixty-one percent of the patients had HER2 overexpression due to polysomy or gene amplification in minor clones (HER2-FISH+ cases), and 35% of patients had slight or no HER2 gain (HER2-FISH-cases). Patients who were classified as HER-all-A had worse outcomes than those designated as HER2-FISH+ and HER2-FISH- in terms of response rate ($P = 0.0006$), PFS ($P < 0.0001$), and OS ($P < 0.0001$). These findings suggest that that tumor HER2 copy numbers may predict the response to anti-EGFR treatment in patients with KRAS wild-type mCRC.

CLINICAL TRIALS USING ANTI-HER2 AGENTS IN METASTATIC COLORECTAL CANCER

Early studies that investigated the effectiveness of using the anti-HER2 antibody trastuzumab in combination with irinotecan- and oxaliplatin-based chemotherapy in previously treated patients with mCRC revealed promising antitumor activity^[37,38]. Since these studies were conducted in unselected patients, they did not provide useful information on the clinical activity of this therapeutic approach.

Some studies investigated whether HER2 inhibition could restore sensitivity to EGFR inhibitors in unselected patients with mCRC (Table 1). In a phase I / II trial, Robinson *et al.*^[39] evaluated the efficacy and tolerability of a combination of pertuzumab and cetuximab in patients with cetuximab-refractory KRAS wild-type metastatic CRC. The study was terminated early following the enrollment of 13 patients due to intolerable side effects such as diarrhea, skin rash, and mucositis. Only seven patients were evaluable for response, with one

Table 1 Summary of completed and ongoing clinical trials of anti- human epidermal growth factor receptor 2 agents in metastatic colorectal cancer

Study	Phase	Treatment	Number of patients	Patient population	RR	mPFS	mOS
Rubinson ^[39]	I / II	Cetuximab + pertuzumab	7	Chemo- and cetuximab-refractory	14%	2.1 mo	3.7 mo
Sartore-Bianchi (HERACLES) ^[40]	II	Trastuzumab + lapatinib	27	Chemo- and cetuximab/ panitumumab-refractory	30%	21 wk	46 wk
Hainsworth (MyPathway) ^[44]	II	Trastuzumab + pertuzumab	34	Chemo-refractory	35%	NR	NR
Siena (HERACLES-RESCUE) ^[42]	II	Trastuzumab- emtansine	Recruiting	Chemo- and cetuximab/ panitumumab and trastuzumab plus lapatinib-refractory			
NCT03457896	II	Neratinib + trastuzumab or cetuximab	Recruiting	Cetuximab and/or chemo- refractory			
MOUNTAINEER ^[45]	II	Tucatinib + trastuzumab	Recruiting	Chemo- and bevacizumab- refractory			

RR: Response rate; mPFS: Median progression-free survival; mOS: Median overall survival; Chemo: Chemotherapy; NR: Not reported.

(14%) patient showing a partial response lasting more than six months, and two (29%) patients achieving stable disease. These results suggested that the use of dual HER2 inhibitors with minimally overlapping toxicities could be a promising option to overcome cetuximab resistance in mCRC.

The seminal HERACLES (HER2 Amplification for Colorectal Cancer Enhanced Stratification) phase 2 trial conducted by Italian researchers tested the activity of dual-targeted trastuzumab and lapatinib therapy in patients with treatment-refractory, KRAS codon 12/13 wild-type and HER2-positive mCRC^[40]. The rationale for this therapeutic approach was primarily based on the above-mentioned preclinical data suggesting promising activity for dual anti-HER2 blockade in this setting. Before patient enrollment, the authors screened 914 patients with KRAS exon 2 (codons 12 and 13) wild-type mCRC and identified 48 (5%) patients who had HER-positive tumors according to the HERACLES Diagnostic Criteria for colorectal cancer (tumors with 3+ HER2 score in more than 50% of cells by IHC or with 2+ HER2 score and a HER2:CEP17 ratio higher than 2.0 in more than 50% of cells by FISH)^[41]. Of these 48 patients, 27 were eligible for the study. Twenty (74%) patients had previously received at least four treatment regimens, including the anti-angiogenesis drugs bevacizumab, regorafenib, or aflibercept, and all patients had been previously treated with the anti-EGFR antibodies cetuximab or panitumumab. Trastuzumab was given intravenously (initial loading dose 4 mg/kg followed by 2 mg/kg weekly), and lapatinib was given orally (1000 mg/d). The treatment was continued until disease progression or until withdrawal of treatment because of an adverse event. The primary endpoint was objective response rate (complete plus partial response). The secondary endpoints were PFS and safety. All 27 patients were evaluable for response. One had a complete response, and seven had a partial response with an overall objective response rate of 30%. Twelve (44%) patients

achieved disease stabilization longer than 16 wk. Median PFS was 21 wk (95%CI: 16-32), and 12 (45%) patients were alive at one year. Treatment was mostly well tolerated. Six of 27 patients (22%) experienced grade 3 adverse events consisting of fatigue, skin rash, and increased bilirubin concentration. The study authors also investigated the molecular determinants of response, and they found that patients with a high *HER2* gene copy number (> 9.45 copies/cell) had significantly longer PFS compared with patients whose tumors had a lower gene copy number (median, 29 wk vs 16 wk, $P = 0.0001$). Patients who had a gene copy number higher than 9.45 were also more likely than patients with a gene copy number lower than 9.45 (44% vs 0%, $P = 0.02$) to have a response to treatment. These results showed that the combination of trastuzumab and lapatinib is safe and effective in treating patients with HER2-positive mCRC resistant to chemotherapy and anti-EGFR agents.

The HERACLES-RESCUE clinical study is currently investigating the activity of trastuzumab-emtansine (T-DM1), an antibody-drug conjugate consisting of trastuzumab linked to the cytotoxic agent emtansine, in patients with HER2-positive mCRC progressing after trastuzumab plus lapatinib^[42]. The rationale for the selection of T-DM1 in this study resulted from testing in patient-derived xenograft models of CRC generated from patients with acquired resistance to trastuzumab and lapatinib in the HERACLES study. These models were found to have high levels of HER2 expression, and treatment with T-DM1 resulted in significant tumor regression, whereas no response was observed in animals treated with pertuzumab alone. Another relevant study, the HERACLES cohort B trial is evaluating the clinical activity of lapatinib or pertuzumab in combination with T-DM1 in patients who are HER2-therapy-naïve and have HER2-positive mCRC^[43].

The MyPathway phase II trial is investigating the efficacy and safety of pertuzumab plus trastuzumab in patients with treatment-refractory mCRC showing

overexpression or amplification of HER2 by gene sequencing and/or by FISH or IHC^[44]. The interim efficacy data reflects initial results from 34 patients. Twelve patients have achieved partial response, and three have achieved stable disease for longer than four months. The median duration of response is 11.1 mo.

Another interesting phase II trial (NCT03457896) is examining the efficacy of pan-HER inhibitor neratinib plus trastuzumab or neratinib plus cetuximab in patients with quadruple wild-type (KRAS/NRAS/BRAF/PIK3CA wild-type) HER2-amplified, HER2-nonamplified (wild-type), or HER2-mutated mCRC. In this trial, patients with HER2-amplified CRC with prior anti-EGFR therapy and/or HER2-mutated CRC with or without prior anti-EGFR therapy will be treated with trastuzumab plus neratinib until disease progression. Patients with HER2 wild-type or HER2-amplified CRC with no prior anti-EGFR therapy will receive cetuximab plus neratinib until disease progression.

The MOUNTAINEER study will test the combination of tucatinib and trastuzumab in patients with HER2 positive, anti-HER2 targeting therapy-naïve, and RAS wild-type mCRC who have been previously treated with chemotherapy and an antiangiogenic drug^[45]. Tucatinib is a very potent and highly selective small molecule inhibitor of HER2 receptor. In HER2 positive xenograft models of CRC, it has shown substantial antitumor activity^[46].

CONCLUSION

Extensive preclinical efforts have identified HER2 amplification or overexpression as a distinct and druggable molecular target in patients with mCRC who exhibit poor sensitivity to anti-EGFR. The ever-expanding clinical experience reveals that dual HER2 blockade may be an effective therapeutic strategy to overcome or reverse tumor resistance in this setting. Moreover, some case examples suggest that sequential HER2 blockade may provide long-term clinical benefit without causing significant class-specific adverse effects in patients with molecularly selected and treatment-refractory mCRC^[47]. The initial results of the HERACLES-RESCUE study will most likely clarify this issue.

REFERENCES

- Moriarty A, O'Sullivan J, Kennedy J, Mehigan B, McCormick P. Current targeted therapies in the treatment of advanced colorectal cancer: a review. *Ther Adv Med Oncol* 2016; **8**: 276-293 [PMID: 27482287 DOI: 10.1177/1758834016646734]
- Chan DLH, Segelov E, Wong RS, Smith A, Herbertson RA, Li BT, Tebbutt N, Price T, Pavlakis N. Epidermal growth factor receptor (EGFR) inhibitors for metastatic colorectal cancer. *Cochrane Database Syst Rev* 2017; **6**: CD007047 [PMID: 28654140 DOI: 10.1002/14651858.CD007047]
- Peeters M, Kafatos G, Taylor A, Gastanaga VM, Oliner KS, Hechmati G, Terwey JH, van Krieken JH. Prevalence of RAS mutations and individual variation patterns among patients with metastatic colorectal cancer: A pooled analysis of randomised controlled trials. *Eur J Cancer* 2015; **51**: 1704-1713 [PMID: 26049686 DOI: 10.1016/j.ejca.2015.05.017]
- Hecht JR, Douillard JY, Schwartzberg L, Grothey A, Kopetz S, Rong A, Oliner KS, Sidhu R. Extended RAS analysis for anti-epidermal growth factor therapy in patients with metastatic colorectal cancer. *Cancer Treat Rev* 2015; **41**: 653-659 [PMID: 26220150 DOI: 10.1016/j.ctrv.2015.05.008]
- Wee P, Wang Z. Epidermal Growth Factor Receptor Cell Proliferation Signaling Pathways. *Cancers* (Basel) 2017; **9**: 52 [PMID: 28513565 DOI: 10.3390/cancers9050052]
- Guo G, Gong K, Wohlfeld B, Hatanpaa KJ, Zhao D, Habib AA. Ligand-Independent EGFR Signaling. *Cancer Res* 2015; **75**: 3436-3441 [PMID: 26282175 DOI: 10.1158/0008-5472.CAN-15-0989]
- Zenonos K, Kyprianou K. RAS signaling pathways, mutations and their role in colorectal cancer. *World J Gastrointest Oncol* 2013; **5**: 97-101 [PMID: 23799159 DOI: 10.4251/wjgo.v5.i5.97]
- Bokemeyer C, Köhne CH, Ciardiello F, Lenz HJ, Heinemann V, Klinkhardt U, Beier F, Duecker K, van Krieken JH, Tejpar S. FOLFOX4 plus cetuximab treatment and RAS mutations in colorectal cancer. *Eur J Cancer* 2015; **51**: 1243-1252 [PMID: 25937522 DOI: 10.1016/j.ejca.2015.04.007]
- Brulé SY, Jonker DJ, Karapetis CS, O'Callaghan CJ, Moore MJ, Wong R, Tebbutt NC, Underhill C, Yip D, Zalberg JR, Tu D, Goodwin RA. Location of colon cancer (right-sided versus left-sided) as a prognostic factor and a predictor of benefit from cetuximab in NCIC CO.17. *Eur J Cancer* 2015; **51**: 1405-1414 [PMID: 25979833 DOI: 10.1016/j.ejca.2015.03.015]
- Venook AP, Niedzwiecki D, Innocenti F, Fruth B, Greene C, O'Neil BH, Shaw JE, Atkins JN, Horvath LE, Polite BN, Meyerhardt JA, O'Reilly EM, Goldberg RM, Hochster HS, Blanke CD, Schilsky RL, Mayer RJ, Bertagnolli MM, Lenz HJ. Impact of primary (1°) tumor location on overall survival (OS) and progression-free survival (PFS) in patients (pts) with metastatic colorectal cancer (mCRC): Analysis of CALGB/SWOG 80405 (Alliance). *J Clin Oncol* 2016; **15** (suppl): Abstract 3504 [DOI: 10.1200/JCO.2016.34.15_suppl.3504]
- Tejpar S, Stintzing S, Ciardiello F, Tabernero J, Van Cutsem E, Beier F, Esser R, Lenz HJ, Heinemann V. Prognostic and Predictive Relevance of Primary Tumor Location in Patients With RAS Wild-Type Metastatic Colorectal Cancer: Retrospective Analyses of the CRYSTAL and FIRE-3 Trials. *JAMA Oncol* 2017; **3**: 194-201 [PMID: 27722750 DOI: 10.1001/jamaoncol.2016.3797]
- Li D, Fu Q, Li M, Li J, Yin C, Zhao J, Li F. Primary tumor site and anti-EGFR monoclonal antibody benefit in metastatic colorectal cancer: a meta-analysis. *Future Oncol* 2017; **13**: 1115-1127 [PMID: 28110551 DOI: 10.2217/fon-2016-0468]
- Sunakawa Y, Ichikawa W, Tsuji A, Denda T, Segawa Y, Negoro Y, Shimada K, Kochi M, Nakamura M, Kotaka M, Tanioka H, Takagane A, Tani S, Yamaguchi T, Watanabe T, Takeuchi M, Fujii M, Nakajima T. Prognostic Impact of Primary Tumor Location on Clinical Outcomes of Metastatic Colorectal Cancer Treated With Cetuximab Plus Oxaliplatin-Based Chemotherapy: A Subgroup Analysis of the JACCRO CC-05/06 Trials. *Clin Colorectal Cancer* 2017; **16**: e171-e180 [PMID: 27856123 DOI: 10.1016/j.clcc.2016.09.010]
- Schwartzberg LS, Rivera F, Karthaus M, Fasola G, Canon JL, Hecht JR, Yu H, Oliner KS, Go WY. PEAK: a randomized, multicenter phase II study of panitumumab plus modified fluorouracil, leucovorin, and oxaliplatin (mFOLFOX6) or bevacizumab plus mFOLFOX6 in patients with previously untreated, unresectable, wild-type KRAS exon 2 metastatic colorectal cancer. *J Clin Oncol* 2014; **32**: 2240-2247 [PMID: 24687833 DOI: 10.1200/JCO.2013.53.2473]
- Zhao B, Wang L, Qiu H, Zhang M, Sun L, Peng P, Yu Q, Yuan X. Mechanisms of resistance to anti-EGFR therapy in colorectal cancer. *Oncotarget* 2017; **8**: 3980-4000 [PMID: 28002810 DOI: 10.18632/oncotarget.14012]
- Therkildsen C, Bergmann TK, Henriksen-Schnack T, Ladelund S, Nilbert M. The predictive value of KRAS, NRAS, BRAF, PIK3CA and PTEN for anti-EGFR treatment in metastatic colorectal cancer: A systematic review and meta-analysis. *Acta Oncol* 2014; **53**: 852-864 [PMID: 24666267 DOI: 10.3109/0284186X.2014.895036]

- 17 **Wang ZH**, Gao QY, Fang JY. Loss of PTEN expression as a predictor of resistance to anti-EGFR monoclonal therapy in metastatic colorectal cancer: evidence from retrospective studies. *Cancer Chemother Pharmacol* 2012; **69**: 1647-1655 [PMID: 22610356 DOI: 10.1007/s00280-012-1886-y]
- 18 **Nandan MO**, Yang VW. An Update on the Biology of RAS/RAF Mutations in Colorectal Cancer. *Curr Colorectal Cancer Rep* 2011; **7**: 113-120 [PMID: 21625338 DOI: 10.1007/s11888-011-0086-1]
- 19 **De Roock W**, Claes B, Bernasconi D, De Schutter J, Biesmans B, Fountzilas G, Kalogeras KT, Kotoula V, Papamichael D, Laurent-Puig P, Penault-Llorca F, Rougier P, Vincenzi B, Santini D, Tonini G, Cappuzzo F, Frattini M, Molinari F, Saletti P, De Dosso S, Martini M, Bardelli A, Siena S, Sartore-Bianchi A, Tabernero J, Macarulla T, Di Fiore F, Gangloff AO, Ciardiello F, Pfeiffer P, Qvortrup C, Hansen TP, Van Cutsem E, Piesseaux H, Lambrechts D, Delorenzi M, Tejpar S. Effects of KRAS, BRAF, NRAS, and PIK3CA mutations on the efficacy of cetuximab plus chemotherapy in chemotherapy-refractory metastatic colorectal cancer: a retrospective consortium analysis. *Lancet Oncol* 2010; **11**: 753-762 [PMID: 20619739 DOI: 10.1016/S1470-2045(10)70130-3]
- 20 **Geissler M**, Martens U, Knorrnschild R, Greeve J, Florschuetz A, Tannapfel A, Wessendorf S, Seufferlein T, Kanzler S, Heinemann V, Held S, Reinacher-Schick A. mFOLFOXIRI + panitumumab versus FOLFOXIRI as first-line treatment in patients with RAS wild-type metastatic colorectal cancer m(CRC): A randomized phase II VOLFI trial of the AIO (AIO-KRK0109). *Ann Oncol* 2017; **28** (suppl 5): 159 [DOI: 10.1093/annonc/mdx393.002]
- 21 **Bertotti A**, Migliardi G, Galimi F, Sassi F, Torti D, Isella C, Corà D, Di Nicolantonio F, Buscarino M, Petti C, Ribero D, Russolillo N, Muratore A, Massucco P, Pisacane A, Molinaro L, Valtorta E, Sartore-Bianchi A, Risio M, Capussotti L, Gambacorta M, Siena S, Medico E, Sapino A, Marsoni S, Comoglio PM, Bardelli A, Trusolino L. A molecularly annotated platform of patient-derived xenografts ("xenopatients") identifies HER2 as an effective therapeutic target in cetuximab-resistant colorectal cancer. *Cancer Discov* 2011; **1**: 508-523 [PMID: 22586653 DOI: 10.1158/2159-8290.CD-11-0109]
- 22 **Yonesaka K**, Zejnullahu K, Okamoto I, Satoh T, Cappuzzo F, Souglakos J, Ercan D, Rogers A, Roncalli M, Takeda M, Fujisaka Y, Philips J, Shimizu T, Maenishi O, Cho Y, Sun J, Destro A, Taira K, Takeda K, Okabe T, Swanson J, Itoh H, Takada M, Lifshits E, Okuno K, Engelman JA, Shivdasani RA, Nishio K, Fukuoka M, Varella-Garcia M, Nakagawa K, Jänne PA. Activation of ERBB2 signaling causes resistance to the EGFR-directed therapeutic antibody cetuximab. *Sci Transl Med* 2011; **3**: 99ra86 [PMID: 21900593 DOI: 10.1126/scitranslmed.3002442]
- 23 **Wieduwilt MJ**, Moasser MM. The epidermal growth factor receptor family: biology driving targeted therapeutics. *Cell Mol Life Sci* 2008; **65**: 1566-1584 [PMID: 18259690 DOI: 10.1007/s00188-008-7440-8]
- 24 **Moasser MM**. The oncogene HER2: its signaling and transforming functions and its role in human cancer pathogenesis. *Oncogene* 2007; **26**: 6469-6487 [PMID: 17471238 DOI: 10.1038/sj.onc.1210477]
- 25 **Huang G**, Chantray A, Epstein RJ. Overexpression of ErbB2 impairs ligand-dependent downregulation of epidermal growth factor receptors via a post-transcriptional mechanism. *J Cell Biochem* 1999; **74**: 23-30 [PMID: 10381258 DOI: 10.1002/(SICI)1097-4644(19990701)74:1<23::AID-JCB3>3.0.CO;2-L]
- 26 **Karunakaran D**, Tzahar E, Beerli RR, Chen X, Graus-Porta D, Ratzkin BJ, Seger H, Hynes NE, Yarden Y. ErbB-2 is a common auxiliary subunit of NDF and EGF receptors: implications for breast cancer. *EMBO J* 1996; **15**: 254-264 [PMID: 8617201 DOI: 10.1002/j.1460-2075.1996.tb00356.x]
- 27 **Holbro T**, Beerli RR, Maurer F, Koziczak M, Barbas CF 3rd, Hynes NE. The ErbB2/ErbB3 heterodimer functions as an oncogenic unit: ErbB2 requires ErbB3 to drive breast tumor cell proliferation. *Proc Natl Acad Sci U S A* 2003; **100**: 8933-8938 [PMID: 12853564 DOI: 10.1073/pnas.1537685100]
- 28 **Alimandi M**, Romano A, Curia MC, Muraro R, Fedi P, Aaronson SA, Di Fiore PP, Kraus MH. Cooperative signaling of ErbB3 and ErbB2 in neoplastic transformation and human mammary carcinomas. *Oncogene* 1995; **10**: 1813-1821 [PMID: 7538656]
- 29 **Leto SM**, Sassi F, Catalano I, Torri V, Migliardi G, Zanella ER, Throsby M, Bertotti A, Trusolino L. Sustained Inhibition of HER3 and EGFR Is Necessary to Induce Regression of HER2-Amplified Gastrointestinal Carcinomas. *Clin Cancer Res* 2015; **21**: 5519-5531 [PMID: 26296355 DOI: 10.1158/1078-0432.CCR-14-3066]
- 30 **Kavuri SM**, Jain N, Galimi F, Cottino F, Leto SM, Migliardi G, Searleman AC, Shen W, Monsey J, Trusolino L, Jacobs SA, Bertotti A, Bose R. HER2 activating mutations are targets for colorectal cancer treatment. *Cancer Discov* 2015; **5**: 832-841 [PMID: 26243863 DOI: 10.1158/2159-8290.CD-14-1211]
- 31 **Richman SD**, Southward K, Chambers P, Cross D, Barrett J, Hemmings G, Taylor M, Wood H, Hutchins G, Foster JM, Oumie A, Spink KG, Brown SR, Jones M, Kerr D, Handley K, Gray R, Seymour M, Quirke P. HER2 overexpression and amplification as a potential therapeutic target in colorectal cancer: analysis of 3256 patients enrolled in the QUASAR, FOCUS and PICCOLO colorectal cancer trials. *J Pathol* 2016; **238**: 562-570 [PMID: 26690310 DOI: 10.1002/path.4679]
- 32 **Seo AN**, Kwak Y, Kim DW, Kang SB, Choe G, Kim WH, Lee HS. HER2 status in colorectal cancer: its clinical significance and the relationship between HER2 gene amplification and expression. *PLoS One* 2014; **9**: e98528 [PMID: 24879338 DOI: 10.1371/journal.pone.0098528]
- 33 **Tu J**, Yu Y, Liu W, Chen S. Significance of human epidermal growth factor receptor 2 expression in colorectal cancer. *Exp Ther Med* 2015; **9**: 17-24 [PMID: 25452770 DOI: 10.3892/etm.2014.2063]
- 34 **Wu S**, Ma C, Li W. Does overexpression of HER-2 correlate with clinicopathological characteristics and prognosis in colorectal cancer? Evidence from a meta-analysis. *Diagnostic Pathology* 2015; **10**: 144 [DOI: 10.1186/s13000-015-0380-3]
- 35 **Jeong JH**, Kim J, Hong YS, Kim D, Kim JE, Kim SY, Kim KP, Yoon YK, Kim D, Chun SM, Park Y, Jang SJ, Kim TW. HER2 Amplification and Cetuximab Efficacy in Patients With Metastatic Colorectal Cancer Harboring Wild-type RAS and BRAF. *Clin Colorectal Cancer* 2017; **16**: e147-e152 [PMID: 28223103 DOI: 10.1016/j.clcc.2017.01.005]
- 36 **Martin V**, Landi L, Molinari F, Fountzilas G, Geva R, Riva A, Saletti P, De Dosso S, Spitale A, Tejpar S, Kalogeras KT, Mazzucchelli L, Frattini M, Cappuzzo F. HER2 gene copy number status may influence clinical efficacy to anti-EGFR monoclonal antibodies in metastatic colorectal cancer patients. *Br J Cancer* 2013; **108**: 668-675 [PMID: 23348520 DOI: 10.1038/bjc.2013.4]
- 37 **Ramanathan RK**, Hwang JJ, Zamboni WC, Sinicrope FA, Safran H, Wong MK, Earle M, Brufsky A, Evans T, Troetschel M, Walko C, Day R, Chen HX, Finkelstein S. Low overexpression of HER-2/neu in advanced colorectal cancer limits the usefulness of trastuzumab (Herceptin) and irinotecan as therapy. A phase II trial. *Cancer Invest* 2004; **22**: 858-865 [PMID: 15641483 DOI: 10.1081/CNV-200039645]
- 38 **Clark JW**, Niedzwiecki D, Hollis D, Mayer R. Phase II trial of 5-fluorouracil (5-FU), leucovorin (LV), oxaliplatin (Ox), and trastuzumab (T) for patients with metastatic colorectal cancer (CRC) refractory to initial therapy. *Proc Am Soc Clin Oncol* 2003; **22**: Abstract 3584
- 39 **Rubinson DA**, Hochster HS, Ryan DP, Wolpin BM, McCleary NJ, Abrams TA, Chan JA, Iqbal S, Lenz HJ, Lim D, Rose J, Bekaii-Saab T, Chen HX, Fuchs CS, Ng K. Multi-drug inhibition of the HER pathway in metastatic colorectal cancer: results of a phase I study of pertuzumab plus cetuximab in cetuximab-refractory patients. *Invest New Drugs* 2014; **32**: 113-122 [PMID: 23568716 DOI: 10.1007/s10637-013-9956-5]
- 40 **Sartore-Bianchi A**, Trusolino L, Martino C, Bencardino K, Lonardi S, Bergamo F, Zagonel V, Leone F, Depetris I, Martinelli E, Troiani T, Ciardiello F, Racca P, Bertotti A, Siravegna G, Torri V, Amatu A, Ghezzi S, Marrapese G, Palmeri L, Valtorta E, Cassingena A, Lauricella C, Vanzulli A, Regge D, Veronese S, Comoglio PM, Bardelli A, Marsoni S, Siena S. Dual-targeted

- therapy with trastuzumab and lapatinib in treatment-refractory, KRAS codon 12/13 wild-type, HER2-positive metastatic colorectal cancer (HERACLES): a proof-of-concept, multicentre, open-label, phase 2 trial. *Lancet Oncol* 2016; **17**: 738-746 [PMID: 27108243 DOI: 10.1016/S1470-2045(16)00150-9]
- 41 **Valtorta E**, Martino C, Sartore-Bianchi A, Penault-Llorca F, Viale G, Risio M, Rugge M, Grigioni W, Bencardino K, Lonardi S, Zagonel V, Leone F, Noe J, Ciardiello F, Pinto C, Labianca R, Mosconi S, Graiff C, Aprile G, Frau B, Garufi C, Loupakis F, Racca P, Tonini G, Lauricella C, Veronese S, Truini M, Siena S, Marsoni S, Gambacorta M. Assessment of a HER2 scoring system for colorectal cancer: results from a validation study. *Mod Pathol* 2015; **28**: 1481-1491 [PMID: 26449765 DOI: 10.1038/modpathol.2015.98]
 - 42 **Siena S**, Bardelli A, Sartore-Bianchi A, Martino C, Siravegna G, Magri A, Leone F, Zagonel V, Lonardi S, Amatu A, Tosi F, Racca P, Ponzetti A, Ciardiello F, Marsoni S. HER2 amplification as a 'molecular bait' for trastuzumab-emtansine (T-DM1) precision chemotherapy to overcome anti-HER2 resistance in HER2 positive metastatic colorectal cancer: the HERACLES-RESCUE trial. *J Clin Oncol* 2016; **34**: 774 [DOI: 10.1200/jco.2016.34.4_suppl.tps774]
 - 43 **Trusolino L**, Bertotti A, Lonardi S, Sartore-Bianchi A, Martino C, Cottino F, Vurchio V, Valtorta E, Lauricella C, Regge D, Vanzulli A, Zagonel V, Leone F, Racca P, Ciardiello F, Ardizzoni A, Marsoni S, Siena S. Pertuzumab and trastuzumab-emtansine in HER2-positive colorectal cancer: the HERACLES B trial. *Cancer Res* 2016; **76** (Suppl): Abstract CT082 [DOI: 10.1158/1538-7445.AM2016-CT082]
 - 44 **Hainsworth JD**, Meric-Bernstam F, Swanton C, Hurwitz H, Spigel DR, Sweeney C, Burris HA, Bose R, Guo S, Bernaards C, Beattie MS, Stein A, Brammer M, Kurzrock R. Targeted therapy for advanced solid tumors based on molecular profiles: Early results from MyPathway, an open-label, phase II a umbrella basket study. *J Clin Oncol* 2016; **34** (suppl): 11511 [DOI: 10.1200/JCO.2016.34.18_suppl.LBA11511]
 - 45 **Strickler JH**, Niedzwiecki D, Zemla T, Cercek A, Fakih M, Kimmie Ng, Sanchez FA, Wu C, Peterson S, Bandel L, Grothey A, Bekaii-Saab TS. A phase II, open label study of tucatinib (ONT-380) combined with trastuzumab in patients with HER2+ metastatic colorectal cancer (mCRC)(MOUNTAINEER). *J Clin Oncol* 2017; **35** (suppl): TPS3624 [DOI: 10.1200/JCO.2017.35.15_suppl.TPS3624]
 - 46 **Peterson S**, de Vires P, Piasecki J, Rosler R. Tucatinib, a HER2 selective kinase inhibitor, is active in patient derived xenograft (PDX) models of HER2-amplified colorectal, esophageal and gastric cancers. *Ann Oncol* 2017; **28**: v573-v594 [DOI: 10.1093/annonc/mdx390.011]
 - 47 **Martinelli E**, Troiani T, Sforza V, Martini G, Cardone C, Vitiello PP, Ciardiello D, Rachiglio AM, Normanno N, Sartore-Bianchi A, Marsoni S, Bardelli A, Siena S, Ciardiello F. Sequential HER2 blockade as effective therapy in chemorefractory, HER2 gene-amplified, RAS wild-type, metastatic colorectal cancer: learning from a clinical case. *ESMO Open* 2018; **3**: e000299 [DOI: 10.1136/esmoopen-2017-000299]

P- Reviewer: Beltowski J, Cheng TH, Hu T, Temraz S
S- Editor: Wang JL **L- Editor:** A **E- Editor:** Song H





Published by **Baishideng Publishing Group Inc**
7901 Stoneridge Drive, Suite 501, Pleasanton, CA 94588, USA
Telephone: +1-925-223-8242
Fax: +1-925-223-8243
E-mail: bpgoffice@wjgnet.com
Help Desk: <http://www.f6publishing.com/helpdesk>
<http://www.wjgnet.com>

