

World Journal of *Cardiology*

World J Cardiol 2018 September 26; 10(9): 74-122



**REVIEW**

- 74 Myocardial reperfusion injury and oxidative stress: Therapeutic opportunities
González-Montero J, Brito R, Gajardo ALJ, Rodrigo R

MINIREVIEWS

- 87 Established and novel pathophysiological mechanisms of pericardial injury and constrictive pericarditis
Ramasamy V, Mayosi BM, Sturrock ED, Ntsekhe M

ORIGINAL ARTICLE**Basic Study**

- 97 NBCe1 $\text{Na}^+/\text{HCO}_3^-$ cotransporter ablation causes reduced apoptosis following cardiac ischemia-reperfusion injury *in vivo*
Vairamani K, Prasad V, Wang Y, Huang W, Chen Y, Medvedovic M, Lorenz JN, Shull GE

Clinical Trials Study

- 110 Accuracy of myocardial viability imaging by cardiac MRI and PET depending on left ventricular function
Hunold P, Jakob H, Erbel R, Barkhausen J, Heilmair C

LETTERS TO THE EDITOR

- 119 Snugger method - The Oldenburg modification of percutaneous implantation technique
Mashhour A, Zhigalov K, Szczechowicz M, Mkalaluh S, Easo J, Eichstaedt H, Borodin D, Ennker J, Weymann A

ABOUT COVER

Editorial Board Member of *World Journal of Cardiology*, Ioanna Andreadou, PharmD, PhD, Associate Professor, Department of Pharmaceutical Chemistry, University of Athens School of Pharmacy, Athens, Greece

AIM AND SCOPE

World Journal of Cardiology (*World J Cardiol*, *WJC*, online ISSN 1949-8462, DOI: 10.4330) is a peer-reviewed open access journal that aims to guide clinical practice and improve diagnostic and therapeutic skills of clinicians.

WJC covers topics concerning arrhythmia, heart failure, vascular disease, stroke, hypertension, prevention and epidemiology, dyslipidemia and metabolic disorders, cardiac imaging, pediatrics, nursing, and health promotion. Priority publication will be given to articles concerning diagnosis and treatment of cardiology diseases. The following aspects are covered: Clinical diagnosis, laboratory diagnosis, differential diagnosis, imaging tests, pathological diagnosis, molecular biological diagnosis, immunological diagnosis, genetic diagnosis, functional diagnostics, and physical diagnosis; and comprehensive therapy, drug therapy, surgical therapy, interventional treatment, minimally invasive therapy, and robot-assisted therapy.

We encourage authors to submit their manuscripts to *WJC*. We will give priority to manuscripts that are supported by major national and international foundations and those that are of great basic and clinical significance.

INDEXING/ABSTRACTING

World Journal of Cardiology (*WJC*) is now abstracted and indexed in Emerging Sources Citation Index (Web of Science), PubMed, PubMed Central, Scopus, China National Knowledge Infrastructure (CNKI), and Superstar Journals Database.

EDITORS FOR THIS ISSUE

Responsible Assistant Editor: *Xiang Li*
Responsible Electronic Editor: *Yun-Xiao Jian Wu*
Proofing Editor-in-Chief: *Lian-Sheng Ma*

Responsible Science Editor: *Ying Dou*
Proofing Editorial Office Director: *Jin-Lei Wang*

NAME OF JOURNAL
World Journal of Cardiology

ISSN
ISSN 1949-8462 (online)

LAUNCH DATE
December 31, 2009

FREQUENCY
Monthly

EDITORIAL BOARD MEMBERS
All editorial board members resources online at <http://www.wjgnet.com/1949-8462/editorialboard.htm>

EDITORIAL OFFICE
Jin-Lei Wang, Director
World Journal of Cardiology
Baishideng Publishing Group Inc

7901 Stoneridge Drive, Suite 501, Pleasanton, CA 94588, USA
Telephone: +1-925-2238242
Fax: +1-925-2238243
E-mail: editorialoffice@wjgnet.com
Help Desk: <http://www.f6publishing.com/helpdesk>
<http://www.wjgnet.com>

PUBLISHER
Baishideng Publishing Group Inc
7901 Stoneridge Drive, Suite 501, Pleasanton, CA 94588, USA
Telephone: +1-925-2238242
Fax: +1-925-2238243
E-mail: bpgoffice@wjgnet.com
Help Desk: <http://www.f6publishing.com/helpdesk>
<http://www.wjgnet.com>

PUBLICATION DATE
September 26, 2018

COPYRIGHT

© 2018 Baishideng Publishing Group Inc. Articles published by this Open-Access journal are distributed under the terms of the Creative Commons Attribution Non-commercial License, which permits use, distribution, and reproduction in any medium, provided the original work is properly cited, the use is non commercial and is otherwise in compliance with the license.

SPECIAL STATEMENT

All articles published in journals owned by the Baishideng Publishing Group (BPG) represent the views and opinions of their authors, and not the views, opinions or policies of the BPG, except where otherwise explicitly indicated.

INSTRUCTIONS TO AUTHORS
<http://www.wjgnet.com/bpg/gerinfo/204>

ONLINE SUBMISSION
<http://www.f6publishing.com>

Snugger method - The Oldenburg modification of perceval implantation technique

Ahmed Mashhour, Konstantin Zhigalov, Marcin Szczechowicz, Sabreen Mkalaluh, Jerry Easo, Harald Eichstaedt, Dmitry Borodin, Jürgen Ennker, Alexander Weymann

Ahmed Mashhour, Konstantin Zhigalov, Marcin Szczechowicz, Sabreen Mkalaluh, Jerry Easo, Harald Eichstaedt, Dmitry Borodin, Jürgen Ennker, Alexander Weymann, Department of Cardiac Surgery, European Medical School Oldenburg-Groningen, Carl von Ossietzky University Oldenburg, Oldenburg 26133, Niedersachsen, Germany

ORCID number: Ahmed Mashhour (0000-0003-4496-3610); Konstantin Zhigalov (0000-0002-6440-3736); Marcin Szczechowicz (0000-0002-0711-7354); Sabreen Mkalaluh (0000-0003-0250-0060); Jerry Easo (0000-0001-9445-5716); Harald Eichstaedt (0000-0001-5106-3886); Dmitry Borodin (0000-0003-4716-0653); Jürgen Ennker (0000-0002-9946-6147); Alexander Weymann (0000-0003-2966-6159).

Author contributions: Mashhour A wrote the paper and collected the data; Zhigalov K, Szczechowicz M, Mkalaluh S and Borodin D collected the data; Eichstaedt H, Easo J, Ennker J and Weymann A developed the technique, performed the surgeries and revised the paper.

Conflict-of-interest statement: The authors have no conflicts of interest to declare.

Open-Access: This article is an open-access article which was selected by an in-house editor and fully peer-reviewed by external reviewers. It is distributed in accordance with the Creative Commons Attribution Non Commercial (CC BY-NC 4.0) license, which permits others to distribute, remix, adapt, build upon this work non-commercially, and license their derivative works on different terms, provided the original work is properly cited and the use is non-commercial. See: <http://creativecommons.org/licenses/by-nc/4.0/>

Manuscript source: Unsolicited Manuscript

Correspondence to: Alexander Weymann, MD, PhD, Consultant Cardiac Surgeon, Surgeon, Department of Cardiac Surgery, European Medical School Oldenburg-Groningen, Carl von Ossietzky University Oldenburg, Rahel-Strauß-Street 10, Oldenburg 26133, Niedersachsen, Germany. weymann.alexander@klinikum-oldenburg.de
Telephone: +49-441-4032820
Fax: +49-441-4032830

Received: April 14, 2018

Peer-review started: April 16, 2018

First decision: June 6, 2018

Revised: July 9, 2018

Accepted: August 26, 2018

Article in press: August 26, 2018

Published online: September 26, 2018

Abstract

We present a modified implantation technique of the Perceval® sutureless aortic valve (LivaNova, London, United Kingdom) that involves the usage of snuggers for the guiding sutures during valve deployment. Both limbs of each guiding suture are pulled through an elastic tube, which is fixed with a Pean clamp, which tightens the sutures and fixes the prosthesis to the aortic annulus during valve deployment. This method proved safe and useful in over 120 cases. Valve implantation was facilitated and the need for manipulation by the assistant or the nurse was eliminated.

Key words: Aortic valve; Surgical; Perceval; Snugger; Sutureless aortic valve

© The Author(s) 2018. Published by Baishideng Publishing Group Inc. All rights reserved.

Core tip: In this article, we are presenting a modified implantation technique of the Perceval sutureless aortic valve prosthesis to enhance proper positioning of the prosthesis and aid the reproducibility of the implantation procedure. The modification involves using snuggers to fix the valve prosthesis to the aortic annulus during deployment.

Mashhour A, Zhigalov K, Szczechowicz M, Mkalaluh S, Easo J, Eichstaedt H, Borodin D, Ennker J, Weymann A. Snugger

method - The Oldenburg modification of perceval implantation technique. *World J Cardiol* 2018; 10(9): 119-122 Available from: URL: <http://www.wjgnet.com/1949-8462/full/v10/i9/119.htm> DOI: <http://dx.doi.org/10.4330/wjc.v10.i9.119>

TO THE EDITOR

Introduction

Surgery of the aortic valve replacement (AVR) is still recommended in certain patients with aortic valve disease. Two approaches have become quite popular; surgical and trans-catheter aortic valve replacement (SAVR and TAVR, respectively), whereby TAVR is mostly reserved for elderly patients with higher surgical risk^[1,2]. Although not considered in the current guidelines, the sutureless variety of SAVR has been proven to reduce the overall surgical risk by significantly reducing operative and cross-clamp times, while demonstrating lower incidence of known complications of TAVR with comparable or even better results, especially in intermediate-risk patients^[3-5].

The Perceval valve (Sorin Group Italia Srl, Saluggia, Italy) is a self-anchoring, self-expanding, sutureless, surgical aortic bioprosthesis. The valve leaflets are mounted to an elastic nickel-titanium alloy stent^[3]. The stent anchors the valve *via* six sinusoidal posts to the aortic root at the sinuses of Valsalva, while the valve prosthesis seals the left ventricular outflow tract (LVOT) through an intra-annular and a supra-annular sealing ring. Correctly positioned, the leaflets of the valve prosthesis are aligned with those of the native aortic valve and the inflow ring of the prosthesis lies at the level of the insertion plane of the native leaflets^[6]. The intra-annular ring of the Perceval valve prosthesis is supplied with three eyelets to pass guiding sutures which are previously made at the hinge points of the native aortic valve leaflets.

The valve prosthesis is then inserted into the aortic root over these guiding sutures and deployed "hand-held" in position. We describe a modification of this technique, where the prosthesis is virtually "fixed" onto the aortic annulus during deployment, which guarantees correct positioning of the prosthesis and aid the reproducibility of the implantation procedure.

Implantation technique according to the manufacturer (Sorin group)

The aortotomy should be in a transverse manner at least 3.5 cm above the aortic annulus to facilitate aortic closures. The native aortic valve is excised as with other SAVR prostheses. Although a complete decalcification of the aortic annulus is not necessary, a regular annular profile is essential for proper sealing. Sizing of the aortic annulus should be performed using the dedicated sizers. Now, the prepared prosthesis can be put in place. To ensure correct placement and alignment, a suture is made at hinge point of each leaflet perpendicular to the

annulus, so that the three sutures are approximately 120° equidistant. The suture points should be 2-3 mm afar from each side of the insertion plane of the leaflets. After each suture is taken, the needle should be cut off and both ends of the thread secured with a clamp.

Each of the guiding sutures is then passed through one of the eyelets of the prosthesis. After that, the valve prosthesis is parachuted into the aorta sliding on the guiding threads which are kept straight with a gentle pull maintaining alignment with the aorta. Correct position of the prosthesis is reached when it is descended until it is stopped at the insertion points of the threads and the commissural struts of the prosthesis are aligned with the native commissures.

The valve is then released in two steps. First, the inflow section is released by rotating the control button on the delivery device until a click is heard and felt. At this stage, it is important to ensure that the sinusoidal struts correspond to the sinuses of Valsalva and that the stent of the prosthesis does not obstruct the coronary ostia. Second, the outflow section is released by withdrawing the sliding sheath off the holder avoiding rotational movement. It is important to keep the holder in an axial position to aorta all the time.

After visual assessment of the correct position and alignment of the prosthesis, patency of the coronary ostia and that no annulus is visible below and above the valve inflow ring, the inflow ring should be postdilated (4 atmospheric pressure for 30 s) using a dedicated catheter. While the postdilation balloon is inflated, warm sterile saline is poured within the aortic root to ensure optimal valve sealing and optimized anchoring. The guiding sutures are removed and the aortotomy is closed as usual taking care not to capture the stent of the prosthesis within the closure suture.

How we do it

Preparations of the prosthesis and the aortic root as well as the sizing procedure and prosthesis selection are similar to the method described above. The guiding sutures are also placed as described. We use 3/0 double-armed poly-propylene sutures. The suture is made with one needle from the LVOT side to the aorta side of the hinge point of each leaflet leaving 2-3 mm on each side as recommended above. The other needle is passed through the eyelet of the Perceval prosthesis before both needles are cut off.

Now, instead of directly securing the thread with a clamp, both ends are passed through an elastic tube making a snugger. While holding the prosthesis holder in place and axial to the aortic root, the snuggers are tightened. While tightening each snugger, both ends of the thread are pulled upwards. This "pull" is partially opposed by a light downward pressure on the prosthesis in the direction of the insertion of the guiding suture. The snugger is then pulled tight and secured with a Pean clamp (Figure 1).

This is repeated with the other two guiding sutures.

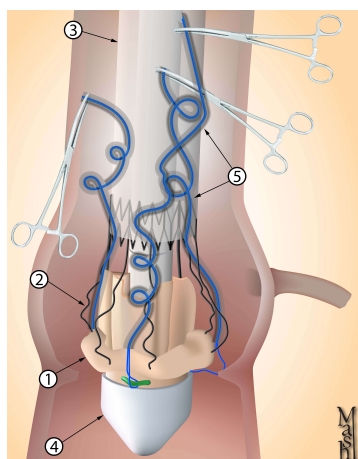


Figure 1 Graphic presentation of the prosthesis in place after tightening the snares and securing with clamps. 1 represents valve prosthesis; 2 represents valve stent; 3 represents shaft of the dual holder device; 4 represents tip of the dual holder device; 5 represents the snares.

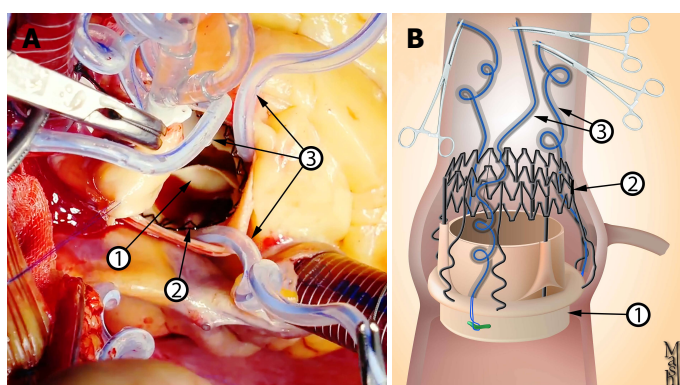


Figure 2 Intraoperative picture. A: Graphic presentation of the prosthesis after deployment; B: Prosthesis. Notice that the snare should not lie between the ring of the prosthesis and the annulus of the aorta. 1 represents valve prosthesis; 2 represents valve stent; 3 represents the snares.

The assistant should retract the aortic wall slightly open, so that the descent of the elastic tube into the tightened position is done under direct vision. It is important that the snuggers are tight enough; however, care should be taken that the elastic tube ends above the sealing ring of the inflow stent of the prosthesis and not trapped between the ring and the aortic annulus (Figure 2), as this could lead to incomplete deployment of the prosthesis, difficult withdrawal of the elastic tube and, potentially, dislodgement of the prosthesis during withdrawal of the elastic tube.

Next, the prosthesis is deployed in the same fashion described above. In this step, the assistant can help stabilize the prosthesis and hold the aorta open to aid visualization. Checking for correct positioning *etc.* as well as postdilation and irrigation with warm saline are also performed as described above.

Now, the snuggers are loosened and the elastic tubes are withdrawn. This should be done slowly and under direct vision taking care not to dislodge the prosthesis. The threads are then pulled out carefully. The prosthesis is checked again for proper anchoring and correct seat, and the aortotomy is closed.

Comment

As rapid-deployment prosthesis, one of the main benefits of the Perceval prosthesis is reducing operative and cross-clamp times through simplifying the surgical implantation technique. However, absolute stability is required during valve deployment to ensure proper seating of the prosthesis within the aortic root. Otherwise, valve malposition could occur^[7].

On the contrary, in the technique described in this work, after tightening the snuggers, the prosthesis and the aortic annulus are fixed together eliminating the need for extra manipulations by the assistant or the nurse, so that the surgeon can self-sufficiently deploy the valve with one hand holding the delivery device and the other hand rotating the control button to release the valve.

Moreover, while tightening each snugger, the surgeon should pay attention to this one guiding suture; a step which is repeated with each suture at a time. On the contrary, the standard technique recommended by the manufacturer requires ensuring that the prosthesis is seated in the right position in respect to the three guiding sutures simultaneously.

According to the manufacturer's recommendations, traction sutures should be released prior to the deployment of the valve. We did not consider this step necessary as the snuggers would literally fix the valve prosthesis to the aortic annulus at three points forcing it into planarity and thus eliminating any distorting leverage exerted by the traction sutures. The continued presence of the traction sutures allows better visualization of the aortic annulus during prosthesis deployment.

In the manufacturer's recommendations, in case of a hypoplastic coronary ostium, the first guiding suture should be in the corresponding sinus. We did not encounter this in our case series. We also did not find any reports on the use of Perceval prosthesis in cases with a hypoplastic coronary ostium. Indeed, this should not be problematic. Nevertheless, the modification proposed in this work would add more security to the implantation, as the snuggers push the prosthesis down as far as possible, guaranteeing freedom of the hypoplastic ostium.

The use of snuggers, was reported once to facilitate a total endoscopic AVR^[8]. However, to our knowledge, the use of snuggers to fixate the Perceval prosthesis during deployment in the way described in this work has not been described before. Until now, we have used this modification in over 120 patients with 100% primary success and excellent postoperative results.

REFERENCES

- 1 Nishimura RA, Otto CM, Bonow RO, Carabello BA, Erwin JP 3rd, Fleisher LA, Jneid H, Mack MJ, McLeod CJ, O'Gara PT, Rigolin VH, Sundt TM 3rd, Thompson A. 2017 AHA/ACC Focused Update of the 2014 AHA/ACC Guideline for the Management of Patients With Valvular Heart Disease: A Report of the American College of Cardiology/American Heart Association Task Force on Clinical Practice Guidelines. *Circulation* 2017; **135**: e1159-e1195 [PMID: 28298458 DOI: 10.1161/CIR.0000000000000503]
- 2 Baumgartner H, Falk V, Bax JJ, De Bonis M, Hamm C, Holm PJ, Iung B, Lancellotti P, Lansac E, Rodriguez Muñoz D, Rosenhek R, Sjögren J, Tornos Mas P, Vahanian A, Walther T, Wendler O, Windecker S, Zamorano JL; ESC Scientific Document Group. 2017 ESC/EACTS Guidelines for the management of valvular heart disease. *Eur Heart J* 2017; **38**: 2739-2791 [PMID: 28886619 DOI: 10.1093/eurheartj/ehx391]
- 3 Fischlein T, Meuris B, Hakim-Meibodi K, Misfeld M, Carrel T, Zembala M, Gaggianesi S, Madonna F, Laborde F, Asch F, Haverich A; CAVALIER Trial Investigators. The sutureless aortic valve at 1 year: A large multicenter cohort study. *J Thorac Cardiovasc Surg* 2016; **151**: 1617-1626.e4 [PMID: 26936009 DOI: 10.1016/j.jtcvs.2015.12.064]
- 4 Laborde F, Fischlein T, Hakim-Meibodi K, Misfeld M, Carrel T, Zembala M, Madonna F, Meuris B, Haverich A, Shrestha M; Cavalier Trial Investigators. Clinical and haemodynamic outcomes in 658 patients receiving the Perceval sutureless aortic valve: early results from a prospective European multicentre study (the Cavalier Trial)†. *Eur J Cardiothorac Surg* 2016; **49**: 978-986 [PMID: 26245628 DOI: 10.1093/ejcts/ezv257]
- 5 Kadam PD, Chuan HH. Erratum to: Rectocutaneous fistula with transmigration of the suture: a rare delayed complication of vault fixation with the sacrospinous ligament. *Int Urogynecol J* 2016; **27**: 505 [PMID: 26811110 DOI: 10.1007/s00192-016-2952-5]
- 6 Folliguet TA, Laborde F, Zannis K, Ghorayeb G, Haverich A, Shrestha M. Sutureless perceval aortic valve replacement: results of two European centers. *Ann Thorac Surg* 2012; **93**: 1483-1488 [PMID: 22541180 DOI: 10.1016/j.athoracsur.2012.01.071]
- 7 Santarpino G, Pfeiffer S, Concistrè G, Fischlein T. A supra-annular malposition of the Perceval S sutureless aortic valve: the 'χ-movement' removal technique and subsequent reimplantation. *Interact Cardiovasc Thorac Surg* 2012; **15**: 280-281 [PMID: 22535542 DOI: 10.1093/icvts/ivs148]
- 8 Vola M, Fuzellier JF, Gerbay A, Campisi S. First in Human Totally Endoscopic Perceval Valve Implantation. *Ann Thorac Surg* 2016; **102**: e299-e301 [PMID: 27645967 DOI: 10.1016/j.athoracsur.2016.03.045]

P- Reviewer: Iacoviello M, Dai X, Falconi M S- Editor: Dou Y
L- Editor: A E- Editor: Wu YXJ





Published by **Baishideng Publishing Group Inc**
7901 Stoneridge Drive, Suite 501, Pleasanton, CA 94588, USA
Telephone: +1-925-223-8242
Fax: +1-925-223-8243
E-mail: bpgoffice@wjgnet.com
Help Desk: <http://www.f6publishing.com/helpdesk>
<http://www.wjgnet.com>

