

Intravenous drug abuse and tricuspid valve endocarditis: Growing trends in the Middle East Gulf region

Prashanth Panduranga, Seif Al-Abri, Jawad Al-Lawati

Prashanth Panduranga, Department of Cardiology, Royal Hospital, Muscat-111, Oman

Seif Al-Abri, Department of Medicine, Royal Hospital, PB 1331, Muscat-111, Oman

Jawad Al-Lawati, Department of Non-communicable Diseases, Ministry of Health, PB 393, Muscat-113, Oman

Author contributions: All the authors contributed to this paper.

Correspondence to: Prashanth Panduranga, MD, FRCP (Edin), Department of Cardiology, Royal Hospital, Post Box 1331, Muscat-111, Oman. prashanthp_69@yahoo.co.in

Telephone: +968-92-603746 Fax: +968-24-599841

Received: June 8, 2013 Revised: September 10, 2013

Accepted: October 16, 2013

Published online: November 26, 2013

Key words: Drug abuser; Illicit drugs; Infective endocarditis; Tricuspid valve; Middle East

Core tip: It is presumed that tricuspid valve endocarditis is uncommon in the Middle East region. However, recently published global data indicate growing trends in the use of illicit drug abuse in the Middle East Gulf region. The Middle East Gulf States, currently a transit market, are also becoming a growing consumer market in view of the consumption patterns of substance abuse in the youth. This article reviews the epidemiology of illicit drug abuse in the Middle East Gulf region as well as diagnosis and treatment of tricuspid valve endocarditis.

Abstract

Traditionally, tricuspid valve endocarditis is uncommon in the Middle East region. However, recent global data indicate growing trends in the use of illicit drug abuse, specifically injectable heroin, in the Middle East Gulf region. The presence of many transit port services in the Middle East Gulf States has led to smuggling of substance abuse drugs in the region. The Middle East Gulf States, currently a transit market, are also becoming a growing consumer market in view of the increased substance abuse in the youth. However, there is a paucity of data with respect to the prevalence or incidence of tricuspid valve endocarditis in the region, probably due to underdiagnosis or underreporting. A high index of suspicion of tricuspid valve endocarditis is essential in patients with a history of intravenous drug abuse. This article reviews the epidemiology of illicit drug abuse in the Middle East Gulf region, as well as the diagnosis and treatment of tricuspid valve endocarditis, and calls for all physicians in the region to be vigilant while dealing with intravenous drug abuse.

© 2013 Baishideng Publishing Group Co., Limited. All rights reserved.

Panduranga P, Al-Abri S, Al-Lawati J. Intravenous drug abuse and tricuspid valve endocarditis: Growing trends in the Middle East Gulf region. *World J Cardiol* 2013; 5(11): 397-403 Available from: URL: <http://www.wjgnet.com/1949-8462/full/v5/i11/397.htm> DOI: <http://dx.doi.org/10.4330/wjc.v5.i11.397>

INTRODUCTION

Illicit drug abuse, including intravenous drug abuse (IVDA), is increasing in the Middle East Gulf region^[1,2]. The existence of many transit port services in the Middle East Gulf States (Saudi Arabia, United Arab Emirates (UAE), Oman, Bahrain, Kuwait and Qatar) has contributed to smuggling of substance abuse drugs in the region^[1,2]. The Middle East and Gulf, traditionally transit markets, are also increasingly becoming consumer markets in view of their geographical location and the young population of the region (60% below 15 years). As a direct consequence, this may have led to increasing correlates of drug abuse such as overdose, dependence, psychosis, suicide, road traffic accidents, cutaneous complications, thrombophlebitis of veins, myocardial infarction, pulmonary embolism, infective endocarditis

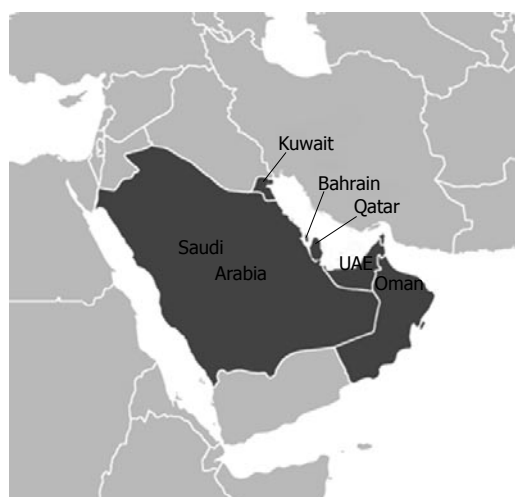

Figure 1 Map of Middle East Gulf States. UAE: United arab emirates.

(IE) specifically tricuspid valve endocarditis (TVE), pneumonia, pulmonary tuberculosis, septicemia, transmission of blood-borne infections (human immune deficiency virus (HIV)/hepatitis) and have also impacted on increased mortality due to overdose^[2]. However, there is a paucity of data with respect to the incidence of tricuspid valve endocarditis in this region, probably due to under-diagnosis or underreporting. In addition, there is a lack of epidemiological studies documenting the burden of disease in terms of prevalence and related morbidity and mortality due to drug abuse in this region. This review article summarizes the epidemiology of illicit drug abuse in the Middle East Gulf Region (Figure 1) in relation to the diagnosis and treatment of TVE.

EPIDEMIOLOGY AND BURDEN OF ILLICIT DRUG ABUSE IN THE MIDDLE EAST GULF REGION

The commonly abused illicit substances can be broadly grouped as stimulants (amphetamines/methamphetamines/crystal meth/speed/captagon tablets/khat /3,4-methylenedioxy-N-methylamphetamine/ecstasy, lysergic acid diethylamide, cocaine/crack and cannabis/marijuana/ganja/hashish/bhang), hypnotics (barbiturates and methaqualones) and opiates (morphine, heroin/smack/brown sugar, opium, methadone). Among these, the most commonly injected drug is heroin^[1]. However, morphine, amphetamines/methamphetamines, and cocaine are also common^[1].

Globally, the United Nations Office on Drugs and Crime (UNODC), estimates that there were about 149-271 million people aged 15-64 years (3.3%-6.1%) who used an illicit drug at least once in 2009^[1]. A large systematic review which included UNODC data reported 125-203 million people to be cannabis users, 15-39 million were opioid, amphetamine or cocaine users, and 11-21 million IVDAs^[2]. The highest levels of use were in North America, Western Europe and Oceania. The

Middle East data suggested that 6-12 million (2.4%-4.8%) were cannabis users, 2-3 million were opioid users (0.8%-1.4%), 0.4-4 million were amphetamine users (0.2%-1.7%) and 0.04-0.6 million were cocaine users^[2]. Opioid use, including heroin, had an estimated 12 to 21 million users globally. The highest rates of opioid use was reported in the Middle Eastern regions, where up to 1.4% of the population aged 15 to 64 had tried the drug at least once in 2009^[2].

Data from the Eastern Mediterranean Regional Office of the World Health Organization suggest a prevalence of illicit drug use disorders at the rate of 3500 per 100000 population and that of injecting drug use to be 172 per 100000 population^[3]. A report from UAE estimated that about 40% of all illegal drugs in the world are sold in the Gulf region^[4]. The same report noted that the mean age of new drug abusers has dropped from 17-18 years to 10 years^[4]. Most of the illicit drugs destined for African and European countries transited *via* the Gulf States, with significant leakage to the Gulf States^[4]. In a report from Oman, quoting the Ministry of Health, 1521 drug misuse-related cases were reported in the period 2006-2011 and the most common mode of misuse was IVDA (66%)^[5].

In 2002, a report from Al-Amiri Hospital in Kuwait estimated the presence of 18000-20000 drug users in this small Gulf State, the equivalent of 1% its total population^[6]. Unemployment, excess disposable income, boredom and frustration were cited as important factors for the youth to take up drugs. In addition, drug dealers easily get couriers among the thousands of expatriate laborers entering Kuwait^[6]. Another survey conducted among university students in Kuwait revealed that the total lifetime prevalence of illicit drug use was 14.4% and the most frequently used illicit substance was marijuana (11%)^[7]. On multivariate logistic regression analysis, drug use was significantly associated with age, poor academic performance, high family income, being an only child in the family, divorced parents and graduation from a private high school^[7].

TRICUSPID VALVE ENDOCARDITIS PATHOGENESIS

Right sided endocarditis accounts for 5%-10% of all IE and predominantly affects the tricuspid valve (TV)^[8-10]. TVE commonly occur among IVDAs^[11,12]. The cause for the increased prevalence of TVE in IVDAs is multifactorial. Frontera *et al*^[10] suggested possible mechanisms which include: (1) recurrent episodes of particulate matter bombardment (drug solutions may contain particulate matter like talc) leading to damage of TV; (2) TV intimal damage, vasospasm (cocaine induced) and thrombus formation due to injected drugs; (3) increased right sided cardiac turbulence secondary to drug-induced pulmonary hypertension (buprenorphine); (4) increased expression of matrix molecules on the TV which are capable of binding microorganisms in IVDAs; (5) injection of large

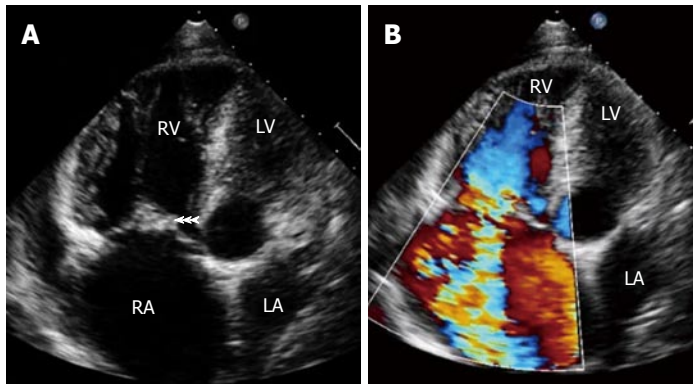


Figure 2 Transthoracic echocardiography showing (A) large vegetation attached to tricuspid valve leaflets (arrowheads) in a patient with intravenous drug abuse and septic pulmonary emboli. Note hugely dilated right atrium and right ventricle and (B) severe tricuspid regurgitation. RA: Right atrium; RV: Right ventricle; LA: Left atrium; LV: Left ventricle.

“bacterial loads” from contaminated drug solutions causing IE; and (6) IVDA-related “immune dysregulation” with or without coexistent HIV infection. In addition, poor injection hygiene (*e.g.*, lack of skin cleaning before injecting), injecting with unsterile needles, multiple needle sharing and injecting contaminated drug solutions which tends to introduce high bacterial loads.

WORLDWIDE INCIDENCE OF TVE

Among the published reports, the overall incidence of IE among IVDA ranges from 1.5-20 per 1000 drug user per year^[10]. In the United States, the incidence is estimated at 1.5 to 3.3 cases per 1000 person-years^[12]. From the Western series, acute infection is responsible for 60% of all hospital admissions among IVDA. Among these acute infections, TVE is implicated in 5%-15% of these cases^[12,13]. It is also estimated that the incidence of IE in IVDA is 2%-5% per year and is responsible for 5% to 10% of the overall death rate^[14]. In the large multinational International Collaboration on Endocarditis-Pro prospective Cohort Study (ICE-PCS) evaluating 2781 patients with IE, 10% of the patients were IVDA^[15].

INCIDENCE OF TVE IN THE MIDDLE EAST

There are few published reports of IE from Middle East Gulf States. Among these studies, IVDA is reported in only 1 study. Even although the Middle East region has the highest prevalence of IVDA among all countries in the world^[2], the incidence of TVE and IVDA is reported to be very low. This may be due to either underdiagnosis or underreporting. In a study from Oman published in 2003 and involving 90 patients with IE, there were no patients with TVE or with a history of IVDA^[16]. This was similar to studies from Yemen (72 patients) and Kuwait (60 patients), with no involvement of TV or history of IVDA^[17,18]. However, between 2006 and 2011, 7 cases of TVE with 3 of them reporting active IVDA were reported from Oman (personal communication). In a study from Saudi Arabia among 83 patients with IE, 4 cases of native TV involvement and 1 case of prosthetic TV involvement were reported, but with no mention of IVDA^[19]. In a second study from Saudi Arabia, out of 47 cases of endocarditis, TV was affected in 3 patients

(6.4%), pulmonic valve in 2 patients and both pulmonic valve and TV in 1 patient (2.1%). In addition, 2 (4.3%) patients gave a history of IVDA^[20]. A study from Lebanon also reported 7% (6/91) of patients with IE had TVE and no IVDA^[21].

CLINICAL MANIFESTATIONS

The majority of IVDA with TVE are young, between 20-40 years of age, and predominantly men (male:female ratio, 4 to 6:1)^[12]. The most common presenting manifestations of TVE are persistent fever, bacteremia and multiple pulmonary emboli^[9,11]. Respiratory symptoms are more common in TVE than left sided endocarditis. Dyspnea, pleuritic chest pain, cough and hemoptysis are the most common symptoms. Patients can present with metastatic abscesses in lungs that may lead to repeated episodes of dyspnea with hypoxemia and may mimic pulmonary embolism. However, left sided endocarditis in IVDA is not uncommon and when any peripheral emboli or stroke occur, either left sided endocarditis or paradoxical embolism should be strongly suspected in patients with IVDA^[11]. It is important to note that history and physical examination are not diagnostic of TVE in patients with IVDA. There is an absence of underlying heart disease in two-thirds of the patients. Symptoms and signs may be nonspecific. In about 65% of IVDA with TVE, heart murmurs are not appreciated^[11]. This is in view of normal or mildly elevated right ventricular pressures resulting in a low velocity less turbulent tricuspid regurgitation (TR) jet^[11]. Generally, respiratory findings dominate the clinical, chest X-ray and computed tomography (CT) scan features. They can even mimic other respiratory infections like pulmonary tuberculosis^[22].

DIAGNOSIS

The two most important diagnostic features of TVE in patients with IVDA are echocardiographic evidence of vegetation (Figure 2A) and the presence of septic embolic phenomena^[11]. In addition, moderate to severe tricuspid regurgitation may be present (Figure 2B). In IVDA with IE, TV is commonly involved in about 60%-80% of cases, with reported mortality of 5%-10%^[9]. In a study of 105 IVDA with IE, 86% were right sided and 14%

were left sided^[11]. In IVDAs, both sides of the heart are usually involved simultaneously in 5% to 10% of cases^[13]. TV vegetations generally grow to a larger size (> 2 cm) due to low pressure in right heart chambers and thus may mimic fungal endocarditis^[11]. Vegetations may embolize and can be seen in the right ventricle or pulmonary artery or entrapped in the tricuspid chordal apparatus^[11,22]. Transthoracic echocardiography (TTE) plays an important role in the diagnosis of TVE. Many IVDAs are young and generally have good echo windows, resulting in good high resolution images^[11]. In addition, as the TV is relatively nearer to the transducer, excellent images can be obtained by TTE. TEE is indicated in patients with poor echo window or in those with initial negative TTE in whom there is high index of suspicion of TVE^[11]. The diagnostic yield of TTE is comparable with that of TEE in IVDAs^[23].

Duke's criteria have been predominantly applied for left sided endocarditis and have not been studied specifically in TVE. However, the two major criteria of typical echocardiographic features of TVE along with positive blood cultures with a typical organism should be regarded as diagnostic of TVE^[11]. Blood culture is positive in a high proportion of TVE. When the culture is negative, it is usually due to prior antibiotic use or due to rare organisms such as Bartonella and HACEK organisms. The predominant organism of TVE in IVDAs is Staphylococcus aureus (60%-90%)^[9-15]. Other organisms causing TVE are pseudomonas aeruginosa, other gram-negative bacilli, poly-microbial infections, fungi and group B streptococci^[9-15]. In a study, the incidence of IE was 17% among all staphylococcal bacteremia patients and 46% among IVDAs^[13]. In another study, 24% of IVDAs developed methicillin resistant staphylococcus aureus, of whom 41% developed IE^[24]. Thus, in IVDAs, if patients develop staphylococcal bacteremia, nearly 50% of them go on to develop TVE. In another study among IVDAs presenting with fever to emergency departments, negative predictors of TVE were lack of skin infection, tachycardia, hyponatremia, pneumonia on chest radiograph, history of endocarditis, thrombocytopenia and heart murmur. The best criteria combination of lack of skin infection, tachycardia and cardiac murmur had a sensitivity and negative predictive value of 100%^[25].

COMPLICATIONS

Septic pulmonary embolism in patients with TVE occurs in 75% to 100% of patients^[26]. It may cause pulmonary infarction, pulmonary abscesses, bilateral pneumothoraces, mycotic aneurysms of pulmonary arteries, pleural effusions and empyema^[9,11]. The chest X-ray may show pulmonary infiltrates or opacities in about 56% of radiographs at presentation^[11]. Typical chest manifestations on CT scan due to emboli are pulmonary infiltrates, obstruction, nodules or wedge shaped opacities with or without cavitations and abscesses suggesting septic emboli, which are seen in 80% of such patients^[9-14]. The use of large

proximal veins (femoral veins) in IVDAs may result in life-threatening septic deep venous thrombosis and pulmonary embolism^[27].

Right heart failure is common due to acute pulmonary hypertension or severe TR or TV obstruction^[9,11]. Large vegetations can cause tethering of the septal and lateral valve leaflets, causing the TV to remain open throughout systole and leading to severe TR. In addition, prolapse, perforation, right ventricular dilation and flail leaflet due to disruption can all lead to severe TR. Large vegetations can even protrude through patent foramen ovale into the left atrium^[28]. Paravalvar abscess formation occurs infrequently. Hypoxemia and paradoxical embolism can occur due to right to left shunting through a patent foramen ovale^[11].

MANAGEMENT AND PROGNOSIS

Uncomplicated TVE is successfully treated medically in 80% of patients, with only 20% needing surgical intervention^[12,29]. The reason why TVE responds well to medical therapy is that right sided heart involvement, even when severe, often allows time for medical treatment because of the greater tolerance for TR and pulmonary embolization^[29]. Hence, it is recommended to wait before surgical intervention if possible until sepsis resolves with antibiotic treatment^[29]. Right sided involvement, younger age and lack of pre-existing heart disease or other underlying diseases have been thought to explain the better prognosis of Staphylococcus aureus endocarditis among IVDAs than in the general population.

In methicillin-sensitive staphylococcal aureus native-valve endocarditis, beta-lactamase-resistant penicillins, like flucloxacillin, oxacillin or glycopeptides (teicoplanin or vancomycin), combined with gentamycin (for 2 wk) is recommended^[9]. In uncomplicated TVE, medical treatment should be continued for 4-6 wk^[12]. However, IVDAs pose a unique challenge in the treatment as they are poor or non-compliant to medication and follow-up, get early self-discharge from hospital and may go back to injecting drugs again once discharged from hospital. This naturally leads to high rates of relapse and re-infection^[30]. Given the low likelihood of adherence to a 4 wk course of antimicrobials among IVDAs, shorter courses of therapy, with a combination of β -lactam with or without an aminoglycoside (for 2 wk) have become an accepted standard^[12,30]. However, in a few centers in highly selected IVDA IE patients, with appropriate counseling and monitoring, it was possible to treat with outpatient parenteral antibiotic therapy using peripherally inserted central catheter lines^[31]. Poly-microbial endocarditis is more frequent in IVDA, which may need long-term suppressive therapy, specifically if fungal endocarditis is present^[32]. The most important organisms in poly-microbial IE in IVDAs are: Staphylococcus aureus, Streptococcus pneumoniae and Pseudomonas aeruginosa, as well as mixed cultures of Candida spp. and bacteria^[33].

The European Society for Cardiology guidelines made

some recommendations for operative indications for TVE in the active stage. These recommendations are: (1) refractory right heart failure secondary to severe persistent TR; (2) IE caused by organisms which are difficult to eradicate (*e.g.*, persistent fungi) or bacteremia for at least 7 d despite adequate antibiotic therapy; and (3) TV vegetations > 20 mm which persist after recurrent pulmonary emboli with or without concomitant right heart failure^[9]. Surgical options include vegetectomy, valvectomy, valve repair/reconstruction with annuloplasty ring or replacement (either mechanical or bioprosthesis valves)^[29,34]. A few authors opine that in IVDAs, vegetectomy and valve repair is preferred, avoiding artificial material and thus preventing prosthetic valve endocarditis^[29,35,36]. If a valve replacement is done, some authors prefer a bioprosthesis valve as it could be better in terms of prognosis than a mechanical valve^[36-38]. However, in a few studies, both mechanical and bioprosthesis valves have been successfully implanted in IVDAs with a similar 15 year survival (47.8% for mechanical *vs* 46.7% for bioprosthesis valves) and re-operation free survival (53% for mechanical *vs* 52% for bioprosthesis valves)^[39,40].

Prognosis in TVE is generally good and in-hospital mortality is less than 10%^[9-14]. Vegetation length > 20 mm and fungal etiology were found to be the main predictors of death in right sided IE in IVDAs^[41,42]. In the ICE-PCS registry, 22% of TVE patients needed surgery and in-hospital mortality was 6%^[15]. In patients with IE and HIV infection, there was higher total mortality at 2 mo, specifically in those with a CD4 count below 200 per microl^[43,44]. In addition, any left sided involvement and age greater than 35 years are independently associated with mortality^[45-47]. In a study, IVDAs with IE admitted to intensive care unit had very high mortality (27%), mainly due to sepsis and septic embolization^[48]. In patients with repeated IVDA and endocarditis, the prognosis is poor and few authors are of the opinion that these patients should be offered valve replacement only once. If they develop a second episode of endocarditis, they should not be offered another valve replacement surgery^[49,50].

CONCLUSION

In conclusion, recent reports indicate increasing trends in IVDA in the Middle East region. However, there is lack of reports about TVE, probably due to underdiagnosis or underreporting. TVE can mimic other respiratory diseases and may mislead in obtaining early diagnosis. A high index of suspicion of TVE is essential in patients with IVDA. In addition to already prevailing regulations and strict laws against drug trafficking in the Middle East Gulf region, programs to increase public awareness about the harmful effects of drug abuse are essential. Furthermore, a de-addiction drive among the youth in this region, anti-drug campaigns and the establishment of more rehabilitation centers are the need of the hour for eradicating this menace.

REFERENCES

- 1 **UN Office on Drugs and Crime.** World drug report 2011. Available from: URL: <http://www.humansecuritygateway.com/showRecord.php?RecordId=35492>
- 2 **Degenhardt L, Hall W.** Extent of illicit drug use and dependence, and their contribution to the global burden of disease. *Lancet* 2012; **379**: 55-70 [PMID: 22225671 DOI: 10.1016/S0140-6736(11)61138-0]
- 3 **World Health Organization.** Available from: URL: <http://www.emro.who.int/health-topics/substance-abuse/index.html>
- 4 **Maryam Mirza.** UAE drug trend claims younger victims. Available from: URL: <http://gulfnews.com/news/gulf/uae/crime/uae-drug-trend-claims-younger-victims-1.1169631>
- 5 **Muscat Daily staff writer.** Number of women drug addicts on the rise in Oman, October 21, 2012-10-21. Available from: URL: <http://www.muscatdaily.com/Archive/Oman/Number-of-women-drug-addicts-on-the-rise-in-Oman-1s4y>
- 6 Available from: URL: <http://www.mapinc.org/drugnews/v02.n1485.a02.html>
- 7 **Bajwa HZ, Al-Turki AS, Dawas AM, Behbehani MQ, Al-Mutairi AM, Al-Mahmoud S, Shukkur M, Thalib L.** Prevalence and factors associated with the use of illicit substances among male university students in Kuwait. *Med Princ Pract* 2013; **22**: 458-463 [PMID: 23635908]
- 8 **Hoen B, Alla F, Selton-Suty C, Béguinot I, Bouvet A, Briancçon S, Casalta JP, Danchin N, Delahaye F, Etienne J, Le Moing V, Lepout C, Mainardi JL, Ruimy R, Vandenesch F.** Changing profile of infective endocarditis: results of a 1-year survey in France. *JAMA* 2002; **288**: 75-81 [PMID: 12090865]
- 9 **Habib G, Hoen B, Tornos P, Thuny F, Prendergast B, Vilacosta I, Moreillon P, de Jesus Antunes M, Thilen U, Lekakis J, Lengyel M, Müller L, Naber CK, Nihoyannopoulos P, Moritz A, Zamorano JL.** Guidelines on the prevention, diagnosis, and treatment of infective endocarditis (new version 2009): the Task Force on the Prevention, Diagnosis, and Treatment of Infective Endocarditis of the European Society of Cardiology (ESC). Endorsed by the European Society of Clinical Microbiology and Infectious Diseases (ESCMID) and the International Society of Chemotherapy (ISC) for Infection and Cancer. *Eur Heart J* 2009; **30**: 2369-2413 [PMID: 19713420 DOI: 10.1093/eurheartj/ehp285]
- 10 **Frontera JA, Gradon JD.** Right-side endocarditis in injection drug users: review of proposed mechanisms of pathogenesis. *Clin Infect Dis* 2000; **30**: 374-379 [PMID: 10671344]
- 11 **Moss R, Munt B.** Injection drug use and right sided endocarditis. *Heart* 2003; **89**: 577-581 [PMID: 12695478]
- 12 **Baddour LM, Wilson WR, Bayer AS, Fowler VG, Bolger AF, Levison ME, Ferrieri P, Gerber MA, Tani LY, Gewitz MH, Tong DC, Steckelberg JM, Baltimore RS, Shulman ST, Burns JC, Falace DA, Newburger JW, Pallasch TJ, Takahashi M, Taubert KA.** Infective endocarditis: diagnosis, antimicrobial therapy, and management of complications: a statement for healthcare professionals from the Committee on Rheumatic Fever, Endocarditis, and Kawasaki Disease, Council on Cardiovascular Disease in the Young, and the Councils on Clinical Cardiology, Stroke, and Cardiovascular Surgery and Anesthesia, American Heart Association: endorsed by the Infectious Diseases Society of America. *Circulation* 2005; **111**: e394-e434 [PMID: 15956145]
- 13 **Ruotsalainen E, Sammalkorpi K, Laine J, Huotari K, Sarna S, Valtonen V, Järvinen A.** Clinical manifestations and outcome in *Staphylococcus aureus* endocarditis among injection drug users and nonaddicts: a prospective study of 74 patients. *BMC Infect Dis* 2006; **6**: 137 [PMID: 16965625]
- 14 **Miró JM, del Río A, Mestres CA.** Infective endocarditis and cardiac surgery in intravenous drug abusers and HIV-1 infected patients. *Cardiol Clin* 2003; **21**: 167-184, v-vi [PMID: 12695625]

- 12874891]
- 15 **Murdoch DR**, Corey GR, Hoen B, Miró JM, Fowler VG, Bayer AS, Karchmer AW, Olaison L, Pappas PA, Moreillon P, Chambers ST, Chu VH, Falcó V, Holland DJ, Jones P, Klein JL, Raymond NJ, Read KM, Tripodi MF, Utili R, Wang A, Woods CW, Cabell CH. Clinical presentation, etiology, and outcome of infective endocarditis in the 21st century: the International Collaboration on Endocarditis-Pro prospective Cohort Study. *Arch Intern Med* 2009; **169**: 463-473 [PMID: 19273776 DOI: 10.1001/archinternmed.2008.603]
- 16 **Suleiman K J**, Prashanth P. The Pattern of Infective Endocarditis in a Tertiary Care Hospital in Oman: A Ten-Year Prospective Study. *Heart Views* 2003; **4**: 3
- 17 **Khaled AA**, Al-Noami AY, Al-Ansi M, Faiza AA. Clinical features and outcome of infective endocarditis in yemeni patients treated with empirical antibiotic therapy. *Heart Views* 2010; **11**: 2-9 [PMID: 21042457]
- 18 **Kiwan YA**, Hayat N, Vijayaraghavan DG, Das Chugh T, Khan N, Mualla F, Madi S. Infective endocarditis: a prospective study of 60 consecutive cases. *Mater Med Pol* 1990; **22**: 173-175 [PMID: 2132422]
- 19 **Al-Tawfiq JA**, Sufi I. Infective endocarditis at a hospital in Saudi Arabia: epidemiology, bacterial pathogens and outcome. *Ann Saudi Med* 2009; **29**: 433-436 [PMID: 19847079 DOI: 10.4103/0256-4947.57164]
- 20 **Nashmi A**, Memish ZA. Infective endocarditis at a tertiary care centre in Saudi Arabia: review of 47 cases over 10 years. *East Mediterr Health J* 2007; **13**: 64-71 [PMID: 17546907]
- 21 **Kanafani ZA**, Mahfouz TH, Kanj SS. Infective endocarditis at a tertiary care centre in Lebanon: predominance of streptococcal infection. *J Infect* 2002; **45**: 152-159 [PMID: 12387770]
- 22 **Panduranga P**, Al-Mukhaini M, Sulaiman K, Al-Abri S. Tricuspid valve endocarditis in an intravenous drug abuser masquerading as pulmonary tuberculosis. *Heart Views* 2010; **11**: 121-124 [PMID: 21577381 DOI: 10.4103/1995-705X.76805]
- 23 **San Román JA**, Vilacosta I, López J, Revilla A, Arnold R, Sevilla T, Rollán MJ. Role of transthoracic and transesophageal echocardiography in right-sided endocarditis: one echocardiographic modality does not fit all. *J Am Soc Echocardiogr* 2012; **25**: 807-814 [PMID: 22727494 DOI: 10.1016/j.echo.2012.05.016]
- 24 **Bassetti S**, Battagay M. Staphylococcus aureus infections in injection drug users: risk factors and prevention strategies. *Infection* 2004; **32**: 163-169 [PMID: 15188077]
- 25 **Rodriguez R**, Alter H, Romero KL, Kea B, Chiang W, Fortman J, Marks C, Cheung P, Conti S. A pilot study to develop a prediction instrument for endocarditis in injection drug users admitted with fever. *Am J Emerg Med* 2011; **29**: 894-898 [PMID: 20685064 DOI: 10.1016/j.ajem.2010.04.006]
- 26 **Robbins MJ**, Soeiro R, Frishman WH, Strom JA. Right-sided valvular endocarditis: etiology, diagnosis, and an approach to therapy. *Am Heart J* 1986; **111**: 128-135 [PMID: 3946140]
- 27 **Koh YX**, Chng JK, Tan SG. A rare case of septic deep vein thrombosis in the inferior vena cava and the left iliac vein in an intravenous drug abuser. *Ann Vasc Dis* 2012; **5**: 389-392 [PMID: 23555542 DOI: 10.3400/avd.cr.12.00036]
- 28 **Johri AM**, Kovacs KA, Kafka H. An unusual case of infective endocarditis: extension of a tricuspid valve vegetation into the left atrium through a patent foramen ovale. *Can J Cardiol* 2009; **25**: 429-431 [PMID: 19584975]
- 29 **Gottardi R**, Bialy J, Devyatko E, Tschernich H, Czerny M, Wolner E, Seitelberger R. Midterm follow-up of tricuspid valve reconstruction due to active infective endocarditis. *Ann Thorac Surg* 2007; **84**: 1943-1948 [PMID: 18036912]
- 30 **Yung D**, Kottachchi D, Neupane B, Haider S, Loeb M. Antimicrobials for right-sided endocarditis in intravenous drug users: a systematic review. *J Antimicrob Chemother* 2007; **60**: 921-928 [PMID: 17881630]
- 31 **Ho J**, Archuleta S, Sulaiman Z, Fisher D. Safe and successful treatment of intravenous drug users with a peripherally inserted central catheter in an outpatient parenteral antibiotic treatment service. *J Antimicrob Chemother* 2010; **65**: 2641-2644 [PMID: 20864497 DOI: 10.1093/jac/dkq355]
- 32 **Popescu GA**, Prazuck T, Poisson D, Picu C. A "true" polymicrobial endocarditis: *Candida tropicalis* and *Staphylococcus aureus*--to a drug user. Case presentation and literature review. *Rom J Intern Med* 2005; **43**: 157-161 [PMID: 16739876]
- 33 **Sousa C**, Botelho C, Rodrigues D, Azeredo J, Oliveira R. Infective endocarditis in intravenous drug abusers: an update. *Eur J Clin Microbiol Infect Dis* 2012; **31**: 2905-2910 [PMID: 22714640 DOI: 10.1007/s10096-012-1675-x]
- 34 **Morokuma H**, Minato N, Kamohara K, Minematsu N. Three surgical cases of isolated tricuspid valve infective endocarditis. *Ann Thorac Cardiovasc Surg* 2010; **16**: 134-138 [PMID: 20930670]
- 35 **Akinosoglou K**, Apostolakis E, Koutsogiannis N, Leivaditis V, Gogos CA. Right-sided infective endocarditis: surgical management. *Eur J Cardiothorac Surg* 2012; **42**: 470-479 [PMID: 22427390 DOI: 10.1093/ejcts/ezs084]
- 36 **Musci M**, Siniawski H, Pasic M, Grauhan O, Weng Y, Meyer R, Yankah CA, Hetzer R. Surgical treatment of right-sided active infective endocarditis with or without involvement of the left heart: 20-year single center experience. *Eur J Cardiothorac Surg* 2007; **32**: 118-125 [PMID: 17412606]
- 37 **Kaiser SP**, Melby SJ, Zierer A, Schuessler RB, Moon MR, Moazami N, Pasque MK, Huddleston C, Damiano RJ, Lawton JS. Long-term outcomes in valve replacement surgery for infective endocarditis. *Ann Thorac Surg* 2007; **83**: 30-35 [PMID: 17184626]
- 38 **Rabkin DG**, Mokadam NA, Miller DW, Goetz RR, Verrier ED, Aldea GS. Long-term outcome for the surgical treatment of infective endocarditis with a focus on intravenous drug users. *Ann Thorac Surg* 2012; **93**: 51-57 [PMID: 22054655 DOI: 10.1016/j.athoracsur.2011.08.016]
- 39 **Rizzoli G**, Vendramin I, Nesseris G, Bottio T, Guglielmi C, Schiavon L. Biological or mechanical prostheses in tricuspid position? A meta-analysis of intra-institutional results. *Ann Thorac Surg* 2004; **77**: 1607-1614 [PMID: 15111151]
- 40 **Carrier M**, Hébert Y, Pellerin M, Bouchard D, Perrault LP, Cartier R, Basmajian A, Pagé P, Poirier NC. Tricuspid valve replacement: an analysis of 25 years of experience at a single center. *Ann Thorac Surg* 2003; **75**: 47-50 [PMID: 12537191]
- 41 **Martín-Dávila P**, Navas E, Fortún J, Moya JL, Cobo J, Pintado V, Quereda C, Jiménez-Mena M, Moreno S. Analysis of mortality and risk factors associated with native valve endocarditis in drug users: the importance of vegetation size. *Am Heart J* 2005; **150**: 1099-1106 [PMID: 16291005]
- 42 **Okonta KE**, Adamu YB. What size of vegetation is an indication for surgery in endocarditis? *Interact Cardiovasc Thorac Surg* 2012; **15**: 1052-1056 [PMID: 22962320 DOI: 10.1093/icvts/ivs365]
- 43 **Cecchi E**, Imazio M, Tidu M, Forno D, De Rosa FG, Dal Conte I, Preziosi C, Lipani F, Trincherio R. Infective endocarditis in drug addicts: role of HIV infection and the diagnostic accuracy of Duke criteria. *J Cardiovasc Med (Hagerstown)* 2007; **8**: 169-175 [PMID: 17312433]
- 44 **Yasar KK**, Pehlivanoglu F, Gursoy S, Sengoz G. Tricuspid Endocarditis and Septic Pulmonary Embolism in an Intravenous Drug User with advanced HIV Infection. *Oman Med J* 2011; **26**: 365-367 [PMID: 22125735 DOI: 10.5001/omj.2011.90]
- 45 **De Rosa FG**, Cicalini S, Canta F, Audagnotto S, Cecchi E, Di Perri G. Infective endocarditis in intravenous drug users from Italy: the increasing importance in HIV-infected patients. *Infection* 2007; **35**: 154-160 [PMID: 17565456]
- 46 **Thalme A**, Westling K, Julander I. In-hospital and long-term mortality in infective endocarditis in injecting drug users compared to non-drug users: a retrospective study of 192 episodes. *Scand J Infect Dis* 2007; **39**: 197-204 [PMID:

- 17366047]
- 47 **Kamaledeen A**, Young C, Attia RQ. What are the differences in outcomes between right-sided active infective endocarditis with and without left-sided infection? *Interact Cardiovasc Thorac Surg* 2012; **14**: 205-208 [PMID: 22159232 DOI: 10.1093/icvts/ivr012]
 - 48 **Saydain G**, Singh J, Dalal B, Yoo W, Levine DP. Outcome of patients with injection drug use-associated endocarditis admitted to an intensive care unit. *J Crit Care* 2010; **25**: 248-253 [PMID: 19906509 DOI: 10.1016/j.jcrc.2009.09.007]
 - 49 **Yeo KK**, Chang WJ, Lau JM, Tan SY. Valve replacement in endocarditis: setting limits in noncompliant intravenous drug abusers. *Hawaii Med J* 2006; **65**: 168, 170-171 [PMID: 16895269]
 - 50 **Bromage DI**, McLauchlan DJ, Nightingale AK. Do cardiologists and cardiac surgeons need ethics? Achieving happiness for a drug user with endocarditis. *Heart* 2009; **95**: 885-887 [PMID: 19168473 DOI: 10.1136/hrt.2008.163782]

P-Reviewer: Castillo R **S-Editor:** Zhai HH
L-Editor: Roemmele A **E-Editor:** Wang CH





Published by **Baishideng Publishing Group Co., Limited**
Flat C, 23/F., Lucky Plaza,
315-321 Lockhart Road, Wan Chai, Hong Kong, China
Fax: +852-65557188
Telephone: +852-31779906
E-mail: bpgoffice@wjgnet.com
<http://www.wjgnet.com>

