

World Journal of *Clinical Cases*

World J Clin Cases 2018 November 26; 6(14): 716-868





REVIEW

- 716 Current status of surgical treatment of colorectal liver metastases
Xu F, Tang B, Jin TQ, Dai CL

MINIREVIEWS

- 735 The assessment of endosonographers in training
Hedenström P, Sadik R
- 745 Necroptosis in inflammatory bowel disease and other intestinal diseases
Li S, Ning LG, Lou XH, Xu GQ

ORIGINAL ARTICLE

Case Control Study

- 753 Benefits of the Seattle biopsy protocol in the diagnosis of Barrett's esophagus in a Chinese population
Lee SW, Lien HC, Chang CS, Lin MX, Chang CH, Ko CW

Retrospective Study

- 759 Modified laparoscopic Sugarbaker repair of parastomal hernia with a three-point anchoring technique
Huang DY, Pan L, Chen QL, Cai XY, Fang J

SYSTEMATIC REVIEWS

- 767 Safety of laparoscopic surgery in digestive diseases with special reference to antithrombotic therapy: A systematic review of the literature
Fujikawa T, Ando K

CASE REPORT

- 776 Epstein-Barr virus-associated hemophagocytic syndrome in a patient with ulcerative colitis during treatment with azathioprine: A case report and review of literature
Miyaguchi K, Yamaoka M, Tsuzuki Y, Ashitani K, Ohgo H, Miyagawa Y, Ishizawa K, Kayano H, Nakamoto H, Imaeda H
- 781 Acquired hemophilia A in solid cancer: Two case reports and review of the literature
Saito M, Ogasawara R, Izumiyama K, Mori A, Kondo T, Tanaka M, Morioka M, Ieko M
- 786 Glutaric acidemia type II patient with thalassemia minor and novel electron transfer flavoprotein-A gene mutations: A case report and review of literature
Saral NY, Aksungar FB, Aktuglu-Zeybek C, Coskun J, Demirelce O, Serteser M

- 791** Meckel's diverticulum diagnosis by video capsule endoscopy: A case report and review of literature
García-Compeán D, Jiménez-Rodríguez AR, Del Cueto-Aguilera ÁN, Herrera-Quñones G, González-González JA, Maldonado-Garza HJ
- 800** Carney complex: Two case reports and review of literature
Li S, Duan L, Wang FD, Lu L, Jin ZY
- 807** Ileal bronchogenic cyst: A case report and review of literature
Chen HY, Fu LY, Wang ZJ
- 811** Application of ultrasound in aggressive angiomyxoma: Eight case reports and review of literature
Zhao CY, Su N, Jiang YX, Yang M
- 820** Solitary rectal ulcer syndrome complicating sessile serrated adenoma/polyps: A case report and review of literature
Sun H, Sheng WQ, Huang D
- 825** Subdural empyema complicated with intracranial hemorrhage in a postradiotherapy nasopharyngeal carcinoma patient: A case report and review of literature
Chen JC, Tan DH, Xue ZB, Yang SY, Li Y, Lai RL
- 830** Giant monostotic osteofibrous dysplasia of the ilium: A case report and review of literature
Liu YB, Zou TM
- 836** Postoperative redislocation of the hip in a patient with congenital insensitivity to pain with anhidrosis: A case report and review of literature
Wang R, Liu Y, Zhou YY, Wang JY, Xu ZJ, Chen SY, Wang QQ, Yuan P
- 842** Open surgical treatment of choledochocoele: A case report and review of literature
Yang J, Xiao GF, Li YX
- 847** Mesenteric heterotopic pancreas in a pediatric patient: A case report and review of literature
Tang XB, Liao MY, Wang WL, Bai YZ
- 854** Intralesional and topical glucocorticoids for pretibial myxedema: A case report and review of literature
Zhang F, Lin XY, Chen J, Peng SQ, Shan ZY, Teng WP, Yu XH



- 862** Octreotide reverses shock due to vasoactive intestinal peptide-secreting adrenal pheochromocytoma: A case report and review of literature

Hu X, Cao W, Zhao M

ABOUT COVER

Editorial Board Member of *World Journal of Clinical Cases*, Manabu Watanabe, MD, PhD, Full Professor, Division of Gastroenterology and Hepatology, Department of Internal medicine, Toho University Medical Center, Ohashi Hospital, Tokyo 153-8515, Japan

AIM AND SCOPE

World Journal of Clinical Cases (*World J Clin Cases*, *WJCC*, online ISSN 2307-8960, DOI: 10.12998) is a peer-reviewed open access academic journal that aims to guide clinical practice and improve diagnostic and therapeutic skills of clinicians.

The primary task of *WJCC* is to rapidly publish high-quality Autobiography, Case Report, Clinical Case Conference (Clinicopathological Conference), Clinical Management, Diagnostic Advances, Editorial, Field of Vision, Frontier, Medical Ethics, Original Articles, Clinical Practice, Meta-Analysis, Minireviews, Review, Therapeutics Advances, and Topic Highlight, in the fields of allergy, anesthesiology, cardiac medicine, clinical genetics, clinical neurology, critical care, dentistry, dermatology, emergency medicine, endocrinology, family medicine, gastroenterology and hepatology, geriatrics and gerontology, hematology, immunology, infectious diseases, internal medicine, obstetrics and gynecology, oncology, ophthalmology, orthopedics, otolaryngology, pathology, pediatrics, peripheral vascular disease, psychiatry, radiology, rehabilitation, respiratory medicine, rheumatology, surgery, toxicology, transplantation, and urology and nephrology.

INDEXING/ABSTRACTING

World Journal of Clinical Cases (*WJCC*) is now indexed in PubMed, PubMed Central, Science Citation Index Expanded (also known as SciSearch®), and Journal Citation Reports/Science Edition. The 2018 Edition of Journal Citation Reports cites the 2017 impact factor for *WJCC* as 1.931 (5-year impact factor: N/A), ranking *WJCC* as 60 among 154 journals in Medicine, General and Internal (quartile in category Q2).

EDITORS FOR THIS ISSUE

Responsible Assistant Editor: *Xiang Li*
Responsible Electronic Editor: *Han Song*
Proofing Editor-in-Chief: *Lian-Sheng Ma*

Responsible Science Editor: *Fang-Fang Ji*
Proofing Editorial Office Director: *Jin-Lei Wang*

NAME OF JOURNAL
World Journal of Clinical Cases

ISSN
ISSN 2307-8960 (online)

LAUNCH DATE
April 16, 2013

FREQUENCY
Semimonthly

EDITORS-IN-CHIEF
Sandro Vento, MD, Department of Internal Medicine, University of Botswana, Private Bag 00713, Gaborone, Botswana

EDITORIAL BOARD MEMBERS
All editorial board members resources online at <http://www.wjgnet.com/2307-8960/editorialboard.htm>

EDITORIAL OFFICE
Jin-Lei Wang, Director

World Journal of Clinical Cases
Baishideng Publishing Group Inc
7901 Stoneridge Drive, Suite 501, Pleasanton, CA 94588, USA
Telephone: +1-925-2238242
Fax: +1-925-2238243
E-mail: editorialoffice@wjgnet.com
Help Desk: <http://www.f6publishing.com/helpdesk>
<http://www.wjgnet.com>

PUBLISHER
Baishideng Publishing Group Inc
7901 Stoneridge Drive, Suite 501, Pleasanton, CA 94588, USA
Telephone: +1-925-2238242
Fax: +1-925-2238243
E-mail: bpgoffice@wjgnet.com
Help Desk: <http://www.f6publishing.com/helpdesk>
<http://www.wjgnet.com>

PUBLICATION DATE
November 26, 2018

COPYRIGHT

© 2018 Baishideng Publishing Group Inc. Articles published by this Open Access journal are distributed under the terms of the Creative Commons Attribution Non-commercial License, which permits use, distribution, and reproduction in any medium, provided the original work is properly cited, the use is non commercial and is otherwise in compliance with the license.

SPECIAL STATEMENT

All articles published in journals owned by the Baishideng Publishing Group (BPG) represent the views and opinions of their authors, and not the views, opinions or policies of the BPG, except where otherwise explicitly indicated.

INSTRUCTIONS TO AUTHORS

<http://www.wjgnet.com/bpg/gerinfo/204>

ONLINE SUBMISSION

<http://www.f6publishing.com>

Epstein–Barr virus-associated hemophagocytic syndrome in a patient with ulcerative colitis during treatment with azathioprine: A case report and review of literature

Kazuya Miyaguchi, Minoru Yamaoka, Yoshikazu Tsuzuki, Keigo Ashitani, Hideki Ohgo, Yoshitaka Miyagawa, Keisuke Ishizawa, Hidekazu Kayano, Hidetomo Nakamoto, Hiroyuki Imaeda

Kazuya Miyaguchi, Minoru Yamaoka, Yoshikazu Tsuzuki, Keigo Ashitani, Hideki Ohgo, Yoshitaka Miyagawa, Hidetomo Nakamoto, Hiroyuki Imaeda, Department of General Internal Medicine, Saitama Medical University, Iruma-gun 350-0495, Saitama, Japan

Yoshikazu Tsuzuki, Hideki Ohgo, Hiroyuki Imaeda, Department of Gastroenterology, Saitama Medical University, Iruma-gun 350-0495, Saitama, Japan

Keisuke Ishizawa, Hidekazu Kayano, Department of Pathology, Saitama Medical University, Iruma-gun 350-0495, Saitama, Japan

ORCID number: Kazuya Miyaguchi (0000-0003-0701-3608); Minoru Yamaoka (0000-0003-2350-5223); Yoshikazu Tsuzuki (0000-0003-3029-7469); Keigo Ashitani (0000-0002-5043-892X); Hideki Ohgo (0000-0002-3916-2918); Yoshitaka Miyagawa (0000-0002-4429-7227); Keisuke Ishizawa (0000-0003-4751-7691); Shuichi Kayano (0000-0001-9349-4959); Hidetomo Nakamoto (0000-0003-3975-5067); Hiroyuki Imaeda (0000-0003-0898-6540).

Author contributions: Miyaguchi K was involved in data collection, data analysis, and writing up the first draft of the paper; Tsuzuki Y contributed towards data analysis, and patient follow-up in the out-patient unit; Yamaoka M contributed to medical treatment; Imaeda H supervised, and finalized the manuscript; all authors approved the final manuscript.

Informed consent statement: Written informed consent was obtained from the patient.

Conflict-of-interest statement: The authors have no conflicts of interest to declare.

CARE Checklist (2013) statement: This manuscript has completed the CARE Checklist (2013).

Open-Access: This article is an open-access article which was selected by an in-house editor and fully peer-reviewed by external reviewers. It is distributed in accordance with the Creative

Commons Attribution Non Commercial (CC BY-NC 4.0) license, which permits others to distribute, remix, adapt, build upon this work non-commercially, and license their derivative works on different terms, provided the original work is properly cited and the use is non-commercial. See: <http://creativecommons.org/licenses/by-nc/4.0/>

Manuscript source: Unsolicited manuscript

Corresponding author to: Yoshikazu Tsuzuki, FACC, MD, PhD, Associate Professor, Department of Gastroenterology, Saitama Medical University, 38 Morohongo, Moroyama-machi, Iruma-gun 350-0495, Saitama, Japan. ytsuzuki@saitama-med.ac.jp
Telephone: +81-49-2761667
Fax: +81-49-2761667

Received: June 22, 2018

Peer-review started: June 22, 2018

First decision: August 1, 2018

Revised: August 18, 2018

Accepted: October 8, 2018

Article in press: October 8, 2018

Published online: November 26, 2018

Abstract

A 19-year-old female was diagnosed with ulcerative colitis when she presented with persistent melena, and has been treated with 5-aminosalicylic acid for 4 years, with additional azathioprine for 2 years at our hospital. The patient experienced high-grade fevers, chills, and cough five d prior to presenting to the outpatient unit. At first, the patient was suspected to have developed neutropenic fever; however, she was diagnosed with Epstein-Barr virus-associated hemophagocytic syndrome (EB-VAHS) upon fulfilling the diagnostic criteria after bone marrow aspiration. When patients with

inflammatory bowel disease treated with immunomodulators, such as thiopurine preparations, develop fever, EB-VAHS should be considered in the differential diagnosis.

Key words: Inflammatory bowel disease; Azathioprine; Virus-associated hemophagocytic syndrome; Ulcerative colitis; Case report

© The Author(s) 2018. Published by Baishideng Publishing Group Inc. All rights reserved.

Core tip: A 19-year-old female was diagnosed with ulcerative colitis, and has been receiving treatment with 5-aminosalicylic acid for 4 years, with additional azathioprine for 2 years. The patient experienced high-grade fever five d prior to presenting to the outpatient unit. She was diagnosed with Epstein-Barr virus-associated hemophagocytic syndrome (VAHS). VAHS is one of the rare and life-threatening pathophysiological conditions induced by thiopurine treatment. In such cases, early diagnosis is necessary, along with management of therapy, and related complications. When patients with inflammatory bowel disease, treated with immunomodulators such as thiopurine preparations, demonstrate high fever, VAHS should be considered in the differential diagnosis.

Miyaguchi K, Yamaoka M, Tsuzuki Y, Ashitani K, Ohgo H, Miyagawa Y, Ishizawa K, Kayano H, Nakamoto H, Imaeda H. Epstein-Barr virus-associated hemophagocytic syndrome in a patient with ulcerative colitis during treatment with azathioprine: A case report and review of literature. *World J Clin Cases* 2018; 6(14): 776-780 Available from: URL: <http://www.wjgnet.com/2307-8960/full/v6/i14/776.htm> DOI: <http://dx.doi.org/10.12998/wjcc.v6.i14.776>

INTRODUCTION

Virus-associated hemophagocytic syndrome (VAHS) is an extremely rare and life-threatening complication, sometimes induced by viral infection. It is characterized by high-grade fever, hepatosplenomegaly, pancytopenia, and disseminated intravascular coagulation (DIC). The syndrome is diagnosed by the presence of histiocytosis in the lymphoreticular network (*i.e.*, the bone marrow)^[1]. The etiological agent is a virus, such as Epstein-Barr virus (EBV), cytomegalovirus (CMV), herpes zoster virus, human herpesvirus 6, rubella, measles virus, or influenza virus. Among them, Epstein-Barr VAHS (EB-VAHS) tends to be severe^[2].

Thiopurine formulations are reported to be effective for the long-term remission of inflammatory bowel disease (IBD)^[3]. However, side effects such as myelosuppression, hepatic dysfunction, pancreatitis, hair loss, and gastrointestinal symptoms are observed in approximately 3% of patients. In particular, myelosuppression is reported to occur within 2 mo of drug

administration^[4]. A recent report also suggested that patients with IBD receiving thiopurine treatment are at an increased risk of developing lymphoproliferative disorders^[5]. Therefore, it is necessary to consider the adverse effects of thiopurine treatment when fever, leukopenia, hepatic dysfunction, *etc.* are observed.

Here we report a case of EB-VAHS during the treatment of ulcerative colitis with drugs including azathioprine (AZA).

CASE REPORT

A 19-year-old female with frequent bloody stools presented to our hospital in 2017. She was diagnosed with ulcerative colitis (pancolitis) by total colonoscopy in 2013. The patient was treated with 3600 mg/d of 5-aminosalicylic acid (5-ASA) and went into remission. She experienced recurrence of bloody stools in 2015, and was treated with 50 mg/d of AZA. Although AZA treatment was initiated, the patient occasionally experienced bloody stools and prednisolone (PSL) was administered, after which her condition improved. The AZA dose was increased to 100 mg/d in 2016. Although she occasionally experienced bloody stools, her symptoms were relieved by additional administration of 5-ASA suppositories.

The patient was admitted to our hospital with fever, ocular pains, chills, and cough for 5 d prior to admission in 2017. Her neutrophil count had decreased to 589/ μ L, and leukocyte reduction was not evident in blood results 2 d before her symptoms started. The patient developed a fever of 38.8 °C, but showed no abnormalities in the chest and abdomen, with no observed cervical lymph node swelling.

The patient presented with fever, along with mild anemia [hemoglobin (Hb), 11.1 g/dL], mild thrombocytopenia (13.0×10^4 / μ L), mildly elevated C-reactive protein (CRP) (1.32 mg/dL), and neutropenia [white blood cell (WBC), 940/ μ L; neutrophils, 589/ μ L].

Colonoscopy revealed that the mucosa was mildly inflamed only on the left side of the colon; the endoscopic subscore was Mayo score 1 (Figure 1). The patient was treated with 2 g/d of cefepime and granulocyte-colony stimulating factor (G-CSF), but her WBC and neutrophil counts improved only to 2650/ μ L, and 1661/ μ L, respectively. The fever persisted, and her condition was complicated by the appearance of right cervical lymphadenopathy. Splenomegaly and splenic infarction were observed *via* thoracoabdominal contrast computed tomography scanning (Figure 2). In addition, liver dysfunction (Aspartate transaminase, 225 IU/L; alanine aminotransferase, 200 IU/L), and increases in lactate dehydrogenase (LDH) (589 IU/L), ferritin (740 ng/mL), and soluble interleukin 2 receptor (sIL-2R) (5210 IU/mL) were observed on biochemical examination. Aggravated anemia (Hb, 9.4 g/dL), thrombocytopenia (8×10^4 / μ L), and the appearance of atypical lymphocytes (Aty-Lym, 2%) were also

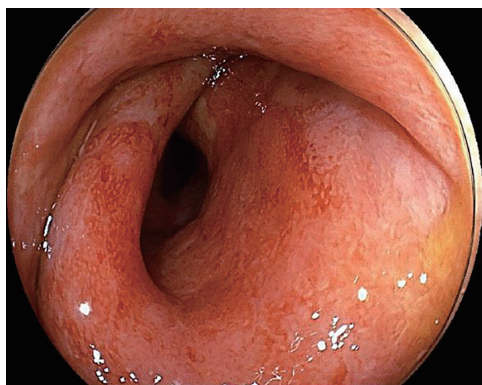


Figure 1 Colonoscopy showing diffuse redness, disappearance of vasculature, and mucosal edema in the descending colon-rectum, suggesting a Mayo Endoscopic Subscore of 1.

observed on peripheral blood examination. Bone marrow smear examination showed an increase in foamy macrophages, and blood cell phagocytosis (Figure 3), but no chromosomal abnormalities. Furthermore, antibody test results, were suggestive of primary acute EBV infection, as follows: EB immunoglobulin M (EB-IgM) positive, EB-IgG positive, EB nuclear antigen (EBNA) negative, and EB deoxyribonucleic acid (EB-DNA) positive (1.0×10^4 copies/mL). CMV IgG was negative. The diagnostic criteria for VAHS are as follows: (1) blood cell phagocytosis, myelocyte phagocytosis; (2) elevated ferritin; and (3) elevated sIL-2R levels (≥ 2400 IU/mL). Taken together, the patient was diagnosed with EB-VAHS. The patient was treated with steroid pulse therapy (methylprednisolone 1000 mg/d for 3 d), and her symptoms and examination findings improved. After pulse therapy, PSL was tapered gradually from 60 mg/d. The follow-up lab examination data after improvement from VAHS was as follows: WBC $6720/\mu\text{L}$, Hb 13.4 g/dL, platelet 16.2×10^4 , LDH 175U/L, At-Lym negative, EB-virus capsid antigen (EB-VCA) IgM negative, EB-VCA IgG positive ($\times 40$), EBNA 1.3C.I, EB-DNA positive, ferritin 18 ng/mL, sIL-2R 290 IU/mL. The patient was discharged after a couple of weeks and was followed-up in the outpatient unit.

DISCUSSION

The initial diagnosis was neutropenic fever accompanied by bone marrow suppression, probably due to AZA administration. However, bone marrow suppression by AZA often occurs within 2 mo of initiation, however here, 1 year had passed since AZA was increased from 50 mg to 100 mg before bone marrow suppression was evident. In addition, the patient showed only minor improvement to white blood cell, and neutrophil counts, while fever persisted during G-CSF treatment. The diagnosis of VAHS was made based on symptoms such as cervical lymph node swelling, splenomegaly, hepatic dysfunction, pancytopenia, elevated LDH, elevated ferritin, elevated sIL-2R, and the appearance of At-Lym. However, a bone marrow biopsy was

required to make a definite diagnosis. Although the mechanism of VAHS is yet to be completely elucidated, it is reported that activation of T-cells, as well as macrophage proliferation, and the production of cytokines triggered by viral infection such as EBV are responsible for characteristic symptoms like high-grade fever, hepatosplenomegaly, pancytopenia, and DIC^[1]. These symptoms could be related to disease severity^[6]. Therefore, when VAHS is strongly suspected by clinical findings, it is recommended that treatment should be initiated before fulfilling the diagnostic criteria^[7]. The treatment for VAHS is divided into four steps^[1]. First, steroid such as cyclosporine and etoposide are administered to control the resultant hypercytokinemia, and plasma exchange may be considered if hypercytokinemia is resistant to initial treatment. Second, if there is a virus-specific treatment, the etiological virus should be targeted. Third, if the virus is refractory to treatment, removal of virus-infected lymphocytes by CHOP therapy (cyclophosphamide, doxorubicin, vincristine, and prednisone), according to treatment for malignant lymphoma, should be considered. Fourth, supportive therapy for secondary infection, DIC, and central nervous symptom and hepatic disorders may be considered.

Eight cases of CMV infection and five of EBV infection have been reported to be VAHS cases after AZA administration during ulcerative colitis treatment^[8-15]; however, the etiological virus is unknown in most cases. There have also been reports that it is unknown whether the syndrome is caused due to acute or chronic infection, however, most cases are positive for both IgM and IgG. Therefore, the pathology of VAHS is thought to be mainly caused by reactivation of chronic viral infection, although VAHS could also occur due to acute viral infection. In the present case, EB-IgM was positive and EBNA was negative; therefore, this case of VAHS was caused by primary acute infection. It is difficult to diagnose VAHS in many cases, and the syndrome occurs during remission rather than immediately after AZA administration. Prognosis greatly differs between EBV-, and non-EBV-associated cases and 70% of non-EBV-associated cases are reported to be cured only by supportive therapy^[2]. In contrast, in EBV-associated cases, a more severe course was observed and 4 of 16 patients with VAHS died during IBD therapy^[9,12,14,15]. Old age, DIC, elevated ferritin, thrombocytopenia, anemia, jaundice, and chromosomal abnormalities are frequently observed, and are poor prognostic factors^[15]. Some studies reported chromosomal abnormalities after chromosome analysis of bone marrow cells revealed an abnormal karyotype, although none were specific. In the present case, no DIC or chromosomal abnormalities were observed, and the clinical course was well controlled. The factors responsible for VAHS in patients with IBD are as follows: (1) mucosal immune systems, such as immune tolerance in the intestinal tract, are destroyed due to IBD; (2) immunomodulating drug therapy increases susceptibility too many infections

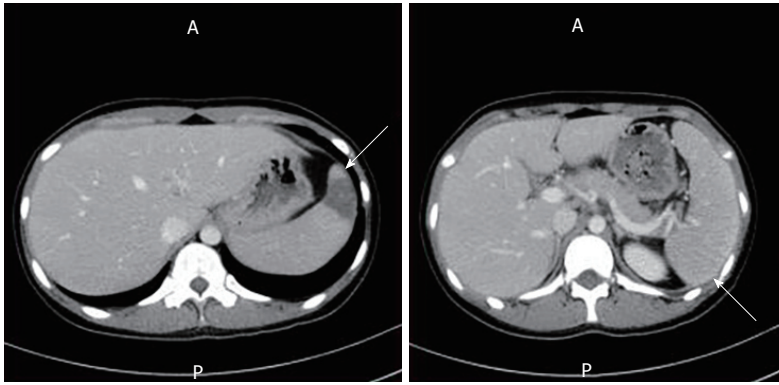


Figure 2 Thoracoabdominal contrast computed tomography scanning. Computed tomography scan showing an area of low density in the spleen, suggesting splenic infarction (left arrow) and splenomegaly (right arrow).

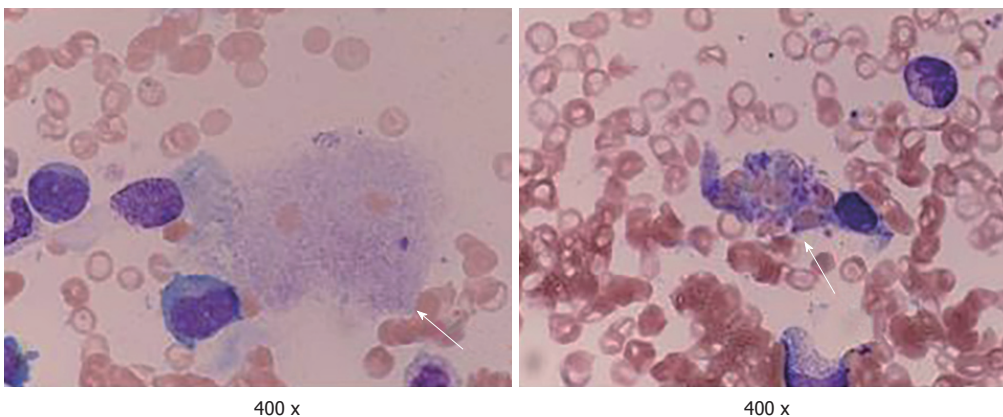


Figure 3 Hematoxylin and Eosin staining (400 × magnification) in the specimen of bone marrow smear. It shows the increase in macrophages (left arrow) and hemophagocytosis (right arrow).

including opportunistic infections; (3) once viral infection occurs, the pathogen-exclusion mechanism does not function well, and the immune response loses efficacy.

Therefore, long-term AZA administration might trigger EB infection and induce VAHS. However, to prove this theory, one needs to demonstrate an immunosuppressive state at the time of EB infection, and the subsequent exponential cytokine storm after EB infection, leading to VAHS.

VAHS is a rare but potentially life-threatening complication of EBV infection. Although this syndrome is also rare in patients with IBD treated with thiopurine preparations, administration of immunosuppressants or immunomodulators may increase the risk of viral infection.

Therefore, when high-grade fever, cytopenia, and elevated liver enzyme, ferritin, and LDH levels are observed in patients with ulcerative colitis treated with thiopurine preparations, VAHS should be considered in the differential diagnosis if CMV or EBV infection is confirmed. In addition, it should be remembered that hemophagocytosis is a fatal disease and caution should always be implemented to avoid this fatal consequences.

ARTICLE HIGHLIGHTS

Case characteristics

19-year-old female presented high-grade fevers, chills, and cough five d prior to presenting to the outpatient unit.

Clinical diagnosis

Patient was diagnosed with Epstein-Barr virus-associated hemophagocytic syndrome upon fulfilling the diagnostic criteria after bone marrow aspiration, during the treatment with azathioprine (AZA) for UC.

Differential diagnosis

Febrile neutropenia.

Laboratory diagnosis

Pancytopenia (white blood cell, 2650/ μ L; hemoglobin, 9.4 g/dL; platelet, 8.0×10^4); lactate dehydrogenase, 589 U/L; atypical lymphocytes, 2.0%; Epstein-Barr virus capsid antigen immunoglobulin M (EB-VCA-IgM), positive; EB-VCA-IgG, positive; EB nuclear antigen, negative; EB deoxyribonucleic acid, positive (1.0×10^4 copies/mL); blood cell phagocytosis; myelocyte phagocytosis; ferritin elevation; and elevated soluble interleukin 2 receptor (≥ 2400 IU/mL).

Imaging diagnosis

Contrast computed tomography showed spleen swelling and spleen infarction.

Pathological findings

Bone marrow examination confirmed blood cell phagocytosis.

Treatment

Steroid pulse therapy and post-steroid therapy.

Related reports

A case report by N'guyen *et al*^[11] suggests that EBV-specific clinical and virological management should be considered when treating a patient with IBD with AZA.

Term explanation

VAHS is a rare pathophysiological condition induced by thiopurine treatment for IBD, caused by excessive lymphocytic cytokine production during viral infection.

Experience and lessons

VAHS should be included in the differential diagnosis during thiopurine treatment for IBD.

REFERENCES

- 1 **Ramos-Casals M**, Brito-Zerón P, López-Guillermo A, Khamashta MA, Bosch X. Adult haemophagocytic syndrome. *Lancet* 2014; **383**: 1503-1516 [PMID: 24290661 DOI: 10.1016/S0140-6736(13)61048-X]
- 2 **Fisman DN**. Hemophagocytic syndromes and infection. *Emerg Infect Dis* 2000; **6**: 601-608 [PMID: 11076718 DOI: 10.3201/eid0606.000608]
- 3 **Timmer A**, McDonald JW, Tsoulis DJ, Macdonald JK. Azathioprine and 6-mercaptopurine for maintenance of remission in ulcerative colitis. *Cochrane Database Syst Rev* 2012; CD000478 [PMID: 22972046 DOI: 10.1002/14651858.CD000478.pub3]
- 4 **Lewis JD**, Abramson O, Pascua M, Liu L, Asakura LM, Velayos FS, Hutfless SM, Alison JE, Herrinton LJ. Timing of myelosuppression during thiopurine therapy for inflammatory bowel disease: implications for monitoring recommendations. *Clin Gastroenterol Hepatol* 2009; **7**: 1195-1201; quiz 1141-1142 [PMID: 19631285 DOI: 10.1016/j.cgh.2009.07.019]
- 5 **Beaugerie L**, Brousse N, Bouvier AM, Colombel JF, Lémann M, Cosnes J, Hébuterne X, Cortot A, Bouhnik Y, Gendre JP, Simon T, Maynadié M, Hermine O, Faivre J, Carrat F; CESAME Study Group. Lymphoproliferative disorders in patients receiving thiopurines for inflammatory bowel disease: a prospective observational cohort study. *Lancet* 2009; **374**: 1617-1625 [PMID: 19837455 DOI: 10.1016/S0140-6736(09)61302-7]
- 6 **Kawaguchi H**, Miyashita T, Herbst H, Niedobitek G, Asada M, Tsuchida M, Hanada R, Kinoshita A, Sakurai M, Kobayashi N. Epstein-Barr virus-infected T lymphocytes in Epstein-Barr virus-associated hemophagocytic syndrome. *J Clin Invest* 1993; **92**: 1444-1450 [PMID: 8397226 DOI: 10.1172/JCI116721]
- 7 **Filipovich AH**. Hemophagocytic lymphohistiocytosis (HLH) and related disorders. *Hematology Am Soc Hematol Educ Program* 2009; 127-131 [PMID: 20008190 DOI: 10.1182/asheducation-2009.1.127]
- 8 **Posthuma EF**, Westendorp RG, van der Sluys Veer A, Kluin-Nelemans JC, Kluin PM, Lamers CB. Fatal infectious mononucleosis: a severe complication in the treatment of Crohn's disease with azathioprine. *Gut* 1995; **36**: 311-313 [PMID: 7883236 DOI: 10.1136/gut.36.2.311]
- 9 **Sijpkens YW**, Allaart CF, Thompson J, van't Wout J, Kluin PM, den Ottolander GJ, Bieger R. Fever and progressive pancytopenia in a 20-year-old woman with Crohn's disease. *Ann Hematol* 1996; **72**: 286-290 [PMID: 8624386 DOI: 10.1007/s002770050174]
- 10 **Serrate C**, Silva-Moreno M, Dartigues P, Poujol-Robert A, Sokol H, Gorin NC, Coppo P. Epstein-Barr virus-associated lymphoproliferation awareness in hemophagocytic syndrome complicating thiopurine treatment for Crohn's disease. *Inflamm Bowel Dis* 2009; **15**: 1449-1451 [PMID: 19177429 DOI: 10.1002/ibd.20823]
- 11 **N'guyen Y**, Andreoletti L, Patey M, Lecoq-Lafon C, Cornillet P, Léon A, Jaussaud R, Fieschi C, Strady C. Fatal Epstein-Barr virus primo infection in a 25-year-old man treated with azathioprine for Crohn's disease. *J Clin Microbiol* 2009; **47**: 1252-1254 [PMID: 19193838 DOI: 10.1128/JCM.02052-08]
- 12 **Chauveau E**, Terrier F, Casassus-Buihle D, Moncoucy X, Oddes B. Macrophage activation syndrome after treatment with infliximab for fistulated Crohn's disease. *Presse Med* 2005; **34**: 583-584 [PMID: 15962497 DOI: 10.1016/S0755-4982(05)83984-3]
- 13 **Siegel CA**, Bensen SP, Ely P. Should rare complications of treatment influence decision-making in ulcerative colitis? *Inflamm Bowel Dis* 2007; **13**: 242 [PMID: 17206713 DOI: 10.1002/ibd.20064]
- 14 **Koketsu S**, Watanabe T, Hori N, Umetani N, Takazawa Y, Nagawa H. Hemophagocytic syndrome caused by fulminant ulcerative colitis and cytomegalovirus infection: report of a case. *Dis Colon Rectum* 2004; **47**: 1250-1253; discussion 1253-1255 [PMID: 15148644 DOI: 10.1007/s10350-004-0543-x]
- 15 **Imashuku S**. Advances in the management of hemophagocytic lymphohistiocytosis. *Int J Hematol* 2000; **72**: 1-11 [PMID: 10979202]

P- Reviewer: Yuksel I, Khoury T, Pham PTT **S- Editor:** Dou Y
L- Editor: A **E- Editor:** Song H





Published by **Baishideng Publishing Group Inc**
7901 Stoneridge Drive, Suite 501, Pleasanton, CA 94588, USA
Telephone: +1-925-223-8242
Fax: +1-925-223-8243
E-mail: bpgoffice@wjgnet.com
Help Desk: <http://www.f6publishing.com/helpdesk>
<http://www.wjgnet.com>

