

Name of journal: *World journal of Clinical Cases*

Manuscript NO: 40249

Manuscript Type: CASE REPORT

Atypical lipomatous tumor occurred in ligamentum teres of liver: A case report and review of literature

Daisuke Usuda, Kento Takeshima, Ryusho Sangen, Kisuke Nakamura, Kei Hayashi, Hideyuki Okamura, Yasuhiro Kawai, Yuji Kasamaki, Yoshitsugu Inuma, Hitoshi Saito, Tsugiyasu Kanda, Sachio Urashima

Abstract

A 61-year-old male was referred to our hospital with a three-month history of persistent epigastralgia and right hypochondralgia. Initial examination revealed a fist-size mass at the epigastric fossa. Ultrasonography showed a hemangioma and a mosaic echoic lesion in ventromedian with poor blood-flow signal and linear hyperechoic part inside, and clear

Match Overview

- | Match Number | Source | Words | Similarity |
|--------------|---|----------|------------|
| 1 | Internet
crawled on 28-Mar-2018
serval.unil.ch | 36 words | 2% |
| 2 | Crossref
Seth M. Pollack, Qianchuan He, Jennifer H. Yearley, Ryan E merson et al. "T-cell infiltration and clonality correlate with pr | 26 words | 1% |

全部

图片

新闻

视频

购物

更多

设置

工具

找到约 12,700 条结果 (用时 0.45 秒)

Solitary Fibrous Tumor in the Round Ligament of the Liver: A Fortunate ...

<https://www.ncbi.nlm.nih.gov/pmc/articles/PMC3364086/> ▼ 翻译此页

作者: L Beyer - 2012 - 被引用次数: 8 - 相关文章

2012年4月18日 - Key words: Solitary fibrous tumors, **Liver**, Round ligament ... The initial biopsy was reexamined and regarded as suspicious for low-grade **sarcoma** or SFT. T. Leiomyosarcoma occurring in the **ligamentum teres** of the **liver**: a ...

A symptomatic cyst of the ligamentum teres of the liver: A case report

<https://www.ncbi.nlm.nih.gov/pmc/articles/PMC2712865/> ▼ 翻译此页

作者: EE Lagoudianakis - 2008 - 被引用次数: 6 - 相关文章

2008年5月28日 - Keywords: **Ligamentum teres** mass, **Liver** cyst, Right upper quadrant mass, ... in the **falciform ligament** and **ligamentum teres** of the **liver** are **lipoma**[4-6], ... T. Leiomyosarcoma occurring in the **ligamentum teres** of the **liver**: a ...

Clear Cell Myomelanocytic Tumor of Falciform Ligament/Ligamentum ...

<https://www.dovemed.com/.../clear-cell-myomelanocytic-tumor-falciform-li...> ▼ 翻译此页

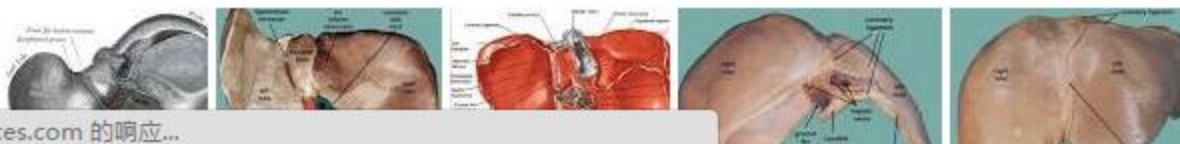
2017年3月24日 - ... ligament and **ligament teres** present in the right side of the **liver**. ... Tumor of **Falciform Ligament/Ligamentum Teres** usually occurs in young adults ... Adipocytic tumor; Clear cell **sarcoma**; Gastrointestinal stromal tumor (GIST) ...

Tumors and Tumor-Like Lesions of the Hepatic Ligaments | SpringerLink

https://link.springer.com/10.1007/978-3-319-26956-6_116 - 翻译此页

2016年10月20日 - Among mesenchymal tumors, **lipoma** is a well-known, albeit rare. ... Malignant Mesothelioma Round **Ligament Falciform Ligament Left Hepatic** ...

Liposarcoma occurred in ligamentum teres ...的图片搜索结果



[全部](#)[图片](#)[新闻](#)[视频](#)[购物](#)[更多](#)[设置](#)[工具](#)

找到约 4,980 条结果 (用时 0.52 秒)

Well-Differentiated Liposarcoma, an Atypical Lipomatous Tumor, of the ...

<https://www.ncbi.nlm.nih.gov/pmc/articles/PMC3081650/> ▼ [翻译此页](#)

作者: T Yuri - 2011 - 被引用次数: 15 - [相关文章](#)

2011年3月29日 - Here, we **report** the **case** of a 73-year-old Japanese man with a ... well-differentiated (WD) liposarcoma (**atypical lipomatous tumor**) [1]. ... However, tumors that **occur** in deep anatomic sites tend to recur. Here, a **case** of WD liposarcoma in the duodenal mesentery is presented, and the **literature** is **reviewed**.

缺少字词: teres

Atypical lipomatous tumor/well-differentiated liposarcoma of the ... - NCBI

<https://www.ncbi.nlm.nih.gov/pubmed/23992781> - [翻译此页](#)

作者: YB Kim - 2014 - 被引用次数: 10 - [相关文章](#)

2013年8月29日 - **Atypical lipomatous tumor**/well-differentiated liposarcoma of the gingiva: a **case report and review of literature**. ... Oral liposarcomas have been reported to **occur** mainly on the buccal mucosa, with other sites including the floor ...

缺少字词: ligamentum teres liver

Primary Pleomorphic Liposarcoma of Liver: A Case Report and ...

<https://www.hindawi.com/journals/cr/hep/2013/398910/> ▼ [翻译此页](#)

作者: PR Naik - 2013 - 被引用次数: 5 - [相关文章](#)

2012年12月12日 - Twelve **cases** of primary liposarcoma of the **liver** have been previously reported. We present the thirteenth **case**, which **occurred** in an adult ...

缺少字词: ligamentum teres

[PDF] Primary perivascular epithelioid cell tumor of the liver not related to ...

<https://pdfs.semanticscholar.org/.../db8f83b89641ab33c0242c2ec9c186e694...> ▼ [翻译此页](#)

[全部](#)[图片](#)[新闻](#)[视频](#)[购物](#)[更多](#)[设置](#)[工具](#)

找到约 4,220 条结果 (用时 0.45 秒)

Primary Pleomorphic Liposarcoma of Liver: A Case Report and ...

<https://www.hindawi.com/journals/cr/hep/2013/398910/> - [翻译此页](#)作者: PR Naik - 2013 - [被引用次数: 5](#) - [相关文章](#)

2012年12月12日 - Case Reports in Hepatology is a peer-reviewed, Open Access journal that ... Primary Pleomorphic Liposarcoma of Liver: A Case Report and Review of the Literature ... Virchow first described a malignant tumor of fatty tissue arising in the lower ... subtype (50% of liposarcomas) and includes atypical lipoma.

缺少字词: ligamentum teres

An atypical lipomatous tumor mimicking a giant fibrovascular polyp of ...

<https://www.ncbi.nlm.nih.gov/pmc/articles/PMC5671807/> - [翻译此页](#)作者: KE Ioanidis - 2017 - [相关文章](#)

2017年10月27日 - Keywords: case report, giant fibrovascular polyp, hypopharynx, liposarcoma However, when they do occur in this region they are usually of the ... polyp of the esophagus: report of a case and a critical review of literature.

缺少字词: ligamentum teres liver

Atypical lipomatous tumor/well-differentiated liposarcoma of the ... - NCBI

<https://www.ncbi.nlm.nih.gov/pubmed/23992781> - [翻译此页](#)作者: YB Kim - 2014 - [被引用次数: 10](#) - [相关文章](#)

2013年8月29日 - Atypical lipomatous tumor/well-differentiated liposarcoma of the gingiva: a case report and review of literature. ... Oral liposarcomas have been reported to occur mainly on the buccal mucosa, with other sites including the floor ...

缺少字词: ligamentum teres liver

[PDF] Acute abdomen as an unusual presentation of hepatic ... - CiteSeerX

citeseerx.ist.psu.edu/viewdoc/download?doi=10.1.1.655.2020&rep... - [翻译此页](#)作者: AM Priola - 2009 - [被引用次数: 28](#) - [相关文章](#)

2007年11月5日 - myomelanocytic tumors of the falciform ligament/ligamentum teres (CCMTs) repre-