


# World Journal of *Clinical Pediatrics*

*World J Clin Pediatr* 2018 October 25; 7(4): 89-104





**REVIEW**

- 89      Perianal infectious dermatitis: An underdiagnosed, unremitting and stubborn condition  
*Serban ED*

**ABOUT COVER**

Editorial Board Member of *World Journal of Clinical Pediatrics*, Stanley P Galant, MD, Full Professor, Pediatrics, Childrens Hospital of Orange County University of California Irvine, Orange, CA 92868, United States

**AIM AND SCOPE**

*World Journal of Clinical Pediatrics* (*World J Clin Pediatr*, *WJCP*, online ISSN 2219-2808, DOI: 10.5409) is a peer-reviewed open access academic journal that aims to guide clinical practice and improve diagnostic and therapeutic skills of clinicians.

*WJCP* covers a variety of clinical medical topics, including fetal diseases, inborn, newborn diseases, infant diseases, genetic diseases, diagnostic imaging, endoscopy, and evidence-based medicine and epidemiology. Priority publication will be given to articles concerning diagnosis and treatment of pediatric diseases. The following aspects are covered: Clinical diagnosis, laboratory diagnosis, differential diagnosis, imaging tests, pathological diagnosis, molecular biological diagnosis, immunological diagnosis, genetic diagnosis, functional diagnostics, and physical diagnosis; and comprehensive therapy, drug therapy, surgical therapy, interventional treatment, minimally invasive therapy, and robot-assisted therapy.

We encourage authors to submit their manuscripts to *WJCP*. We will give priority to manuscripts that are supported by major national and international foundations and those that are of great clinical significance.

**INDEXING/ABSTRACTING**

*World Journal of Clinical Pediatrics* is now abstracted and indexed in PubMed, PubMed Central, China National Knowledge Infrastructure (CNKI), and Superstar Journals Database.

**EDITORS FOR THIS ISSUE**

**Responsible Assistant Editor:** *Xiang Li*  
**Responsible Electronic Editor:** *Shu-Yu Yin*  
**Proofing Editor-in-Chief:** *Lian-Sheng Ma*

**Responsible Science Editor:** *Ying Dou*  
**Proofing Editorial Office Director:** *Jin-Lei Wang*

**NAME OF JOURNAL**

*World Journal of Clinical Pediatrics*

**ISSN**

ISSN 2219-2808 (online)

**LAUNCH DATE**

June 8, 2012

**EDITORS-IN-CHIEF**

**Consolato M Sergi, FRCP(C), MD, PhD, Professor,** Department of Lab Medicine and Pathology, University of Alberta, Alberta T6G 2B7, Canada

**Toru Watanabe, MD, PhD, Professor,** Department of Pediatrics, Niigata City General Hospital, Niigata 950-1197, Japan

**EDITORIAL BOARD MEMBERS**

All editorial board members resources online at <http://www.wjgnet.com/2219-2808/editorialboard.htm>

**EDITORIAL OFFICE**

Jin-Lei Wang, Director  
*World Journal of Clinical Pediatrics*  
Baishideng Publishing Group Inc  
7901 Stoneridge Drive, Suite 501, Pleasanton, CA 94588, USA  
Telephone: +1-925-2238242  
Fax: +1-925-2238243  
E-mail: [editorialoffice@wjgnet.com](mailto:editorialoffice@wjgnet.com)  
Help Desk: <http://www.f6publishing.com/helpdesk>  
<http://www.wjgnet.com>

**PUBLISHER**

Baishideng Publishing Group Inc  
7901 Stoneridge Drive,  
Suite 501, Pleasanton, CA 94588, USA  
Telephone: +1-925-223-8242  
Fax: +1-925-223-8243  
E-mail: [bpgoffice@wjgnet.com](mailto:bpgoffice@wjgnet.com)  
Help Desk: <http://www.f6publishing.com/helpdesk>  
<http://www.wjgnet.com>

**PUBLICATION DATE**

October 25, 2018

**COPYRIGHT**

© 2018 Baishideng Publishing Group Inc. Articles published by this Open-Access journal are distributed under the terms of the Creative Commons Attribution Non-commercial License, which permits use, distribution, and reproduction in any medium, provided the original work is properly cited, the use is non commercial and is otherwise in compliance with the license.

**SPECIAL STATEMENT**

All articles published in journals owned by the Baishideng Publishing Group (BPG) represent the views and opinions of their authors, and not the views, opinions or policies of the BPG, except where otherwise explicitly indicated.

**INSTRUCTIONS TO AUTHORS**

<http://www.wjgnet.com/bpg/gerinfo/204>

**ONLINE SUBMISSION**

<http://www.f6publishing.com>

## Perianal infectious dermatitis: An underdiagnosed, unremitting and stubborn condition

Elena Daniela Serban

Elena Daniela Serban, 2<sup>nd</sup> Department of Pediatrics, "Iuliu Hatieganu" University of Medicine and Pharmacy, Emergency Hospital for Children, Cluj-Napoca 400177, Romania

ORCID number: Elena Daniela Serban (0000-0003-0906-1232).

**Author contributions:** Serban ED contributed to the paper's conception and design, the data collection, extraction, analysis and evaluation, the interpretation of results, and the manuscript's preparation, critical revision, editing and final submission.

**Conflict-of-interest statement:** The author declares there are no potential conflicts of interest relevant to this publication.

**Open-Access:** This article is an open-access article which was selected by an in-house editor and fully peer-reviewed by external reviewers. It is distributed in accordance with the Creative Commons Attribution Non Commercial (CC BY-NC 4.0) license, which permits others to distribute, remix, adapt, build upon this work non-commercially, and license their derivative works on different terms, provided the original work is properly cited and the use is non-commercial. See: <http://creativecommons.org/licenses/by-nc/4.0/>

**Manuscript source:** Invited manuscript

**Correspondence to:** Elena Daniela Serban, MD, PhD, Associate Professor, Pediatric Gastroenterologist, 2<sup>nd</sup> Department of Pediatrics, "Iuliu Hatieganu" University of Medicine and Pharmacy, Emergency Hospital for Children, 5 Crisan Street, Cluj-Napoca 400177, Romania. [daniela.serban@umfcluj.ro](mailto:daniela.serban@umfcluj.ro)  
Telephone: +40-264-532216  
Fax: +40-264-590478

Received: June 24, 2018

Peer-review started: June 25, 2018

First decision: August 2, 2018

Revised: August 23, 2018

Accepted: October 8, 2018

Article in press: October 9, 2018

Published online: October 25, 2018

ficial inflammation of the perianal skin, which is of bacterial origin (classically, *group A beta-hemolytic streptococci*). This narrative review aims to critically review and summarize the available scientific literature regarding pediatric PID, being the first of its kind, to the best of the author's knowledge. It also reports the first cases of Romanian children with PID. Multiple databases were subjected to systematic literature search (from 1966 to April 30, 2018) to identify studies and case reports of children with PID. As such, this review provides updated information about essential aspects of PID (epidemiology, etiology, pathogenesis, as well as clinical features, required investigations and therapeutic options) and of diagnostic pitfalls. Although a well-defined entity, PID remains largely underdiagnosed. PID may mimic other common conditions with skin manifestations (like candidiasis, pinworms, eczema, irritant dermatitis, anal fissure, hemorrhoids, Crohn's disease, psoriasis, seborrheic dermatitis, zinc deficiency dermatosis and even sexual abuse), with consequent unnecessary, sometimes expensive and invasive investigations and futile therapies, which cause patients and families discomfort and distress. Since PID has an unremitting course, early recognition is imperative, as it allows for prompt and efficacious antibiotic therapy. However, PID represents a stubborn condition and, even if properly treated, its recurrence rate remains high. Further well-designed prospective randomized controlled trials, with adequate follow-up, are required in order to formulate the optimum personalized antibiotic therapy (oral alone or in association with topical medication), able to prevent recurrences. Awareness of this condition by healthcare professionals should improve patient outcomes.

**Key words:** Perianal dermatitis; Perianal streptococcal dermatitis; *Beta-hemolytic streptococci*; *Staphylococcus aureus*; Perineal streptococcal dermatitis; Perianal swab culture; Differential diagnosis; Antibiotic therapy; Perianal streptococcal disease

### Abstract

Perianal infectious dermatitis (PID) represents a super-

© **The Author(s) 2018.** Published by Baishideng Publishing Group Inc. All rights reserved.

**Core tip:** Perianal infectious dermatitis (PID) represents a superficial inflammation of the perianal skin, which is of bacterial origin. This narrative review aims to summarize the available literature regarding pediatric PID, being the first of its kind, to the best of the author's knowledge. An updated insight into the main features of PID is provided, including diagnostic pitfalls. PID may mimic other common conditions with skin manifestations, with consequent application of a treatment that is wrong. The unremitting course of PID makes early recognition and antibiotic therapy crucial. Recurrence rates of PID remain high. Awareness of this condition should improve patient outcomes.

Serban ED. Perianal infectious dermatitis: An underdiagnosed, unremitting and stubborn condition. *World J Clin Pediatr* 2018; 7(4): 89-104 Available from: URL: <http://www.wjgnet.com/2219-2808/full/v7/i4/89.htm> DOI: <http://dx.doi.org/10.5409/wjcp.v7.i4.89>

## INTRODUCTION

Perianal infectious dermatitis (PID) represents a superficial inflammation of the perianal skin, which is of bacterial origin<sup>[1]</sup>. The first cases of pediatric PID, all caused by *group A beta-hemolytic streptococci* (GAS), were published more than 50 years ago<sup>[2]</sup>. Still today, the clinical hallmark of PID is represented by a characteristic well-demarcated perianal edematous erythema, extending 2-4 cm around the anus<sup>[1-10]</sup>, sometimes with white exudate, pseudo-membranes and superficial anal fissures or cracks<sup>[1,10-12]</sup>. Despite its typical features, PID is still unrecognized by many healthcare professionals<sup>[13]</sup>, as a result, patients are submitted to unnecessary investigations, sometimes invasive and costly (*i.e.*, upper and lower digestive endoscopies under general anesthesia, and magnetic resonance enterography), as well as to various therapies. Delays in diagnosis and treatment increase patient discomfort and stress, which can also affect the patient's family.

The aim of this narrative review, therefore, is to summarize the currently available scientific literature regarding pediatric PID-as an alert to the medical community-to help ensure more instances of correct management. The author provides updated knowledge of essential aspects of PID (epidemiology, etiology, pathogenesis, as well as clinical characteristics, investigations required and therapeutic options) and of diagnostic pitfalls.

## LITERATURE SEARCH

Published full manuscripts and abstracts were identified by a systematic literature search up to the date of April 30, 2018 for MEDLINE (PubMed), Web of Science and Mendeley (starting from 1966), EMBASE (starting from 1974), The Cochrane Library (starting from 1992), Google

Scholar (starting from 2004), and Research Gate (starting from 2008) databases. Titles, abstracts and full-texts were searched without any language restriction. The reference lists from the selected studies were manually examined to identify additional research studies. Duplicates were excluded. The search included the following items/key words: "perianal cellulitis", "perianal dermatitis", "perianal disease", "perianal infection", "perineal dermatitis", "perianal streptococcal cellulitis", "perianal streptococcal infection", "perianal streptococcal dermatitis", "perianal streptococcal disease", "perineal streptococcal disease", "perineal streptococcal dermatitis", "anitis", and "anusitis". Only papers clearly presenting PID [as case reports, case series/observational studies or randomized controlled trials (RCTs)] and focused on children were retained for detailed analysis.

## Data extraction

The following data were extracted: Last name of the first author; publication year; country; authors' field of medical practice and working department; study design; characteristics of the included population (*i.e.*, sample size, age, sex); symptoms and signs; etiology of the PID; presence or absence of pharyngitis or other site infections; results of throat culture and other relevant laboratory investigations; duration until diagnosis; important data concerning infections in family/community; previous investigations, diagnoses and therapies; type and duration of medication used to cure the PID; presence and rate of recurrence; medication used for recurrences; potential limits of the studies; and, any other relevant data regarding PID.

## Characteristics of included studies

Sixty-four full-text articles reporting on pediatric cases of PID were included, being available from either the mentioned databases or (for older papers) by personally contacting their authors (email and/or phone). Only one reported on a RCT<sup>[12]</sup> (including 35 children); the remaining represented descriptive observational prospective studies/case series [6 articles, comprising a total of 351 patients (between 10 and 150/study)]<sup>[2,6,11,14-16]</sup>, descriptive observational retrospective studies/case series [16 articles, comprising a total of 549 patients (between 6 and 157/study)]<sup>[4,5,8,10,17-28]</sup>, and case reports [41, comprising a total of 75 patients (between 1 and 4 cases/report)]<sup>[3,7,9,13,29-65]</sup>. Three cases diagnosed by this author were also added, giving a total of 78 case reports that were analyzed in this review. Ultimately, the analysis in this review involved the 78 patients from the case reports, 35 from RCTs, 549 from retrospective studies and 351 from prospective studies, giving a total number of PID pediatric cases of 1013.

The main characteristics of the included studies/case series are presented in Tables 1 and 2, and of the case reports in Tables 3 and 4. Four cases presented as case reports did not have the full-text manuscript available in electronic form<sup>[35,48,64]</sup>; however, they are described in Tables 3 and 4, are included in the total number of



**Table 1 Studies/case series with perianal infectious dermatitis: Clinical and bacteriological patient characteristics**

Name, yr, country, study design	Population size; age; sex	Symptoms/signs <sup>1</sup> ; symptom duration	Etiology of PID	Other findings <sup>2</sup>
Amren, 1966, United States, PS <sup>[2]</sup>	10; 1-8 yr, half < 5 yr; 90% M	Painful defecation, constipation, anal pruritus, perianal pain, mucoid or bloody anal discharge; 1 F also with vulvo-vaginitis	GAS (culture)	Throat GAS positive: 28% (no symptoms)
Spear, 1985, United States, RS <sup>[26]</sup>	14; mean age 3.9 yr (1-10 yr); 11 M	Painful defecation (14), constipation (6), bloody stool (7), anal fissure (5); mean duration: 6.2 mo (range: 1-12 mo)	GAS (culture)	
Kokx, 1987, United States, RS <sup>[4]</sup>	31; 7 mo to 8 yr (mean 4.25 ± 1.8 yr); 77% M	Perianal itching (78%), rectal pain (52%), and blood-streaked stool (35%)	GAS and RADT	Throat GAS positive: 64%; identical perianal and pharyngeal T-type (T28, 5 cases; T4, 4; T2, 1)
Krol, 1990, Canada, RS <sup>[20]</sup>	8; 8 mo to 10 yr; 6 M	Perianal pruritus (8); painful defecation (4); anal fissure (2); bloody stool (1); 3 wk to 6 mo	GAS (culture)	
Grant, 1993, United Kingdom, RS <sup>[10]</sup>	20; 5 mo to 12 yr (mean 5 yr); 75% M	Perianal discomfort (14) and itch (13), fresh blood per rectum (12), pain on defecation (10), perianal pain (4), anal mucus discharge (2); 3 wk to 1 yr (mean 3 mo)	GAS (culture)	
Patrizi, 1994, Italy, RS <sup>[22]</sup>	1. 10 yr, M 2. 4 yr, F 3. 5 yr, F 4. 9 yr, M 5. 7 yr, M	1. Pruritus, tenesmus, constipation, acute GP and mild balanitis 2. Anal pruritus, vulvar and perineal erythema, and GP; 4 mo 3. PID and GP 4. Painful defecation, GP; 1 mo 5. PID and balanitis	GAS (culture)	1. Throat GAS negative; penile GAS: same antibiogram 2. Throat GAS negative 3. Throat GAS positive 4. Throat GAS positive 5. GAS tonsillitis 3 mo before; penile GAS and mother with cervical GAS (child and mother bathing together)
Wright, Australia, 1994, PS <sup>[11]</sup>	22; 5 mo to 8 yr (mean 41 mo); 13 M	Painful defecation, bleeding ± anal pain, perianal pruritus, constipation	Culture: 12 GAS, 1 GBS, 1 GCS	
Mostafa, 1997, Egypt, PS <sup>[15]</sup>	150; 2 mo to 11 yr (mean 3.8 ± 2.1 yr); 75% M	Perianal itching (15%), gastroenteritis (34%)	BHS: 35.3%, <i>S. aureus</i> 3.4%	Throat: BHS 44% (GAS 21.3%, non-GAS 22.7%); PID caused by GAS: 53.8% with same GAS in the throat
Barzilai, 1998, Israel, PS <sup>[14]</sup>	18; 7 mo to 5.4 yr; 10 M	Perianal pruritus (50%); painful defecation or constipation (44%); anal fissure (39%); purulent secretion (27%); rectal bleeding (16%); 2 GP	GAS	GAS in other locations: 72%; 4 siblings throat GAS positive (no symptoms)
Mogielnicki, 2000, United States, RS <sup>[5]</sup>	23; mean age 5 yr (1-11 yr); 13 F	13 only PID; 2 PID + vulvo-vaginitis; 8 only vulvo-vaginitis	GAS (culture)	Throat GAS positive: 92% (± symptoms)
Mateo, 2002, Spain, RS <sup>[19]</sup>	10; 9 mo to 7 yr; 6 M	Oozing and rectal bleeding, anal pruritus, pain on defecation; 1 M also GP; 20 d to 2 yr	GAS	Throat GAS positive: 3/6
Petersen, 2003, Denmark, RS <sup>[27]</sup>	17; mean age 6 yr (3-13 yr)	Painful defecation, fresh blood on stool	GAS 12 (11 M) T28	Throat GAS positive 12%; 6/12 with T28 from kindergarten
Landolt, 2005, Switzerland, RS <sup>[17]</sup>	13; 7 F	Obstipation (58%), painful defecation (50%), perianal itching (25%), melena (25%); 10 cases with > 1 symptom	GAS positive in 12	
Echeverría Fernández, 2006, Spain, PS <sup>[6]</sup>	19; 6 mo to 4 yr (median age 12 mo)	Anal pruritus (19), constipation (9), anal fissures (5), rectal bleeding (4), vulvo-vaginitis (2)	GAS (RADT and culture)	Throat GAS positive: 80%; GAS pharyngitis: 1 case
Meury, 2008, Switzerland, RCT <sup>[12]</sup>	35; 1-16 yr	Either typical erythema or at least 2 of: perianal itching, rectal pain, painful defecation, constipation, blood-streaked stool, rectal mucopurulent discharge, or anal fissure	GAS	
Jongen, 2008, Germany, RS <sup>[8]</sup>	21; < 14 yr (mean age 6.3 yr); 76% M	Perianal itching, sore anus, bleeding and pain at defecation; mean duration of 6.6 months (2 wk to 2 yr)	17 GAS, 4 GBS (culture)	
Shouval, 2008, Israel, RS <sup>[18]</sup>	11; 6 mo to 4 yr (mean 24 mo); 73% M	Irritability (all), perianal itching (6) and pain (3); < 28 d	GAS (RADT)	
Heath, 2009, United States, RS <sup>[26]</sup>	26; 5 mo to 12 yr; 15 F	Anal erythema or recurrent buttocks dermatitis; in PID caused by <i>S. aureus</i> : specific small papules and pustules of the buttocks or extension of the erythema to adjacent buttock skin	<i>S. aureus</i> 82%, GAS, GBS	
Olson, 2011, United States, RS <sup>[25]</sup>	81; mean age, M: 4.1 yr and F: 4.6 yr; 58% M	(86.4%) perianal involvement; (22.2%) symptoms for at least 2 wk (6.2% with symptoms for at least 4 wk); the rest: duration < 1 wk	GAS	
Clegg, 2015, United States, RS <sup>[23]</sup>	157; 18 d to 12.5 yr, mean 4.8 yr, 53% M	Predominant site of involvement: M: perianal (86%) and F: perivaginal area (62%); 9.8 d	GAS	Throat GAS positive: 95%; 100% concordance between perineal and pharyngeal GAS

Cohen, 2015, France, PS <sup>[16]</sup>	132; mean age 46.6 ± 23.5 mo; 64% M	Painful defecation, anal fissure, bloody stools; 4 also vulvo-vaginitis; 2 wk	GAS (RADT and culture)	
Garcia, 2015, Spain, RS <sup>[21]</sup>	6; 9 mo to 5 yr (mean age 3 yr); 5 M	Perianal rash (6), rectal pain (3), itching (2), vaginitis (1)	GAS	GAS pharyngitis: 30%
Sterbenc, 2016, Slovenia, RS <sup>[24]</sup>	89 cases < 15 yr (84.7%); median age 5 yr		GAS, GBS, GCS, GGS	

<sup>1</sup>Besides typical perianal erythema; <sup>2</sup>Especially throat culture and infections in the family/community. AB: Antibiotic; BHS: Beta-hemolytic streptococci; F: Female; GAS: Group A beta-hemolytic streptococci; GBS: Group B beta-hemolytic streptococci; GCS: Group C beta-hemolytic streptococci; GP: Guttate psoriasis; M: Male; Pen: Penicillin; PID: Perianal infectious dermatitis; PS: Prospective study; RADT: Rapid antigen detection test; RCT: Randomized controlled trial; RS: Retrospective study; *S. aureus*: *Staphylococcus aureus*; T2: T-type 2 of GAS; T28: T-type 28 of GAS; T4: T-type 4 of GAS.

patients analyzed, and provided epidemiological, clinical and bacteriological data. Five papers found as references in other reports could not be included, as their abstracts and full-text manuscripts were not available in electronic format and there was also no reply to this author's inquiry, initially made in December 2016<sup>[66-70]</sup>. Table 5 presents previous investigations, diagnoses and therapies in children finally diagnosed with PID.

## DEFINITIONS AND TERMS USED

Initially, the PID condition was described as "perianal cellulitis" in 1996 by Amren *et al*<sup>[2]</sup>; this term has since been used by other authors<sup>[10,14,28-31,38,56,59,61,63]</sup>. However, the term "cellulitis" was later considered inaccurate, since inflammation involves only the skin<sup>[4,20]</sup>. The more appropriate term of "perianal streptococcal dermatitis" was introduced by Krol<sup>[20]</sup> in 1990 and used both in pediatric<sup>[8,9,12,13,17,19,20,22,24,34-36,39-47,49,51-53,55]</sup> and adult cases<sup>[71-75]</sup>. The terms "anitis"<sup>[13,55]</sup> and "anusitis"<sup>[67]</sup> were also used, but only in a few papers. Other authors preferred to name this condition "perianal streptococcal infection"<sup>[7,11,16,18,27,33,37,50,60,65,76,77]</sup> or "perianal streptococcal disease", as introduced in 1987 by Kokx *et al*<sup>[4,62,64,78]</sup>. Mogielnicki *et al*<sup>[5]</sup> introduced the term "perineal streptococcal disease", as the infection may extend to genital organs. Others preferred "perineal streptococcal infection"<sup>[23]</sup> or "perineal streptococcal dermatitis"<sup>[3,25,79]</sup>. Recently, the proposed term is "PID"<sup>[1]</sup>, as other infectious bacterial agents have also been proven to cause this condition<sup>[3,8,24,26,32,58]</sup>.

## EPIDEMIOLOGY

The incidence of pediatric PID is unknown. With so many terms used for the same condition, it is not surprising that its frequency is not determined. However, the main reason for this unknown incidence is considered the fact that PID remains too often unrecognized by healthcare professionals. PID appears all over the world and has been reported by authors in various countries from different continents, including the United States<sup>[2,4,5,23,25,26,28,32,38,43,46,57,59,61-63]</sup>, Canada<sup>[3,20,40]</sup>, Australia<sup>[11,33]</sup>, Africa (Egypt<sup>[15]</sup>), Europe (United Kingdom<sup>[7,10,29,30,65]</sup>,

Spain<sup>[6,19,21,31,42,64]</sup>, Italy<sup>[22,35,39,47,48]</sup>, The Netherlands<sup>[36,60]</sup>, Finland<sup>[37]</sup>, Sweden<sup>[41,50]</sup>, Germany<sup>[8,9,45]</sup>, Denmark<sup>[27]</sup>, Switzerland<sup>[12,17,54]</sup>, France<sup>[13,16,55]</sup>, Greece<sup>[58]</sup>, Asia (India<sup>[44]</sup>, Taiwan<sup>[49]</sup>, Japan<sup>[51,52]</sup>, Iran<sup>[56]</sup>), Israel<sup>[14,18]</sup> and Turkey<sup>[53]</sup>. It appears that no cases have been published from Eastern Europe.

Considering incidence of PID caused by GAS among all pediatric consultations in different services, rates have varied from 1 case/2000 patients (May 1964 through July 1965 in a pediatric department in the United States<sup>[2]</sup> and in a study published in 2015 from another pediatric center in the United States<sup>[23]</sup>) to 1 case/400 outpatient visits (January through March 1990 in a pediatric hospital in the United States)<sup>[80]</sup>, 1 case/218 patients (October 1985 through June 1986 in a pediatric hospital in the United States)<sup>[4]</sup>, 1 case/200 patients (during the year 1997 in a department of pediatrics and community and family medicine in the United States)<sup>[5]</sup> and 1 case/20 patients (October 2000 through May 2001 in a pediatric clinic in Switzerland)<sup>[17]</sup>. As seen, most data have originated from the United States, with only one report being from Europe. The only other European paper reporting frequency of PID was a German case series, albeit from a colorectal surgery clinic. PID was detected in 16% of patients aged a maximum of 14 year with anorectal complaints, from February 2003 through September 2006<sup>[8]</sup>. In a rural area of Denmark, the annual incidence was determined to be 2-7 in 1000 children<sup>[27]</sup>. From a survey performed among general practitioners in 1996 in an urban area of the United Kingdom, it was concluded that PID might be seen, on average, once or twice a year. Lack of awareness was considered the main reason for PID being missed in primary care<sup>[7]</sup>.

Regarding age, PID is particularly encountered in children, especially between the ages of 6 mo and 10 years<sup>[2-4,8,11,20,22,28]</sup>, with a maximum incidence peak between 3 years and 6 years<sup>[24]</sup>. However, cases have been described in infants less than 6 mo of age<sup>[15,23,26,43,57]</sup> or older than 10 years<sup>[5,10,15,23,26,27,39,48,62]</sup>, and even in adults<sup>[52,61,71-78,81-84]</sup>.

Boys have been initially described as predominantly affected by PID, representing about or more than 70%-80% of cases<sup>[2,4,8,10,15,18,20,21,28]</sup> (Table 1). Also, most

**Table 2 Studies/case series with perianal infectious dermatitis: Therapy and follow-up of patients**

Name, yr, country	Therapy of PID and results	Follow-up of PID
Amren, 1966, United States <sup>[2]</sup>	IM Pen, 10 d plus oral Pen, 10 d: disappearance of symptoms in 2-3 d	After therapy: 2 cases GAS positive; 10 d of Pen (same type): Effective in eradicating GAS in both cases
Spear, 1985, United States <sup>[28]</sup>	Oral Pen: rapid resolution of PID	Recurrence of infection: Not uncommon, requiring a repeated course of oral AB
Kokx, 1987, United States <sup>[4]</sup>	Oral Pen or amoxicillin, 10 d: clinical and bacteriological clearance in 61%	39% relapses, treated with IM or oral Pen; 4 children failed; 3 successfully treated with oral clindamycin, 10 d; 4 <sup>th</sup> case successfully treated with oral Pen (10 d) and rifampin (last 4 d)
Krol, 1990, Canada <sup>[20]</sup>	Oral Pen, 10 d plus topical mupirocin in 4 cases (these 4 without recurrence)	2 cases: 2 <sup>nd</sup> course of therapy within 1 mo
Grant, 1993, United Kingdom <sup>[10]</sup>	Oral Pen, 3 wk: 14 responded (6 plus topical fucidin)	6 cases: No complete response; successful 2 <sup>nd</sup> course of oral Pen and topical fucidin
Patrizi, 1994, Italy <sup>[22]</sup>	1. Oral erythromycin, 14 d 2. Oral Pen, 2 wk  3. Oral erythromycin, 2 wk 4. Oral erythromycin and topical mupirocin, 2 wk 5. Amoxicillin, 2 wk: good results	1. 4 wk later, GP and PID disappeared and all swabs negative 2. Lesions improved, but swab positive: erythromycin, 2 wk: complete healing (including negative GAS) 3. Lesions disappeared in maximum 5 wk 4. 4 wk later, lesions and culture negative 5. 4 wk later, perianal GAS, no lesions; 2 <sup>nd</sup> course of amoxicillin: good results
Wright, Australia, 1994 <sup>[11]</sup>	Oral amoxicillin - clavulanate plus topical bacitracin, 2 wk	50%: Response to treatment in 2 wk; no recurrence
Barzilai, 1998, Israel <sup>[14]</sup>	Oral amoxicillin, 10 d and topical mupirocin: 16 patients clinically cured; perianal cultures GAS negative: days 3-5 of therapy and weeks 2 to 3 post-therapy	Recurrence: 2 cases (clinical and culture); successfully retreated 1 wk after finishing first therapy
Mateo, 2002, Spain <sup>[19]</sup>	IM Pen (1), oral amoxicillin (5), topical mupirocin (4)	All with favorable response and no recurrence
Petersen, 2003, Denmark <sup>[27]</sup>	Oral Pen, 10 d: ineffective in 3 cases	3 cases: Clarithromycin, 7 d; no recurrence
Landolt, 2005, Switzerland <sup>[17]</sup>	10 with > 1 symptom: oral Pen, 10 d; 3: oral or IV amoxicillin-clavulanate	4 with persistent symptoms: 2 <sup>nd</sup> course of AB - oral Pen (3 cases), 14 d and oral clarithromycin (1 case), 10 d; 1 mo later: all 4 healed
Echeverría Fernández, 2006, Spain <sup>[6]</sup>	Oral Pen, 10 d	Favorable in 85%, perianal GAS negative in 95%
Meury, 2008, Switzerland <sup>[12]</sup>	15 cases: oral Pen, 10 d and 14 cases: oral cefuroxime, 7 d	Clinical improvement: More rapid in the cefuroxime group ( $P = 0.028$ ) and perianal GAS negative the last day of therapy in 93% on cefuroxime vs 47% on Pen ( $P < 0.01$ )
Jongen, 2008, Germany <sup>[8]</sup>	Oral Pen ± local polihexanid, 10-14 d	1 case: New GAS associated PID 5 mo later; successfully treated with oral AB
Shouval, 2008, Israel <sup>[18]</sup>	Oral amoxicillin, 10 d and topical mupirocin (8/11); complete healing in 73%	Recurrence: 3/11; 2 <sup>nd</sup> course of AB administered
Heath, 2009, United States <sup>[26]</sup>	Oral cephalexin for <i>S. aureus</i> : Successful in all but one; 4 cases with <i>S. aureus</i> cleared on topical mupirocin and 1 on bleach baths and topical steroids	1 case with MRSA: 2 <sup>nd</sup> course of oral AB required
Olson, 2011, United States <sup>[25]</sup>	Oral AB alone: 81.4%; topical agent alone: 2.5%; both: 16%; duration: oral beta-lactams 10 d, azithromycin 5 d, cephalexin 5 d, oral Pen 14 d	Recurrence 32.1%; recurrence within 6 wk 69.2%; recurrence rate: After Pen or amoxicillin 38.1% vs 27.8% after a beta-lactamase resistant AB (adjusted odds ratio: 2.02)
Clegg, 2015, United States <sup>[23]</sup>	Amoxicillin 82.2%; cephalexin 11%; other AB 7%; topical therapy: 6%	Recurrence rate (symptomatic PID) 6 mo after the initial episode: 13.4% after any AB, 12.4% after amoxicillin, 29.4% after cephalexin, and 0% after all other AB (oral Pen, amoxicillin-clavulanate, azithromycin, clarithromycin, cefprozil and cefdinir)
García, 2015, Spain <sup>[21]</sup>	Oral AB (Pen 5, amoxicillin 1), plus 4 topical mupirocin and 3 clotrimazole	Satisfactory; 1 recurrence
Sterbenc, 2016, Slovenia <sup>[24]</sup>		All BHS: susceptible to Pen; all GAS susceptible to clindamycin, 1.4% resistant to erythromycin; GBS resistant to erythromycin in 14.8% and clindamycin in 7.4% of cases

AB: Antibiotic; BHS: Beta-hemolytic streptococci; GAS: Group A beta-hemolytic streptococci; GBS: Group B beta-hemolytic streptococci; GP: Guttae psoriasis; IM: Intramuscular; IV: Intravenous; Pen: Penicillin; MRSA: Methicillin-resistant *S. aureus*; PID: Perianal infectious dermatitis.

case reports have presented male patients (Table 3). No precise reason has been found for this predominance; hormones and immune factors may contribute to it<sup>[52]</sup>. However, other series showed smaller rates of male predominance (53%<sup>[23]</sup>, 55.5%<sup>[14]</sup>, 58%<sup>[25]</sup>, 59%<sup>[11]</sup>,

60%<sup>[19]</sup> and 64%<sup>[16]</sup>), while four studies reported a slight female predominance (54%<sup>[17]</sup>, 57%<sup>[5,26]</sup> and 63%<sup>[6]</sup>).

Concerning seasons, most cases of PID caused by GAS appeared in winter<sup>[2,5,8,19]</sup> and spring<sup>[2,5,24]</sup>, when GAS infections of the upper respiratory tract are also more



**Table 3 Case reports with perianal infectious dermatitis: Clinical and bacteriological patient characteristics**

Name, yr, country	Case age, sex	Symptoms/signs <sup>1</sup> ; symptom duration	Etiology of PID	Other findings <sup>2</sup>
Hirschfeld, 1970, United States <sup>[59]</sup>	1-2. 6 yr, F and 3 yr brother 3-4. 5 yr and 3 yr brothers (unrelated family)	1-2. Painful defecation; several days 3-4. Same history and symptoms	GAS (culture)	1-2. Both had sore throats 2 wk prior 3-4. Throat GAS positive (1 case)
Farmer, 1987, United Kingdom <sup>[65]</sup>	1. 4 yr, M 2. 5 yr, F	1. White anal discharge, perianal pustules; 3 wk 2. Perianal itching, pain on defecation, dysuria; vulva affected; 3 wk	GAS (culture)	
Rehder, 1998, United States <sup>[61]</sup>	1. 3 yr, M 2. 3 yr, M 3. 4 yr, M 4. 1 yr, F	1. Rectal irritation; 6 mo 2. Perianal pain and itching; 5 wk 3. Perirectal pain; 6 wk 4. GP; 3 wk	GAS (culture)	1. Sibling, 6 yr: GAS pharyngitis recently 2. Patient: throat GAS positive; sibling with recent sore throat 3. Identical GAS from anus and throat
Honig, 1988, United States <sup>[62]</sup>	4; 15 mo, 6, 8 and 12 yr; 3 M	Anal pruritus, bloody anal discharge; GP: 2 cases, appeared 9 mo after onset of PID; 1 M with PID history of 2 yr	GAS (culture)	
Marks, 1988, United States <sup>[63]</sup>	5 yr, M	Perianal irritation and pruritus, bloody discharge; 2 wk	GAS (culture)	
Guerrero - Vázquez 1989, Spain <sup>[64]</sup>	2 cases	Perianal irritation in both; seropurulent anal and balano-preputial discharge in 1 case	GAS (culture)	
Duhra, 1990, United Kingdom <sup>[29]</sup>	5 yr, M	Painful defecation, micturition, bloody stool; penile erythema swelling; 4 wk	GAS (culture)	GAS positive from penile skin; members of patient's family: severe sore throat recently
Goodyear, 1991, United Kingdom <sup>[30]</sup>	4 yr, M	Painful defecation, blood-streaked liquid stool; fecal incontinence; 6 wk	GAS (culture)	
Medina, 1992, Spain <sup>[31]</sup>	4 yr, M	Perianal pruritus and bleeding; 3 mo	GAS (culture)	
Montemarano, 1993, United States <sup>[32]</sup>	3 yr, M	Painful perianal area, satellite pustules; 2 mo	<i>S. aureus</i> (culture)	<i>S. aureus</i> positive in anterior nares and satellite pustule
Guppy, 1993, Australia <sup>[33]</sup>	1. 7 yr, M 2-3. His 2 brothers, 5 and 2.5 yr 4. 4 yr, M 3 yr, M	1. Perianal excoriation; 8 wk 2-3. Similar history 4. Typical PID; penis lesions later; 4 wk Perianal itching; 2 mo	GAS (culture)	The three siblings bathing together
Paradisi, 1993, Italy <sup>[34]</sup>	1. 3 yr, F 2. 5 ½ yr, M, brother	Painful defecation, perianal itching, rectal bleeding, constipation	GAS	
van Zeijl, 1996, Netherlands <sup>[36]</sup>	4; 3 M (1, 6 and 8 yr, the last 2 brothers); 1 F (2 yr)	Constipation, painful defecation, diarrhea	GAS (culture)	Brothers shared same toilet
Saxen, 1997, Finland <sup>[37]</sup>	1. 3 yr, M 2-3. Other cases	1. Itchy anus and bloody stool; 1 w 2. Same symptoms	GAS (T28)	2. Throat GAS positive, identical (T28)
Berlin, 1997, United States <sup>[38]</sup>	3 yr, M	Constipation, myositis	GAS (culture)	His mother had sore throat GAS positive
Bugatti, 1998, Italy <sup>[39]</sup>	12 yr, M	Perianal discharge, 1 mo	GAS (culture)	
Adams, 1999, Canada <sup>[40]</sup>	1 yr, M	Typical PID	GAS (culture)	
Roos, 1999, Sweden <sup>[41]</sup>	5 yr, M	Anal pruritus	GAS T28 (culture)	Case: throat GAS negative; mother: GAS tonsillitis positive; anal and throat GAS identical
Velez, 1999, Spain <sup>[42]</sup>	2 yr, M	Fever 39-40 °C, erythema: perianal, genitalia and proximal thighs	GAS (culture)	Throat negative
Herbst, 2000, Germany <sup>[9]</sup>	4 yr, M	GP; 6 w history; PID discovered at physical exam	GAS (culture)	Patient and family members: Negative GAS throat
Brilliant, 2000, United States <sup>[43]</sup>	1. 4 yr, M 2-3. 2 mo and 30 mo 4. 4 yr, F	1. Rectal itching and pain, scant mucoid discharge 2-3. Several days later with similar symptoms 4. Plus vulvitis	GAS (RADT + culture)	2-3. Siblings of case 1 4. Neighbor of the 3 cases
Balasubramanian, 2000, India <sup>[44]</sup>	1. 13 mo, M 2. 11 mo, M 3. 13 mo, F	1. Fever, painful defecation, anal pruritus; 2 d 2-3. Fever, painful defecation	GAS (culture)	
Heidelberger, Germany, 2000 <sup>[45]</sup>	1. 6 yr, M 2. 9 yr, M	1. Anal itching and burning; 3 mo 2. Balanitis and impetigo	GAS (culture)	

Nowicki, 2000, United States <sup>[46]</sup>	7 yr, M	Perianal itching, painful defecation; 10 d	GAS (culture)	Throat GAS negative
Soulliet, 2000, France <sup>[13]</sup>	7 yr, F	Vulvar erythema, perirectal pain, painful defecation, constipation; perioral impetigo; 3 wk	GAS (culture)	Perioral GAS positive
Lunghi, 2001, Italy <sup>[47]</sup>	Brother (4 yr) and sister (6 yr)	1 also vulvo-vaginitis; 4 mo	GAS (culture)	Throat GAS positive in both patients
Romano, 2002, Italy <sup>[48]</sup>	12 yr, M	PID and GP	GAS	
Huang, 2003, Taiwan <sup>[49]</sup>	6 yr, M	Perianal itching, painful defecation, scant mucoid discharge	GAS (culture)	Throat GAS positive
Reimer, 2004, Sweden <sup>[50]</sup>	1. 4 yr, M 2. 6 yr, M	1. Perianal discomfort 2. Purulent discharge plus balanitis	1. GAS (RADT) 2. GAS	2. Penis culture GAS positive; father treated for GAS pharyngitis; brother, 4 yr with GAS PID and brother 2 yr with GAS pharyngitis
Takeshita, 2006, Japan <sup>[51]</sup>	3. 4 yr, F 1. 2 yr, F	3. Perianal pain, vulvar erythema and pain 1. PID; 2 wk	3. GAS GAS (culture)	
Usuki, 2006, Japan <sup>[52]</sup>	2. 6 mo, M 5 yr, F	2. PID; 1 wk PID	GAS (RADT)	4 d later: Father with symptoms of PID and GAS positive
Ulger, 2007, Turkey <sup>[53]</sup>	3 yr, M	Pain on defecation, anal pruritus; 8 d; GP; 2 d	GAS (culture)	Sore throat 2 wk before; no culture, no therapy needed
Greisser, 2008, Swiss <sup>[54]</sup>	7 yr, M	Perianal pain and pruritus, yellow discharge; 3 d	GAS (RADT + culture)	Throat GAS negative
Lehman, 2009, United Kingdom <sup>[7]</sup>	3 yr, F	Itchy bottom and painful defecation; 2 wk	GAS (culture)	
Ledoux, 2009, France <sup>[55]</sup>	4 yr, M	PID for 2 wk; lesions of GP since second week	GAS (culture)	
Rasi, 2009, Iran <sup>[56]</sup>	4 yr, M	Rectal itching and burning, pain on defecation; plaque type psoriasis; 3 mo	GAS (RADT)	
Block, 2013, United States <sup>[57]</sup>	1. 2 mo, F 2. 4 mo, F	1. PID and vulvar erythema 2. Blood in diaper	GAS	1. 8 yr sibling: previous GAS pharyngitis
Theotokatou, 2014, Greece <sup>[58]</sup>	1. 8 yr, M 2. 10 yr, M, brother	1. Perianal itching, constipation, blood-streaked stool; 3 wk 2. Perianal itching and mucous discharge (2 wk after onset of symptoms of his brother)	<i>Enterococcus faecalis</i> (culture) in both)	
Zhang, 2016, Canada <sup>[3]</sup>	1. 4 yr, M 2. 4 yr, M 3. 3 yr, F	1. Painful defecation, GP, penile erythema 2. Painful defecation, GP 3. Perivulvar erythema, small amount of greenish-yellowish vaginal discharge	1. GAS and <i>S. aureus</i> 2. GBS 3. GCS	1. Throat GAS positive 2. Throat culture negative 3. Throat culture negative; vulvar culture few GCS and scant <i>S. aureus</i>
Garritsen, 2017, Netherlands <sup>[60]</sup>	19 mo, M	PID and 1 wk later: GP	GAS	
Serban, present study, Romania	1. 9 yr 4 mo, M 2. 9 yr 6 mo, M 3. 11 yr 9 mo, M	1. Perianal pain and pruritus, anal mucous and bloody discharge, painful defecation; 6 wk 2. Anal pruritus, painful defecation, anal mucous and bloody discharge 3. Anal pruritus, mucous and bloody discharge, painful defecation, constipation	1. GBS and <i>S. aureus</i> (culture) 2. GAS (culture) 3. GAS (culture)	1. Throat GAS, GBS and <i>S. aureus</i> negative 2. Throat GAS positive 3. Throat GAS negative

<sup>1</sup>Besides typical perianal erythema; <sup>2</sup>Especially throat culture and infections in the family/community. F: Female; GAS: Group A beta-hemolytic streptococci; GBS: Group B beta-hemolytic streptococci; GCS: Group C beta-hemolytic streptococci; GP: Guttate psoriasis; M: Male; PID: Perianal infectious dermatitis; RADT: Rapid antigen detection test; *S. aureus*: *Staphylococcus aureus*; T28: T-type 28 of GAS.

prevalent. Only 30% of cases were reported in June and July in the initial paper by Amren *et al*<sup>[2]</sup>, while the rest were during spring and winter. A recent prospective study found most cases in autumn (peak of 21% in November)<sup>[16]</sup>, while a report published that same year showed a maximum incidence between October and March (65% of cases)<sup>[23]</sup>. Interestingly, PID caused by group B streptococci (GBS) also had a maximum incidence during winter and spring<sup>[24]</sup>.

Cases of PID in the same family and/or with inter-familial spread have been extensively documented, transmitted from children to parents<sup>[52]</sup> or *vice versa*<sup>[22,38,50]</sup> or between siblings<sup>[14,33,35,36,43,47,50,58,59]</sup> or other family

members<sup>[26]</sup> or friends<sup>[43]</sup>. In the study by Kokx *et al*<sup>[4]</sup>, among 31 children from 19 families, intrafamilial spread was detected only in siblings and occurred in 50% of the possible situations, with 7 families representing multiple cases of PID. Also, small epidemics (outbreaks) in daycare centers have been published<sup>[5,27,37]</sup>. In the study reported by Mogielnicki *et al*<sup>[5]</sup>, of 23 cases, 10 had contact with someone with PID. Saxén *et al*<sup>[37]</sup> showed that a small outbreak of 3 culture-confirmed PID cases caused by GAS and 2 non-verified clinical PID cases occurred within 9 d in a group of 20 daycare children. The following risk factors for PID have been described: perianal skin lesions; poor hygiene; poor living conditions; overcrowded houses;

**Table 4 Case reports with perianal infectious dermatitis: Therapy and follow-up of patients**

Name, yr, country	Case age, sex	Therapy of PID and results	Follow-up of PID
Hirschfeld, 1970, United States <sup>[59]</sup>	1-2. 6 yr, F and 3 yr brother 3-4. 5 yr and 3 yr brothers (unrelated family)	Oral Pen	
Farmer, 1987, United Kingdom <sup>[65]</sup>	1. 4 yr, M 2. 5 yr, F	1. Oral Pen: prompt and complete recovery 2. Oral Pen, 1 wk: asymptomatic	
Rehder, 1998, United States <sup>[61]</sup>	1. 3 yr, M  2. 3 yr, M 3. 4 yr, M	1. Oral Pen, 2 wk  2. Oral Pen, 2 wk 3. Oral Pen, 3 wk	1. 2 wk later, erythema and GAS positive: erythromycin, for 1 mo; no recurrence (including culture) 2. No recurrence (including cultures) 3. Perianal cultures positive after 2 and 3 wk: erythromycin, 10 d: negative culture 4. All negative
Honig, 1988, United States <sup>[62]</sup>	4; 15 mo, 6, 8 and 12 yr; 3 M	4. Oral Pen, 3 wk: both conditions cleared Oral Pen, 10 d; PID cleared in 3 cases within 10-14 d	The 4 <sup>th</sup> case with PID history of 2 Y: 10 d of erythromycin, cleared PID and negative culture; psoriasis cleared 14-35 d after institution of therapy
Marks, 1988, United States <sup>[63]</sup>	5 yr, M	Oral Pen, 14 d; rash progressively healed (completely in 17 d)	
Duhra, 1990, UK <sup>[29]</sup>	5 yr, M	Oral Pen, 3 wk: clearance of penile lesion (2 wk), but not perianal, also with positive GAS	Other 2 wk of oral Pen cleared PID and GAS
Goodyear, 1991, United Kingdom <sup>[30]</sup>	4 yr, M	Oral Pen, 10 d; completely resolved in 2 wk	Follow up 2 mo later: clinically well
Medina, 1992, Spain <sup>[31]</sup>	4 Y, M	Topical mupirocin, 10 d: Completely resolved	Negative cultures 1 wk and 1 mo later
Montemarano, 1993, United States <sup>[32]</sup>	3 Y, M	Oral erythromycin, 10 d: Rapid cure	
Guppy, 1993, Australia <sup>[33]</sup>	1. 7 yr, M  2-3. His 2 brothers, 5 and 2.5 yr	1. Oral Pen, 10 d  2. Oral Pen, 10 d 3. Oral Pen, 10 d, initially improved	1. After stopping Pen, rectal bleeding: Cefaclor, 10 d, no recurrence 2. No recurrence 3. 3 mo later: Persistent perianal infection: erythromycin
Paradisi M, 1993, Italy <sup>[34]</sup>	4. 4 yr, M 3 yr, M	4. Oral Pen, 2 wk, incomplete resolution Topical erythromycin, 15 d: Complete clinical and bacteriologic resolution	4. Erythromycin, 4 wk: Complete resolution No recurrence
van Zeijl, 1996, Netherlands <sup>[36]</sup>	4; 3 M (1, 6 and 8 yr, the last 2 brothers); 1 F (2 yr)	Oral Pen, 10 d ± mupirocin or fucidin Oral amoxicillin + fucidin	
Saxen, 1997, Finland <sup>[37]</sup>	1. 3 yr, M	1. Oral Pen, 10 d: clearance within 2 d	1. 1 wk after stopping Pen: PID recurrence, with GAS positive; oral cephalixin: good results
Berlin, 1997, United States <sup>[38]</sup>	3 yr, M	IV antibiotics (not mentioned)	Symptoms resolved entirely after 2 wk
Bugatti, 1998, Italy <sup>[39]</sup>	12 yr, M	Amoxicillin, 10 d: Rapid resolution of symptoms	
Adams, 1999, Canada <sup>[40]</sup>	1 yr, M	Oral Pen and topical mupirocin, 10 d	
Roos, 1999, Sweden <sup>[41]</sup>	5 yr, M	Cefadroxil plus topical fucidin, 10 d	No recurrence
Velez, 1999, Spain <sup>[42]</sup>	2 yr, M	Cefaclor, 10 ds: complete healing	2 wk after therapy: Acral (hands and feet) scarlatiniform desquamation
Herbst, 2000, Germany <sup>[9]</sup>	4 yr, M	Oral Pen and topical fucidin, 2 wk: Complete healing (including culture)	
Brilliant, 2000, United States <sup>[43]</sup>	1. 4 yr, M 2-3. 2 mo and 30 mo 4. 4 yr, F	1. Oral amoxicillin, dramatic improvement 1 d 2-3. Same effective therapy 4. Same effective therapy	
Balasubramanian, 2000, India <sup>[44]</sup>	1. 13 mo, M 2. 11 mo, M 3. 13 mo, F	Oral Pen, 10 d; symptoms clearance in 3 d	
Heidelberger, Germany, 2000 <sup>[45]</sup>	1. 6 yr, M 2. 9 yr, M	1: Oral Pen, 10 d 2. Same plus topical clioquinol; in both cases, all lesions disappeared	
Nowicki, 2000, United States <sup>[46]</sup>	7 yr, M	Oral Pen: Symptoms and signs disappeared	1 wk following Pen, peeling from his fingers tip (toes not involved)
Soulliet, 2000, France <sup>[13]</sup>	7 yr, F	Amoxicillin, 10 d; perianal lesions cleared by day 2	
Lunghi, 2001, Italy <sup>[47]</sup>	Brother (4 yr) and sister (6 yr)	IM Pen, 4 wk, plus local mupirocin	Complete resolution (with negative culture) within 4 wk; no relapse in 4 mo

Huang, 2003, Taiwan <sup>[49]</sup>	6 yr, M	Oral Pen and topical mupirocin, 14 d: clinical healing after 4 d	After starting Pen: desquamation of fingers and perioral skin
Reimer, 2004, Sweden <sup>[50]</sup>	1. 4 yr, M 2. 6 yr, M 3. 4 yr, F	Oral Pen in all cases: quickly healed	
Takeshita, 2006, Japan <sup>[51]</sup>	1. 2 yr, F 2. 6 mo, M	Oral antibiotics: rapid resolution of the condition	
Usuki, 2006, Japan <sup>[52]</sup>	5 yr, F	Oral and topical antibiotics	
Ulger, 2007, Turkey <sup>[53]</sup>	3 yr, M	Oral Pen, 2 wk; topical corticosteroids for GP; all lesions healed	No recurrence
Greisser, 2008, Swiss <sup>[54]</sup>	7 yr, M	Oral amoxicillin, 6 d: Rapid improvement	No recurrence
Ledoux, 2009, France <sup>[55]</sup>	4 yr, M	Josamycin 1 mo and desonide for GP: All symptoms subsided	No relapse in 6 mo
Rasi, 2009, Iran <sup>[56]</sup>	4 yr, M	Oral amoxicillin, 10 d: Clinical response within 3 d, healed in 3 wk; GAS negative after 3 wk	No improvement of psoriatic lesions
Block, 2013, United States <sup>[57]</sup>	1. 2 mo, F 2. 4 mo, F	Amoxicillin, 10 d, in both patients	No recurrence in both cases
Theotokatou, 2014, Greece <sup>[58]</sup>	1. 8 yr, M 2. 10 yr, M, brother	Oral cefuroxime and topical mupirocin for both brothers: effective by day 4	
Zhang 2016, Canada <sup>[3]</sup>	1. 4 yr, M 2. 4 yr, M 3. 3 yr, F	1. Oral cefuroxime, 7 d plus topical fucidin 2. Oral cefuroxime, 7 d plus betamethasone for GP 3. Oral cefuroxime, 7 d plus topical fucidin; persistent erythema and discharge	1. 3 mo later: Throat and anus GAS negative; PID cleared 2. 2 wk later, perianal GBS positive: topical Fucidin; 3 mo later: GBS negative and cleared GP 3. Vulvar culture: GCS and GBS, perianal culture: GCS; culture from vaginal introitus: positive GAS: oral amoxicillin, 10 d
Garritsen, 2017, Netherlands <sup>[60]</sup>	19 mo, M	Oral Pen plus mometasone for GP; 4 wk: PID and GP significantly improved	
Serban, present study, Romania	1. 9 yr 4 mo, M 2. 9 yr 6 mo, M 3. 11 yr 9 mo, M	1. Spiramycin and topical mupirocin, 2 wk: improvement after 2 d; perianal culture negative on day 7; completely healed after 12 d 2. Spiramycin, 2 wk: improvement since day 2; negative perianal culture on day 7; completely healed after 1 wk 3. Spiramycin and topical bacitracin plus neomycin, 3 wk: improvement after 5 d; negative perianal culture on day 7; healed completely after 2 wk	1. No recurrence after 2 yr 2. No recurrence after 7 mo 3. No recurrence after 2 mo

F: Female; GAS: Group A beta-hemolytic streptococci; GBS: Group B beta-hemolytic streptococci; GCS: Group C beta-hemolytic streptococci; GP: Guttate psoriasis; IM: Intramuscular; IV: Intravenous; M: Male; Pen: Penicillin; PID: Perianal infectious dermatitis.

atopic dermatitis; chronic dialysis; and, malnutrition.

## ETIOLOGY

The vast majority of cases in the pediatric literature are caused by GAS (Tables 1 and 3). It has been considered that the type T28 emm 28 of GAS (one of the most detected types causing PID) harbors unique properties, which may increase the likelihood of perineal infection<sup>[4,5,27,37,41]</sup>. However, other agents have been detected as well, like GBS<sup>[3,8,11,26]</sup> (such cases include 1 from this author's own experience), group C streptococci (GCS)<sup>[3]</sup>, group G streptococci (GGS)<sup>[11]</sup>, *Staphylococcus aureus* (*S. aureus*)<sup>[15,26,32]</sup>, and *Enterococcus faecalis* (*E. faecalis*)<sup>[58]</sup>. Mostafa *et al*<sup>[15]</sup> reported 150 children with PID, over a period of 4 mo, from which 35.3% were positive for beta-hemolytic streptococci (BHS) (GAS representing 21.3% and non-GAS representing 18%) and 3.4% for *S. aureus*. In a retrospective 10-year study of patients with PID, 105 BHS were isolated from the perianal area of the same number of patients. GAS, GBS, GCS and

GGS were cultured in 69.5%, 25.7%, 2.8% and 2%, respectively<sup>[24]</sup>.

## PATHOGENESIS

A few theories have been suggested for the infection of the perianal area, especially for GAS. They include spread by hand contact with the oral cavity and then perianal area, deglutition of GAS with dissemination along the gastrointestinal tract, contaminated fomites (communal bathtubs or toilets), and airborne spread<sup>[3,5,79,85,86]</sup>. GAS are not considered part of the perianal skin flora<sup>[2]</sup> and asymptomatic carriage is exceedingly rare<sup>[22]</sup>.

Digital oral-anal contact is a well-documented route<sup>[5,8,24]</sup>. The perianal area could be infected by scratching with hands containing bacteria from mouth or nose or other skin infected sites. Bacteria could belong to the same person (autoinoculation)<sup>[2]</sup> or to other people<sup>[1,5,8,24]</sup>, either from respiratory tract (aerosols), flatulence<sup>[86]</sup> or direct touch (*i.e.*, kisses from a sibling)<sup>[57]</sup>. Some children with PID caused by GAS had other members of the family

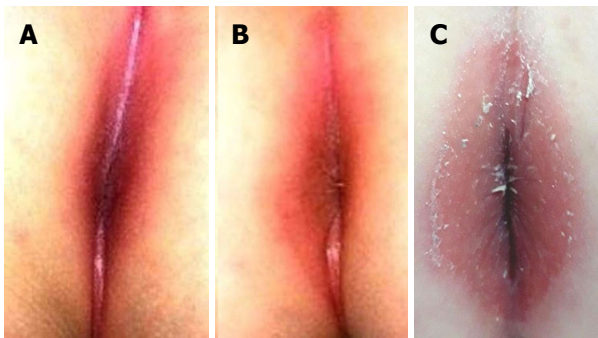
**Table 5 Previous investigations, diagnoses and therapies in children with perianal infectious dermatitis**

Name, yr, country	Population size; age; sex	Previous performed investigations and/or suspected diagnosis	Previous therapy
Spear, 1985, United States <sup>[28]</sup>	14; mean age 3.9 yr (range: 1-10 yr); M/F: 3.7/1	2 proctoscopies under general anesthesia, upper gastrointestinal x-ray series, barium enema; anal fissure, IBD, behavior disturbance, psychogenic stool holding, psoriasis, candidiasis, ammoniacal diaper dermatitis	Laxatives, suppositories, hydrocortisone, polymyxin, bacitracin and neomycin, povidone-iodine, triamcinolone
Farmer, 1987, United Kingdom <sup>[65]</sup>	1. 4 yr, M 2. 5 yr, F	1. Anal pinworms (negative) 2. Anal pinworms (negative)	1. Piperazine, miconazole, and hydrocortisone cream 2. Clotrimazole cream
Kokx, 1987, United States <sup>[4]</sup>	31; 7 mo to 8 yr, mean 4.25 ± 1.8 yr; M 77%	Hemorrhoids, poor hygiene, perianal allergy to toilet paper perfumes, rectal fissures, and/or constipation	
Rehder, 1998, United States <sup>[61]</sup>	1. 3 yr, M 2. 3 yr, M  3. 4 yr, M	  3. Pinworms	1. Soaks, topical antifungals and corticosteroids 2. Topical hydrocortisone, nystatin, triamcinolone and zinc oxide 3. Oral cefaclor, with clearing of erythema, but recurrence
Marks, 1988, United States <sup>[63]</sup>	5 yr, M	Pinworms and stool for ova and parasites: negative	Topical A and D ointment, hydrocortisone, ketoconazole
Duhra, 1990, United Kingdom <sup>[29]</sup>	5 yr, M	Considered as possible case of sexual abuse; threadworms, candidiasis, psoriasis and eczema	Treatment for threadworms, candidiasis, psoriasis and eczema
Goodyear, 1991, United Kingdom <sup>[30]</sup>	4 yr, M	Examination under anesthesia and proctoscopy	Stool softeners, stimulant laxatives, topical anesthetics, steroid and antifungal creams
Montemarano, 1993, United States <sup>[32]</sup>	3 yr, M		Topical and oral nystatin
Grant, 1993, United Kingdom <sup>[10]</sup>	20; 5 mo to 12 yr; 75% M	2 cases: suspected Crohn's disease 1 case: suspected sexual abuse	3 patients treated for worms, 7 treated for constipation, 5 topical treatment (steroids, lignocaine, eosin, fucidin)
Guppy, 1993, Australia <sup>[33]</sup>	1. 7 yr, M  2-3. 5 and 2.5 yr  4. 4 yr, M		1. Topical antifungal, antibacterial and steroid creams, oral pyrantel embonate and metronidazole 2-3. Various antifungal, antibacterial and steroid creams, oral pyrantel embonate 4. Local nystatin, hydrocortisone; oral pyrantel embonate
Patrizi, 1994, Italy <sup>[22]</sup>	5; 4-10 yr; 3 M		Topical agents, including steroid cream
Bugatti, 1998, Italy <sup>[39]</sup>	12 yr, M		Topical antifungal agents
Adams, 1999, Canada <sup>[40]</sup>	1 yr, M		Topical corticosteroids and clotrimazole
Roos, 1999, Sweden <sup>[41]</sup>	5 yr, M		Topical steroids
Herbst, 2000, Germany <sup>[9]</sup>	4 yr, M		Various ointments for the last several months
Brilliant, 2000, United States <sup>[43]</sup>	1. 4 yr, M  4. 4 yr, F		1. Topical ointment and baby powder, topical antifungal 4. Topical antifungal
Heidelberger, 2000, Germany <sup>[45]</sup>	1. 6 yr, M 2. 9 yr, M		1. Tannolact seat baths and topical tetracycline 2. Tannolact seat baths and topical clotrimazole
Soulliet, 2000, France <sup>[13]</sup>	7 yr, F	Candidiasis	Nystatin unsuccessful for suspected candidiasis
Lunghi, 2001, Italy <sup>[47]</sup>	Brother (4 yr) and sister (6 yr)		Both: Local and oral antifungal drugs for 4 mo
Mateo, 2002, Spain <sup>[19]</sup>	10; 9 mo to 7 yr; 6 M		4 cases: 2 steroids cream, 1 clotrimazole cream and 1 betamethasone and clotrimazole cream
Reimer, 2004, Sweden <sup>[50]</sup>	1. 4 yr, M 3. 4 yr, F	1. Pinworms (negative)	3. Local ointment (kenacutan)
Jongen, 2008, Germany <sup>[8]</sup>	21; < 14 yr (mean age 6.3 yr), 76% M	Anoscopy and rectoscopy: negative	Topical agents (zinc paste, corticosteroids, antimycotic ointments)
Rasi, 2009, Iran <sup>[56]</sup>	4 yr, M		Topical antibiotics, steroids and antifungal creams, 3 mo
Zhang, 2016, Canada <sup>[3]</sup>	1: 4 yr, M 3: 3 yr, F		1. Topical terbinafine and hydrocortisone acetate 3. Gentle skin care, zinc barrier cream, topical antifungals, corticosteroids, and mupirocin
Garritsen, 2017, Netherlands <sup>[60]</sup>	19 mo, M		Topical corticosteroids and antimycotic agents



Serban, present paper, Romania	1. 9 yr 4 mo, M	1. Psoriasis, pinworms, candidiasis, eczema; Hospitalization in 6 public clinics and 2 private hospitals; upper and lower endoscopy under general anesthesia; magnetic resonance enterography – all negative; considered as Crohn's disease and sent to our clinic	1. Topical antibiotics, steroids, antifungal and anesthetics creams; oral antiallergics
	2. 9 yr 6 mo, M	2. Pinworms, intestinal dysbiosis	2. Oral probiotics and therapy against worms; topical baneocin and neomycin, cortisone and anti-hemorrhoids
	3. 11 yr 9 mo, M	3. Eczema, anal fissure, constipation	3. Oral probiotics, osmotic laxatives and stool softeners; topical hydrocortisone, cicatrizants

F: Female; IBD: Inflammatory bowel disease; M: Male.



**Figure 1** Perianal infectious dermatitis. A, B, C: Well-demarcated perianal erythema; B, C: With white exudate. Personal cases from the author (Elena Daniela Serban).

recently diagnosed with GAS pharyngitis (siblings<sup>[57,61]</sup>, mother<sup>[38,41]</sup> or father<sup>[50]</sup>). Self-inoculation has been reported in studies showing positive throat culture for GAS when PID was diagnosed. The rates of isolation of GAS from the throat of these children (with or without concomitant pharyngitis) have varied from 28%<sup>[2]</sup> to 38%<sup>[14]</sup>, 50%<sup>[19]</sup>, 53.8%<sup>[15]</sup>, 64%<sup>[4]</sup>, 80%<sup>[6]</sup>, 92%<sup>[5]</sup> and 95%<sup>[23]</sup>. The high pharyngeal carrier frequency found in the studies by Mogielnicki *et al*<sup>[5]</sup> and Clegg *et al*<sup>[23]</sup> was considered very suggestive for PID, leading to a quick diagnosis (only 9.8 d)<sup>[23]</sup>. Also, case reports showed the same finding - concomitant positive throat culture for GAS<sup>[3,13,22,37,47,49,59,61]</sup> and 1 case from this author) and presence of *S. aureus* in the anterior nares<sup>[32]</sup>.

Eradication from pharynx could be more rapid than from the perineal area, explaining the various frequencies<sup>[5]</sup>. Conversely, only 6% of children with GAS pharyngitis are anal carriers of GAS<sup>[87]</sup>. In one study, the T-types of the pharyngeal and perianal GAS were identical<sup>[4]</sup>. Other authors also showed that the same perianal GAS was found in the throat<sup>[15,23,37,61]</sup>. Mostafa *et al*<sup>[15]</sup> reported 3.4% of PID caused by *S. aureus*, with the same bacteria in the throat in 2.7% of cases.

Children may infect the perianal skin also while using a shared toilet (sitting on it or cleaning the area after touching toilet, without washing hands) and/or communal baths<sup>[4,22,33,36]</sup>, facts that could also explain the intrafamilial or interfamilial spread<sup>[1,27,37]</sup>. During the outbreak in a daycare center, the transmission route was reported to be most likely the common toilet and especially its GAS-

contaminated plastic toilet seat<sup>[37]</sup>.

Also, it had previously been suggested that oral bacteria can pass intact into the digestive tract and colonize the anus; however, this hypothesis is not accepted anymore<sup>[56]</sup>.

## CLINICAL PRESENTATION

Specifically, symptoms appear in otherwise healthy children, without fever, malaise or other systemic symptoms<sup>[1,33,44]</sup>. Symptoms like anal pruritus (itching), painful defecation with consequent retentive constipation, anal pain, mucous (sometimes purulent)<sup>[12,14]</sup> and/or bloody anal discharge (blood-streaked stools) are usually present<sup>[2,4-8,10,28,43,59]</sup>. Very rarely, abdominal pain (related to defecation or to retention to defecation)<sup>[21]</sup>, fecal incontinence<sup>[2,21,30]</sup> or tenesmus<sup>[21,22]</sup> could be associated. Exceptionally, other symptoms have been reported, including fever<sup>[21,44]</sup>, irritability<sup>[18]</sup>, diarrhea<sup>[15,36]</sup> and muscular pain<sup>[38]</sup>. Synthesizing data from the literature (Tables 1 and 3), the following frequencies of symptoms and signs are detected: perianal itching (78%-100%); painful defecation (50%); constipation (47%-58%); blood-streaked stools (21%-60%); purulent secretion (27%); anal fissures (26%-40%); perianal pain (20%); and, mucous discharge at the anal margin (10%)<sup>[4-8,10,11,14,17,20,21]</sup>.

The hallmark of PID (found in all included cases) is represented by the aspect of the perianal area - superficial, intense edematous vivid red erythema (like "raw beef"), rarely pink, sharply demarcated, extending 2-4 cm around the anus<sup>[1-10]</sup>. The area is sometimes extremely tender, rendering physical examination very difficult. White exudate, pseudomembranes and superficial anal fissures or cracks could also be detected<sup>[1,10-12]</sup>. Three cases of PID from this author's experience are illustrated in Figure 1. The typical appearance could change, however, after applying various topical creams, rendering the diagnosis more difficult.

Infection can extend to genital organs, resulting in vulvo-vaginitis<sup>[2,3,5,6,13,16,21-23,43,47,50,57,65]</sup> or balanitis<sup>[3,22,23,29,33,42,45,50,64]</sup>, and cultures from these areas grow same type of bacteria<sup>[2,22,29]</sup>. Small papules or pustules on the buttocks are suggestive for *S. aureus*<sup>[26,32]</sup>. Sometimes, extraperineal rash (mostly papulo-pustular or impetiginous) could also be associated, up to 35.8% in a recent series<sup>[25]</sup>. Another cutaneous finding, acral

desquamation (following therapy for PID caused by GAS and concomitant with resolution of PID) was reported by three authors; these included fingers<sup>[42,46,49]</sup>, toes<sup>[42]</sup>, and perioral skin<sup>[49]</sup>. The presence of acral desquamation has been suggested to be the effect of streptococcal exotoxin<sup>[42,46,49]</sup>. Rarely, when PID is diagnosed early, concomitant pharyngitis may be found<sup>[6,21,22,25]</sup>.

## INVESTIGATIONS

Simple methods are required to diagnose PID (Tables 1 and 3). Culture of anal, perianal and perineal swabs represent the best option for diagnosis<sup>[3]</sup>. Physicians should specifically ask for *BHS* culture, on blood agar plates, as laboratories do not adequately search for them in the evaluation of routine perianal swabs<sup>[8,11,20,28,57,59]</sup>. Culture allows detection of the bacteria causing PID, besides GAS (including *non-GAS*, *S. aureus* and *E. faecalis*)<sup>[3,26,32,58]</sup>. Moreover, it allows identification of their sensitivity to antibiotics, given that antibiotic resistance has become a seriously increasing issue across the world. Stool culture is not recommended<sup>[24]</sup>.

For GAS, the rapid antigen detection test (RADT) of the swab could be used, allowing a quicker diagnosis<sup>[24]</sup>. Depending on the method of RADT, the sensitivity for extrapharyngeal GAS ranges from 77.9% to 98.0%, suggesting that this test may represent a rapid, practical and accurate diagnostic tool for point-of-care differentiation of GAS associated PID from other conditions with similar presentations<sup>[88]</sup>. A recent French prospective multicenter study showed RADT to have a sensitivity of 98% and a specificity of 72.8%<sup>[16]</sup>. However, RADT does not have formal approval for extrapharyngeal testing<sup>[16,57]</sup>. A negative RADT result needs additional testing by bacterial culture<sup>[3,23,74]</sup>.

Sophisticated tests, like pulse field gel electrophoresis, allowing genotyping of the bacteria, are reserved for research studies<sup>[37]</sup>, especially to determine if types of bacteria are identical in outbreaks.

## DIAGNOSIS

As shown, with a high index of suspicion, the simple culture (or RADT) of the perianal skin confirms the PID diagnosis<sup>[28]</sup>. Although most patients included in this review were seen primarily by their pediatrician or family physician, only three papers were published by physicians from primary healthcare facilities<sup>[5,7,50]</sup>. Most published reports diagnosing PID have come from dermatologists, working in dermatology university centers<sup>[3,15,20,22,31,34,35,40,42,45,52,56,63,79]</sup> or hospitals<sup>[29,32,47,55]</sup>, as well as from those in pediatric dermatology university centers<sup>[49,53,54,60-62]</sup> or hospitals<sup>[13,19,26,30]</sup>. Also, many of the patients were diagnosed by physicians from pediatric university centers<sup>[6,17,18,21,23,25,27,44,57]</sup> or hospitals<sup>[4,10,16,33,36,39,64,65]</sup>. There were four reports of PID diagnosed in surgery services<sup>[8,11,51,58]</sup>. Only one paper was published, respectively, by authors from a pediatric

gastroenterology clinic<sup>[46]</sup>, pediatric radiology clinic<sup>[38]</sup>, pediatric infectious clinic<sup>[14]</sup>, ear nose and throat clinic<sup>[41]</sup> and from an emergency medicine hospital<sup>[43]</sup>.

Characteristically, a delay in diagnosis is reported by most authors (mean of 6 mo, ranging from 1 mo to 1 year)<sup>[28]</sup>. As such, many children undergo unnecessary investigations and therapies<sup>[33]</sup>. A few reports showed a 2-year delay to diagnosis<sup>[8,19,62]</sup>. However, diagnosis is sometimes established within 1 mo (e.g., 3 wk<sup>[13,19,58,61,65]</sup>, 2 wk<sup>[7,8,16,25,51,55,63]</sup>, 10 d<sup>[23,46]</sup>, 1 wk<sup>[25,37,52]</sup>, 3 d<sup>[54]</sup> and 2 d<sup>[53]</sup>). Table 5 presents previous suspected diagnoses and performed tests in children with PID (including the present cases). As shown, PID was misdiagnosed most often as candidiasis<sup>[13,28,29]</sup>, pinworms<sup>[50,61,65]</sup>, anal fissure<sup>[4,28]</sup>, psoriasis<sup>[28,29]</sup>, possible sexual abuse<sup>[10,29]</sup>, eczema/atopic dermatitis<sup>[29]</sup>, constipation<sup>[4]</sup>, Crohn's disease<sup>[10]</sup>, inflammatory bowel disease, ammoniacal diaper dermatitis, psychogenic stool holding<sup>[28]</sup>, threadworms<sup>[29]</sup>, hemorrhoids, poor hygiene, perianal allergy<sup>[4]</sup>, and gut dysbiosis. As seen, not only can misdiagnosis lead to improper therapies but also to potential severe consequences on family harmony and to legal issues. Just carrying out anal tests for pinworms appears far less erroneous, costly and/or invasive than performing lower and upper endoscopies under general anesthesia<sup>[8,28,30]</sup>, upper gastrointestinal X-ray series and barium enema<sup>[28]</sup>, as well as magnetic resonance enterography.

## DIFFERENTIAL DIAGNOSIS

As anticipated from the previous paragraph, differential diagnosis of PID is vast and, unfortunately, patients are commonly overlooked<sup>[4,43,57,58]</sup>. Besides the conditions already mentioned, differential diagnosis encompasses seborrheic dermatitis, Langerhans cell histiocytosis, zinc deficiency dermatosis<sup>[43,54,88]</sup>, intertrigo<sup>[18]</sup>, redness from vigorous wiping, fecal incontinence<sup>[11]</sup>, and lichen planus<sup>[1]</sup>.

## DISEASE COURSE AND COMPLICATIONS

PID does not resolve spontaneously. The longer the time until correct diagnosis and therapy, the higher is the risk for discomfort and complications. Complications related to streptococcal infections include impetigo<sup>[13,25,45]</sup> and immunological conditions, like post-streptococcal acute glomerulonephritis (commonly known as PSAGN) and rheumatic fever. Although among the included studies, no such immunological complications were found, a urine analysis may be performed to screen for possible PSAGN<sup>[7,79]</sup>. GAS-associated PID may trigger acute guttate psoriasis (GP)<sup>[3,9,19,22,48,53,55,60-62,83]</sup>, plaque-psoriasis<sup>[56]</sup> or pustular psoriasis<sup>[77]</sup>. Treating PID also resolves the skin disease, as was mostly reported, except for 1 case of GP<sup>[3]</sup> and 1 of plaque-psoriasis<sup>[56]</sup>. Among the cases with GBS-associated PID, GP developed in 1 child<sup>[3]</sup> and one adult<sup>[83]</sup>. GP could be determined by stimulation of T cells by superantigens, in GAS infections; however, GBS do not produce superantigenic exotoxins<sup>[3]</sup>. In patients with GP, the perianal/perineal area should be carefully inspected,

and cultured when appropriate, to exclude PID as a triggering factor<sup>[20,60]</sup>.

## TREATMENT

Since PID usually goes unrecognized for a long time, patients are erroneously treated for other conditions, as shown in Table 5 (including the present cases). The most used topical agents were antifungal agents<sup>[3,13,16,22,27,31-33,35,36,42,43,47,49,51,61,64,65]</sup> and corticosteroids<sup>[3,4,8,10,19,22,28-30,33,40,41,56,60,61]</sup>. Other topical agents were represented by antibiotics<sup>[3,10,28,33,45,56]</sup>, antiseptics, suppositories<sup>[10,28]</sup>, zinc oxide<sup>[3,4,8]</sup>, anesthetics<sup>[10,30]</sup>, kenacutan<sup>[50]</sup>, tannate<sup>[45]</sup>, vitamins A and D<sup>[61]</sup>, antihemorrhoids and cicatrizants. Oral medication included laxatives<sup>[10,28,30]</sup>, anthelmintics<sup>[10,33,65]</sup>, antibiotics<sup>[4,33]</sup>, nystatin<sup>[32,47]</sup>, antihistaminic agents and probiotics. A survey on general practitioners from an area in the United Kingdom appears as very illustrative for the various modalities of managing this peculiar condition. After a case with PID was presented, physicians were asked what their management would be at the first consultation. Their answers included "anthelmintics (54%), stool softeners (52%), taking a perianal swab (31%), topical anesthetics (28%), antifungal cream (22%), looking for possible sexual abuse (17%), topical antiseptics (11%), systemic antibiotics (7%), and looking for inflammatory bowel disease (7%)"<sup>[7]</sup>. This highlights PID as being largely unknown still; and, more worrisomely, almost one-fifth of the general practitioners considered investigating for possible sexual abuse.

Conversely, an early correct antibiotic therapy leads to a dramatic and rapid improvement of symptoms, in 1 d<sup>[43]</sup>, 2 d<sup>[2,13,37,39]</sup> or 3 d<sup>[2,44,56]</sup>, with reports showing healing of PID after 4 d<sup>[49,58]</sup> (Tables 2 and 4). The actual goal of therapy is represented by complete healing (CH), meaning disappearance of clinical signs and eradication of perianal bacteria. CH has been reported 2 wk<sup>[4,9,14,30,61,62]</sup> to 4 wk after starting therapy<sup>[47]</sup>.

Two studies mentioned obtaining CH with topical antibiotics as a sole therapy (erythromycin<sup>[34]</sup> and mupirocin<sup>[31]</sup>); however, oral antibiotics are considered the medication of choice<sup>[13,25,79]</sup>. Classically, the medication of choice against GAS consisted of oral penicillin (Pen)<sup>[2,4,8,10,12,17,20-22,25,27-30,33,37,45,46,50,53,59-63]</sup> (Tables 2 and 4). Duration of Pen therapy ranged from 7 d<sup>[65]</sup> to 10 d<sup>[2,4,6,8,12,17,20,27,30,33,36,37,44,45,62]</sup>, 2 wk<sup>[8,22,33,53,61,63]</sup>, 3 wk<sup>[10,29,61]</sup> and 4 wk<sup>[22]</sup>. Amoxicillin has been considered a good alternative<sup>[19,21,43]</sup>, given for 6 d<sup>[54]</sup>, 10 d<sup>[4,13,36,39,56,57]</sup> or 2 wk<sup>[22]</sup>. Other authors used cefaclor<sup>[42]</sup>, amoxicillin-clavulanate<sup>[11,17]</sup>, erythromycin<sup>[22]</sup>, or josamycin<sup>[55]</sup>. In many cases, oral antibiotic was used in combination with a topical agent. Pen was associated with topical antibiotics (mupirocin<sup>[20,21,36,40]</sup> or fucidin<sup>[9,10,36]</sup>) or antiseptics (clioquinol<sup>[45]</sup> or polyhexanid<sup>[8]</sup>). Amoxicillin was combined with fucidin<sup>[36]</sup> or mupirocin<sup>[14,18]</sup> and amoxicillin-clavulanate with topical bacitracin<sup>[11]</sup>. As for macrolides, erythromycin was associated with mupirocin<sup>[22]</sup> and spiramycin was used in the cases belonging to the present

author, in combination with mupirocin and bacitracin plus neomycin, respectively. Cefadroxil was associated with fucidin<sup>[41]</sup> and cefuroxime with fucidin<sup>[3]</sup> or mupirocin<sup>[58]</sup>. Cefuroxime plus topical fucidin was used in PID caused by GAS and *S. aureus*, by GBS and by GCS<sup>[3]</sup>. In cases with *S. aureus* only, oral erythromycin and cephalexin were used<sup>[26,32]</sup>.

It is quite difficult to appreciate the treatment efficacy, since some authors reported only clinical healing, while others considered CH and others did not mention the type of healing. CH was reported after Pen<sup>[22]</sup>, amoxicillin<sup>[56]</sup>, cefaclor<sup>[42]</sup>, Pen combined with fucidin<sup>[9]</sup>, erythromycin with mupirocin<sup>[22]</sup>, spiramycin with mupirocin or with bacitracin plus neomycin. More details about the CH are presented in Tables 2 and 4<sup>[4,6,14,18]</sup>.

Some patients required a second course of antibiotic, either to cure symptoms or to eradicate perianal bacteria, or both. Some authors preferred to use the same antibiotic (Pen<sup>[2,17,20,29]</sup>, amoxicillin<sup>[22]</sup> or cephalexin<sup>[26]</sup>), detailed in Tables 2 and 4. Other authors chose a different antibiotic for the second course. After ineffective oral Pen, erythromycin<sup>[22,61]</sup>, cefaclor<sup>[37]</sup> or clarithromycin<sup>[17,27]</sup> determined CH. In a GCS-associated PID case, after oral cefuroxime plus topical fucidin being ineffective, oral amoxicillin lead to CH<sup>[3]</sup>.

The only published RCT, by Meury *et al*<sup>[12]</sup>, compared 15 children treated with oral Pen with 14 cases with cefuroxime, all with GAS-associated PID. Both clinical improvement and eradication of perianal GAS were significantly higher with cefuroxime *versus* Pen (Table 2). However, the study was not blinded and there was no follow-up after the end of treatment, precluding evaluation of optimal duration for the cefuroxime therapy<sup>[12]</sup>.

## PROGNOSIS

From the data presented, it appears that most cases are easy to cure (*i.e.*, reaching CH). However, recurrence (clinical and/or bacteriological) may occur and a repeated course of antibiotics is required<sup>[4]</sup>. Assessing recurrence rate appears rather difficult, as most cases did not have a precise follow-up period. No clinical recurrence was reported after oral Pen<sup>[30]</sup>, amoxicillin-clavulanate<sup>[11]</sup> and cefadroxil plus topical fucidin<sup>[11]</sup>. No clinical and bacteriological recurrence was detected after topical mupirocin<sup>[31]</sup> and josamycin<sup>[17]</sup>. In the study by Kokx *et al*<sup>[4]</sup>, the 39% relapses were treated with Pen. In children treated with amoxicillin plus mupirocin, the recurrence rate varied between 11%<sup>[14]</sup> and 27%<sup>[18]</sup>. In a series of 21 cases treated with oral Pen plus topical polihexanid, only 5% showed recurrence<sup>[8]</sup>.

In one of the largest published studies of GAS-associated PID (81 cases), recurrence was detected in 32% of cases, significantly higher after Pen or amoxicillin *vs* a beta-lactamase-resistant antibiotic (Table 2). A meta-analysis performed by the same authors showed that the pooled recurrence rate after Pen or amoxicillin was significantly higher than after a beta-lactamase-resistant antibiotic (odds ratio: 2.39, 95%CI: 1.18-4.81)<sup>[25]</sup>. In



the largest (157 cases with GAS-associated PID) and most recent series, patients were treated with various antibiotics. The clinical recurrence rate, 6 mo after the first episode, was much higher after using cephalexin *versus* amoxicillin (Table 2). Recurrence after amoxicillin was predicted by a delayed diagnosis and having a sibling with PID around the time of the first episode<sup>[23]</sup>.

Recurrences appearing soon after therapy may be due to poor compliance with antibiotics or their inadequate dosage. Alternatively, some recurrences could be the result of a reinfection in the context of a continuous exposure (intrafamilial or close contact), due to poor hygiene<sup>[4]</sup>. Therefore, in those with frequent relapses, it is recommended to screen (and eventually treat) other members of the family<sup>[57]</sup>. Improvement of personal (hands washing, individual use of toothbrush, towels, toilets, etc.) and collective hygiene is indispensable.

## CONCLUSION

To the best of the author's knowledge, this is the first narrative review of all published available pediatric cases with PID, to date. Although the clinical characteristics of PID are well-defined, it still remains a misdiagnosed entity, with an underestimated frequency. PID could appear at any age and affect females as well. Given its infectious origin, PID may have intra- and/or interfamily spread. The vast majority of cases are caused by GAS; however, other BHS (like GBS, GCS and GGS) and *S. aureus* have been described. These bacteria could also be found in the upper respiratory tract. Since PID may mimic other common conditions with skin manifestations, laboratory tests are required for correct diagnosis. RADT could suffice to identify GAS, but bacterial culture is the most reliable tool for diagnosis. If not properly diagnosed and treated, PID has a chronic, unremitting course.

Oral Pen or amoxicillin could be used for the initial treatment of BHS-associated PID; however, the recurrence rate is high (up to 40%). Various beta-lactamase-resistant antibiotics could be used instead (like cephalosporines, amoxicillin-clavulanate, macrolides and clindamycin). Combining oral antibiotics with topical antiseptics or antibiotics may accelerate bacterial clearance. Duration of therapy should be 14-21 d. Therapeutic efficacy should be appreciated both clinically and bacteriologically; throat culture should also be repeated, if it was positive. Recurrence rates of PID remain high. Improvement of personal and collective hygiene is essential.

## RESEARCH PERSPECTIVES

Prospective well-designed (multicenter) clinical trials are required in order to detect the incidence of this condition. Moreover, randomized controlled studies, with adequate follow-up, should be performed in order to formulate the optimum personalized antibiotic therapy (oral alone or in association with topical medication) able to induce complete healing and prevent recurrences. An interesting topic of future research will be determining

whether the same bacteria cause recurrences.

## REFERENCES

1. Juern AM, Drolet BA. Cutaneous bacterial infections. In: Kliegman RM, Stanton BF, St. Geme III JW, Schor NF, editors. Nelson Textbook of Pediatrics. 20<sup>th</sup> ed. Philadelphia: Elsevier, 2016: 3209
2. Amren DP, Anderson AS, Wannamaker LW. Perianal cellulitis associated with group A streptococci. *Am J Dis Child* 1966; **112**: 546-552 [PMID: 5928818 DOI: 10.1001/archpedi.1966.02090150090007]
3. Zhang C, Haber RM. The ABCs of Perineal Streptococcal Dermatitis. *J Cutan Med Surg* 2017; **21**: 102-107 [PMID: 27628908 DOI: 10.1177/1203475416670369]
4. Kokx NP, Comstock JA, Facklam RR. Streptococcal perianal disease in children. *Pediatrics* 1987; **80**: 659-663 [PMID: 3313256]
5. Mogielnicki NP, Schwartzman JD, Elliott JA. Perineal group A streptococcal disease in a pediatric practice. *Pediatrics* 2000; **106**: 276-281 [PMID: 10920151 DOI: 10.1542/peds.106.2.276]
6. Echeverría Fernández M, López-Menchero Oliva JC, Marañón Pardillo R, Míguez Navarro C, Sánchez Sánchez C, Vázquez López P. [Isolation of group A beta-hemolytic Streptococcus in children with perianal dermatitis]. *An Pediatr (Barc)* 2006; **64**: 153-157 [PMID: 16527068 DOI: 10.1157/13084175]
7. Lehman R, Pinder S. Streptococcal perianal infection in children. *BMJ* 2009; **338**: b1517 [PMID: 19416994 DOI: 10.1136/bmj.b1517]
8. Jongen J, Eberstein A, Peleikis HG, Kahlke V, Herbst RA. Perianal streptococcal dermatitis: an important differential diagnosis in pediatric patients. *Dis Colon Rectum* 2008; **51**: 584-587 [PMID: 18324440 DOI: 10.1007/s10350-008-9237-0]
9. Herbst RA, Hoch O, Kapp A, Weiss J. Guttate psoriasis triggered by perianal streptococcal dermatitis in a four-year-old boy. *J Am Acad Dermatol* 2000; **42**: 885-887 [PMID: 10767696 DOI: 10.1016/S0190-9622(00)90263-9]
10. Grant HW, MacKinlay GA, Bisset WH, Uttley WS. Perianal cellulitis in children caused by group A streptococcus. *Pediatr Surg Int* 1993; **8**: 410-411 [DOI: 10.1007/BF00176730]
11. Wright JE, Butt HL. Perianal infection with beta haemolytic streptococcus. *Arch Dis Child* 1994; **70**: 145-146 [PMID: 8129441 DOI: 10.1136/adc.70.2.145]
12. Meury SN, Erb T, Schaad UB, Heininger U. Randomized, comparative efficacy trial of oral penicillin versus cefuroxime for perianal streptococcal dermatitis in children. *J Pediatr* 2008; **153**: 799-802 [PMID: 18692203 DOI: 10.1016/j.jpeds.2008.06.035]
13. Souillet AL, Truchot F, Jullien D, Dumas V, Faure M, Floret D, Claudy A. [Perianal streptococcal dermatitis]. *Arch Pediatr* 2000; **7**: 1194-1196 [PMID: 11109946 DOI: 10.1016/S0929-693X(00)00129-9]
14. Barzilai A, Choen HA. Isolation of group A streptococci from children with perianal cellulitis and from their siblings. *Pediatr Infect Dis J* 1998; **17**: 358-360 [PMID: 9576401 DOI: 10.1097/00006454-199804000-00024]
15. Mostafa WZ, Arnaout HH, el-Lawindi MI, el-Abidin YM. An epidemiologic study of perianal dermatitis among children in Egypt. *Pediatr Dermatol* 1997; **14**: 351-354 [PMID: 9336803 DOI: 10.1111/j.1525-1470.1997.tb00979.x]
16. Cohen R, Levy C, Bonacorsi S, Wollner A, Koskas M, Jung C, Béchet S, Chalumeau M, Cohen J, Bidet P. Diagnostic accuracy of clinical symptoms and rapid diagnostic test in group A streptococcal perianal infections in children. *Clin Infect Dis* 2015; **60**: 267-270 [PMID: 25313248 DOI: 10.1093/cid/ciu794]
17. Landolt M, Heininger U. Prevalence of perianal streptococcal dermatitis in children and adolescents. *Praxis (Bern 1994)* 2005; **94**: 1467-1471 [PMID: 16209362 DOI: 10.1024/0369-8394.94.38.1467]
18. Shouval DS, Schurr D, Nussinovitch M. Presentation of perianal group A streptococcal infection as irritability among children. *Pediatr Dermatol* 2008; **25**: 568-570 [PMID: 18950404 DOI: 10.1111/j.1525-1470.2008.00737.x]
19. Mateo JR, Carrero González PA, Pérez ES. Dermatitis estreptocócica perianal. *Actas Dermosifiliogr* 2002; **93**: 243-246 [DOI: 10.1016/S0001-7310(02)76565-4]
20. Krol AL. Perianal streptococcal dermatitis. *Pediatr Dermatol* 1990; **7**: 97-100 [PMID: 2359737 DOI: 10.1111/j.1525-1470.1990.tb00662.x]

- 21 **García Osés I**, Martínez de Zabarte Fernández JM, Puig García C, Arnal Alonso JM. Pensando en la dermatitis perianal. *Pediatría Atención Primaria* 2015; **17**: 51-55 [DOI: 10.4321/S1139-76322015000100012]
- 22 **Patrizi A**, Costa AM, Fiorillo L, Neri I. Perianal streptococcal dermatitis associated with guttate psoriasis and/or balanoposthitis: a study of five cases. *Pediatr Dermatol* 1994; **11**: 168-171 [PMID: 8041660 DOI: 10.1111/j.1525-1470.1994.tb00574.x]
- 23 **Clegg HW**, Giftos PM, Anderson WE, Kaplan EL, Johnson DR. Clinical Perineal Streptococcal Infection in Children: Epidemiologic Features, Low Symptomatic Recurrence Rate after Treatment, and Risk Factors for Recurrence. *J Pediatr* 2015; **167**: 687-93.e1-2 [PMID: 26095284 DOI: 10.1016/j.jpeds.2015.05.034]
- 24 **Šterbenc A**, Seme K, Lah LL, Točkova O, Kamhi Trop T, Švent-Kučina N, Pirš M. Microbiological characteristics of perianal streptococcal dermatitis: a retrospective study of 105 patients in a 10-year period. *Acta Dermatovenereol Alp Pannonica Adriat* 2016; **25**: 73-76 [PMID: 28006879 DOI: 10.15570/actaapa.2016.21]
- 25 **Olson D**, Edmonson MB. Outcomes in children treated for perineal group A beta-hemolytic streptococcal dermatitis. *Pediatr Infect Dis J* 2011; **30**: 933-936 [PMID: 21747323 DOI: 10.1097/INF.0b013e318228492a]
- 26 **Heath C**, Desai N, Silverberg NB. Recent microbiological shifts in perianal bacterial dermatitis: Staphylococcus aureus predominance. *Pediatr Dermatol* 2009; **26**: 696-700 [PMID: 20199443 DOI: 10.1111/j.1525-1470.2009.01015.x]
- 27 **Petersen JP**, Kaltoft MS, Misfeldt JC, Schumacher H, Schønheyder HC. Community outbreak of perianal group A streptococcal infection in Denmark. *Pediatr Infect Dis J* 2003; **22**: 105-109 [PMID: 12586971 DOI: 10.1097/01.inf.0000048907.22286.b5]
- 28 **Spear RM**, Rothbaum RJ, Keating JP, Blaufuss MC, Rosenblum JL. Perianal streptococcal cellulitis. *J Pediatr* 1985; **107**: 557-559 [PMID: 4045605 DOI: 10.1016/S0022-3476(85)80019-6]
- 29 **Duhra P**, Ilchyshyn A. Perianal streptococcal cellulitis with penile involvement. *Br J Dermatol* 1990; **123**: 793-796 [PMID: 2265096 DOI: 10.1111/j.1365-2133.1990.tb04199.x]
- 30 **Goodyear HM**, Knowles L, Harper JJ. Faecal incontinence due to perianal cellulitis. *Acta Paediatr Scand* 1991; **80**: 1107-1108 [PMID: 1750350 DOI: 10.1111/j.1651-2227.1991.tb11794.x]
- 31 **Medina S**, Gómez MI, de Misa RF, Ledo A. Perianal streptococcal cellulitis: treatment with topical mupirocin. *Dermatology* 1992; **185**: 219 [PMID: 1446090 DOI: 10.1159/000247453]
- 32 **Montemarano AD**, James WD. Staphylococcus aureus as a cause of perianal dermatitis. *Pediatr Dermatol* 1993; **10**: 259-262 [PMID: 8415304 DOI: 10.1111/j.1525-1470.1993.tb00372.x]
- 33 **Guppy DH**. Perianal group A streptococcal infection. *J Paediatr Child Health* 1993; **29**: 144-145 [PMID: 8489795 DOI: 10.1111/j.1440-1754.1993.tb00468.x]
- 34 **Paradisi M**, Cianchini G, Angelo C, Conti G, Puddu P. Efficacy of topical erythromycin in treatment of perianal streptococcal dermatitis. *Pediatr Dermatol* 1993; **10**: 297-298 [PMID: 8415314 DOI: 10.1111/j.1525-1470.1993.tb00384.x]
- 35 **Paradisi M**, Cianchini G, Angelo C, Conti G, Puddu P. Perianal streptococcal dermatitis: two familial cases. *Cutis* 1994; **54**: 341-342 [PMID: 7835063]
- 36 **van Zeijl JH**, Korver CR. [Perianal streptococcal dermatitis in children]. *Ned Tijdschr Geneesk* 1996; **140**: 2191-2193 [PMID: 8984357]
- 37 **Saxén H**, Muotiala A, Rostila T, Vuopio-Varkila J. Outbreak of perianal Streptococcus pyogenes infection in a day-care center. *Pediatr Infect Dis J* 1997; **16**: 247-249 [PMID: 9041610 DOI: 10.1097/00006454-199702000-00016]
- 38 **Berlin SC**, Morrison SC, Myers MT, Sivitt CJ, Weinert DM. Pediatric case of the day. Streptococcal myositis and perianal cellulitis. *AJR Am J Roentgenol* 1997; **169**: 303, 306-307 [PMID: 9207558 DOI: 10.2214/ajr.169.1.9207558]
- 39 **Bugatti L**, Filosa G, Ciattaglia G. Perianal dermatitis in a child. Perianal streptococcal dermatitis (PSD). *Arch Dermatol* 1998; **134**: 1147, 1150 [PMID: 9762032 DOI: 10.1001/archderm.134.9.1145-c]
- 40 **Adams SP**. Dermacase. Perianal streptococcal dermatitis. *Can Fam Physician* 1999; **45**: 2059, 2066 [PMID: 10509216]
- 41 **Roos K**, Lind L, Holm SE, Grahn-Håkansson E. Perianal streptococcal dermatitis. The possible protective role of alpha-streptococci against spread and recurrence of group A streptococcal throat infection. *Scand J Prim Health Care* 1999; **17**: 46-48 [PMID: 10229993 DOI: 10.1080/028134399750002890]
- 42 **Vélez A**, Moreno JC. Febrile perianal streptococcal dermatitis. *Pediatr Dermatol* 1999; **16**: 23-24 [PMID: 10027994 DOI: 10.1046/j.1525-1470.1999.99006.x]
- 43 **Brilliant LC**. Perianal streptococcal dermatitis. *Am Fam Physician* 2000; **61**: 391-393, 397 [PMID: 10670505]
- 44 **Balasubramanian S**, Padmasani LN, Mouli NC. Perianal streptococcal dermatitis. *Indian Pediatr* 2000; **37**: 433-435 [PMID: 10781241]
- 45 **Heidelberger A**, Cremer H, Ring J, Abeck D. [Perianal streptococcal dermatitis]. *Hautarzt* 2000; **51**: 86-89 [PMID: 10743579 DOI: 10.1007/s001050050018]
- 46 **Nowicki MJ**, Bishop PR, Parker PH. Digital desquamation--a new finding in perianal streptococcal dermatitis. *Clin Pediatr (Phila)* 2000; **39**: 237-239 [PMID: 10791137 DOI: 10.1177/000992280003900408]
- 47 **Lunghi F**, Finzi M, Frati C. Two familial cases of perianal streptococcal dermatitis. *Cutis* 2001; **68**: 183-184 [PMID: 11579781]
- 48 **Romano I**, Venturi C, Bassissi P. Perianal streptococcal dermatitis and guttate psoriasis. Case report. *Eur J Pediatr Dermatol* [Internet] 2002; **2**: 93-96
- 49 **Huang TJ**, Liu TY, Chen FL. Perianal streptococcal dermatitis. *Dermatol Sin* [Internet] 2003; **21**: 142-145
- 50 **Reimer M**. Perianal/vulvovaginal/penile streptococcal infection. A childhood disease easily diagnosed with rapid testing. *Lakartidningen* 2004; **101**: 3327-3328 [PMID: 15543955]
- 51 **Takeshita T**, Gondo H, Tsuji G, Furue M. Three cases of perianal streptococcal dermatitis. *Nishi Nihon Hifuka* 2006; **68**: 644-647 [DOI: 10.2336/nishinihonhifu.68.644]
- 52 **Usuki K**. Perianal streptococcal dermatitis in father and daughter. *Nishi Nihon Hifuka* 2006; **68**: 512-514 [DOI: 10.2336/nishinihonhifu.68.512]
- 53 **Ulger Z**, Gelenava T, Kosay Y, Darcan S. Acute guttate psoriasis associated with streptococcal perianal dermatitis. *Clin Pediatr (Phila)* 2007; **46**: 70-72 [PMID: 17164513 DOI: 10.1177/1084713806297157]
- 54 **Greisser J**, Niederer-Loher A, Kernland Lang K. Perianal erythema in a child--group A streptococci?!. *Praxis (Bern 1994)* 2008; **97**: 143-145 [PMID: 18549015 DOI: 10.1024/1661-8157.97.3.143]
- 55 **Ledoux M**, Chazerain V, Saiag P, Mahé E. [Streptococcal perianal dermatitis and guttate psoriasis]. *Ann Dermatol Venerol* 2009; **136**: 37-41 [PMID: 19171228 DOI: 10.1016/j.annder.2008.06.013]
- 56 **Rasi A**, Pour-Heidari N. Association between plaque-type psoriasis and perianal streptococcal cellulitis and review of the literature. *Arch Iran Med* 2009; **12**: 591-594 [PMID: 19877754]
- 57 **Block SL**. Perianal dermatitis: much more than just a diaper rash. *Pediatr Ann* 2013; **42**: 12-14 [PMID: 23316826 DOI: 10.3928/00904481-20121221-05]
- 58 **Theotokatou S**, Saravakos P, Niopa M, Kallinikos A. Bacterial perianal dermatitis caused by Enterococcus faecalis with intrafamily spread: Report of a rare case. *J Pediatr Infect Dis* 2015; **9**: 043-046 [DOI: 10.3233/JPI-140407]
- 59 **Hirschfeld AJ**. Two family outbreaks of perianal cellulitis associated with group A beta-hemolytic streptococci. *Pediatrics* 1970; **46**: 799-802 [PMID: 4991446]
- 60 **Garritsen FM**, Kraag DE, de Graaf M. Guttate psoriasis triggered by perianal streptococcal infection. *Clin Exp Dermatol* 2017; **42**: 536-538 [PMID: 28543851 DOI: 10.1111/ced.13129]
- 61 **Rehder PA**, Eliezer ET, Lane AT. Perianal cellulitis. Cutaneous group A streptococcal disease. *Arch Dermatol* 1988; **124**: 702-704 [PMID: 3129994 DOI: 10.1001/archderm.124.5.702]
- 62 **Honig PJ**. Guttate psoriasis associated with perianal streptococcal disease. *J Pediatr* 1988; **113**: 1037-1039 [PMID: 3057157 DOI: 10.1016/S0022-3476(88)80577-8]
- 63 **Marks VJ**, Maksimik M. Perianal streptococcal cellulitis. *J Am Acad Dermatol* 1988; **18**: 587-588 [PMID: 3280624 DOI: 10.1016/



- S0190-9622(88)80298-6]
- 64 **Guerrero Vázquez J**, Sebastián Planes M, de Paz Aparicio P, Garcés Ramos A, Luengo Casasola JL, Valera Pascual MT, Peñalba Moreno G, Olmedo Sanlaureano S. Streptococcal perianal disease and balanoposthitis. *An Esp Pediatr* 1989; **30**: 198-200 [PMID: 2729790]
  - 65 **Farmer G**. Perianal infection with group A streptococcus. *Arch Dis Child* 1987; **62**: 1169-1170 [PMID: 3318714 DOI: 10.1136/adc.62.11.1169]
  - 66 **Castro R**, Rivera J. Recurrent perianal streptococcal cellulitis. *Del Med J* 1988; **60**: 421-422 [PMID: 3044853]
  - 67 **Ellett ML**. Anusitis associated with group A beta-hemolytic streptococci. *Gastroenterol Nurs* 1989; **12**: 53-54 [PMID: 2487812 DOI: 10.1097/00001610-198907000-00014]
  - 68 **Putto-Laurila A**, Ruuskanen O, Mertsola J. Perianal infection caused by group A beta-hemolytic Streptococcus on children. *Duodecim* 1995; **111**: 361-364 [PMID: 8654306]
  - 69 **Broberg A**, Mobacken H. Perianal streptococcal dermatitis is a possibility in therapy-resistant anal redness. *Lakartidningen* 1992; **89**: 3955-3956 [PMID: 1461011]
  - 70 **Teillac-Hamel D**, de Prost Y. Perianal streptococcal dermatitis in children. *Eur J Dermatol* 1992; **2**: 71-74
  - 71 **Neri I**, Bardazzi F, Marzaduri S, Patrizi A. Perianal streptococcal dermatitis in adults. *Br J Dermatol* 1996; **135**: 796-798 [PMID: 8977685 DOI: 10.1046/j.1365-2133.1996.d01-1082.x]
  - 72 **Scheiba N**, Hartschuh W. Perianal streptococcal dermatitis caused by beta-hemolytic group G streptococci in two adults. *Hautarzt* 2011; **62**: 131-133 [PMID: 20835811 DOI: 10.1007/s00105-010-1977-9]
  - 73 **Abdolrasouli A**, Hemmati Y, Amin A, Roushan A, Butler I. Lancefield group G Streptococcus dysgalactiae subsp. equisimilis: an unusual aetiology of perianal streptococcal dermatitis acquired from heterosexual oral-anal intercourse. *Int J STD AIDS* 2012; **23**: 911-912 [PMID: 23258838 DOI: 10.1258/ijsa.2012.012112]
  - 74 **Kahlke V**, Jongen J, Peleikis HG, Herbst RA. Perianal streptococcal dermatitis in adults: its association with pruritic anorectal diseases is mainly caused by group B Streptococci. *Colorectal Dis* 2013; **15**: 602-607 [PMID: 23216793 DOI: 10.1111/codi.12089]
  - 75 **Maatouk I**, Moutran R. Perianal streptococcal dermatitis due to Streptococcus dysgalactiae ssp. Equisimilis in a man who has sex with men. *J Sex Med* 2013; **10**: 2351-2352 [PMID: 23845120 DOI: 10.1111/jsm.12243]
  - 76 **Mahendran R**, Highet AS. Acute perianal streptococcal infection in an adult. *Clin Exp Dermatol* 2002; **27**: 69 [PMID: 11952678 DOI: 10.1046/j.0307-6938.2001.00936.x]
  - 77 **Maiolo C**, Kwok SM, Ross C, Ibbetson J. Perianal streptococcal infection precipitating pustular psoriasis in an adult. *JAAD Case Rep* 2016; **2**: 281-283 [PMID: 27504479 DOI: 10.1016/j.jidcr.2016.05.010]
  - 78 **Orden B**, Manjavacas CG, Mombiola T, Martinez R, Franco A. Streptococcal perianal disease in two healthy adult women. *Clin Microbiol Infect* 1996; **2**: 142 [PMID: 11866832 DOI: 10.1111/j.1469-0691.1996.tb00220.x]
  - 79 **Herbst R**. Perineal streptococcal dermatitis/disease: recognition and management. *Am J Clin Dermatol* 2003; **4**: 555-560 [PMID: 12862498 DOI: 10.2165/00128071-200304080-00005]
  - 80 **Combs JT**. Perianal streptococcal disease. *Clin Pediatr (Phila)* 2000; **39**: 500 [PMID: 10961825 DOI: 10.1177/000992280003900814]
  - 81 **Bafounta ML**, Bloch P, Kernbaum S, Saia P. Group A beta-hemolytic Streptococcus: an unusual etiology of perianal dermatitis in an adult?. *Ann Dermatol Venereol* 1998; **125**: 902-904 [PMID: 9922865]
  - 82 **Tonkovic-Capin V**, Fleming MG, Kleven-Kranz K, Lund MR. Vulvovaginitis and perineal cellulitis due to group A streptococcus in an adult woman. *Arch Dermatol* 2005; **141**: 790-792 [PMID: 15967936 DOI: 10.1001/archderm.141.6.790]
  - 83 **Ergin S**, Elçin G, Sahin S. Guttate psoriasis triggered by perianal cellulitis due to group B streptococci [Turkish]. *Turkish J Dermatology [Internet]* 2009; **3**: 70-72
  - 84 **Kallini JR**, Cohen PR. Perianal and periumbilical dermatitis: Report of a woman with group G streptococcal infection and review of perianal and periumbilical dermatoses. *Dermatol Online J* 2013; **19**: 3 [PMID: 24021363]
  - 85 **McIntyre DM**. An epidemic of Streptococcus pyogenes puerperal and postoperative sepsis with an unusual carrier site—the anus. *Am J Obstet Gynecol* 1968; **101**: 308-314 [PMID: 4967751 DOI: 10.1016/0002-9378(68)90056-2]
  - 86 **Schaffner W**, Lefkowitz LB Jr, Goodman JS, Koenig MG. Hospital outbreak of infections with group A streptococci traced to an asymptomatic anal carrier. *N Engl J Med* 1969; **280**: 1224-1225 [PMID: 4889553 DOI: 10.1056/NEJM196905292802209]
  - 87 **Asnes RS**, Vail D, Grebin B, Sprunt K. Anal carrier rate of group A beta-hemolytic streptococci in children with streptococcal pharyngitis. *Pediatrics* 1973; **52**: 439-441 [PMID: 4581122]
  - 88 **Clegg HW**, Dallas SD, Roddey OF, Martin ES, Swetenburg RL, Koonce EW, Felkner MB, Ryan AG, Presbyterian Pediatric Research Group. Extrapharyngeal group A Streptococcus infection: diagnostic accuracy and utility of rapid antigen testing. *Pediatr Infect Dis J* 2003; **22**: 726-731 [PMID: 12913775 DOI: 10.1097/01.inf.0000078835.72497.ab]

P- Reviewer: Agrawal A, Nkachukwu SN S- Editor: Ji FF  
L- Editor: A E- Editor: Yin SY





Published by **Baishideng Publishing Group Inc**  
7901 Stoneridge Drive, Suite 501, Pleasanton, CA 94588, USA  
Telephone: +1-925-223-8242  
Fax: +1-925-223-8243  
E-mail: [bpgoffice@wjgnet.com](mailto:bpgoffice@wjgnet.com)  
Help Desk: <http://www.f6publishing.com/helpdesk>  
<http://www.wjgnet.com>

