

Pacemaker implantation in a patient with brugada and sick sinus syndrome

Bjarke Risgaard, Henning Bundgaard, Reza Jabbari, Stig Haunsø, Bo Gregers Winkel, Jacob Tfelt-Hansen

Bjarke Risgaard, Reza Jabbari, Stig Haunsø, Bo Gregers Winkel, Jacob Tfelt-Hansen, The Danish National Research Foundation Centre for Cardiac Arrhythmia, University of Copenhagen, 2100 Copenhagen, Denmark

Bjarke Risgaard, Henning Bundgaard, Reza Jabbari, Stig Haunsø, Bo Gregers Winkel, Jacob Tfelt-Hansen, Laboratory of Molecular Cardiology, Department of Cardiology, The Heart Centre, Copenhagen University Hospital Rigshospitalet, 2100 Copenhagen, Denmark

Author contributions: Risgaard B and Jabbari R wrote the paper; Bundgaard H delivered information on and did critical revision; Haunsø S gave funding and did critical revision; Tfelt-Hansen J got the idea and together with Winkel BG delivered information on the patients and did critical revision of the manuscript.

Supported by The Danish Heart Foundation (A3790); the Danish National Research Foundation Centre for Cardiac Arrhythmia; the John and Birthe Meyer Foundation; the Research Foundation at the Heart Centre, Rigshospitalet and the Foundation of Edith and Henrik Henriksens mindelegat (50892)

Correspondence to: Bjarke Risgaard, MD, Department of Cardiology, Section 2142, Copenhagen University Hospital, Rigshospitalet, Blegdamsvej 9, DK-2100 Copenhagen, Denmark. bjarkerisgaard@gmail.com

Telephone: +45-35-456501 Fax: +45-35-456500

Received: September 12, 2012 Revised: December 13, 2012

Accepted: January 23, 2013

Published online: March 26, 2013

treated with implantation of a pacemaker (PM) at another institution. An inherited cardiac disease was one day suddenly suspected, as the patient had a 61-year old brother who was diagnosed with symptomatic BrS, and treated with an implantable cardioverter defibrillator (ICD) after aborted SCD. A mutation screening revealed a *SCN5A* [*S231CfsX251 (c.692-693delCA)*] loss-of-function mutation not previously reported, and as a part of the cascade screening in relatives she was therefore referred to our clinic. In the 7 year period after PM implantation she had experienced no cardiac symptoms, although her electrocardiogram changes now were consistent with a BrS type 1 pattern. A genetic test confirmed that she had the same mutation in *SCN5A* as her brother. In this case-report we present a loss-of function mutation in *SCN5A* not previously associated with BrS nor presented in healthy controls. Sinus node dysfunction has previously been documented in patients with symptomatic BrS, which suggests it is not a rare concomitant. The only accepted treatment of BrS is today implantation of an ICD. In the future studies should evaluate if PM in some cases of symptomatic BrS can be used instead of ICDs in patients with a loss-of-function *SCN5A* mutations

© 2013 Baishideng. All rights reserved.

Abstract

Brugada syndrome (BrS) is a rare and inherited primary arrhythmic syndrome characterized by ST-segment elevations in the right precordial leads (V₁-V₃) with an increased risk of sudden cardiac death (SCD). Arrhythmias in BrS are often nocturnal, and bradyarrhythmias are often seen in patients with loss-of-function mutations in *SCN5A*. In this case-report we present a 75-year old woman referred to our outpatient clinic for inherited cardiac diseases for a familial clinical work-up. Since childhood she had suffered from dizziness, absence seizures, and countless Syncope's. In 2004 sick sinus syndrome was suspected and she was

Key words: Brugada syndrome; Pacemaker; Arrhythmias; Sudden cardiac death

Risgaard B, Bundgaard H, Jabbari R, Haunsø S, Winkel BG, Tfelt-Hansen J. Pacemaker implantation in a patient with brugada and sick sinus syndrome. *World J Cardiol* 2013; 5(3): 65-67 Available from: URL: <http://www.wjgnet.com/1949-8462/full/v5/i3/65.htm> DOI: <http://dx.doi.org/10.4330/wjc.v5.i3.65>

INTRODUCTION

Brugada syndrome (BrS) is a rare and inherited primary

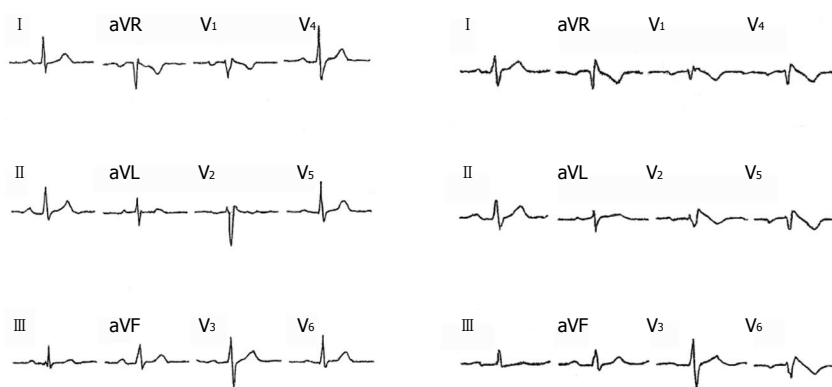


Figure 1 Baseline and Brugada type 1 electrocardiogram. A: Baseline electrocardiogram (ECG) recording; B: Brugada type 1 ECG under 150 mg Flecanide over 10 min intravenously. In V_{4-6} in the recording were placed as elevated electrode position in IC2 at V_1 at sternum and V_2 , respectively.

arrhythmic syndrome characterized by ST-segment elevations in the right precordial leads (V_1 - V_3) with an increased risk of sudden cardiac death (SCD) due to malignant ventricular arrhythmias in the absence of a structural heart disease^[1]. Arrhythmias in BrS are often nocturnal, and brady-arrhythmias are often seen in patients with loss-of-function mutations in the *Sodium channel gene* (*SCN5A*)^[2]. *SCN5A* encodes the alpha subunit ($Na_v1.5$) of the cardiac sodium channel complex and it is the only recommended gene for targeted screening in BrS^[3]. Mutations in *SCN5A* have been reported to be associated with several other types of disease entities such as lone atrial fibrillation and the Long QT Syndrome^[4]. It is suggested that the loss-of-function mutations in *SCN5A* create the substrate for a re-entry circuit in the ventricular myocardium, but may also increase vagal activity, thus facilitating development of arrhythmias^[1].

CASE REPORT

A 75-year old woman was in 2011 referred to our outpatient clinic for inherited cardiac diseases for a familial clinical work-up. Since childhood she had suffered from dizziness, absence seizures, and countless syncope's. In 2004 sick sinus syndrome was suspected as a 24 h Holter monitoring revealed 67 sinus arrests [electrocardiogram (ECG) not available] of more than 2.5 s with the longest being 6.85 s. The asystole were followed by dizziness but no syncope's appeared under surveillance. The SSS diagnosis seemed obvious, and she was treated with implantation of a pacemaker (PM) at another institution.

An inherited cardiac disease was one day suddenly suspected, as the patient had a 61-year old brother who was diagnosed with symptomatic BrS, and treated with an implantable cardioverter defibrillator (ICD) after aborted SCD. A mutation screening revealed a *SCN5A* [*S231CfsX251* (*c.692-693delCA*)] loss-of-function mutation not previously reported, and as a part of the cascade screening in relatives she was therefore referred to our clinic.

In the 7 year period after PM implantation she had experienced no cardiac symptoms. An ECG and elevated electrode placement ECG (EEP-ECG) showed no BrS

pattern. However, BrS was suspected due to the family history and a Flecanide test (150 mg intravenously) was performed. After infusion, 1 and 2 mm ST elevations appeared in V_1 and V_2 , respectively (Figure 1). Changes were consistent with a BrS type 1 ECG pattern and a genetic test confirmed that she had the same mutation in *SCN5A* as her brother. As the patient had been free of symptoms after PM implantation, it was decided not to upgrade to an ICD unless syncope would re-appear.

DISCUSSION

In this case-report we present a loss-of function mutation in *SCN5A* not previously associated with BrS nor presented in healthy controls^[5]. It has been suggested that the loss-of-function mutations in *SCN5A* create the substrate for a re-entry circuit in the ventricular myocardium, but may also increase vagal activity, thus facilitating development of arrhythmias in BrS^[1]. The mutation, that we report, was initially found in a brother diagnosed with BrS after aborted SCD and hereafter in our patient, initially diagnosed with SSS. Sinus node dysfunction has previously been documented in patients with symptomatic BrS, which suggests it is not a rare concomitant^[6,7]. However, PM implant in this case kept the patient free of symptoms for several years, and this support the theory that increased vagal tone may cause bradycardia-related arrhythmias which in other isolated cases have been treated successfully with rapid pacing as well^[1]. The only accepted treatment of BrS is today implantation of an ICD. In the future studies should evaluate if PM in some cases of symptomatic BrS can be used instead of ICDs in patients with ICDs in patients with *SCN5A* loss-of-function mutations.

REFERENCES

- 1 Antzelevitch C. Brugada syndrome. *Pacing Clin Electrophysiol* 2006; **29**: 1130-1159 [PMID: 17038146 DOI: 10.1111/j.1540-8159.2006.00507.x]
- 2 Kananuki H, Ohnishi S, Ohtuka M, Matsuda N, Nirei T, Isogai R, Shoda M, Toyoshima Y, Hosoda S. Idiopathic ventricular fibrillation induced with vagal activity in patients without obvious heart disease. *Circulation* 1997; **95**: 2277-2285

- 3 [PMID: 9142005 DOI: 10.1161/01.CIR.95.9.2277]
Ackerman MJ, Priori SG, Willems S, Berul C, Brugada R, Calkins H, Camm AJ, Ellinor PT, Gollob M, Hamilton R, Hersberger RE, Judge DP, Le Marec H, McKenna WJ, Schulze-Bahr E, Semsarian C, Towbin JA, Watkins H, Wilde A, Wolpert C, Zipes DP. HRS/EHRA expert consensus statement on the state of genetic testing for the channelopathies and cardiomyopathies this document was developed as a partnership between the Heart Rhythm Society (HRS) and the European Heart Rhythm Association (EHRA). *Heart Rhythm* 2011; **8**: 1308-1339 [PMID: 21787999 DOI: 10.1016/j.hrthm.2011.05.020]
- 4 **Tfelt-Hansen J**, Winkel BG, Grunnet M, Jespersen T. Inherited cardiac diseases caused by mutations in the Nav1.5 sodium channel. *J Cardiovasc Electrophysiol* 2010; **21**: 107-115 [PMID: 19845816 DOI: 10.1111/j.1540-8167.2009.01633.x]
- 5 **Exome Variant Server**. 2012. Available from: <http://evs.gs.washington.edu/EVS/> (Accessed 2012 July 1)
- 6 **Sumiyoshi M**, Nakazato Y, Tokano T, Yasuda M, Minoda Y, Nakata Y, Daida H. Sinus node dysfunction concomitant with Brugada syndrome. *Circ J* 2005; **69**: 946-950 [PMID: 16041164 DOI: 10.1253/circj.69.946]
- 7 **Shimizu N**, Iwamoto M, Nakano Y, Sumita S, Ishikawa T, Hokosaki T, Akaike T, Nishizawa T, Takigiku K, Shibata T, Niimura I. Long-term electrocardiographic follow-up from childhood of an adult patient with Brugada syndrome associated with sick sinus syndrome. *Circ J* 2009; **73**: 575-579 [PMID: 19075525 DOI: 10.1253/circj.CJ-07-0659]

P-Reviewer Chahine M **S-Editor** Zhai HH **L-Editor** A
E-Editor Zhang DN

