

# World Journal of *Clinical Cases*

*World J Clin Cases* 2018 November 26; 6(14): 716-868





**REVIEW**

- 716 Current status of surgical treatment of colorectal liver metastases  
*Xu F, Tang B, Jin TQ, Dai CL*

**MINIREVIEWS**

- 735 The assessment of endosonographers in training  
*Hedenström P, Sadik R*
- 745 Necroptosis in inflammatory bowel disease and other intestinal diseases  
*Li S, Ning LG, Lou XH, Xu GQ*

**ORIGINAL ARTICLE**

**Case Control Study**

- 753 Benefits of the Seattle biopsy protocol in the diagnosis of Barrett's esophagus in a Chinese population  
*Lee SW, Lien HC, Chang CS, Lin MX, Chang CH, Ko CW*

**Retrospective Study**

- 759 Modified laparoscopic Sugarbaker repair of parastomal hernia with a three-point anchoring technique  
*Huang DY, Pan L, Chen QL, Cai XY, Fang J*

**SYSTEMATIC REVIEWS**

- 767 Safety of laparoscopic surgery in digestive diseases with special reference to antithrombotic therapy: A systematic review of the literature  
*Fujikawa T, Ando K*

**CASE REPORT**

- 776 Epstein-Barr virus-associated hemophagocytic syndrome in a patient with ulcerative colitis during treatment with azathioprine: A case report and review of literature  
*Miyaguchi K, Yamaoka M, Tsuzuki Y, Ashitani K, Ohgo H, Miyagawa Y, Ishizawa K, Kayano H, Nakamoto H, Imaeda H*
- 781 Acquired hemophilia A in solid cancer: Two case reports and review of the literature  
*Saito M, Ogasawara R, Izumiyama K, Mori A, Kondo T, Tanaka M, Morioka M, Ieko M*
- 786 Glutaric acidemia type II patient with thalassemia minor and novel electron transfer flavoprotein-A gene mutations: A case report and review of literature  
*Saral NY, Aksungar FB, Aktuglu-Zeybek C, Coskun J, Demirelce O, Serteser M*

- 791** Meckel's diverticulum diagnosis by video capsule endoscopy: A case report and review of literature  
*García-Compeán D, Jiménez-Rodríguez AR, Del Cueto-Aguilera ÁN, Herrera-Quñones G, González-González JA, Maldonado-Garza HJ*
- 800** Carney complex: Two case reports and review of literature  
*Li S, Duan L, Wang FD, Lu L, Jin ZY*
- 807** Ileal bronchogenic cyst: A case report and review of literature  
*Chen HY, Fu LY, Wang ZJ*
- 811** Application of ultrasound in aggressive angiomyxoma: Eight case reports and review of literature  
*Zhao CY, Su N, Jiang YX, Yang M*
- 820** Solitary rectal ulcer syndrome complicating sessile serrated adenoma/polyps: A case report and review of literature  
*Sun H, Sheng WQ, Huang D*
- 825** Subdural empyema complicated with intracranial hemorrhage in a postradiotherapy nasopharyngeal carcinoma patient: A case report and review of literature  
*Chen JC, Tan DH, Xue ZB, Yang SY, Li Y, Lai RL*
- 830** Giant monostotic osteofibrous dysplasia of the ilium: A case report and review of literature  
*Liu YB, Zou TM*
- 836** Postoperative redislocation of the hip in a patient with congenital insensitivity to pain with anhidrosis: A case report and review of literature  
*Wang R, Liu Y, Zhou YY, Wang JY, Xu ZJ, Chen SY, Wang QQ, Yuan P*
- 842** Open surgical treatment of choledochocoele: A case report and review of literature  
*Yang J, Xiao GF, Li YX*
- 847** Mesenteric heterotopic pancreas in a pediatric patient: A case report and review of literature  
*Tang XB, Liao MY, Wang WL, Bai YZ*
- 854** Intralesional and topical glucocorticoids for pretibial myxedema: A case report and review of literature  
*Zhang F, Lin XY, Chen J, Peng SQ, Shan ZY, Teng WP, Yu XH*



- 862**    Octreotide reverses shock due to vasoactive intestinal peptide-secreting adrenal pheochromocytoma: A case report and review of literature

*Hu X, Cao W, Zhao M*

## ABOUT COVER

Editorial Board Member of *World Journal of Clinical Cases*, Manabu Watanabe, MD, PhD, Full Professor, Division of Gastroenterology and Hepatology, Department of Internal medicine, Toho University Medical Center, Ohashi Hospital, Tokyo 153-8515, Japan

## AIM AND SCOPE

*World Journal of Clinical Cases* (*World J Clin Cases*, *WJCC*, online ISSN 2307-8960, DOI: 10.12998) is a peer-reviewed open access academic journal that aims to guide clinical practice and improve diagnostic and therapeutic skills of clinicians.

The primary task of *WJCC* is to rapidly publish high-quality Autobiography, Case Report, Clinical Case Conference (Clinicopathological Conference), Clinical Management, Diagnostic Advances, Editorial, Field of Vision, Frontier, Medical Ethics, Original Articles, Clinical Practice, Meta-Analysis, Minireviews, Review, Therapeutics Advances, and Topic Highlight, in the fields of allergy, anesthesiology, cardiac medicine, clinical genetics, clinical neurology, critical care, dentistry, dermatology, emergency medicine, endocrinology, family medicine, gastroenterology and hepatology, geriatrics and gerontology, hematology, immunology, infectious diseases, internal medicine, obstetrics and gynecology, oncology, ophthalmology, orthopedics, otolaryngology, pathology, pediatrics, peripheral vascular disease, psychiatry, radiology, rehabilitation, respiratory medicine, rheumatology, surgery, toxicology, transplantation, and urology and nephrology.

## INDEXING/ABSTRACTING

*World Journal of Clinical Cases* (*WJCC*) is now indexed in PubMed, PubMed Central, Science Citation Index Expanded (also known as SciSearch®), and Journal Citation Reports/Science Edition. The 2018 Edition of Journal Citation Reports cites the 2017 impact factor for *WJCC* as 1.931 (5-year impact factor: N/A), ranking *WJCC* as 60 among 154 journals in Medicine, General and Internal (quartile in category Q2).

## EDITORS FOR THIS ISSUE

Responsible Assistant Editor: *Xiang Li*  
Responsible Electronic Editor: *Han Song*  
Proofing Editor-in-Chief: *Lian-Sheng Ma*

Responsible Science Editor: *Fang-Fang Ji*  
Proofing Editorial Office Director: *Jin-Lei Wang*

NAME OF JOURNAL  
*World Journal of Clinical Cases*

ISSN  
ISSN 2307-8960 (online)

LAUNCH DATE  
April 16, 2013

FREQUENCY  
Semimonthly

EDITORS-IN-CHIEF  
**Sandro Vento, MD**, Department of Internal Medicine, University of Botswana, Private Bag 00713, Gaborone, Botswana

EDITORIAL BOARD MEMBERS  
All editorial board members resources online at <http://www.wjgnet.com/2307-8960/editorialboard.htm>

EDITORIAL OFFICE  
Jin-Lei Wang, Director

*World Journal of Clinical Cases*  
Baishideng Publishing Group Inc  
7901 Stoneridge Drive, Suite 501, Pleasanton, CA 94588, USA  
Telephone: +1-925-2238242  
Fax: +1-925-2238243  
E-mail: [editorialoffice@wjgnet.com](mailto:editorialoffice@wjgnet.com)  
Help Desk: <http://www.f6publishing.com/helpdesk>  
<http://www.wjgnet.com>

PUBLISHER  
Baishideng Publishing Group Inc  
7901 Stoneridge Drive, Suite 501, Pleasanton, CA 94588, USA  
Telephone: +1-925-2238242  
Fax: +1-925-2238243  
E-mail: [bpgoffice@wjgnet.com](mailto:bpgoffice@wjgnet.com)  
Help Desk: <http://www.f6publishing.com/helpdesk>  
<http://www.wjgnet.com>

PUBLICATION DATE  
November 26, 2018

### COPYRIGHT

© 2018 Baishideng Publishing Group Inc. Articles published by this Open Access journal are distributed under the terms of the Creative Commons Attribution Non-commercial License, which permits use, distribution, and reproduction in any medium, provided the original work is properly cited, the use is non commercial and is otherwise in compliance with the license.

### SPECIAL STATEMENT

All articles published in journals owned by the Baishideng Publishing Group (BPG) represent the views and opinions of their authors, and not the views, opinions or policies of the BPG, except where otherwise explicitly indicated.

### INSTRUCTIONS TO AUTHORS

<http://www.wjgnet.com/bpg/gerinfo/204>

### ONLINE SUBMISSION

<http://www.f6publishing.com>

## Acquired hemophilia A in solid cancer: Two case reports and review of the literature

Makoto Saito, Reiki Ogasawara, Koh Izumiyama, Akio Mori, Takeshi Kondo, Masanori Tanaka, Masanobu Morioka, Masahiro Ieko

Makoto Saito, Reiki Ogasawara, Koh Izumiyama, Akio Mori, Takeshi Kondo, Masanori Tanaka, Masanobu Morioka, Department of Internal Medicine and Hematology, Aiiiku Hospital, Sapporo 0640804, Japan

Masahiro Ieko, Department of Internal Medicine, Health Sciences University of Hokkaido, Toubetsu 0610293, Japan

ORCID number: Makoto Saito (0000-0002-2683-9475); Reiki Ogasawara (0000-0002-1136-5035); Koh Izumiyama (0000-0002-0762-6255); Akio Mori (0000-0002-2064-2145); Takeshi Kondo (0000-0001-7455-5824); Masanori Tanaka (0000-0002-8173-6620); Masanobu Morioka (0000-0002-0784-8114); Masahiro Ieko (0000-0003-1854-4543).

Author contributions: Saito M, Ogasawara R, Izumiyama K, Mori A, Kondo T, Tanaka M, Morioka M and Ieko M collected the patient's clinical data; Saito M designed and wrote the report.

Informed consent statement: Consent was obtained from each patient or family (wife) for publication of this report and any accompanying images.

Conflict-of-interest statement: The authors declare that they have no conflicts of interest in this work.

CARE Checklist (2016) statement: I have prepared this report according to the guidelines of the CARE Checklist (2016).

Open-Access: This article is an open-access article which was selected by an in-house editor and fully peer-reviewed by external reviewers. It is distributed in accordance with the Creative Commons Attribution Non Commercial (CC BY-NC 4.0) license, which permits others to distribute, remix, adapt, build upon this work non-commercially, and license their derivative works on different terms, provided the original work is properly cited and the use is non-commercial. See: <http://creativecommons.org/licenses/by-nc/4.0/>

Manuscript source: Unsolicited manuscript

Corresponding author to: Makoto Saito, MD, PhD, Department of Internal Medicine and Hematology, Aiiiku Hospital, Minami 4 Nishi 25 Chuo-ku, Sapporo 0640804, Hokkaido,

Japan. [ikyoku@aiku-hp.or.jp](mailto:ikyoku@aiku-hp.or.jp)  
Telephone: +81-11-5632211

Received: August 20, 2018

Peer-review started: August 21, 2018

First decision: October 11, 2018

Revised: October 21, 2018

Accepted: October 22, 2018

Article in press: October 22, 2018

Published online: November 26, 2018

### Abstract

Acquired hemophilia A (AHA) is a rare, hemorrhagic autoimmune disease, whose pathogenesis involves reduced coagulation factor VIII (FVIII) activity related to the appearance of inhibitors against FVIII. Common etiological factors include autoimmune diseases, malignancy, and pregnancy. We report two cases of AHA in solid cancer. The first case is a 63-year-old man who developed peritoneal and intestinal bleeding after gastrectomy for gastric cancer. He was diagnosed with AHA, and was treated with prednisone, followed by cyclophosphamide. In the second case, a 68-year-old man developed a subcutaneous hemorrhage. He was diagnosed with AHA in hepatocellular carcinoma on CT imaging, and treated with rituximab alone. Hemostasis was achieved for both patients without bypassing agents as the amount of inhibitors was reduced and eradicated. However, both patients died within 1 year due to cancer progression. Successful treatment for AHA in solid cancer can be difficult because treatment of the underlying malignancy is also required.

**Key words:** Acquired hemophilia A; Coagulation factor VIII; Solid cancer; Gastric cancer; Hepatocellular carcinoma; Case report

© The Author(s) 2018. Published by Baishideng Publishing



Group Inc. All rights reserved.

**Core tip:** Acquired hemophilia A (AHA) is a rare hemorrhagic disease usually affecting the elderly, involving reduced coagulation factor VIII activity. Malignancies are reported to occur in association with 10%-15% of patients with AHA. We report two cases of AHA in solid cancer, namely, gastric cancer and hepatocellular carcinoma. Hemostasis was fully achieved owing to eradication of inhibitor against factor VIII, however, both patients died within 1 year due to cancer progression. Successful treatment for AHA in solid cancer can be difficult because not only active hemorrhage management and inhibitor eradication but also treatment of the underlying malignancy is required.

Saito M, Ogasawara R, Izumiyama K, Mori A, Kondo T, Tanaka M, Morioka M, Ieko M. Acquired hemophilia A in solid cancer: Two case reports and review of the literature. *World J Clin Cases* 2018; 6(14): 781-785 Available from: URL: <http://www.wjgnet.com/2307-8960/full/v6/i14/781.htm> DOI: <http://dx.doi.org/10.12998/wjcc.v6.i14.781>

## INTRODUCTION

Acquired hemophilia A (AHA) is a hemorrhagic disease with a decrease in coagulation factor VIII (FVIII) activity due to the appearance of autoantibodies (inhibitors) against FVIII<sup>[1,2]</sup>. The breakdown of the immune control mechanism is speculated to cause this disease<sup>[1]</sup>. AHA is very rare, and the annual incidence is about 1.48/million/year<sup>[2]</sup>. Elderly patients (age  $\geq$  60 years) account for over 80%<sup>[2]</sup>. In the majority of patients with AHA, hemorrhage is sudden and spontaneous, although it occurs in approximately 25% of patients after trauma or invasive procedures<sup>[3]</sup>.

Approximately 50% of patients have no underlying AHA-associated condition. Common etiological factors include autoimmune diseases (14.1%), malignancy (11.5%), and pregnancy (8.9%)<sup>[4]</sup>. The most common cause of solid cancers in AHA is prostate cancer, followed by lung cancer<sup>[5,6]</sup>. A recent study demonstrated that malignancy at baseline was associated with reduced overall survival for patients with AHA<sup>[7]</sup>. In addition, a systematic review described a large number of AHA patients with cancer<sup>[8]</sup>. However, evidence to confirm AHA in association with solid cancers needs to be obtained in more patients. In this study, we performed a retrospective analysis of the clinical characteristics of two AHA patients with solid cancers, namely, gastric cancer and hepatocellular carcinoma (HCC) at our institution.

## CASE REPORT

### Case 1 (Clinical course in Figure 1)

A 63-year-old man had been diagnosed with gastric

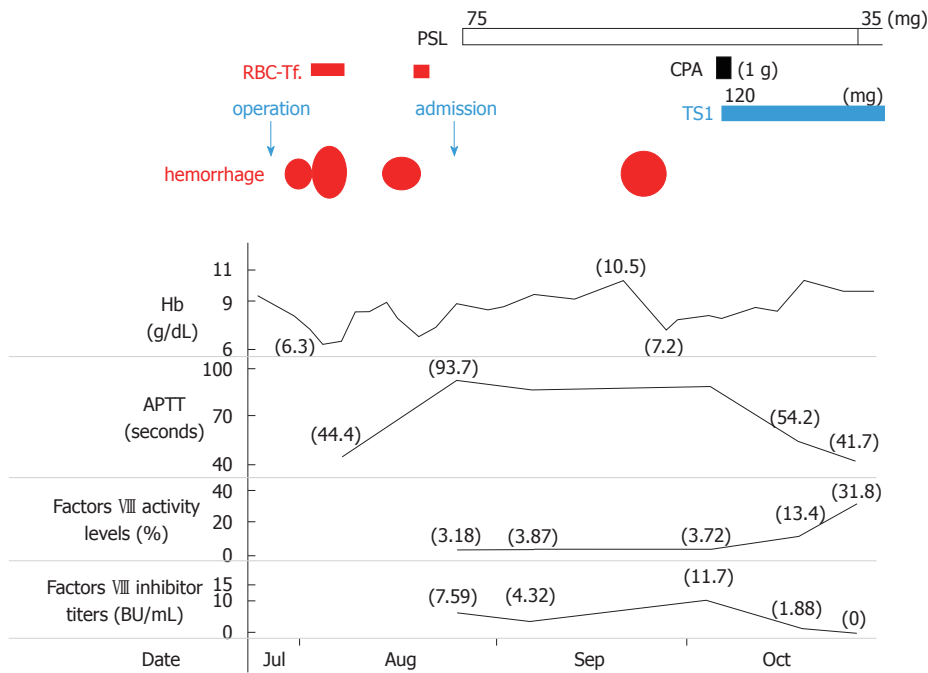
cancer and had undergone a gastrectomy at his nearby hospital. Bleeding within the intraperitoneal drainage tube was observed 5 d after surgery. Intraperitoneal cytology identified gastric cancer cells and a diagnosis of stage IV gastric cancer was confirmed. He developed hematemesis and melena 2 d following the removal of the drainage tube. His anemia worsened and his hemoglobin (Hb) level reached 6.3 g/dL, requiring red blood cell (RBC) transfusions for 5 d consecutively. Endoscopic examination revealed intestinal bleeding from the site of the anastomosis (Figure 2), and endoscopic hemostasis was performed. Subcutaneous hemorrhage became apparent in both lower extremities over several days. Transfusion with a total of 7 units of packed RBC was performed. The activated partial thromboplastin time (APTT) was prolonged to 74.2 s compared to 23.1 s measured preoperatively, and the patient was transferred to our hospital.

On admission, the patient presented with anemia, an Hb level of 9.0 g/dL and a prolonged APTT of 93.7 s. FVIII activity was reduced to 3.18%, the inhibitor titer was 7.59 BU/mL, and he was diagnosed with AHA. Prednisone (PSL 1 mg/kg per day) and tranexamic acid were administered. Although the patient had developed an intramuscular hematoma in the right iliacus muscle approximately 1 mo after treatment, bypassing agents had not been administered because the hemorrhage was not persistent. As the inhibitor titer had increased to 11.7 BU/mL, 1 g of cyclophosphamide (CPA) was additionally administered and chemotherapy for gastric cancer with TS1 (tegafur/gimeracil/oteracil) was initiated. The inhibitors were eradicated, and the patient was discharged 9 wk after treatment for AHA. Because the patient remained in remission for AHA, the PSL dose was reduced and stopped. Treatment for gastric cancer was administered repeatedly; however, the patient died 9 mo after gastrectomy due to carcinomatous peritonitis.

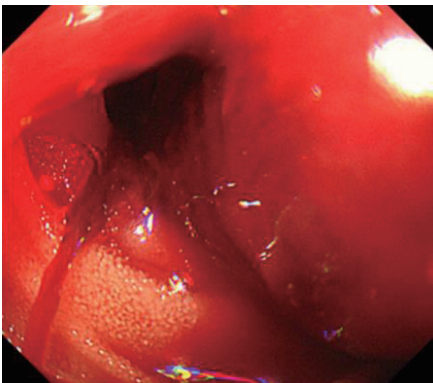
### Case 2

The second patient was a 68-year-old man with a history of cerebral infarction who had developed dementia (ECOG performance status, 3-4), in addition to arteriosclerosis obliterans, diabetes mellitus (DM), and hypertension. He had been taking a small amount (5 mg) of PSL for nephrotic syndrome. He was admitted to the local hospital having developed a non-traumatic subcutaneous hemorrhage in his right forearm. An abdominal computed tomography scan revealed hepatocellular carcinoma (file size 5.5 cm in diameter) (Figure 3). The anemia had progressed and his Hb levels had reduced from 12.7 to 8.1 g/dL, and 1 unit of packed RBC had been transfused. The APTT was prolonged to between 70 and 80 s, and he was transferred to our hospital.

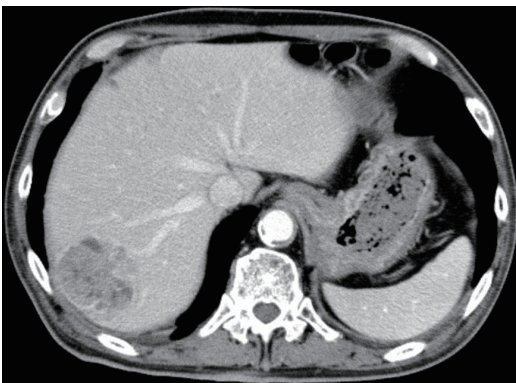
On admission, the patient had anemia lasting, with an Hb of 7.8 g/dL and a prolonged APTT of 94.0 s. FVIII activity was reduced to 3.1%, the inhibitor titer had



**Figure 1 Clinical course in case 1.** RBC-Tf: Red blood cell transfusion; Hb: Hemoglobin; APTT: Activated partial thromboplastin time; PSL: Prednisone; CPA: Cyclophosphamide; TS1: Tegafur/gimeracil/oteracil.



**Figure 2 Esophagogastroduodenoscopy imaging (Case 1).** Intestinal bleeding was detected from the site of anastomosis.



**Figure 3 Abdominal computed tomography imaging (Case 2).** HCC (5.5 cm in diameter) was noted in segment 7 of the liver.

increased to 57.1 BU/mL, and he was diagnosed with

AHA. Although his liver function tests were normal, he tested positive for hepatitis C virus antibodies, and the values of alpha-fetoprotein and protein induced by vitamin K absence-II were significantly higher at 1862 ng/mL and 210 mAU/mL, respectively. His anemia had worsened (Hb level, 6.8 g/dL), and 1 unit of packed RBC was transfused. Bypassing agents were not used as the bleeding was not considered to be severe at that time. In addition to continuing PSL administration (5 mg/d), rituximab (RTX 375 mg/m<sup>2</sup>) was administered 5 times every week in order to eradicate the inhibitors without eliciting side effects. As a result, the inhibitor titer was reduced to 3.5 BU/mL after 3 wk and hemostasis was achieved. The patient was transferred back to his previous hospital to continue treatment for HCC. At this hospital, eradication of the inhibitors was confirmed approximately 1 mo after RTX treatment had terminated. Although transcatheter arterial chemoembolization was performed for HCC, the treatment was not effective, and the HCC continued to progress aggressively. The patient died at the hospice 7 mo after the HCC diagnosis.

## DISCUSSION

Control failure of Treg cell line against autoimmune response to FVIII is considered to be one of the onset factors of AHA<sup>[9]</sup>. More intense antibody responses, that is, higher inhibitor titers (10 BU or more) to FVIII correlated with a predominance of Th2-driven subclasses IgG<sub>4</sub><sup>[10]</sup>.

Malignancies have been reported to occur in 11.5% of patients with AHA<sup>[4]</sup>. This pathological condition can



be attributed to an imbalance in the immune system associated with the onset of solid cancer. However, the true causality and the underlying mechanism by which cancer cells induce autoantibodies to FVIII have not been elucidated yet<sup>[8]</sup>. Iatrogenic bleeding may be the initial sign in AHA patients<sup>[11]</sup>. In case 1, since the APTT before gastrectomy was normal, surgical procedure may be a trigger for the development of an acquired inhibitor against FVIII.

Regardless of the presence or absence of underlying disease, the treatment for AHA is divided into hemostatic therapy for hemorrhage<sup>[4]</sup> and immunotherapy aimed at eradicating inhibitors<sup>[12]</sup>. Bypass hemostatic agents, recombinant activated factor VII and activated prothrombin complex concentrate, are considered to the first-line approach for the treatment of bleeding episodes<sup>[4,13]</sup>. In the study of the European Acquired Haemophilia Registry (EACH 2), 144 of the 482 AHA patients (30%), especially for "non-severe" patients, hemostatic treatment was not required<sup>[4]</sup>. The two patients in our study did not develop life-threatening bleeding after they were transferred to our hospital. Therefore, immunological treatments were administered instead of bypassing agents to achieve hemostasis through reducing the inhibitor titer against FVIII. The EACH2 study demonstrated that among the immunological treatments for AHA, the combination of PSL and CPA was more effective than PSL alone, with remission rates of 80% and 58%, respectively<sup>[12]</sup>. In our first patient, PSL alone was not effective, but the combination of PSL and CPA was effective. Our second patient had DM and was almost bedridden, and could not use either original PSL (1 mg/kg day) or CPA because he was considered to have a high risk of developing fatal infectious diseases. According to Japanese and Italian guidelines<sup>[14,15]</sup>, RTX alone was selected, which is suggested as an alternative treatment, and our patient was successfully treated.

In the recent review based on the histories of 105 cases of AHA in cancers, prostate (25.3%) and lung (15.8%) cancer were more frequent, followed by colon cancer (9.5%)<sup>[8]</sup>. There were 3 cases of gastric cancer<sup>[16-18]</sup> and 2 cases of HCC<sup>[19,20]</sup>. Another case report for AHA with HCC has also been published<sup>[21]</sup>. Compared with the patients with idiopathic AHA, patients with cancer are more likely to show recurrent bleeding and are less likely to achieve a complete response with eradication of the inhibitors<sup>[8]</sup>. As with our two patients, gastric cancer and HCC were both identified as advanced cancers in these studies and patients generally had a poor prognosis. Regarding hemostasis, AHA in our patients was successfully treated, however, both patients died of cancer within 1 year. As noted by Casadiego-Peña *et al.*<sup>[22]</sup>, in the case of AHA with cancer, it is recommended to combine immunological treatment to eradicate the inhibitor with therapy for the malignancy. In our patients, cancer progression may not have occurred due to immunosuppression resulting

from the administration of immunological treatments, but it is more likely that the cancers were already highly advanced at the time of AHA onset.

In conclusion, AHA remission was achieved in both patients despite cancer progression until their deaths. Besides hemostatic therapy and immunological treatments, successful treatment of AHA patients with cancer requires the concurrent treatment of the underlying malignancy. As opposed to hematological malignancies for which chemotherapy is often effective, solid cancers in AHA patients are typically detected at advanced stages. Thus, these patients are likely to have a poor prognosis.

## ACKNOWLEDGMENTS

We would like to thank Doctor Takuro Machida (Sapporo Century Hospital) and Doctor Hajime Sakai (Teine Keijinkai Hospital) for your help in following our two cases reported here.

## ARTICLE HIGHLIGHTS

### Case characteristics

60s two Japanese men with solid cancer [one is gastric cancer, the other is hepatocellular carcinoma (HCC)] had a marked bleeding tendency.

### Clinical diagnosis

Progressed anemia due to severe hemorrhage, requiring blood transfusion.

### Differential diagnosis

Hemorrhagic disease, such as immune thrombocytopenia or disseminated intravascular coagulation.

### Laboratory diagnosis

In both patients, hemoglobin level reached < 7 g/dL, prolonged APTT of 94 s, and FVIII activity was reduced to 3.1%. The inhibitor titer was 7.59 and 57.1 BU/mL respectively, compatible with acquired hemophilia A (AHA). In the second patients, hepatitis C virus antibodies were positive and the levels of alpha-fetoprotein and protein induced by vitamin K absence- II were 1862 ng/mL and 210 mAU/mL, respectively.

### Imaging diagnosis

Endoscopic examination in the first case revealed intestinal bleeding from the site of the anastomosis. Abdominal computed tomography scan in the second patients revealed HCC (5.5 cm in diameter).

### Pathological diagnosis

In the first case, resected stomach and intraperitoneal cytology identified gastric cancer.

### Treatment

Immunological treatments (prednisone and cyclophosphamide in case 1, and rituximab alone in case 2) were administered instead of bypassing agents. Oral tegafur/gimeracil/oteracil was administered in case 1, and transcatheter arterial chemoembolization was performed in case 2.

### Related reports

Recently, a systematic review described a large number of AHA patients with cancer.

### Term explanation

AHA patients with cancer are more likely to exhibit recurrent hemorrhage and are less likely to achieve a complete response with eradication of the neutralizing autoantibodies.

### Experiences and lessons

Besides hemostatic therapy and immunological treatments, successful treatment of AHA patients with cancer requires the concurrent treatment of the underlying malignancy.

## REFERENCES

- 1 **Delgado J**, Jimenez-Yuste V, Hernandez-Navarro F, Villar A. Acquired haemophilia: review and meta-analysis focused on therapy and prognostic factors. *Br J Haematol* 2003; **121**: 21-35 [PMID: 12670328 DOI: 10.1046/j.1365-2141.2003.04162.x]
- 2 **Collins PW**, Hirsch S, Baglin TP, Dolan G, Hanley J, Makris M, Keeling DM, Liesner R, Brown SA, Hay CR; UK Haemophilia Centre Doctors' Organisation. Acquired hemophilia A in the United Kingdom: a 2-year national surveillance study by the United Kingdom Haemophilia Centre Doctors' Organisation. *Blood* 2007; **109**: 1870-1877 [PMID: 17047148 DOI: 10.1182/blood-2006-06-029850]
- 3 **Baudo F**, Mostarda G, de Cataldo F. Acquired factor VIII and factor IX inhibitors: survey of the Italian haemophilia centers (AICE). *Haematologica* 2003; **88** Suppl 12: S93-99 Available from: URL: <https://www.researchgate.net/publication/285180247>
- 4 **Baudo F**, Collins P, Huth-Kühne A, Lévesque H, Marco P, Nemes L, Pellegrini F, Tengborn L, Knoebl P; EACH2 registry contributors. Management of bleeding in acquired hemophilia A: results from the European Acquired Haemophilia (EACH2) Registry. *Blood* 2012; **120**: 39-46 [PMID: 22618709 DOI: 10.1182/blood-2012-02-408930]
- 5 **Reeves BN**, Key NS. Acquired hemophilia in malignancy. *Thromb Res* 2012; **129** Suppl 1: S66-S68 [PMID: 22682137 DOI: 10.1016/S0049-3848(12)70019-1]
- 6 **Sallah S**, Wan JY. Inhibitors against factor VIII in patients with cancer. Analysis of 41 patients. *Cancer* 2001; **91**: 1067-1074 [PMID: 11267950 DOI: 10.1002/1097-0142(20010315)91:6<1067::AID-CNCR1101>3.0.CO;2-4]
- 7 **Tiede A**, Klamroth R, Scharf RE, Trappe RU, Holstein K, Huth-Kühne A, Gottstein S, Geisen U, Schenk J, Scholz U, Schilling K, Neumeister P, Miesbach W, Manner D, Greil R, von Auer C, Krause M, Leimkühler K, Kalus U, Blumtritt JM, Werwitzke S, Budde E, Koch A, Knöbl P. Prognostic factors for remission of and survival in acquired hemophilia A (AHA): results from the GTH-AH 01/2010 study. *Blood* 2015; **125**: 1091-1097 [PMID: 25525118 DOI: 10.1182/blood-2014-07-587089]
- 8 **Napolitano M**, Siragusa S, Mancuso S, Kessler CM. Acquired haemophilia in cancer: A systematic and critical literature review. *Haemophilia* 2018; **24**: 43-56 [PMID: 28960809 DOI: 10.1111/hae.13355]
- 9 **Lacroix-Desmazes S**, Navarrete AM, André S, Bayry J, Kaveri SV, Dasgupta S. Dynamics of factor VIII interactions determine its immunologic fate in hemophilia A. *Blood* 2008; **112**: 240-249 [PMID: 18469198 DOI: 10.1182/blood-2008-02-124941]
- 10 **Reding MT**, Lei S, Lei H, Green D, Gill J, Conti-Fine BM. Distribution of Th1- and Th2-induced anti-factor VIII IgG subclasses in congenital and acquired hemophilia patients. *Thromb Haemost* 2002; **88**: 568-575 [PMID: 12362225 DOI: 10.1055/s-0037-1613257]
- 11 **Boggio LN**, Green D. Acquired hemophilia. *Rev Clin Exp Hematol* 2001; **5**: 389-404; quiz following 431 [PMID: 11844135 DOI: 10.1046/j.1468-0734.2001.00049.x]
- 12 **Collins P**, Baudo F, Knoebl P, Lévesque H, Nemes L, Pellegrini F, Marco P, Tengborn L, Huth-Kühne A; EACH2 registry collaborators. Immunosuppression for acquired hemophilia A: results from the European Acquired Haemophilia Registry (EACH2). *Blood* 2012; **120**: 47-55 [PMID: 22517903 DOI: 10.1182/blood-2012-02-409185]
- 13 **Saito M**, Kanaya M, Izumiyama K, Mori A, Irie T, Tanaka M, Morioka M, Ieko M. Treatment of bleeding in acquired hemophilia A with the proper administration of recombinant activated factor VII: single-center study of 7 cases. *Int J Gen Med* 2016; **9**: 393-399 [PMID: 27843336 DOI: 10.2147/IJGM.S118422]
- 14 **Sakai M**, Amano K, Ogawa K, Takami A, Tokugawa T, Nogami K, Hato T, Fujii T, Matsumoto I, Matsumoto T. Guidelines for the management of acquired hemophilia A: 2017 revision. *Nihon Kessen Shiketsu Gakkai Zasshi* 2017; **28**: 715-747 [DOI: 10.2491/jjst.28.715]
- 15 **Franchini M**, Castaman G, Coppola A, Santoro C, Zanon E, Di Minno G, Morfini M, Santagostino E, Rocino A; AICE Working Group. Acquired inhibitors of clotting factors: AICE recommendations for diagnosis and management. *Blood Transfus* 2015; **13**: 498-513 [PMID: 26192778 DOI: 10.2450/2015.0141-15]
- 16 **Hayashi T**, Morishita E, Asakura H, Nakao S. Two cases of acquired hemophilia A in elderly patients. *Nihon Ronen Igakkai Zasshi* 2010; **47**: 329-333 [PMID: 20847491 DOI: 10.3143/geriatrics.47.329]
- 17 **Sallah S**, Singh P, Hanrahan LR. Antibodies against factor VIII in patients with solid tumors: successful treatment of cancer may suppress inhibitor formation. *Haemostasis* 1998; **28**: 244-249 [PMID: 10420073 DOI: 10.1159/000022438]
- 18 **Harada Y**, Iwai M, Miyoshi M, Ueda Y, Mitsufuji S, Seiki K, Harada M, Kashima K. Life-threatening hemorrhage in a patient with gastric cancer and acquired hemophilia. *Am J Gastroenterol* 1998; **93**: 1372-1373 [PMID: 9707070 DOI: 10.1111/j.1572-0241.1998.421\_b.x]
- 19 **Neilson RF**, Walker ID, Robertson M. Factor VIII inhibitor associated with hepatocellular carcinoma. *Clin Lab Haematol* 1993; **15**: 145-148 [PMID: 8394235 DOI: 10.1111/j.1365-2257.1993.tb00139.x]
- 20 **Croft J**, Sahu S. Acquired haemophilia A in hepatocellular carcinoma. *Br J Haematol* 2014; **164**: 617 [PMID: 24134643 DOI: 10.1111/bjh.12610]
- 21 **Franco-Moreno AI**, Santero-García M, Cabezon-Gutiérrez L, Martín-Díaz RM, García-Navarro MJ. Acquired hemophilia A in a patient with hepatocellular carcinoma: a case report and literature review. *Ann Hematol* 2016; **95**: 2099-2100 [PMID: 27666283 DOI: 10.1007/s00277-016-2825-5]
- 22 **Casadieago-Peña C**, González-Motta A, Perilla OG, Gomez PD, Enciso LJ. Acquired Hemophilia Secondary to Soft-tissue Sarcoma: Case Report from a Latin American Hospital and Literature Review. *Cureus* 2018; **10**: e2621 [PMID: 30027013 DOI: 10.7759/cureus.2621]

**P- Reviewer:** Chedid MF, Niu ZS, Tiberio GAM **S- Editor:** Dou Y  
**L- Editor:** A **E- Editor:** Song H





Published by **Baishideng Publishing Group Inc**  
7901 Stoneridge Drive, Suite 501, Pleasanton, CA 94588, USA  
Telephone: +1-925-223-8242  
Fax: +1-925-223-8243  
E-mail: [bpgoffice@wjgnet.com](mailto:bpgoffice@wjgnet.com)  
Help Desk: <http://www.f6publishing.com/helpdesk>  
<http://www.wjgnet.com>

