

# World Journal of *Gastroenterology*

*World J Gastroenterol* 2018 October 28; 24(40): 4519-4616





### EDITORIAL

- 4519 Extracellular vesicles in liver disease and beyond  
*Morán L, Cubero FJ*
- 4527 Better surgical treatment method for hepatocellular carcinoma with portal vein tumor thrombus  
*Peng SY, Wang XA, Huang CY, Li JT, Hong DF, Wang YF, Xu B*

### MINIREVIEWS

- 4536 Dimensions of hepatocellular carcinoma phenotypic diversity  
*Désert R, Nieto N, Musso O*
- 4548 Second-line rescue treatment of *Helicobacter pylori* infection: Where are we now?  
*Lin TF, Hsu PI*

### ORIGINAL ARTICLE

#### Basic Study

- 4554 Recovery of natural killer cells is mainly in post-treatment period in chronic hepatitis C patients treated with sofosbuvir plus ledipasvir  
*Wang XX, Luo BF, Jiang HJ, Cong X, Jin Q, Ma DL, Wei L, Feng B*
- 4565 *Helicobacter pylori* promotes invasion and metastasis of gastric cancer by enhancing heparanase expression  
*Liu LP, Sheng XP, Shuai TK, Zhao YX, Li B, Li YM*

#### Retrospective Study

- 4578 Self-expandable metal stents in patients with postoperative delayed gastric emptying after distal gastrectomy  
*Kim SH, Keum B, Choi HS, Kim ES, Seo YS, Jeon YT, Lee HS, Chun HJ, Um SH, Kim CD, Park S*
- 4586 Second primary malignancy risk after radiotherapy in rectal cancer survivors  
*Wang TH, Liu CJ, Chao TF, Chen TJ, Hu YW*
- 4596 Outcomes of furazolidone- and amoxicillin-based quadruple therapy for *Helicobacter pylori* infection and predictors of failed eradication  
*Zhang YW, Hu WL, Cai Y, Zheng WF, Du Q, Kim JJ, Kao JY, Dai N, Si JM*

#### Observational Study

- 4606 Long term outcome of antiviral therapy in patients with hepatitis B-associated decompensated cirrhosis  
*Ju YC, Jun DW, Choi J, Saeed WK, Lee HY, Oh HW*

### LETTERS TO THE EDITOR

- 4615 To our readers: Important questions from the editors/editorial board  
*Tanawski AS*

## Contents

*World Journal of Gastroenterology*  
Volume 24 Number 40 October 28, 2018

### ABOUT COVER

Editorial board member of *World Journal of Gastroenterology*, Mortada HF El-Shabrawi, MD, Professor, Department of Pediatrics, Cairo University, Cairo 11559, Egypt

### AIMS AND SCOPE

*World Journal of Gastroenterology* (*World J Gastroenterol*, *WJG*, print ISSN 1007-9327, online ISSN 2219-2840, DOI: 10.3748) is a peer-reviewed open access journal. *WJG* was established on October 1, 1995. It is published weekly on the 7<sup>th</sup>, 14<sup>th</sup>, 21<sup>st</sup>, and 28<sup>th</sup> each month. The *WJG* Editorial Board consists of 642 experts in gastroenterology and hepatology from 59 countries.

The primary task of *WJG* is to rapidly publish high-quality original articles, reviews, and commentaries in the fields of gastroenterology, hepatology, gastrointestinal endoscopy, gastrointestinal surgery, hepatobiliary surgery, gastrointestinal oncology, gastrointestinal radiation oncology, gastrointestinal imaging, gastrointestinal interventional therapy, gastrointestinal infectious diseases, gastrointestinal pharmacology, gastrointestinal pathophysiology, gastrointestinal pathology, evidence-based medicine in gastroenterology, pancreatology, gastrointestinal laboratory medicine, gastrointestinal molecular biology, gastrointestinal immunology, gastrointestinal microbiology, gastrointestinal genetics, gastrointestinal translational medicine, gastrointestinal diagnostics, and gastrointestinal therapeutics. *WJG* is dedicated to become an influential and prestigious journal in gastroenterology and hepatology, to promote the development of above disciplines, and to improve the diagnostic and therapeutic skill and expertise of clinicians.

### INDEXING/ABSTRACTING

*World Journal of Gastroenterology* (*WJG*) is now indexed in Current Contents®/Clinical Medicine, Science Citation Index Expanded (also known as SciSearch®), Journal Citation Reports®, Index Medicus, MEDLINE, PubMed, PubMed Central and Directory of Open Access Journals. The 2018 edition of Journal Citation Reports® cites the 2017 impact factor for *WJG* as 3.300 (5-year impact factor: 3.387), ranking *WJG* as 35<sup>th</sup> among 80 journals in gastroenterology and hepatology (quartile in category Q2).

### EDITORS FOR THIS ISSUE

Responsible Assistant Editor: *Xiang Li*  
Responsible Electronic Editor: *Ying-Na Bian*  
Proofing Editor-in-Chief: *Lian-Sheng Ma*

Responsible Science Editor: *Ruo-Yu Ma*  
Proofing Editorial Office Director: *Ze-Mao Gong*

#### NAME OF JOURNAL

*World Journal of Gastroenterology*

#### ISSN

ISSN 1007-9327 (print)  
ISSN 2219-2840 (online)

#### LAUNCH DATE

October 1, 1995

#### FREQUENCY

Weekly

#### EDITORS-IN-CHIEF

**Andrzej S Tarnawski, MD, PhD, DSc (Med),**  
Professor of Medicine, Chief Gastroenterology, VA Long Beach Health Care System, University of California, Irvine, CA, 5901 E. Seventh Str, Long Beach, CA 90822, United States

#### EDITORIAL BOARD MEMBERS

All editorial board members resources online at <http://www.wjgnet.com/1007-9327/editorialboard.htm>

#### EDITORIAL OFFICE

Ze-Mao Gong, Director  
*World Journal of Gastroenterology*  
Baishideng Publishing Group Inc  
7901 Stoneridge Drive, Suite 501,  
Pleasanton, CA 94588, USA  
Telephone: +1-925-2238242  
Fax: +1-925-2238243  
E-mail: [editorialoffice@wjgnet.com](mailto:editorialoffice@wjgnet.com)  
Help Desk: <http://www.f6publishing.com/helpdesk>  
<http://www.wjgnet.com>

#### PUBLISHER

Baishideng Publishing Group Inc  
7901 Stoneridge Drive, Suite 501,  
Pleasanton, CA 94588, USA  
Telephone: +1-925-2238242  
Fax: +1-925-2238243  
E-mail: [bpgooffice@wjgnet.com](mailto:bpgooffice@wjgnet.com)  
Help Desk: <http://www.f6publishing.com/helpdesk>  
<http://www.wjgnet.com>

#### PUBLICATION DATE

October 28, 2018

#### COPYRIGHT

© 2018 Baishideng Publishing Group Inc. Articles published by this Open-Access journal are distributed under the terms of the Creative Commons Attribution Non-commercial License, which permits use, distribution, and reproduction in any medium, provided the original work is properly cited, the use is non commercial and is otherwise in compliance with the license.

#### SPECIAL STATEMENT

All articles published in journals owned by the Baishideng Publishing Group (BPG) represent the views and opinions of their authors, and not the views, opinions or policies of the BPG, except where otherwise explicitly indicated.

#### INSTRUCTIONS TO AUTHORS

Full instructions are available online at <http://www.wjgnet.com/bpg/gerinfo/204>

#### ONLINE SUBMISSION

<http://www.f6publishing.com>

## Better surgical treatment method for hepatocellular carcinoma with portal vein tumor thrombus

Shu-You Peng, Xu-An Wang, Cong-Yun Huang, Jiang-Tao Li, De-Fei Hong, Yi-Fang Wang, Bin Xu

Shu-You Peng, Jiang-Tao Li, Department of Hepatobiliary and Pancreatic Surgery, The Second Affiliated Hospital of Zhejiang University School of Medicine, Hangzhou 310006, Zhejiang Province, China

Xu-An Wang, Department of General Surgery, Xinhua Hospital Affiliated to Shanghai Jiaotong University School of Medicine, Shanghai 200092, China

Cong-Yun Huang, Department of General Surgery, Yuebei People's Hospital Affiliated to Shantou University School of Medicine, Shaoguan 512025, Guangdong Province, China

De-Fei Hong, Yi-Fang Wang, Bin Xu, Department of Hepatobiliary and Pancreatic Surgery, Sir Run Run Shaw Hospital Affiliated Hospital of Zhejiang University School of Medicine, Hangzhou 310016, Zhejiang Province, China

ORCID number: Shu-You Peng (0000-0003-3989-3056); Xu-An Wang (0000-0001-9437-457X); Cong-Yun Huang (0000-0003-3886-4130); Jiang-Tao Li (0000-0001-7538-2910); De-Fei Hong (0000-0001-8665-1119); Yi-Fan Wang (0000-0002-8828-4268); Bin Xu (0000-0003-0889-5737).

**Author contributions:** Peng SY and Wang XA contributed equally to this work; Peng SY and Wang XA wrote and revised the manuscript; Peng SY designed the "thrombectomy first" approach. All the authors participated in the operations.

**Supported by** Shanghai Pujiang Program, No.17PJD025; and Shanghai Natural Science Foundation, No.17ZR1418500.

**Conflict-of-interest statement:** All the authors deny any form of conflict of interest.

**Open-Access:** This article is an open-access article which was selected by an in-house editor and fully peer-reviewed by external reviewers. It is distributed in accordance with the Creative Commons Attribution Non Commercial (CC BY-NC 4.0) license, which permits others to distribute, remix, adapt, build upon this work non-commercially, and license their derivative works on different terms, provided the original work is properly cited and the use is non-commercial. See: <http://creativecommons.org/licenses/by-nc/4.0/>

**Manuscript source:** Invited manuscript

**Correspondence to:** Xu-An Wang, MD, PhD, Department of General Surgery, Xinhua Hospital Affiliated to Shanghai Jiaotong University School of Medicine, No. 1665, Kongjiang Road, Shanghai 200092, China. [wangxuan@xinhumed.com.cn](mailto:wangxuan@xinhumed.com.cn)  
Telephone: +86-21-25078813

**Received:** August 21, 2018

**Peer-review started:** August 22, 2018

**First decision:** August 30, 2018

**Revised:** September 11, 2018

**Accepted:** October 5, 2018

**Article in press:** October 5, 2018

**Published online:** October 28, 2018

### Abstract

Hepatocellular carcinoma (HCC) with portal vein tumor thrombus (PVTT) is a disease that is not uncommon, but the treatments vary drastically between Eastern and Western countries. In Europe and America, the first line of treatment is systemic therapy such as sorafenib and the surgical treatment is not a recommend option. While an increasing number of studies from China and Japan have suggested that surgical treatment results in better outcomes when compared to transcatheter arterial chemoembolization (TACE), sorafenib, or other nonsurgical treatments, and two classification systems, Japanese Vp classification and Chinese Cheng's classification, were very useful to guide the surgical treatment. We have also found that surgical treatment may be more effective, as we have performed surgical treatment for HCC-PVTT patients over a period of approximately 15 years and achieved good results with the longest surviving time being 13 years and onward. In this study, we review the efficacy and principles of current surgical treatments and introduce our new, more effective surgical technique named "thrombectomy first", which means the tumor thrombus in the main portal vein, the bifurcation or the contralateral portal vein should be removed prior to liver resection. Thus, compression and crushing of PVTT during the operation could be avoided and new intrahepatic



metastases caused by tumor thrombus to the remnant liver minimized. The new technique is even beneficial to the prognosis of Cheng's classification Types III and IV PVTT. The vital tips and tricks for the surgical approach are described.

**Key words:** Portal vein tumor thrombus; Thrombectomy first; Surgery; Hepatocellular carcinoma

© **The Author(s) 2018.** Published by Baishideng Publishing Group Inc. All rights reserved.

**Core tip:** The treatments for hepatocellular carcinoma with portal vein tumor thrombus between Eastern and Western countries vary drastically. In Western countries, the first-line treatment is systemic therapy such as sorafenib, while studies from China and Japan suggest that surgical treatment results in better outcomes. We review the efficacy and principles of current surgical treatments and introduce our new, more effective surgical technique named "thrombectomy first", which means the tumor thrombus would be removed prior to liver resection. We have performed this technique over approximately 15 years and achieved good results with the longest surviving time being 13 years and onward.

Peng SY, Wang XA, Huang CY, Li JT, Hong DF, Wang YF, Xu B. Better surgical treatment method for hepatocellular carcinoma with portal vein tumor thrombus. *World J Gastroenterol* 2018; 24(40): 4527-4535 Available from: URL: <http://www.wjgnet.com/1007-9327/full/v24/i40/4527.htm> DOI: <http://dx.doi.org/10.3748/wjg.v24.i40.4527>

## INTRODUCTION

Portal vein tumor thrombus (PVTT) is not rare, but it is correlated with an extremely poor prognosis, with approximately 40% of patients with hepatocellular carcinoma (HCC) having PVTT when diagnosed<sup>[1]</sup>. HCC with PVTT is recognized as an advanced stage disease (BCLC-C) according to the Barcelona Clinic for Liver Cancer (BCLC) staging system<sup>[2]</sup>. Surgical resection is not a recommended treatment option; the only proposed treatment option is systemic therapy. The tyrosine kinase inhibitors sorafenib and regorafenib have been reported to prolong survival and have been selected as treatment options<sup>[3]</sup>. Both the American Association for the Study of the Liver Disease (AASLD) and the European Association for the Study of the Liver (EASL) accepted the BCLC treatment algorithm<sup>[4,5]</sup>.

Eastern countries have totally opposite views. Experts from mainland China<sup>[6]</sup> and Japan<sup>[7]</sup> as well as other eastern experts<sup>[8]</sup> have recognized that HCC with PVTT is not a contradiction of surgical approach. In selected HCC-PVTT patients, surgical treatment could not only improve the life quality but also prolong the survival time, even though a R0 resection for this malignant disease could

not be achieved. The criteria for surgical resection are defined as follows: (1) PVTT type I / II or type III/IV (but these classifications remain controversial); (2) Good general medical conditions with Eastern Cooperative Oncology Group (ECOG) scores of 0-2; (3) Liver function was Child-Pugh class A or selected class B; (4) Resectable primary tumor, without metastasis; and (5) Enough future liver remnant.

We have performed surgical treatment for HCC-PVTT patients over a period of approximately 15 years and achieved good results, with the longest surviving time being 13 years and onward. In this study, we review the efficacy and principles of current surgical treatments and introduce our new, more effective surgical technique named "thrombectomy first".

## EFFICACY OF SURGICAL TREATMENT

### *Surgical vs nonsurgical treatments*

A Japanese nationwide survey<sup>[9]</sup> of 6474 patients from 645 registered institutions showed that the median survival time (MST) of the operation group was prolonged by 1.77 years compared to the nonsurgical group (2.87 years vs 1.10 years;  $P < 0.001$ ) for the overall cohort and by 0.88 years (2.45 years vs 1.57 years;  $P < 0.001$ ) for the propensity score-matched cohort. Furthermore, the survival rates at 1, 3, and 5 years after diagnosis for the operation group were significantly higher compared to the conventional treatment group, with the survival rates being 70.9%, 43.5%, and 32.9% compared to 62.9%, 31.6%, and 20.1%, respectively. Moreover, subgroup analysis after propensity score matching revealed that surgical treatment provided a survival benefit regardless of age, etiology, serum  $\alpha$ -fetoprotein elevation, tumor number, or hepatitis B or C infection; however, a previous study<sup>[7]</sup> showed that the survival benefits of surgical treatment in Vp4 patient groups were not statistically significant, and most of them could not achieve R0 or R1 resection. Thus, the authors only recommended liver resection as a first line of treatment when PVTT was limited to the first-order branch of the portal vein.

Another large cohort study from China<sup>[10]</sup> analyzed 1580 patients diagnosed with HCC with PVTT from four of the largest tertiary hospitals. The MSTs of the surgical treatment group for types I and II patients were 15.9 and 12.5 mo, respectively, and these MSTs were much better compared to their nonsurgical counterparts. The authors concluded that surgical approaches are the best treatment for type I / II PVTT patients with good liver function. Likewise, several other studies from Eastern countries also suggested the potential survival benefits of surgical treatment in HCC-PVTT patients<sup>[11-14]</sup>; however, most of these studies suggested that operation is not useful for type IV PVTT patients who had a poor prognosis.

### *Surgical vs TACE treatment*

Transcatheter arterial chemoembolization (TACE) is

commonly used to help patients with advanced HCC including PVTT. Recently, many studies reported that surgical treatment had a better prognosis compared to those undergoing TACE, especially for Cheng's types I and II PVTT. Peng *et al.*<sup>[15]</sup> compared 201 HCC patients with PVTT who received surgical treatment and 402 matched cases treated with TACE. The median survival of the surgical treatment and TACE groups was 20.0 mo  $\pm$  1.8 mo and 13.1 mo  $\pm$  0.6 mo, respectively. The 1-, 3-, and 5-year overall survival rates for the surgical and TACE groups were 42.0%, 14.1%, and 11.1% and 37.8%, 7.3%, and 0.5%, respectively ( $P < 0.001$ ). The survival curve for the operation group was better than that for the TACE group. Subgroup analyses showed that the overall survival for the operation group was better than that of the TACE group for type I / II PVTT but not for type III/IV PVTT. This result was concordant with a stratified meta-analysis<sup>[16]</sup>. Other typical studies<sup>[10,17]</sup> also favor the surgical treatment, which showed that the survival rates were better for the surgical resection group than the TACE group for Cheng's type I / II PVTT.

Combining preoperative TACE with surgical resection alone was also compared by Yamamoto<sup>[18]</sup> and Ban<sup>[19]</sup>; neither were able to find a survival benefit with pre-operative TACE for HCC-PVTT patients, especially for Cheng's types III and IV PVTT.

### **Surgical vs sorafenib treatment**

In Western countries, the first-line treatment option for HCC-PVTT is sorafenib, but the MST was short at 6.5 mo in the Eastern countries<sup>[20]</sup> and 10.7 mo in Western areas<sup>[3]</sup>. In a study by Jeong *et al.*<sup>[21]</sup>, 30 patients with HCC-PVTT (Vp3 or Vp4) treated with sorafenib monotherapy had a median survival period of only 3.1 mo. Another typical study by Nakazawa *et al.*<sup>[22]</sup> also revealed that the MST(4.3 mo) was similar for PVTT in the main trunk or in the first branch after treated with sorafenib alone. These data demonstrated that the MST was quite shorter for HCC-PVTT treated with surgical method.

## **SURGICAL CLASSIFICATION**

The tumor extent and the range and position of PVTT affect surgical planning and correlate with overall survival after surgical resection. Thus, the surgical method should aim to achieve a complete resection of the primary tumor and removal of PVTT with a sufficient future remnant liver. Therefore, classification of PVTT is necessary to determine the surgical process.

Currently, there are two classifications that are well accepted and widely used in the Asia-Pacific: the Japanese Vp classification<sup>[23,24]</sup> and the classification suggested by Cheng, who is a Chinese professor<sup>[12,25]</sup>.

### **Japanese classification**

The Liver Cancer Study Group of Japan proposed a helpful macroscopic classification divided into five grades (Vp0-Vp4)<sup>[23,25]</sup> for HCC with PVTT. Each one is defined as follows: (1) no tumor thrombus in the portal vein, Vp0; (2)

existence of a tumor thrombus distal to, but not in, the 2nd-order branches of the portal vein, Vp1; (3) presence of a tumor thrombus in the 2nd-order branches of the portal vein, Vp2; (4) existence of a tumor thrombus in the 1st-order branches of the portal vein, Vp3; and (5) presence of a tumor thrombus in the main trunk of the portal vein or a portal vein branch contralateral to the mainly involved lobe (or both), Vp4.

### **Cheng's classification**

Cheng's new classification system comprises five grades: (1) Type I 0: tumor thrombus formation found under a microscope; (2) Type I : tumor thrombus involving segmental branches of the portal vein or above; (3) Type II : tumor thrombus involving the right/left portal vein; (4) Type III: tumor thrombus involving the main portal vein trunk; and (5) Type IV: tumor thrombus involving the superior mesenteric vein or the inferior vein cava. Furthermore, two subgroups were classified for each type: (1) For Type I : I a, tumor thrombus involving segmental branches of the portal vein or above, and I b, tumor thrombus involving segmental branches of the portal vein extending to sectoral branch; (2) For Type II : II a, tumor thrombus involving the right/left portal vein, and II b, tumor thrombus involving both the left and right portal veins; (3) For Type III : IIIa, tumor thrombus involving the main portal vein trunk for no more than 2 cm below the confluence of the left and right portal veins, and IIIb, tumor thrombus involving the main portal vein trunk for more than 2 cm below the confluence of the left and right portal veins; and (4) For Type IV: IVa, tumor thrombus involving the superior mesenteric vein (SMV), and IVb, tumor thrombus involving the inferior vein cava (IVC).

Compared to the Cheng's classification, the Vp classification does not mention the extension of PVTT involving the SMV or IVC. Vp0 is equal to Type 0, Vp1 is equal to Type I a, Vp2 is equal to Type I b, Vp3 is equal to Type II a, and Vp4 is equal to Type III and Type II b. Most Japanese studies concluded that surgical treatment did not achieve a better survival outcome compared to nonsurgical treatments in Vp4 PVTT. There are, however, disadvantages of the two classifications: (1) both of them do not consider liver function or tumor-correlated factors, such as tumor number and size; and (2) no pathological information of PVTT is described, such as necrotic degree, proliferative type, necrotic type and organized type. Several studies recognized that the Cheng's classification was more applicable than the Vp classification for disease assessment and treatment.

## **SURGICAL METHODS AND EFFICACY**

Based on the two classifications, several surgical resection methods and techniques were introduced.

### **Tumor thrombus lies within the liver resection line**

*En bloc* resection of PVTT with the tumor could be achieved: (1) Segmental hepatectomy is suitable for

Japanese classification Vp1-2 or Cheng's classification Type I; (2) Hemihepatectomy is suitable for Japanese classification Vp3 or Cheng's classification Type IIa, and the primary tumor should be located in the same liver without extending beyond the hemiliver; and (3) Extended hemihepatectomy is suitable for Cheng's classification Type IIb and Japanese classification Vp4 (tumor thrombus in the bifurcation of the portal vein).

#### ***Tumor thrombus lies beyond the liver resection line***

Hepatectomy plus thrombectomy or *en bloc* resection (with or without reconstruction of the main portal vein) can be selected in this kind of HCC-PVTT, which includes Japanese classification Vp4 and Cheng's classification Types III and IV. The PVTT is typically extracted through an incision in the portal vein after resection to the liver.

#### ***Tumor thrombus invades the main portal vein wall***

Combined with the main portal resection, a direct end-to-end reconstruction is usually needed after the hepatectomy when the wall of the main portal vein is invaded by the tumor thrombus or if the removal is difficult. However, this concept is not recommended by the study based on the findings of the Japanese registry, and the result showed that when the tumor thrombus lies beyond the liver resection line or invades the main portal vein wall (type III/IV PVTT), there was no significant improvement in survival after surgical treatment.

#### ***Efficacy of different surgical methods***

Several studies compared the surgical approaches, complications, survival benefit, and recurrence between hepatectomy with thrombectomy and hepatectomy with *en bloc* resection. Most of reports showed that hepatectomy plus thrombectomy or *en bloc* resection was not significantly different no matter for patients with Vp4 or Vp3 PVTT when compared for overall survival and disease-free survival at 1, 3, and 5 years, but hepatectomy had a lower mortality and morbidity<sup>[26,27]</sup>. While some other studies suggested that thrombectomy had a risk of residual tumor and hepatectomy plus *en bloc* resection with or without reconstruction of the main portal vein would theoretically improve the oncological outcomes. Another typical study<sup>[28]</sup> also revealed that the 5-year overall survival and disease-free survival rates were not significantly decreased in HCC patients with PVTT extended to the bifurcation of the portal vein if *en bloc* resection was selected. However, the decision of such surgical manipulations could be based on various factors including the surgeon's expertise in portal vein resection and reconstruction as well as the nature of the thrombus and no randomized controlled trial had been done to compare these techniques.

## **"THROMBECTOMY FIRST" INSTEAD OF "LIVER RESECTION FIRST"**

### ***Most surgical procedures are "liver resection first"***

Most of the studies report that the prognosis is poor for

Vp4 or Types III and IV patients with HCC and PVTT. Shi *et al.*<sup>[25]</sup> compared the surgical effects of Type I/II and Type III/IV PVTT and found that the overall survival and disease-free survival rates of patients with type III or IV PVTT were significantly worse than those of type I or II. The 1- and 3-year overall survival and disease-free survival rates of 78 Type III patients were 24.7% and 3.6% and 3.0% and 0%, respectively. The 1- and 3-year overall survival and disease-free survival rates of 20 Type IV patients were 18.0% and 0% and 0% and 0%, respectively. In Li's report<sup>[27]</sup>, the 1-, 3-, and 5-year OS and DFS rates for the patients whose PVTT extended beyond the resection line were 42.6%, 11.4%, and 5.7% and 15.4%, 5.1%, and 5.1%, respectively.

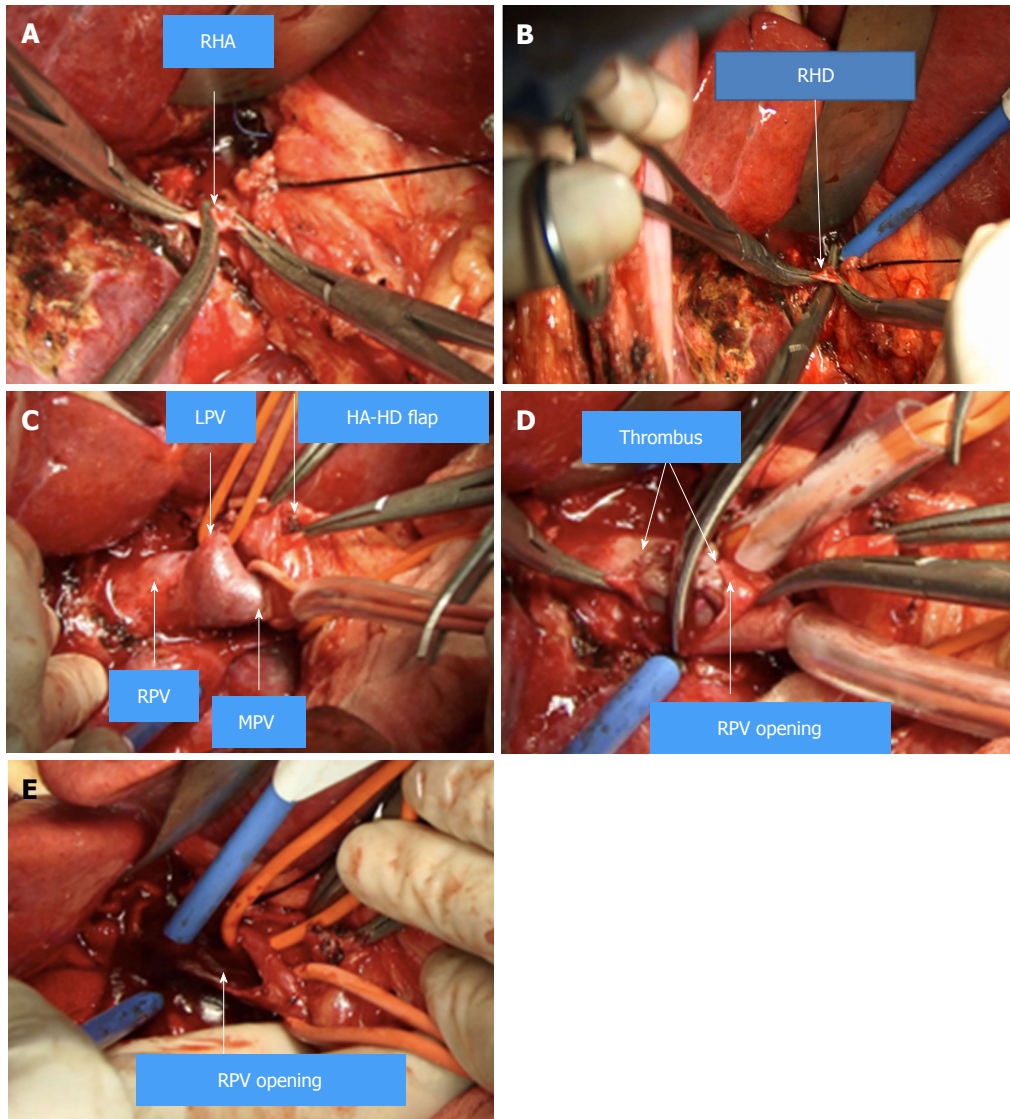
We analyzed these reports and found that almost all of them performed the thrombectomy after the liver resection. Only Daisuke<sup>[19]</sup> performed the removal of PVTT prior to the mobilization and transection of the liver, and the MST and OS were much higher than those of the other studies. The MST of 19 Vp4 patients was 28 mo and the 3- and 5-year overall survival rates were 41.8% and 20.9%, respectively. The MST of 26 Vp3 patients was 18 mo and the 3- and 5-year overall survival rates were 25.2% and 21.2%, respectively.

### ***Efficacy of "thrombectomy first" instead of "liver resection first"***

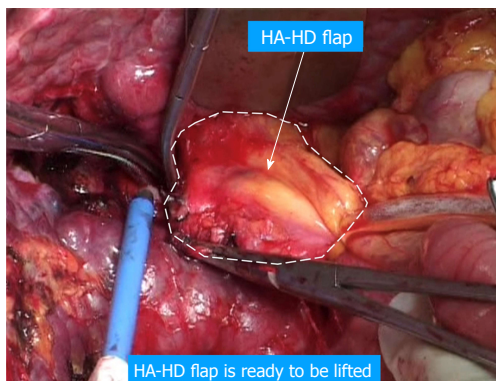
We have performed surgical treatments for Types III and IV PVTT since 2003, and we proposed a "thrombectomy first" surgical concept to provide superior surgical therapeutic effects and simplify the management approach. The tumor thrombus in the main portal vein, the bifurcation or the contralateral portal vein would be removed prior to liver resection. The main advantages of this concept are as follows: (1) Compression and crushing of PVTT during the operative process could be avoided; thus, new intrahepatic metastases caused by tumor scattering from the PVTT to the remnant liver were minimized; (2) The contralateral portal venous flow could be recovered at an early stage of the operation, which is a beneficial measure for the preservation of remnant liver function; and (3) The portal venous pressure decreases as a result of complete removal of tumor thrombus.

The following considers a right hemihepatectomy as an example to explain the detailed surgical process. The main portal vein (MPV) and the right portal vein (RPV) were clearly revealed by dissecting the fascia and Glisson sheath along the right edge of the hepatoduodenal ligament until the point where it entered the right liver. The tissues in the front were then pushed forward to fully expose the anterior wall of the RPV. Both the right hepatic artery (HA) and the right hepatic duct (HD) were then cut and ligated separately with a 1 cm distance from the entry point of the right liver (Figure 1A and B). The right HA and right HD along with the anterior tissues of the Glisson sheath was called the hepatic artery-duct flap (HA-HD flap) (Figures 2 and 3). The left hepatic portal vein was revealed by pulling up and dissecting the flap, and a small branch of the portal vein that entered the caudate lobe was cut and ligated in this process. The





**Figure 1** The “thrombectomy first” approach. A: The right hepatic artery (RHA) was isolated and dissected. B: The right hepatic duct (RHD) was isolated and dissected. C: The left portal vein (LPV), right portal vein (RPV) and the main portal vein (PV) were clearly revealed by dissecting the hepatic artery-hepatic duct (HA-HD) flap. D: The tumor thrombus in the RPV and main portal vein (MPV) was extracted. E: The tape of LPV and PV were both released to flush the remnant tumor thrombus. RHA: Right hepatic artery; RHD: Right hepatic duct; LPV: Left portal vein; RPV: Right portal vein; PV: Portal vein; MPV: Main portal vein; HA-HD: Hepatic artery-hepatic duct.



**Figure 2** The hepatic artery-hepatic duct flap was ready to be lifted. HA-HD: Hepatic artery-hepatic duct.

dissection and taping of the RPV, the left portal vein (LPV)

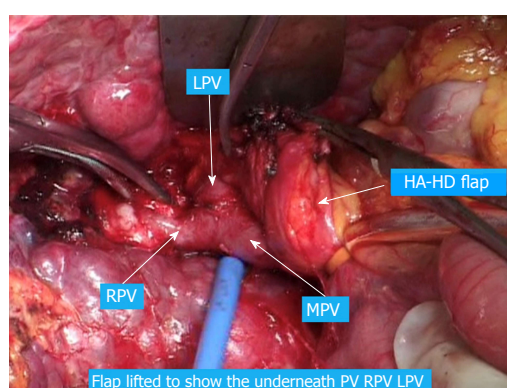
and MPV by vascular slings continued prior to ligation of the RPV distant to the bifurcation, followed by clamping of the LPV and MPV distal to the PVTT (Figure 1C). The anterior wall of the RPV was opened to a 1 cm distance to the confluence (the incision could be extended to the portal trunk longitudinally if necessary). The PVTT in the RPV and MPV was then extracted from the opening (Figure 1D), followed by flushing the potential residual tumor thrombus by the portal vein blood flow by releasing the vascular occlusion band of the MPV. The MPV was occluded again, and the PVTT in the LPV was extracted. The left remnant tumor thrombus was flushed by the reverse portal vein blood through releasing the vascular occlusion band of LPV (the left hepatic artery was not occluded), and a catheter was used to help flushing when necessary. After flushing and confirming that no PVTT remained (Figure 1E), the stump was closed by a



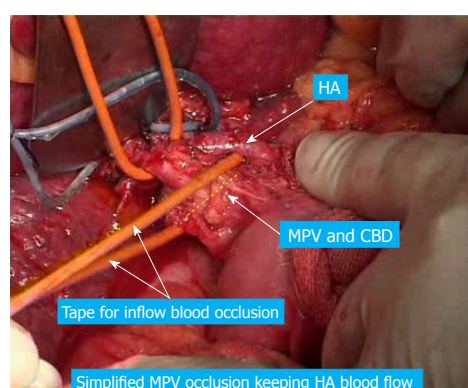
**Table 1** Clinical characteristics of the three cases

Gender	Age	HBV	Tumor location	Tumor size	PVTT classification	Operation	Pre-op treatment	Post-op treatment	Tumor recurrence	Survival time (mo)
M	40	+	Right liver	8 cm × 6 cm	Type IV or Vp4 (right branch extending to the main PV)	Thrombectomy and right hemihepatectomy	TACE (once)	TACE (4 times)	No	162 (still alive)
M	52	+	Right liver	6 cm × 6 cm	Type III or Vp4 (left and right branch)	Thrombectomy and right hemihepatectomy	TACE (once)	TACE (twice)	No	108 (still alive)
M	50	+	Left liver	20 cm × 16 cm	Type IV or Vp4 (left branch and main PV)	Thrombectomy and left hemihepatectomy	No	TACE (once)	No	55 (still alive)

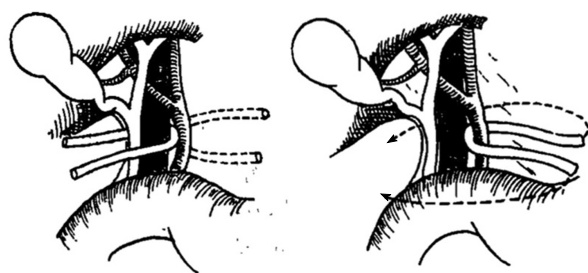
M: Male; HBV: Hepatitis B virus; TACE: Transcatheter arterial chemoembolization; PV: Portal vein; PVTT: Portal vein tumor thrombus.



**Figure 3** The hepatic artery-hepatic duct flap was lifted to show the portal vein, right portal vein, and left portal vein. RPV: Right portal vein; LPV: Left portal vein; MPV: Main portal vein; HA-HD: Hepatic artery-hepatic duct.



**Figure 5** A simplified method to occlude the main portal vein while keeping hepatic artery blood flow. HA: Hepatic artery; MPV: Main portal vein; CBD: Common bile duct.



Simplified MPV occlusion keeping HA blood flow

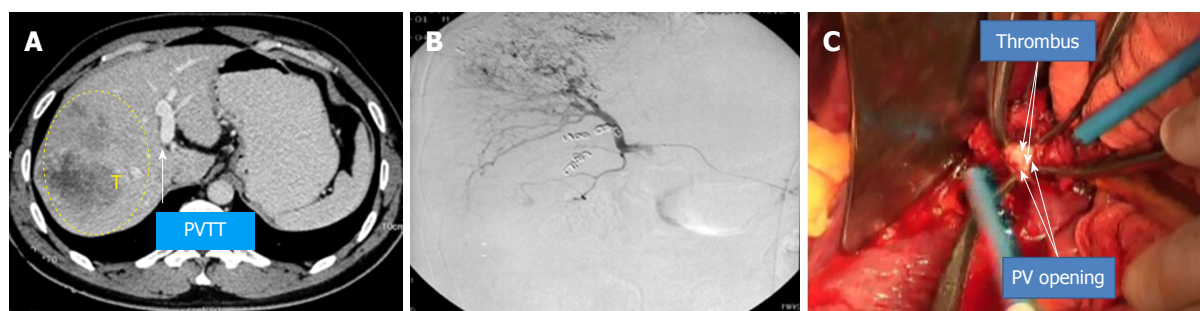
**Figure 4** A simplified method to occlude the main portal vein while keeping hepatic artery blood flow. MPV: Main portal vein; HA: Hepatic artery.

continuous Prolene suture, and the vascular occlusion was released. If the tumor thrombus strongly adhered to the portal vein wall, resection of the portal vein would be required. Direct end-to-end anastomosis was conducted to reconstruct the portal vein with the use of a 6/0 Prolene continuous suture. After suturing, the right liver was mobilized and transected *via* standard procedure, or the anterior approach was performed using PMOD (Peng's Multiple Operative Dissector). To achieve long-term survival, the thrombectomy must be completely cleared. A key element to successfully performing the operation is doing so with no time pressure to prevent sloppiness.

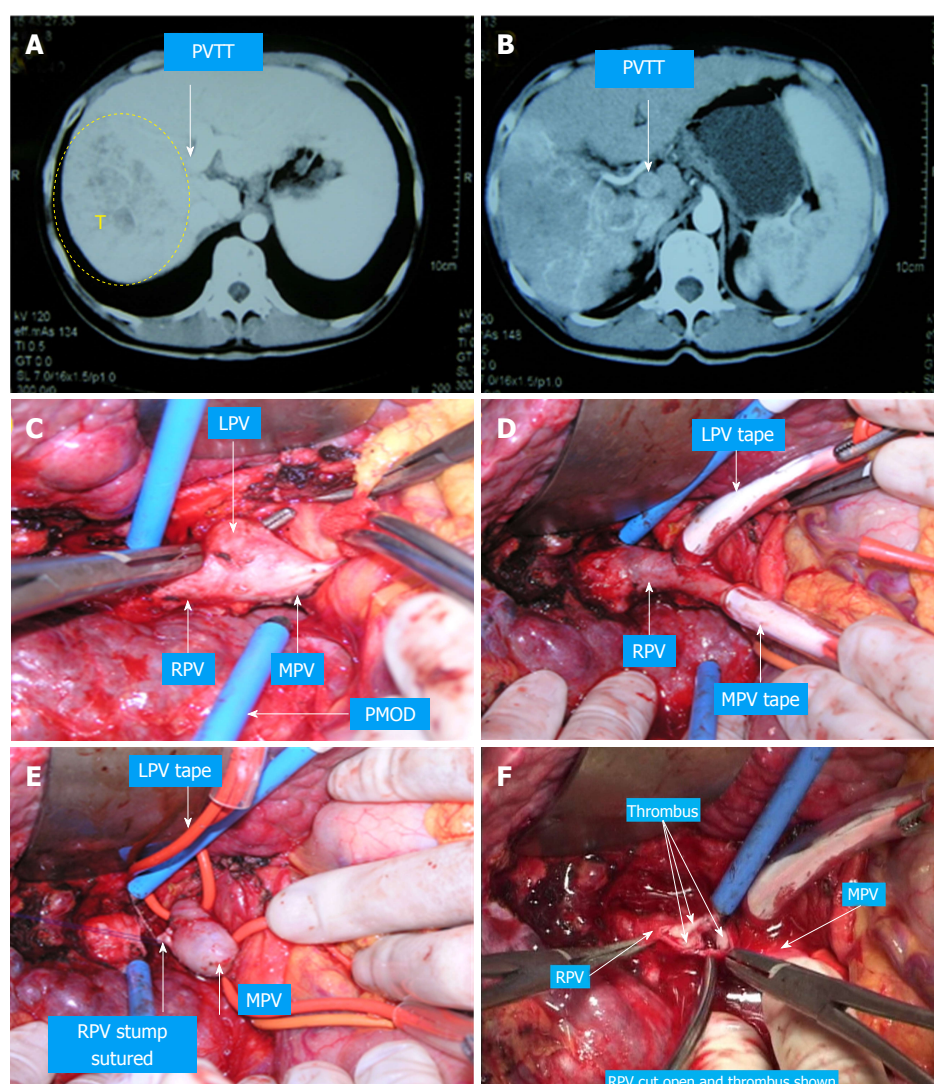
When blocking the MPV, the HA blood flow should be not occluded to protect remnant liver function. If the MPV was difficult to dissect, the selected portal vein occlusion method was used by isolating the common hepatic artery and occluding the portal trunk and common hepatic duct together (Figures 4 and 5).

We have performed the "thrombectomy first" approach at two campuses of the Second Hospital affiliated with Zhejiang University School of Medicine, two campuses of the Sir Run Run Shaw Hospital affiliated with Zhejiang University School of Medicine and Yuebei People's Hospital affiliated with Shantou University School of Medicine for roughly 15 years. Detailed data is still being collected and analyzed (unpublished), but we would like to share three typical Cheng's Type III/IV (Vp4) cases that had long-term survival. The disease-free survival time was 13, 9 and 4.6 years, respectively (Table 1).

Case 1 (Figure 6, the pictures were taken by camera 13 years ago and had poor quality): A 40-year-old man had HBV infection for more than 10 years. The CT scan showed an 8 cm × 6 cm mass with satellite lesions in the right liver, and tumor thrombus was found in the right branch of the portal vein and extended to the MPV, and the liver function was Class A according to Child-Pugh classification. The patient was diagnosed with HCC-PVTT and received TACE once before surgery.



**Figure 6 Case 1.** A: The computed tomography scan showed tumor thrombus in the right portal vein. B: Transcatheter arterial chemoembolization was performed before the operation. C: The thrombus was extracted from the right portal vein opening. PV: Portal vein; PVTT: Portal vein tumor thrombus.



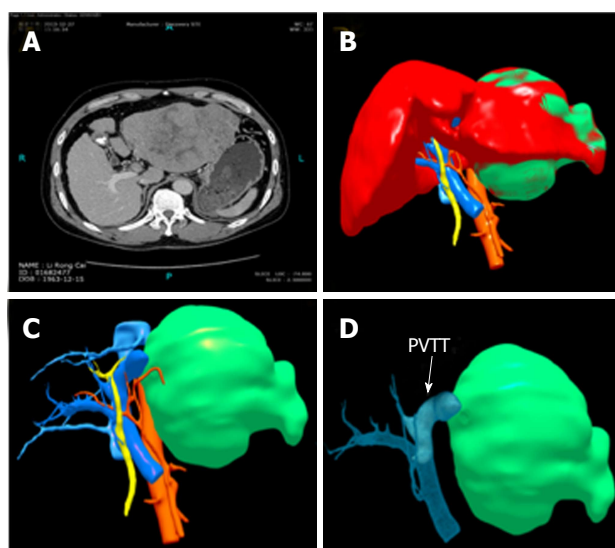
**Figure 7 Case 2.** A: The computed tomography scan showed tumor thrombus in the right portal vein (RPV) and portal vein (PV). B: Transcatheter arterial chemoembolization was performed before the operation. C and D: The left portal vein (LPV), RPV and PV were clearly revealed by dissecting the hepatic artery-hepatic duct flap. E: The LPV and PV were taped. F: Tumor thrombus in the RPV and PV was extracted. G: The tumor thrombus in the LPV was extracted, and the RPV stump was closed. H: Live transection was performed by the anterior approach. PV: Portal vein; PVTT: Portal vein tumor thrombus; RPV: Right portal vein; LPV: Left portal vein; MPV: Main portal vein; HA-HD: Hepatic artery-hepatic duct.

The “thrombectomy first” approach plus right hemihepatectomy was performed in February 2005. The patient recovered smoothly after surgery and continued with TACE treatment four times after the operation.

The patient is still alive and working normally without recurrence.

Case 2 (Figure 7): A 52-year-old man had HBV infection for more than 15 years. The CT scan showed a 6





**Figure 8 Case 3.** A: The computed tomography scan showed the left hepatocellular carcinoma (HCC) and tumor thrombus in the left portal vein (LPV) and portal vein (PV). B and C: 3D reconstruction of the left HCC. D: 3D reconstruction of tumor thrombus in the LPV and PV. PVTT: Portal vein tumor thrombus.

cm × 6 cm mass in the right liver, a 3 cm × 3 cm tumor thrombus in the right branch of the portal vein, and two tumors approximately 0.9 cm × 1.0 cm and thrombus in the left branch. The liver function was Class A according to Child-Pugh classification. The “thrombectomy first” approach plus right hemihepatectomy was performed in August 2009. The patient recovered without any complications and was treated with TACE twice postoperatively. The patient is still alive and working normally without recurrence.

Case 3 (Figure 8): A 50-year-old man had HBV infection for more than 10 years. The CT scan showed a huge mass in the left liver larger than 20 cm × 16 cm, and tumor thrombus was found in the left branch of the portal vein and the main portal vein. The liver function was Child-Pugh Class A. The “thrombectomy first” approach plus left hemihepatectomy was performed in December 2013. The patient received anti-HBV treatment and TACE once after the operation. He is still alive without recurrence.

We usually classify PVTT as follows: (1) Segmental PVTT (thrombus confined in a segment); (2) Lobar PVTT (thrombus confined in the right/left lobe), which is then subdivided into R lobar and L lobar; (3) Main PVTT (thrombus extending to main trunk portal vein), which is then subdivided into R Main PVTT and L Main PVTT; (4) R + M PVTT (Right PVTT extending to both main trunk and left portal vein); and (5) L + M PVTT (Left PVTT extending to both main trunk and right portal vein). Accordingly, case one belongs to R Main PVTT; case two belongs to R + Main PVTT; case three belongs to L Main PVTT. Our classification seems more helpful for determining the method of surgical intervention when compared with other classifications. It is simpler and easier to remember, and thus, more practical for clinical

use.

## CONCLUSION

HCC with PVTT is not a surgical contraindication, and the accumulation of experience and development of technology favor surgical treatments. Treatment guidelines led by China and Japan have confirmed the therapeutic effects of surgical treatment in Type I/II, but the benefit of surgical treatment for Type III/IV is still controversial. Through our experience, we have found that the appropriate surgical approach, especially the new “thrombectomy first” method, would remarkably improve the survival outcomes in patients with Cheng’s III/IV PVTT.

## ACKNOWLEDGMENTS

Many thanks to Yuan-Quan Yu, Yun Jin, Guo-Jun Chen and Xiao-Long Liu for their help collecting the data for the three cases.

## REFERENCES

- 1 Llovet JM, Bustamante J, Castells A, Vilana R, Ayuso Mdel C, Sala M, Brú C, Rodés J, Bruix J. Natural history of untreated nonsurgical hepatocellular carcinoma: rationale for the design and evaluation of therapeutic trials. *Hepatology* 1999; **29**: 62-67 [PMID: 9862851 DOI: 10.1002/hep.510290145]
- 2 Forner A, Llovet JM, Bruix J. Hepatocellular carcinoma. *Lancet* 2012; **379**: 1245-1255 [PMID: 22353262 DOI: 10.1016/S0140-6736(11)61347-0]
- 3 Llovet JM, Ricci S, Mazzaferro V, Hilgard P, Gane E, Blanc JF, de Oliveira AC, Santoro A, Raoul JL, Forner A, Schwartz M, Porta C, Zeuzem S, Bolondi L, Greten TF, Galle PR, Seitz JF, Borbath I, Häussinger D, Giannaris T, Shan M, Moscovici M, Voliotis D, Bruix J; SHARP Investigators Study Group. Sorafenib in advanced hepatocellular carcinoma. *N Engl J Med* 2008; **359**: 378-390 [PMID: 18650514 DOI: 10.1056/NEJMoa0708857]
- 4 Bruix J, Sherman M; American Association for the Study of Liver Diseases. Management of hepatocellular carcinoma: an update. *Hepatology* 2011; **53**: 1020-1022 [PMID: 21374666 DOI: 10.1002/hep.24199]
- 5 European Association For The Study Of The Liver. European Organisation For Research And Treatment Of Cancer. EASL-EORTC clinical practice guidelines: management of hepatocellular carcinoma. *J Hepatol* 2012; **56**: 908-943 [PMID: 22424438 DOI: 10.1016/j.jhep.2011.12.001]
- 6 Cheng S, Chen M, Cai J; National Research Cooperative Group for Diagnosis and Treatment of Hepatocellular Carcinoma with Tumor Thrombus. Chinese expert consensus on multidisciplinary diagnosis and treatment of hepatocellular carcinoma with portal vein tumor thrombus: 2016 edition. *Oncotarget* 2017; **8**: 8867-8876 [PMID: 27780939 DOI: 10.18632/oncotarget.12817]
- 7 Kudo M, Matsui O, Iijima H, Kadoya M, Imai Y, Okusaka T, Miyayama S, Tsuchiya K, Ueshima K, Hiraoka A, Ikeda M, Ogasawara S, Yamashita T, Minami T, Yamakado K; Liver Cancer Study Group of Japan. JSH Consensus-Based Clinical Practice Guidelines for the Management of Hepatocellular Carcinoma: 2014 Update by the Liver Cancer Study Group of Japan. *Liver Cancer* 2014; **3**: 458-468 [PMID: 26280007 DOI: 10.1159/000343875]
- 8 Ho MC, Hasegawa K, Chen XP, Nagano H, Lee YJ, Chau GY, Zhou J, Wang CC, Choi YR, Poon RT, Kokudo N. Surgery for Intermediate and Advanced Hepatocellular Carcinoma: A

- Consensus Report from the 5th Asia-Pacific Primary Liver Cancer Expert Meeting (APPLE 2014). *Liver Cancer* 2016; **5**: 245-256 [PMID: 27781197 DOI: 10.1159/000449336]
- 9 **Kokudo T**, Hasegawa K, Matsuyama Y, Takayama T, Izumi N, Kadoya M, Kudo M, Ku Y, Sakamoto M, Nakashima O, Kaneko S, Kokudo N; Liver Cancer Study Group of Japan. Survival benefit of liver resection for hepatocellular carcinoma associated with portal vein invasion. *J Hepatol* 2016; **65**: 938-943 [PMID: 27266618 DOI: 10.1016/j.jhep.2016.05.044]
  - 10 **Wang K**, Guo WX, Chen MS, Mao YL, Sun BC, Shi J, Zhang YJ, Meng Y, Yang YF, Cong WM, Wu MC, Lau WY, Cheng SQ. Multimodality Treatment for Hepatocellular Carcinoma With Portal Vein Tumor Thrombus: A Large-Scale, Multicenter, Propensity Matching Score Analysis. *Medicine (Baltimore)* 2016; **95**: e3015 [PMID: 26986115 DOI: 10.1097/MD.0000000000003015]
  - 11 **Kojima H**, Hatano E, Taura K, Seo S, Yasuchika K, Uemoto S. Hepatic Resection for Hepatocellular Carcinoma with Tumor Thrombus in the Major Portal Vein. *Dig Surg* 2015; **32**: 413-420 [PMID: 26316188 DOI: 10.1159/000437375]
  - 12 **Shi J**, Lai EC, Li N, Guo WX, Xue J, Lau WY, Wu MC, Cheng SQ. Surgical treatment of hepatocellular carcinoma with portal vein tumor thrombus. *Ann Surg Oncol* 2010; **17**: 2073-2080 [PMID: 20131013 DOI: 10.1245/s10434-010-0940-4]
  - 13 **Chen XP**, Qiu FZ, Wu ZD, Zhang ZW, Huang ZY, Chen YF, Zhang BX, He SQ, Zhang WG. Effects of location and extension of portal vein tumor thrombus on long-term outcomes of surgical treatment for hepatocellular carcinoma. *Ann Surg Oncol* 2006; **13**: 940-946 [PMID: 16788755 DOI: 10.1245/ASO.2006.08.007]
  - 14 **Minagawa M**, Makuuchi M. Treatment of hepatocellular carcinoma accompanied by portal vein tumor thrombus. *World J Gastroenterol* 2006; **12**: 7561-7567 [PMID: 17171782 DOI: 10.3748/wjg.v12.i47.7561]
  - 15 **Peng ZW**, Guo RP, Zhang YJ, Lin XJ, Chen MS, Lau WY. Hepatic resection versus transcatheter arterial chemoembolization for the treatment of hepatocellular carcinoma with portal vein tumor thrombus. *Cancer* 2012; **118**: 4725-4736 [PMID: 22359112 DOI: 10.1002/cncr.26561]
  - 16 **Xue TC**, Xie XY, Zhang L, Yin X, Zhang BH, Ren ZG. Transarterial chemoembolization for hepatocellular carcinoma with portal vein tumor thrombus: a meta-analysis. *BMC Gastroenterol* 2013; **13**: 60 [PMID: 23566041 DOI: 10.1186/1471-230X-13-60]
  - 17 **Liu PH**, Lee YH, Hsia CY, Hsu CY, Huang YH, Chiou YY, Lin HC, Huo TI. Surgical resection versus transarterial chemoembolization for hepatocellular carcinoma with portal vein tumor thrombosis: a propensity score analysis. *Ann Surg Oncol* 2014; **21**: 1825-1833 [PMID: 24499831 DOI: 10.1245/s10434-014-3510-3]
  - 18 **Yamamoto Y**, Ikoma H, Morimura R, Shoda K, Konishi H, Murayama Y, Komatsu S, Shiozaki A, Kuriu Y, Kubota T, Nakanishi M, Ichikawa D, Fujiwara H, Okamoto K, Sakakura C, Ochiai T, Otsuji E. Post-hepatectomy survival in advanced hepatocellular carcinoma with portal vein tumor thrombosis. *World J Gastroenterol* 2015; **21**: 246-253 [PMID: 25574098 DOI: 10.3748/wjg.v21.i1.246]
  - 19 **Ban D**, Shimada K, Yamamoto Y, Nara S, Esaki M, Sakamoto Y, Kosuge T. Efficacy of a hepatectomy and a tumor thrombectomy for hepatocellular carcinoma with tumor thrombus extending to the main portal vein. *J Gastrointest Surg* 2009; **13**: 1921-1928 [PMID: 19727969 DOI: 10.1007/s11605-009-0998-0]
  - 20 **Cheng AL**, Kang YK, Chen Z, Tsao CJ, Qin S, Kim JS, Luo R, Feng J, Ye S, Yang TS, Xu J, Sun Y, Liang H, Liu J, Wang J, Tak WY, Pan H, Burock K, Zou J, Voliotis D, Guan Z. Efficacy and safety of sorafenib in patients in the Asia-Pacific region with advanced hepatocellular carcinoma: a phase III randomised, double-blind, placebo-controlled trial. *Lancet Oncol* 2009; **10**: 25-34 [PMID: 19095497 DOI: 10.1016/S1470-2045(08)70285-7]
  - 21 **Jeong SW**, Jang JY, Shim KY, Lee SH, Kim SG, Cha SW, Kim YS, Cho YD, Kim HS, Kim BS, Kim KH, Kim JH. Practical effect of sorafenib monotherapy on advanced hepatocellular carcinoma and portal vein tumor thrombosis. *Gut Liver* 2013; **7**: 696-703 [PMID: 24312711 DOI: 10.5009/gnl.2013.7.6.696]
  - 22 **Nakazawa T**, Hidaka H, Shibuya A, Okuwaki Y, Tanaka Y, Takada J, Minamino T, Watanabe M, Kokubu S, Koizumi W. Overall survival in response to sorafenib versus radiotherapy in unresectable hepatocellular carcinoma with major portal vein tumor thrombosis: propensity score analysis. *BMC Gastroenterol* 2014; **14**: 84 [PMID: 24886354 DOI: 10.1186/1471-230X-14-84]
  - 23 **Ikai I**, Yamamoto Y, Yamamoto N, Terajima H, Hatano E, Shimahara Y, Yamaoka Y. Results of hepatic resection for hepatocellular carcinoma invading major portal and/or hepatic veins. *Surg Oncol Clin N Am* 2003; **12**: 65-75, ix [PMID: 12735130 DOI: 10.1016/S1055-3207(02)00082-0]
  - 24 **Kudo M**, Izumi N, Kokudo N, Matsui O, Sakamoto M, Nakashima O, Kojiro M, Makuuchi M; HCC Expert Panel of Japan Society of Hepatology. Management of hepatocellular carcinoma in Japan: Consensus-Based Clinical Practice Guidelines proposed by the Japan Society of Hepatology (JSH) 2010 updated version. *Dig Dis* 2011; **29**: 339-364 [PMID: 21829027 DOI: 10.1159/000327577]
  - 25 **Shi J**, Lai EC, Li N, Guo WX, Xue J, Lau WY, Wu MC, Cheng SQ. A new classification for hepatocellular carcinoma with portal vein tumor thrombus. *J Hepatobiliary Pancreat Sci* 2011; **18**: 74-80 [PMID: 20686792 DOI: 10.1007/s00534-010-0314-0]
  - 26 **Chok KS**, Cheung TT, Chan SC, Poon RT, Fan ST, Lo CM. Surgical outcomes in hepatocellular carcinoma patients with portal vein tumor thrombosis. *World J Surg* 2014; **38**: 490-496 [PMID: 24132826 DOI: 10.1007/s00268-013-2290-4]
  - 27 **Shaohua L**, Qiaoxuan W, Peng S, Qing L, Zhongyuan Y, Ming S, Wei W, Rongping G. Surgical Strategy for Hepatocellular Carcinoma Patients with Portal/Hepatic Vein Tumor Thrombosis. *PLoS One* 2015; **10**: e0130021 [PMID: 26076461 DOI: 10.1371/journal.pone.0130021]
  - 28 **Wu CC**, Hsieh SR, Chen JT, Ho WL, Lin MC, Yeh DC, Liu TJ, P'eng FK. An appraisal of liver and portal vein resection for hepatocellular carcinoma with tumor thrombi extending to portal bifurcation. *Arch Surg* 2000; **135**: 1273-1279 [PMID: 11074879 DOI: 10.1001/archsurg.135.11.1273]

**P- Reviewer:** Tomizawa M   **S- Editor:** Ma RY   **L- Editor:** Wang TQ  
**E- Editor:** Yin SY







Published by **Baishideng Publishing Group Inc**  
7901 Stoneridge Drive, Suite 501, Pleasanton, CA 94588, USA  
Telephone: +1-925-223-8242  
Fax: +1-925-223-8243  
E-mail: [bpgoffice@wjgnet.com](mailto:bpgoffice@wjgnet.com)  
Help Desk: <http://www.f6publishing.com/helpdesk>  
<http://www.wjgnet.com>



ISSN 1007-9327

