

# World Journal of *Nephrology*

*World J Nephrol* 2018 November 24; 7(7): 129-147





### MINIREVIEWS

- 129 Confounding risk factors and preventative measures driving nephrolithiasis global makeup  
*Shin S, Srivastava A, Alli NA, Bandyopadhyay BC*

### CASE REPORT

- 143 Awakening the sleeping kidney in a dialysis-dependent patient with fibromuscular dysplasia: A case report and review of literature  
*Chothia MY, Davids MR, Bhikoo R*

**ABOUT COVER**

Editorial Board Member of *World Journal of Nephrology*, Rajesh Kumar, MD, Associate Professor, Division of Molecular Cardiology, College of Medicine, Texas A and M Health Science Center, Temple, TX 76504, United States

**AIM AND SCOPE**

*World Journal of Nephrology* (*World J Nephrol*, *WJN*, online ISSN 2220-6124, DOI: 10.5527) is a peer-reviewed open access academic journal that aims to guide clinical practice and improve diagnostic and therapeutic skills of clinicians.

*WJN* covers topics concerning kidney development, renal regeneration, kidney tumors, therapy of renal disease, hemodialysis, peritoneal dialysis, kidney transplantation, diagnostic imaging, evidence-based medicine, epidemiology and nursing. Priority publication will be given to articles concerning diagnosis and treatment of nephrology diseases. The following aspects are covered: Clinical diagnosis, laboratory diagnosis, differential diagnosis, imaging tests, pathological diagnosis, molecular biological diagnosis, immunological diagnosis, genetic diagnosis, functional diagnostics, and physical diagnosis; and comprehensive therapy, drug therapy, surgical therapy, interventional treatment, minimally invasive therapy, and robot-assisted therapy.

We encourage authors to submit their manuscripts to *WJN*. We will give priority to manuscripts that are supported by major national and international foundations and those that are of great basic and clinical significance.

**INDEXING/ABSTRACTING**

*World Journal of Nephrology* (*WJN*) is now abstracted and indexed in PubMed, PubMed Central, China National Knowledge Infrastructure (CNKI), and Superstar Journals Database.

**EDITORS FOR THIS ISSUE**

Responsible Assistant Editor: *Xiang Li*  
Responsible Electronic Editor: *Yun-Xiao Jian Wu*  
Proofing Editor-in-Chief: *Lian-Sheng Ma*

Responsible Science Editor: *Fan-Fan Ji*  
Proofing Editorial Office Director: *Jin-Lei Wang*

**NAME OF JOURNAL**  
*World Journal of Nephrology*

**ISSN**  
ISSN 2220-6124 (online)

**LAUNCH DATE**  
February 6, 2012

**FREQUENCY**  
Continuous

**EDITORIAL BOARD MEMBERS**  
All editorial board members resources online at <http://www.wjnet.com/2220-6124/editorialboard.htm>

**EDITORIAL OFFICE**  
Jin-Lei Wang, Director  
*World Journal of Nephrology*  
Baishideng Publishing Group Inc

7901 Stoneridge Drive,  
Suite 501, Pleasanton, CA 94588, USA  
Telephone: +1-925-2238242  
Fax: +1-925-2238243  
E-mail: [editorialoffice@wjnet.com](mailto:editorialoffice@wjnet.com)  
Help Desk: <http://www.f6publishing.com/helpdesk>  
<http://www.wjnet.com>

**PUBLISHER**  
Baishideng Publishing Group Inc  
7901 Stoneridge Drive,  
Suite 501, Pleasanton, CA 94588, USA  
Telephone: +1-925-2238242  
Fax: +1-925-2238243  
E-mail: [bpgoffice@wjnet.com](mailto:bpgoffice@wjnet.com)  
Help Desk: <http://www.f6publishing.com/helpdesk>  
<http://www.wjnet.com>

**PUBLICATION DATE**  
November 24, 2018

**COPYRIGHT**  
© 2018 Baishideng Publishing Group Inc. Articles published by this Open-Access journal are distributed under the terms of the Creative Commons Attribution Non-commercial License, which permits use, distribution, and reproduction in any medium, provided the original work is properly cited, the use is non commercial and is otherwise in compliance with the license.

**SPECIAL STATEMENT**  
All articles published in journals owned by the Baishideng Publishing Group (BPG) represent the views and opinions of their authors, and not the views, opinions or policies of the BPG, except where otherwise explicitly indicated.

**INSTRUCTIONS TO AUTHORS**  
<http://www.wjnet.com/bpg/gerinfo/204>

**ONLINE SUBMISSION**  
<http://www.f6publishing.com>

## Awakening the sleeping kidney in a dialysis-dependent patient with fibromuscular dysplasia: A case report and review of literature

Mogamat-Yazied Chothia, Mogamat Razeen Davids, Raisa Bhikoo

Mogamat-Yazied Chothia, Renal Unit, Tygerberg Hospital, Cape Town 7505, South Africa

Mogamat-Yazied Chothia, Mogamat Razeen Davids, Raisa Bhikoo, Division of Nephrology, Department of Medicine, Tygerberg Hospital and Stellenbosch University, Cape Town 7505, South Africa

ORCID number: Mogamat-Yazied Chothia (0000-0002-9801-1300); Mogamat Razeen Davids (0000-0003-4900-0231); Raisa Bhikoo (0000-0002-9913-8792).

**Author contributions:** Chothia MY and Davids MR were involved in the care of the patient; all of the authors contributed to writing of the paper and review of the final manuscript.

**Informed consent statement:** The patient provided consent for publication of this case report and its accompanying images.

**Conflict-of-interest statement:** The authors declare that they have no conflicts of interest.

**CARE Checklist (2013) statement:** The authors have read the CARE Checklist (2013), and the manuscript was prepared and revised according to the CARE Checklist (2013).

**Open-Access:** This article is an open-access article which was selected by an in-house editor and fully peer-reviewed by external reviewers. It is distributed in accordance with the Creative Commons Attribution Non Commercial (CC BY-NC 4.0) license, which permits others to distribute, remix, adapt, build upon this work non-commercially, and license their derivative works on different terms, provided the original work is properly cited and the use is non-commercial. See: <http://creativecommons.org/licenses/by-nc/4.0/>

**Manuscript source:** Unsolicited manuscript

Corresponding author to: Mogamat-Yazied Chothia, MD, Senior Lecturer, Renal Unit, Tygerberg Hospital, Francie van Zijl Drive, Parow Valley, Cape Town 7505, South Africa. [yaziedc@sun.ac.za](mailto:yaziedc@sun.ac.za)  
Telephone: +27-21-9386590

Fax: +27-21-9385555

Received: August 15, 2018

Peer-review started: August 17, 2018

First decision: August 31, 2018

Revised: September 6, 2018

Accepted: October 10, 2018

Article in press: October 10, 2018

Published online: November 24, 2018

### Abstract

Renal artery stenosis is a common cause of secondary hypertension and chronic kidney disease. We present here a case of fibromuscular dysplasia that was treated with surgical revascularization, resulting in recovery of kidney function with eventual cessation of chronic dialysis. The case involves a 25-year-old female with coincidentally discovered hypertension, who underwent further investigations revealing a diagnosis of renal artery stenosis due to fibromuscular dysplasia. She subsequently developed two episodes of malignant hypertension, with flash pulmonary oedema and worsening renal failure that resulted in dialysis dependence. After evidence was obtained that the right kidney was still viable, a revascularization procedure was performed, improving blood pressure control and restoring kidney function, thereby allowing dialysis to be stopped. This case highlights the importance of evaluating patients with renal artery stenosis for revascularization before committing them to a life of chronic dialysis.

**Key words:** Renal artery stenosis; Fibromuscular dysplasia; Revascularisation; Dialysis; Caes report

© The Author(s) 2018. Published by Baishideng Publishing Group Inc. All rights reserved.

**Core tip:** Renal failure requiring dialysis support is a rare complication of renal artery stenosis due to fibromuscular dysplasia. We present a 25-year-old woman with fibromuscular dysplasia who developed dialysis dependence following acute loss of kidney function after suspected renal arterial dissection. Surgical revascularization resulted in dialysis cessation and improved blood pressure control. This case illustrates that in well-selected dialysis-dependent patients with renal artery stenosis secondary to fibromuscular dysplasia, surgical revascularization may not only improve the control of blood pressure but also restore enough kidney function for dialysis cessation.

Chothia MY, Davids MR, Bhikoo R. Awakening the sleeping kidney in a dialysis-dependent patient with fibromuscular dysplasia: A case report and review of literature. *World J Nephrol* 2018; 7(7): 143-147 Available from: URL: <http://www.wjgnet.com/2220-6124/full/v7/i7/143.htm> DOI: <http://dx.doi.org/10.5527/wjn.v7.i7.143>

## INTRODUCTION

Renal artery stenosis (RAS) is a common cause of secondary hypertension and chronic kidney disease. The most common cause of RAS is atherosclerosis, while fibromuscular dysplasia (FMD) is regarded as a rare aetiology. The latter is regarded as a non-atherosclerotic, non-inflammatory vascular disease, most frequently affecting the renal arteries (60%-75%) followed by the carotid arteries (25%-30%); however, many other vascular beds have been described<sup>[1]</sup>.

The pathological classification of FMD is based on the arterial layer primarily affected. The most common pathological type is medial fibroplasia, which has a characteristic "string-of-beads" appearance on renal angiography. The cause of FMD remains unknown but may have a genetic component since the disease tends to affect first-degree relatives of affected individuals<sup>[2]</sup>. The disease is frequently asymptomatic and may only be identified coincidentally. Studies have reported that FMD represents < 10% of cases of renovascular hypertension<sup>[3]</sup>. Even more uncommon is renal failure due to FMD, despite studies reporting that up to 63% of patients have loss of kidney volume<sup>[4]</sup>.

We present herein a case of FMD that resulted in severe dialysis-dependent renal failure, where there was recovery of kidney function following revascularization and eventual cessation of chronic dialysis.

## CASE REPORT

A 25-year-old female was seen in August 2015 at our medical outpatient clinic after hypertension was diagnosed following surgery for a distal tibia-fibula fracture. During hospitalisation, the patient's systolic and diastolic blood pressure (BP) was noted to be in the range of

180-225 mmHg and 110-130 mmHg, respectively, despite anti-hypertensive therapy that included hydrochlorothiazide 25 mg daily and amlodipine 10 mg daily.

The patient showed no symptoms related to her hypertension. On clinical examination, she had a normal body habitus with a body mass index of 23 kg/m<sup>2</sup> and no syndromic features for an endocrine cause of hypertension. All pulses were palpable and equal in volume, with no radio-femoral delay. There were no differences in BP between the right and left upper limbs, or between the upper and lower limbs. No renal or carotid arterial bruits were audible. There was a prominent, pressure-loaded apical impulse. Her serum creatinine concentration was 67 µmol/L.

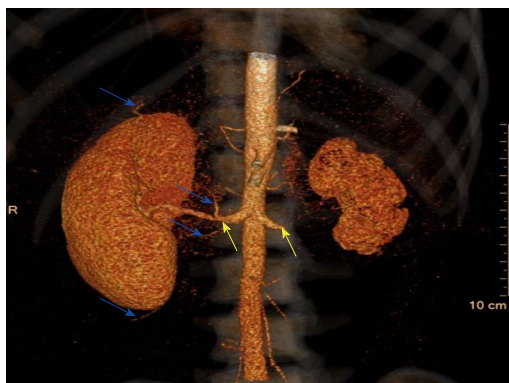Since parenchymal kidney disease and renovascular disease are the two most common causes of secondary hypertension, a radiological examination of these systems was performed. Ultrasound measurements of the patient's left and right kidney showed a discrepancy in sizes of 72 mm and 117 mm, respectively. Resistive index could not be determined for the left kidney, due to very poor perfusion; however, the right kidney had normal perfusion, with a resistive index of 60%. Computed tomography angiography (CTA) revealed normal cortico-medullary enhancement in the right kidney, while the left kidney had cortical infarcts and fibrous tissue that encased the left renal artery, originating approximately 8 mm from the ostium up to the level of the renal hilum with near-complete occlusion. The right renal artery had nearly 50% stenosis that originated 17 mm from the ostium. The rest of the aorta and its branches were otherwise normal in configuration.

A diagnosis of FMD was made, since the CTA was most consistent with this condition (as opposed to Takayasu's arteritis). The lumina of the aorta and its branches were not narrowed and had a smooth wall, and no post-stenotic dilatations were noted. Also, the origins of the stenosis in the renal arteries were not at the ostia but rather at the mid-vessel level.

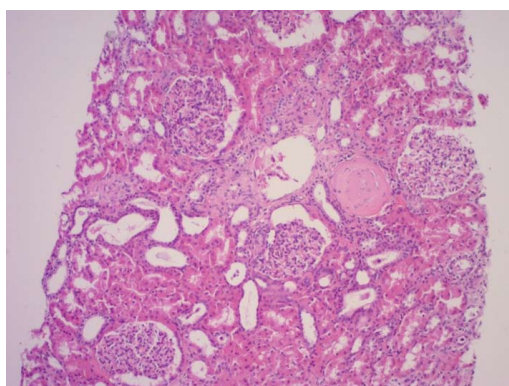
During this time, the patient's serum creatinine had increased slightly to 87 µmol/L and she developed resistant hypertension. Her antihypertensive regimen included atenolol at 50 mg daily, furosemide at 160 mg daily, amlodipine at 10 mg daily and minoxidil 5 mg daily. Antagonists of the renin-angiotensin system were avoided due to the concern of effects that this class of drugs may have on renal function.

In January 2016, the patient presented with malignant hypertension, flash pulmonary oedema and a serum creatinine level that had risen to 1807 µmol/L. Despite this, her urine volumes ranged from 700 mL to 1000 mL daily. Repeat ultrasound showed that the right kidney size was now 92 mm and that the resistive index had increased to 70%. A diuresis renogram revealed a differential function of 80% in the right kidney and 20% in the left, with poor global function. The patient was initiated on haemodialysis and her serum creatinine improved to 650 µmol/L. Dialysis was stopped. However, 3 wk later, she re-presented with a second episode

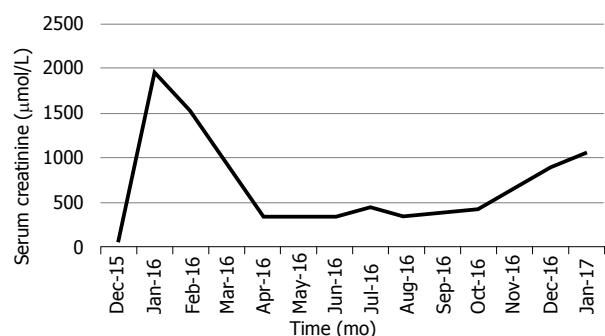




**Figure 1** Three-dimensional computed tomography reconstruction. Extensive collateral blood supply to the right kidney (blue arrows) and origins of the renal arterial stenosis (yellow arrows) are shown.



**Figure 2** Results of the kidney biopsy. Normal appearing tissue (haematoxylin and eosin stain, at 100 × high power field magnification).



**Figure 3** The patient's serum creatinine levels over time.

of malignant hypertension and flash pulmonary oedema and her serum creatinine had again increased to 1509 μmol/L. Haemodialysis was then re-initiated.

Notably, the patient's urine volumes throughout this entire period remained at nearly 1000 mL daily, which was an indication of ongoing right kidney perfusion, possibly *via* collateral blood vessels. This was confirmed on a repeat CTA (Figure 1). A kidney biopsy of the right kidney was performed and revealed viable, normal-appearing tissue (Figure 2).

Due to the abrupt loss of kidney function, arterial

dissection and/or thrombosis involving the right renal artery was suspected. Because of limited experience with the endovascular treatment of complicated renal arterial lesions at our centre, a decision was made to attempt primary surgical revascularization. Due to the negligible contribution to overall kidney function, no interventions were planned for the left kidney.

In April 2016, the patient underwent *ex vivo* reconstruction of the right renal artery using a saphenous venous graft from the left leg. A long segment of arterial dissection up to the branch vessels was identified. The occluded arterial segment was resected, and the venous graft was interposed with end-to-side anastomoses. Post-operative Doppler ultrasound showed that the kidney size had increased to 132 mm and excellent renal perfusion was noted.

Approximately 1 wk post-operatively, the patient complained of right flank pain. An ultrasound examination revealed a right perinephric haematoma and suspected kinking of the ureter, causing hydronephrosis. A pigtail catheter was placed to drain the haematoma, and a double-J-stent was inserted to relieve the obstruction. There was a dramatic improvement of both kidney function and BP control. Haemodialysis was tapered and eventually discontinued. Her serum creatinine settled at 350 μmol/L, nearly 2 mo following surgery. BP control was achieved with a single agent. The patient remained dialysis-free for 9 mo before her chronic kidney disease progressed and she eventually returned to chronic dialysis (Figure 3).

## DISCUSSION

The "sleeping" kidney is a term used to describe a non-functioning but viable kidney, usually due to RAS. Most of the reported cases have involved those with atherosclerotic RAS, with fewer cases involving FMD.

The main blood supply to the kidneys is *via* the renal arteries; however, they also have a rich collateral blood supply. These pre-formed collateral vessels originate from branches of the renal capsular, peri-pelvic and peri-ureteric systems<sup>[5]</sup>. We suspect that our patient must have had an extensive collateral blood supply to the right kidney since she maintained good urine volumes of up to 1000 mL per day despite the demonstration on CTA of extremely poor perfusion *via* the main right renal artery.

Renal arterial dissection may cause renal infarction and subsequent chronic kidney disease; however, FMD as a cause of chronic kidney disease is very uncommon and cases that progress to end-stage kidney disease are rare<sup>[6,7]</sup>. A large registry of FMD patients showed that out of a total of 447 vascular events, 4.3% of patients had renal arterial dissection and that only 1.6% and 0.9% of patients had renal failure and renal infarction, respectively<sup>[7]</sup>. In our case, renal arterial dissection and/or thrombosis was suspected as a cause of acute kidney injury due to the unexplained, abrupt loss of kidney

function.

The indications for renal revascularization, as recommended by the American Heart Association (commonly known as the AHA), include resistant hypertension, new-onset hypertension, branch disease, dissection and aneurysm, and the preservation of kidney function<sup>[7]</sup>. Regarding the latter, the AHA recommends revascularization when there is progressive decline in kidney function and/or reduction in kidney mass. We decided to offer our patient a revascularization procedure because she had resistant hypertension that was complicated by episodes of malignant hypertension and flash pulmonary oedema. Also, the on-going urine production despite the negligible perfusion seen on radioisotope renogram and CTA suggested a potentially viable right kidney.

There are no guidelines regarding revascularization of RAS in dialysis-dependent patients. A study that investigated 15 hypertensive patients with non-functioning kidneys due to either complete or segmental renal arterial occlusion found that the presence of viable glomeruli on kidney biopsy, angiographic evidence of collateral blood supply, and the presence of a patent distal renal artery were associated with successful revascularization and salvage of non-functioning kidneys<sup>[8]</sup>. In addition, others have recommended kidney length of at least 90 mm and renal vein renin sampling as an additional measure of nephron viability<sup>[9-11]</sup>. Our case demonstrated three of these criteria: the right kidney size being 92 mm; detection of collateral perfusion on CTA as well as on Doppler ultrasound; and, kidney biopsy showing normal glomeruli without tubular atrophy or significant interstitial fibrosis.

Guidelines recommend percutaneous transluminal angioplasty (PTA) as the primary revascularization procedure for renal FMD, with surgery as a secondary procedure if PTA is unsuccessful<sup>[7]</sup>. However, these studies predominantly focussed on the effect of PTA on the rates of hypertension cure and/or control. Evidence for PTA to restore or preserve renal function is less robust, with many studies, albeit their representing a small number, reporting unclear outcomes with none of the patients established on dialysis<sup>[12-18]</sup>. One study demonstrated that 12 of 14 patients had improved renal function following PTA, with a mean serum creatinine concentration of 212  $\mu\text{mol/L}$  at baseline that improved to 150  $\mu\text{mol/L}$  after a mean follow-up period of 33 mo<sup>[19]</sup>. Again, none of these patients were dialysis-dependent. There have been few documented case reports of successful renal revascularization in dialysis-dependent patients. In a case of presumed FMD that was dialysis-dependent for 6 mo, the patient became dialysis-independent following surgical correction that involved a spleno-renal bypass procedure<sup>[20]</sup>.

In our case, the decision to surgically repair the right renal artery instead of attempting PTA was largely influenced by the abrupt loss of kidney function, which suggested arterial dissection and/or thrombosis. Also,

the lack of local experience with regards to renal arterial stenting was an additional factor that influenced our decision. Because our patient was dialysis-dependent and had a potentially salvageable solitary kidney, we believed that surgical repair would offer the greatest chance for successful revascularization.

The outcomes of revascularization in dialysis-dependent patients are not well known. In the case mentioned above, the patient remained dialysis-free for 17 mo, with a serum creatinine of 203  $\mu\text{mol/L}$ . In a study that included 6 patients with FMD and required a secondary revascularization procedure after a failed primary procedure, all cases were dialysis-free after an average follow-up of 58 mo<sup>[21]</sup>; however, none of those patients were dialysis-dependent prior to surgery. The initial indication for revascularization in all cases was for BP control rather than improvement of kidney function. Our patient had improvement of both hypertension as well as kidney function but eventually returned to dialysis after 9 mo.

In conclusion, the case presented herein illustrates that in well-selected dialysis-dependent patients with RAS, revascularization may not only improve BP control but also restore kidney function. Patients with RAS should be evaluated for revascularization before fully committing them to a life of chronic dialysis.

## ARTICLE HIGHLIGHTS

### Case characteristics

We report the case of a young woman with renal artery stenosis (RAS) due to fibromuscular dysplasia who became dialysis dependent following arterial dissection; after surgical revascularization, the patient was able to stop dialysis.

### Clinical diagnosis

Renal artery stenosis secondary to fibromuscular dysplasia complicated by arterial dissection and subsequent dialysis dependence.

### Differential diagnosis

Renal artery stenosis secondary to Takayasu's arteritis.

### Imaging diagnosis

Three-dimensional computed tomography reconstruction indicating a rich collateral renal blood supply and confirming the origins and extent of the renal artery stenosis.

### Pathological diagnosis

Kidney biopsy confirming viable tissue.

### Treatment

Surgical revascularization by *ex vivo* repair of the renal artery using a saphenous venous graft.

### Related reports

The paper by Libertino *et al* is important for readers to appreciate how to identify those patients that are likely to have a good response to revascularization.

### Term explanation

The "sleeping" kidney refers to a non-functional but potentially viable kidney that may recover function following revascularization.

**Experiences and lessons**

Patients with RAS should be evaluated for revascularisation before fully committing them to a life of chronic dialysis.

**REFERENCES**

- 1 **Slovut DP**, Olin JW. Fibromuscular dysplasia. *N Engl J Med* 2004; **350**: 1862-1871 [PMID: 15115832 DOI: 10.1056/NEJMra032393]
- 2 **Pannier-Moreau I**, Grimbert P, Fiquet-Kempf B, Vuagnat A, Jeunemaitre X, Corvol P, Plouin PF. Possible familial origin of multifocal renal artery fibromuscular dysplasia. *J Hypertens* 1997; **15**: 1797-1801 [PMID: 9488242 DOI: 10.1097/00004872-199715120-00092]
- 3 **Safian RD**, Textor SC. Renal-artery stenosis. *N Engl J Med* 2001; **344**: 431-442 [PMID: 11172181 DOI: 10.1056/NEJM200102083440607]
- 4 **Goncharenko V**, Gerlock AJ Jr, Shaff MI, Hollifield JW. Progression of renal artery fibromuscular dysplasia in 42 patients as seen on angiography. *Radiology* 1981; **139**: 45-51 [PMID: 7208940 DOI: 10.1148/radiology.139.1.7208940]
- 5 **Love L**, Bush IM. Early demonstration of renal collateral arterial supply. *Am J Roentgenol Radium Ther Nucl Med* 1968; **104**: 296-301 [PMID: 5685789 DOI: 10.2214/ajr.104.2.296]
- 6 **Kadian-Dodov D**, Gornik HL, Gu X, Froehlich J, Bacharach JM, Chi YW, Gray BH, Jaff MR, Kim ES, Mace P, Sharma A, Kline-Rogers E, White C, Olin JW. Dissection and Aneurysm in Patients With Fibromuscular Dysplasia: Findings From the U.S. Registry for FMD. *J Am Coll Cardiol* 2016; **68**: 176-185 [PMID: 27386771 DOI: 10.1016/j.jacc.2016.04.044]
- 7 **Olin JW**, Gornik HL, Bacharach JM, Biller J, Fine LJ, Gray BH, Gray WA, Gupta R, Hamburg NM, Katzen BT, Lookstein RA, Lumsden AB, Newburger JW, Rundek T, Sperati CJ, Stanley JC; American Heart Association Council on Peripheral Vascular Disease; American Heart Association Council on Clinical Cardiology; American Heart Association Council on Cardiopulmonary, Critical Care, Perioperative and Resuscitation; American Heart Association Council on Cardiovascular Disease in the Young; American Heart Association Council on Cardiovascular Radiology and Intervention; American Heart Association Council on Epidemiology and Prevention; American Heart Association Council on Functional Genomics and Translational Biology; American Heart Association Council for High Blood Pressure Research; American Heart Association Council on the Kidney in Cardiovascular Disease; American Heart Association Stroke Council. Fibromuscular dysplasia: state of the science and critical unanswered questions: a scientific statement from the American Heart Association. *Circulation* 2014; **129**: 1048-1078 [PMID: 24548843 DOI: 10.1161/01.cir.0000442577.96802.8c]
- 8 **Libertino JA**, Zinman L, Breslin DJ, Swinton NW Jr, Legg MA. Renal artery revascularization. Restoration of renal function. *JAMA* 1980; **244**: 1340-1342 [PMID: 7411806 DOI: 10.1001/jama.1980.03310120028017]
- 9 **Schefft P**, Novick AC, Stewart BH, Straffon RA. Renal revascularization in patients with total occlusion of the renal artery. *J Urol* 1980; **124**: 184-186 [PMID: 7401228 DOI: 10.1016/S0022-5347(17)55365-3]
- 10 **Lawrie GM**, Morris GC Jr, DeBaake ME. Long-term results of treatment of the totally occluded renal artery in forty patients with renovascular hypertension. *Surgery* 1980; **88**: 753-759 [PMID: 7444759]
- 11 **Whitehouse WM Jr**, Kazmers A, Zelenock GB, Erlandson EE, Cronenwett JL, Lindenauer SM, Stanley JC. Chronic total renal artery occlusion: effects of treatment on secondary hypertension and renal function. *Surgery* 1981; **89**: 753-763 [PMID: 7017988]
- 12 **Trinquart L**, Mounier-Vehier C, Sapoval M, Gagnon N, Plouin PF. Efficacy of revascularization for renal artery stenosis caused by fibromuscular dysplasia: a systematic review and meta-analysis. *Hypertension* 2010; **56**: 525-532 [PMID: 20625080 DOI: 10.1161/HYPERTENSIONAHA.110.152918]
- 13 **Millan VG**, McCauley J, Kopelman RI, Madias NE. Percutaneous transluminal renal angioplasty in nonatherosclerotic renovascular hypertension. Long-term results. *Hypertension* 1985; **7**: 668-674 [PMID: 3161823 DOI: 10.1161/01.HYP.7.5.668]
- 14 **Bell GM**, Reid J, Buist TA. Percutaneous transluminal angioplasty improves blood pressure and renal function in renovascular hypertension. *Q J Med* 1987; **63**: 393-403 [PMID: 2958895]
- 15 **Greminger P**, Steiner A, Schneider E, Kuhlmann U, Steurer J, Siegenthaler W, Vetter W. Cure and improvement of renovascular hypertension after percutaneous transluminal angioplasty of renal artery stenosis. *Nephron* 1989; **51**: 362-366 [PMID: 2521925 DOI: 10.1159/000185323]
- 16 **Bonelli FS**, McKusick MA, Textor SC, Kos PB, Stanson AW, Johnson CM, Sheedy PF 2nd, Welch TJ, Schirger A. Renal artery angioplasty: technical results and clinical outcome in 320 patients. *Mayo Clin Proc* 1995; **70**: 1041-1052 [PMID: 7475333 DOI: 10.4065/70.11.1041]
- 17 **Rodríguez Pérez JC**, Maynar Moliner M, Pérez Borges P, Plaza Toledano C, Reyes Pérez R, Pulido Duque JM, Palop Cubillo L, Rodríguez Pérez A. [The long-term results on arterial pressure and kidney function after the percutaneous transluminal dilatation of renal artery stenosis]. *Med Clin (Barc)* 1997; **108**: 366-372 [PMID: 9139142]
- 18 **Mounier-Vehier C**, Lions C, Jaboureck O, Devos P, Haulon S, Wibaux M, Carré A, Beregi JP. Parenchymal consequences of fibromuscular dysplasia renal artery stenosis. *Am J Kidney Dis* 2002; **40**: 1138-1145 [PMID: 12460031 DOI: 10.1053/ajkd.2002.36855]
- 19 **Tegtmeyer CJ**, Selby JB, Hartwell GD, Ayers C, Tegtmeyer V. Results and complications of angioplasty in fibromuscular disease. *Circulation* 1991; **83**: 1155-1161 [PMID: 1825043]
- 20 **Agraharkar M**, Nair V, Patlovany M. Recovery of renal function in dialysis patients. *BMC Nephrol* 2003; **4**: 9 [PMID: 14563216 DOI: 10.1186/1471-2369-4-9]
- 21 **Hansen KJ**, Deitch JS, Oskin TC, Ligush J Jr, Craven TE, Dean RH. Renal artery repair: consequence of operative failures. *Ann Surg* 1998; **227**: 678-689; discussion 689-690 [PMID: 9605659 DOI: 10.1097/0000658-199805000-00008]

**P- Reviewer:** Friedman EA, Mahmoud KM, Robles NR, Yong D

**S- Editor:** Ma RY **L- Editor:** A **E- Editor:** Wu YXJ







Published by **Baishideng Publishing Group Inc**  
7901 Stoneridge Drive, Pleasanton, CA 94588, USA  
Telephone: +1-925-223-8242  
Fax: +1-925-223-8243  
E-mail: [bpgoffice@wjgnet.com](mailto:bpgoffice@wjgnet.com)  
Help Desk: <http://www.f6publishing.com/helpdesk>  
<http://www.wjgnet.com>

