

World Journal of *Clinical Cases*

World J Clin Cases 2018 December 6; 6(15): 869-1072





REVIEW

- 869 Biomarkers in colorectal cancer: Current clinical utility and future perspectives
Vacante M, Borzi AM, Basile F, Biondi A
- 882 Inflammation and de-differentiation in pancreatic carcinogenesis
Seimiya T, Otsuka M, Iwata T, Tanaka E, Suzuki T, Sekiba K, Yamagami M, Ishibashi R, Koike K

MINIREVIEWS

- 892 Management of gastroesophageal reflux disease: Patient and physician communication challenges and shared decision making
Klenzak S, Danelisen I, Brannan GD, Holland MA, van Tilburg MA
- 901 Non-small bowel lesion detection at small bowel capsule endoscopy: A comprehensive literature review
Koffas A, Laskaratos FM, Epstein O

ORIGINAL ARTICLE

Case Control Study

- 908 Genetic associations of inflammatory bowel disease in a South Asian population
Niriella MA, Liyanage IK, Kodisinghe SK, De Silva AP, Rajapakshe N, Nanayakkara SD, Luke D, Silva T, Nawarathne M, Peiris RK, Kalubovila UP, Kumarasena SR, Dissanayake VH, Jayasekara RW, de Silva HJ
- 916 Clinical relevance of atrial septal aneurysm and patent foramen ovale with migraine
He L, Cheng GS, Du YJ, Zhang YS

Retrospective Study

- 922 Current trends of liver cirrhosis in Mexico: Similitudes and differences with other world regions
Méndez-Sánchez N, Zamarripa-Dorsey F, Panduro A, Purón-González E, Coronado-Alejandro EU, Cortez-Hernández CA, Higuera de la Tijera F, Pérez-Hernández JL, Cerda-Reyes E, Rodríguez-Hernández H, Cruz-Ramón VC, Ramírez-Pérez OL, Aguilar-Olivos NE, Rodríguez-Martínez OF, Cabrera-Palma S, Cabrera-Álvarez G
- 931 Retrograde intrarenal surgery vs miniaturized percutaneous nephrolithotomy to treat lower pole renal stones 1.5-2.5 cm in diameter
Li MM, Yang HM, Liu XM, Qi HG, Weng GB

Clinical Trials Study

- 936 Comparative study on operative trauma between microwave ablation and surgical treatment for papillary thyroid microcarcinoma

Xu B, Zhou NM, Cao WT, Gu SY

Observational Study

- 944 Association between functional abdominal pain disorders and asthma in adolescents: A cross-sectional study

Kumari MV, Devanarayana NM, Amarasiri L, Rajindrajith S

Prospective Study

- 952 Evaluating mucosal healing using colon capsule endoscopy predicts outcome in patients with ulcerative colitis in clinical remission

Takano R, Osawa S, Uotani T, Tani S, Ishida N, Tamura S, Yamade M, Iwaizumi M, Hamaya Y, Furuta T, Miyajima H, Sugimoto K

META-ANALYSIS

- 961 Probiotic Medilac-S® for the induction of clinical remission in a Chinese population with ulcerative colitis: A systematic review and meta-analysis

Sohail G, Xu X, Christman MC, Tompkins TA

- 985 Impact of body mass index on short-term outcomes of laparoscopic gastrectomy in Asian patients: A meta-analysis

Chen HK, Zhu GW, Huang YJ, Zheng W, Yang SG, Ye JX

- 995 Scoring systems for prediction of mortality in decompensated liver cirrhosis: A meta-analysis of test accuracy

Wu SL, Zheng YX, Tian ZW, Chen MS, Tan HZ

CASE REPORT

- 1007 Gangrenous cholecystitis: A silent but potential fatal disease in patients with diabetic neuropathy. A case report

Mehrzad M, Jehle CC, Roussel LO, Mehrzad R

- 1012 Successful endovascular treatment of endoscopically unmanageable hemorrhage from a duodenal ulcer fed by a renal artery: A case report

Anami S, Minamiguchi H, Shibata N, Koyama T, Sato H, Ikoma A, Nakai M, Yamagami T, Sonomura T

- 1018** Didactic surgical experience of thyroid metastasis from renal cell carcinoma: A case report
Yamauchi M, Kai K, Shibamiya N, Shimazu R, Monji M, Suzuki K, Kakinoki H, Tobu S, Kuratomi Y
- 1024** Gastric cancer with severe immune thrombocytopenia: A case report
Zhao ZW, Kang WM, Ma ZQ, Ye X, Yu JC
- 1029** Injury to the axillary artery and brachial plexus caused by a closed floating shoulder injury: A case report
Chen YC, Lian Z, Lin YN, Wang XJ, Yao GF
- 1036** Pancreatic panniculitis and solid pseudopapillary tumor of the pancreas: A case report
Zhang MY, Tian BL
- 1042** Intermittent abdominal pain accompanied by defecation difficulties caused by Chilaiditi syndrome: A case report
Luo XG, Wang J, Wang WL, Yu CZ
- 1047** Endoscopic titanium clip closure of gastric fistula after splenectomy: A case report
Yu J, Zhou CJ, Wang P, Wei SJ, He JS, Tang J
- 1053** Successful steroid treatment for acute fibrinous and organizing pneumonia: A case report
Ning YJ, Ding PS, Ke ZY, Zhang YB, Liu RY
- 1059** Sub-Tenon's urokinase injection-assisted vitrectomy in early treatment of suprachoroidal hemorrhage: Four cases report
Chai F, Ai H, Deng J, Zhao XQ
- 1067** Plexiform fibromyxoma of the small bowel: A case report
Zhang WG, Xu LB, Xiang YN, Duan CH

ABOUT COVER

Editorial Board Member of *World Journal of Clinical Cases*, Steven M Schwarz, MD, Professor, Department of Pediatrics, Children's Hospital at Downstate, SUNY-Downstate Medical Center, Brooklyn, NY 11203, United States

AIM AND SCOPE

World Journal of Clinical Cases (*World J Clin Cases*, *WJCC*, online ISSN 2307-8960, DOI: 10.12998) is a peer-reviewed open access academic journal that aims to guide clinical practice and improve diagnostic and therapeutic skills of clinicians.

The primary task of *WJCC* is to rapidly publish high-quality Autobiography, Case Report, Clinical Case Conference (Clinicopathological Conference), Clinical Management, Diagnostic Advances, Editorial, Field of Vision, Frontier, Medical Ethics, Original Articles, Clinical Practice, Meta-Analysis, Minireviews, Review, Therapeutics Advances, and Topic Highlight, in the fields of allergy, anesthesiology, cardiac medicine, clinical genetics, clinical neurology, critical care, dentistry, dermatology, emergency medicine, endocrinology, family medicine, gastroenterology and hepatology, geriatrics and gerontology, hematology, immunology, infectious diseases, internal medicine, obstetrics and gynecology, oncology, ophthalmology, orthopedics, otolaryngology, pathology, pediatrics, peripheral vascular disease, psychiatry, radiology, rehabilitation, respiratory medicine, rheumatology, surgery, toxicology, transplantation, and urology and nephrology.

INDEXING/ABSTRACTING

World Journal of Clinical Cases (*WJCC*) is now indexed in PubMed, PubMed Central, Science Citation Index Expanded (also known as SciSearch®), and Journal Citation Reports/Science Edition. The 2018 Edition of Journal Citation Reports cites the 2017 impact factor for *WJCC* as 1.931 (5-year impact factor: N/A), ranking *WJCC* as 60 among 154 journals in Medicine, General and Internal (quartile in category Q2).

EDITORS FOR THIS ISSUE

Responsible Assistant Editor: *Xiang Li*
Responsible Electronic Editor: *Wen-Wen Tan*
Proofing Editor-in-Chief: *Lian-Sheng Ma*

Responsible Science Editor: *Ying Dou*
Proofing Editorial Office Director: *Jin-Lei Wang*

NAME OF JOURNAL
World Journal of Clinical Cases

ISSN
ISSN 2307-8960 (online)

LAUNCH DATE
April 16, 2013

FREQUENCY
Semimonthly

EDITORS-IN-CHIEF
Sandro Vento, MD, Department of Internal Medicine, University of Botswana, Private Bag 00713, Gaborone, Botswana

EDITORIAL BOARD MEMBERS
All editorial board members resources online at <http://www.wjgnet.com/2307-8960/editorialboard.htm>

EDITORIAL OFFICE
Jin-Lei Wang, Director

World Journal of Clinical Cases
Baishideng Publishing Group Inc
7901 Stoneridge Drive, Suite 501, Pleasanton, CA 94588, USA
Telephone: +1-925-2238242
Fax: +1-925-2238243
E-mail: editorialoffice@wjgnet.com
Help Desk: <http://www.f6publishing.com/helpdesk>
<http://www.wjgnet.com>

PUBLISHER
Baishideng Publishing Group Inc
7901 Stoneridge Drive, Suite 501, Pleasanton, CA 94588, USA
Telephone: +1-925-2238242
Fax: +1-925-2238243
E-mail: bpgoffice@wjgnet.com
Help Desk: <http://www.f6publishing.com/helpdesk>
<http://www.wjgnet.com>

PUBLICATION DATE
December 6, 2018

COPYRIGHT

© 2018 Baishideng Publishing Group Inc. Articles published by this Open Access journal are distributed under the terms of the Creative Commons Attribution Non-commercial License, which permits use, distribution, and reproduction in any medium, provided the original work is properly cited, the use is non commercial and is otherwise in compliance with the license.

SPECIAL STATEMENT

All articles published in journals owned by the Baishideng Publishing Group (BPG) represent the views and opinions of their authors, and not the views, opinions or policies of the BPG, except where otherwise explicitly indicated.

INSTRUCTIONS TO AUTHORS

<http://www.wjgnet.com/bpg/gerinfo/204>

ONLINE SUBMISSION

<http://www.f6publishing.com>

Intermittent abdominal pain accompanied by defecation difficulties caused by Chilaiditi syndrome: A case report

Xia-Gang Luo, Jing Wang, Wu-Lin Wang, Chun-Zhao Yu

Xia-Gang Luo, Jing Wang, Wu-Lin Wang, Chun-Zhao Yu, Department of General Surgery, the Second Affiliated Hospital of Nanjing Medical University, Nanjing 210011, Jiangsu Province, China

ORCID number: Xia-Gang Luo (0000-0002-7674-7958); Jing Wang (0000-0001-8517-3469); Wu-Lin Wang (0000-0002-3177-3845); Chun-Zhao Yu (0000-0002-2485-9042).

Author contributions: Luo XG wrote the paper; Wang J, Wang WL collected the data and relevant images; Yu CZ revised the paper.

Supported by the National Natural Science Foundation of China, No. 30972910, 81172269; Jiangsu Provincial Commission of Health and Family Planning, No. Z201603; Science and Technology Development Fund of Nanjing Health and Family Planning Commission, No. YKK16233; Youth talent support program of Nanjing City during the 13th Five-Year Plan Period, No. QRX17107.

Informed consent statement: The patient was not required to give informed consent as the analysis included completely anonymous data; informed consent was obtained before any medical investigation or initiation of treatment as required.

Conflict-of-interest statement: The authors declare no conflict of interest.

CARE Checklist (2016) statement: The authors have read the CARE Checklist (2016), and the manuscript was prepared according to the CARE Checklist (2016).

Open-Access: This article is an open-access article which was selected by an in-house editor and fully peer-reviewed by external reviewers. It is distributed in accordance with the Creative Commons Attribution Non Commercial (CC BY-NC 4.0) license, which permits others to distribute, remix, adapt, build upon this work non-commercially, and license their derivative works on different terms, provided the original work is properly cited and the use is non-commercial. See: <http://creativecommons.org/licenses/by-nc/4.0/>

Manuscript source: Unsolicited manuscript

Corresponding author to: Chun-Zhao Yu, MD, PhD, Professor, Department of General Surgery, the Second Affiliated Hospital of Nanjing Medical University, No. 121 Jiangjiayuan Road, Nanjing 210011, Jiangsu Province, China. chunzhaoyu@njmu.edu.cn
Telephone: +86-25-58509832
Fax: +86-25-58509994

Received: September 12, 2018

Peer-review started: September 12, 2018

First decision: October 11, 2018

Revised: October 18, 2018

Accepted: October 22, 2018

Article in press: October 22, 2018

Published online: December 6, 2018

Abstract

We report a case of intermittent lower abdominal pain and distension accompanied by defecation difficulties for 3 years due to Chilaiditi syndrome in a 59-year-old male. Before admission to our hospital, the patient had undergone gastroscopy, which showed gastritis and duodenitis, and colonoscopy, which showed cecum deformation and cicatricial changes of the mucous membrane in the colon hepatic flexure. A computed tomography (CT) scan of the abdomen at our hospital confirmed right hepatic atrophy and interposition of the colon. Moreover, CT simulation endoscopy identified cystic dilatation in the colon hepatic flexure with the widest diameter of 8.2 cm. The patient was diagnosed with Chilaiditi syndrome. As the patient was unable to endure his defecation difficulties, he underwent a laparoscope-assisted right hemicolectomy. The patient had a good recovery. During the follow-up period of 9 mo, the patient remained symptom-free.

Key words: Abdominal pain; Diagnosis; Management; Laparoscope-assisted right hemicolectomy; Chilaiditi sign; Chilaiditi syndrome; Case report

© **The Author(s) 2018.** Published by Baishideng Publishing Group Inc. All rights reserved.

Core tip: We report a rare case of intermittent lower abdominal pain and distension accompanied by defecation difficulties due to Chilaiditi syndrome. The incidence of Chilaiditi syndrome is very low and is easily misdiagnosed. Imaging examination is an important diagnostic technique for Chilaiditi syndrome.

Luo XG, Wang J, Wang WL, Yu CZ. Intermittent abdominal pain accompanied by defecation difficulties caused by Chilaiditi syndrome: A case report. *World J Clin Cases* 2018; 6(15): 1042-1046 Available from: URL: <http://www.wjgnet.com/2307-8960/full/v6/i15/1042.htm> DOI: <http://dx.doi.org/10.12998/wjcc.v6.i15.1042>

INTRODUCTION

The Chilaiditi sign refers to the abnormal interposition of the colon or small bowel between the liver and right diaphragm, which was first observed in a clinical examination by Cantini in 1865. Subsequently, Demetrius Chilaiditi, a Greek radiologist, reported three cases of hepatodiaphragmatic interposition in 1910. Soon afterwards, this abnormal condition was named Chilaiditi sign. Chilaiditi sign always exists in individuals without clinical symptoms and is often an incidental finding through chest or abdominal radiography. If the Chilaiditi sign is associated with other respiratory and digestive symptoms such as abdominal pain, constipation, vomiting, respiratory distress, anorexia, volvulus, intestinal obstruction and perforation in a patient, the name is designated as Chilaiditi syndrome. The incidental finding at clinical imaging examination is rare, with an incidence of 0.025%-0.28%^[1], it is more prevalent in males than in females, with a ratio of 4:1, and the incidence rate increases with age^[2], especially in the elderly and the mentally ill^[3]. Chilaiditi sign and Chilaiditi syndrome are chronic but benign conditions. Due to the low incidence and lack of specificity in clinical manifestations, clinicians should pay careful attention while making diagnoses to avoid misdiagnosis and mistreatment.

Here, we report a rare case of a 59-year-old male who was initially diagnosed with colitis and constipation. The patient was finally diagnosed with Chilaiditi syndrome by computed tomography (CT) scan and underwent laparoscope-assisted right hemicolectomy.

CASE REPORT

A 59-year-old male patient was admitted to the De-

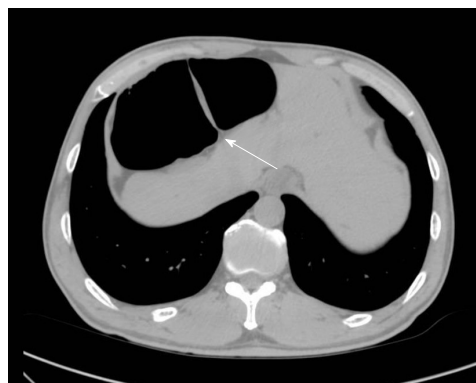

Figure 1 Computed tomography findings. Computed tomography shows an interposition of the colon hepatic flexure between the liver and the right diaphragm.

partment of General Surgery in the Second Affiliated Hospital of Nanjing Medical University (Nanjing, China) due to intermittent lower abdominal pain and distension accompanied by defecation difficulties for 3 years. These symptoms were initially relieved by laxatives but recently started to exacerbate. The patient denied nausea, vomiting, fever, melena and hematochezia. He had undergone several medical examinations including gastroscopy in another hospital, which showed gastritis and duodenitis. His colonoscopy showed cecum deformation and cicatricial changes of the mucous membrane in the colon hepatic flexure. The patient had never underwent surgery. There was nothing remarkable in his past medical and family histories. His vital signs were unremarkable. Upon physical examination, no obvious cardiovascular or respiratory system abnormalities were found. His abdomen was flat and soft. There were no signs of obvious pressure pain, rebound tenderness or abdominal mass. Murphy's sign was negative. Auscultation revealed normal bowel sounds. Blood, urine, stool, as well as liver and kidney function tests, coagulation studies, and electrocardiograms were all unremarkable. Chest X-rays revealed an abnormal gas shadow in the right subphrenic space and a segment of gaseous distended colon, which was interposed between the liver and the right diaphragm. A CT scan of the abdomen confirmed right hepatic atrophy and interposition of the colon (Figure 1). Further imaging by CT simulation endoscopy identified a cystic dilatation in the colon hepatic flexure, where the maximum diameter was 8.2 cm. There was no evidence of bowel wall thickening or bowel obstruction (Figure 2). These findings, together with the symptoms this patient was experiencing, indicated that the patient has Chilaiditi syndrome. There was no urgent indication for surgery. However, the patient was unable to endure his defecation difficulties and finally underwent laparoscope-assisted right hemicolectomy. Postoperative recovery was uneventful. He was discharged after 14 d of hospitalization with close follow-up. During a 4-wk follow-up period, he reported

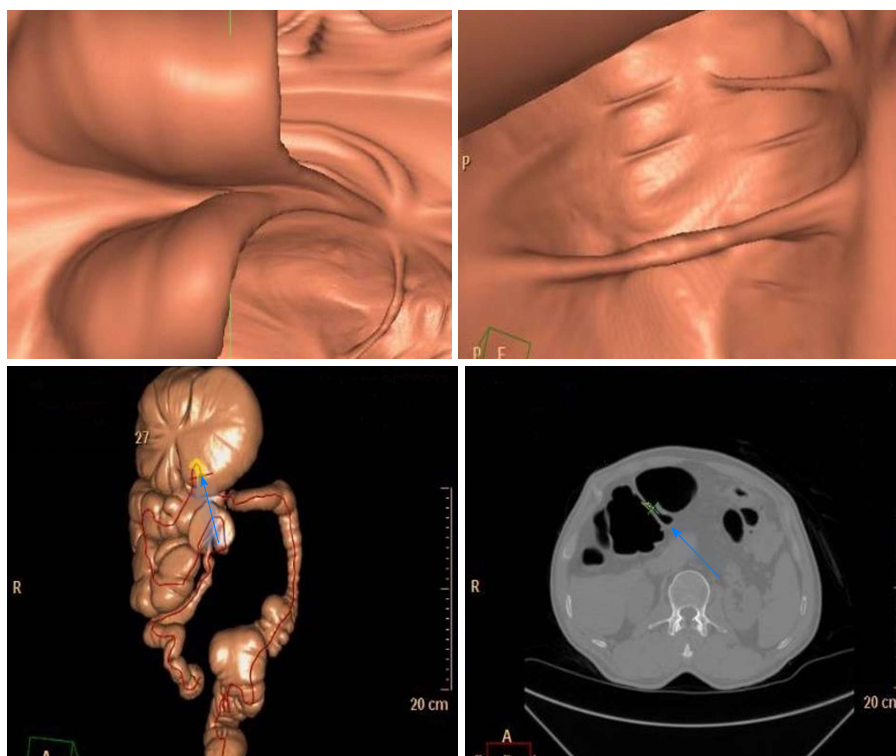


Figure 2 Computed tomography simulation endoscopy findings. Computed tomography simulation endoscopy identified a cystic dilatation in the colon hepatic flexure, which was intertwined between the liver and right diaphragm.

complete resolution of abdominal pain and distension. Moreover, defecation improved due to ameliorated regularity of bowel movements. During the subsequent 9-mo follow-up period, the patient remained symptom-free.

DISCUSSION

Normally, upper abdominal anatomy, including the suspensory ligament of the liver, mesocolon, liver, and the falciform ligament, can maintain a suitable space around the liver. Under normal physiological conditions, it is impossible for interposition of the colon or other organs to occur. The change of the relationship between the colon, the small intestine and the diaphragm is generally due to changes in anatomy. As a result, this change contributes to the occurrence of Chilaiditi syndrome. Under the Chilaiditi sign or Chilaiditi syndrome condition, the colon hepatic flexure, ascending colon, transverse colon, and small bowel, either alone or in combination with the colon, are the most common interposed organs.

The etiology of Chilaiditi syndrome remains controversial^[4] and multiple factors have been documented to contribute^[5]. Congenital disorders that can lead to Chilaiditi syndrome include small or ptotic liver, deficient falciform ligament, deficient suspensory ligament and congenital malposition or malrotation of the colon, and redundant colon. Furthermore, acquired disorders that can lead to Chilaiditi syndrome include cirrhosis, degeneration of the diaphragm, paralysis of the phrenic nerve, increased intrathoracic pressure caused by

emphysema or tuberculosis, and abnormal dilatation of the colon^[6]. Some special groups including overweight individuals^[7] and persons with high abdominal fat content^[8] tend to have higher incidence in migration of the colon or small intestine. In addition, some operations concerning the liver can also cause Chilaiditi syndrome^[9]. In our case, the cause of Chilaiditi syndrome is unclear, but the redundant colon and dilatation of colon at the hepatic flexure are presumed to relate to Chilaiditi syndrome. Although the Chilaiditi sign is asymptomatic, we must carefully consider the presence of gases under the diaphragm in chest radiographs. Careful monitoring of these patients is required, as they have the potential risk of perforation complications during various diagnostic and therapeutic processes, such as percutaneous liver biopsy, thoracentesis and colonoscopy^[10]. When patients need liver puncture, B ultrasound or CT guidance is necessary to avoid potential intestinal perforation^[11].

The diagnosis of Chilaiditi sign seems to be relatively easy because the interposition of the colon is occasionally found on chest films, abdominal plain films or B-ultrasounds, and this sign can be present temporarily or permanently^[12]. When the condition is suspected, supplementary lateral chest radiographs, especially in the left decubitus position, are necessary. To differentiate from pneumoperitoneum, in which case patients require emergency surgery, gases can still be seen below the diaphragm in the left decubitus position when the body position is changed^[13]. In spite of this, chest and abdominal radiography is still not as sensitive

as CT scans for diagnosis^[14].

Differential diagnosis including renal or biliary colic, sub-phrenic abscess, pneumoperitoneum or congenital diaphragmatic hernia must be considered in addition to Chilaiditi syndrome^[15]. In rare cases, other intestinal diseases may also occur at the same time as Chilaiditi syndrome. There are several reports of intestinal perforation caused by Chilaiditi syndrome^[1,16,17]. Under such complicated conditions, further CT scan imaging of the abdomen is recommended if necessary and will help clinicians make correct diagnoses^[18]. Our patient was initially treated in other hospitals and was diagnosed with enteritis and constipation. Luckily, the patient did not receive secondary damage during colonoscopy examination. It was revealed that the colonic mucosa was flaky, striate, linear, with reticulate white scars, slightly higher than normal mucosa. With 3 years of conservative treatment in the outside institute, the symptoms of the patient appeared ingravescence. With the intention to avoid potential complications as a result of invasive examination, abdominal CT and CT simulation endoscopy were arranged in our hospital. The imaging by CT simulation endoscopy identified a cystic dilatation in the colon hepatic flexure with the widest diameter of 8.2 cm, which seemed to be similar to volvulus. Based on the CT manifestations and the absence of severe abdominal pain, vomiting, and fever, we excluded the diagnosis of intestinal volvulus, and the patient was finally diagnosed with Chilaiditi syndrome.

Chilaiditi syndrome generally does not require surgical intervention^[19]. Management strategies for Chilaiditi syndrome consist of conservative treatment and surgical intervention. Conservative treatment based on different clinical symptoms is always effective, and these measures include bed rest, fluid therapy, gastrointestinal decompression, enemas, and stool softeners^[15]. For obese patients, losing weight, which gradually decreases the frequency and intensity of the patient's symptoms, is also a very important and effective method^[7]. If conservative treatment is unsuitable or the patient has serious complications, such as intestinal obstruction, ischemia, volvulus and perforation^[20], surgical intervention is recommended^[21]. There are different operations for this syndrome, including transverse or right hemicolectomy, colopexy, and hepatoxey^[22]. According to the literature, about 26% of all patients with Chilaiditi sign and Chilaiditi syndrome underwent surgical treatment, and stayed asymptomatic during different follow-up periods^[14]. Recently, minimally-invasive surgery, such as laparoscopic surgery, is recommended^[23], even to the extent that there is a report of robotic-assisted technique for the surgical management of Chilaiditi syndrome^[24].

In the presented case, conservative treatment was first recommended because there were no symptoms of intestinal perforation, necrosis and volvulus. However, the patient complained that he could not tolerate long-term intermittent abdominal pain, distension and diffi-

culty with defecation. He therefore demanded surgical treatment to resolve his symptoms. Based on the patient's preference and given the long course of his condition, the patient underwent laparoscopic-assisted right hemicolectomy. With the preexisting abdominal distention, an artificial pneumoperitoneum was created through a small open incision to avoid secondary injury during surgery. As a result, the patient had a good recovery.

Chilaiditi sign and Chilaiditi syndrome are two different states of the same condition. Now that interposition can be found in all patients, why is it that some patients are asymptomatic, while others are symptomatic? We speculate that patients with asymptomatic Chilaiditi sign may become symptomatic for Chilaiditi syndrome in the following situations: (A) sudden increased activity of the redundant colon; (B) increased bowel movements; (C) sudden gas increase in the intestine; and (D) severe increased pressure in the chest with cough in patients with pulmonary tuberculosis or empyema. At present, the etiological classification and pathogenesis of Chilaiditi syndrome are not elaborated thoroughly; therefore, more research should be encouraged to reveal the specific etiology and pathogenesis of Chilaiditi syndrome.

In conclusion, we present a rare case and highlight the importance of proper diagnosis and treatment for subdiaphragmatic gas. When gas is presented under the diaphragm, surgeons and medical students need to consider this syndrome routinely instead of performing emergency surgery as conventional medical education suggests. This condition is typically conservatively treated, and surgery is only required when the conservative treatment is invalid.

ARTICLE HIGHLIGHTS

Case characteristics

A 59-year-old male patient was admitted to our hospital due to intermittent lower abdominal pain and distension accompanied by defecation difficulties for 3 years.

Clinical diagnosis

Chilaiditi syndrome.

Differential diagnosis

Renal or biliary colic, sub-phrenic abscess, pneumoperitoneum or congenital diaphragmatic hernia.

Laboratory diagnosis

Computed tomography (CT) scan of the abdomen confirmed right hepatic atrophy and interposition of the colon. CT simulation endoscopy identified a cystic dilatation in the colon hepatic flexure with the widest diameter of approximately 8.2 cm.

Imaging diagnosis

Chilaiditi syndrome.

Treatment

The patient underwent laparoscope-assisted right hemicolectomy.

Related reports

The incidence of Chilaiditi syndrome is very low. Imaging examination is very important for differential diagnosis and can avoid unnecessary emergency operation. The main treatment is conservative treatment.

Term explanation

Chilaiditi sign refers to the abnormal interposition of the colon or small bowel between the liver and right diaphragm. Once Chilaiditi sign is associated with a variety of clinical respiratory and digestive symptoms, the name is designated as Chilaiditi syndrome.

Experiences and lessons

Chilaiditi syndrome is rare. Due to its low incidence, Chilaiditi syndrome is easily misdiagnosed. Imaging examination is an important diagnostic technique in Chilaiditi syndrome.

REFERENCES

- 1 Aldoss IT, Abuzetun JY, Nusair M, Suker M, Porter J. Chilaiditi syndrome complicated by cecal perforation. *South Med J* 2009; **102**: 841-843 [PMID: 19593284 DOI: 10.1097/SMJ.0b013e3181ad5d62]
- 2 Yin AX, Park GH, Garnett GM, Balfour JF. Chilaiditi syndrome precipitated by colonoscopy: a case report and review of the literature. *Hawaii J Med Public Health* 2012; **71**: 158-162 [PMID: 22787564]
- 3 Joo YE. Chilaiditi's sign. *Korean J Gastroenterol* 2012; **59**: 260-261 [PMID: 22563617 DOI: 10.4166/kjg.2012.59.3.260]
- 4 Hountis P, Chounti M. Chilaiditi's sign or syndrome? Diagnostic question in two patients with concurrent cardiovascular diseases. *Monaldi Arch Chest Dis* 2017; **87**: 775 [PMID: 28967734 DOI: 10.4081/monaldi.2017.775]
- 5 Gad MM, Al-Husseini MJ, Salahia S, Saad AM, Amin R. Chilaiditi syndrome - a rare case of pneumoperitoneum in the emergency department: a case report. *J Med Case Rep* 2018; **12**: 263 [PMID: 30219091 DOI: 10.1186/s13256-018-1804-y]
- 6 Moaven O, Hodin RA. Chilaiditi syndrome: a rare entity with important differential diagnoses. *Gastroenterol Hepatol (N Y)* 2012; **8**: 276-278 [PMID: 22723763]
- 7 Sorrentino D, Bazzocchi M, Badano L, Toso F, Giagu P. Heart-touching Chilaiditi's syndrome. *World J Gastroenterol* 2005; **11**: 4607-4609 [PMID: 16052699 DOI: 10.3748/wjg.v11.i29.4607]
- 8 Farkas R, Moalem J, Hammond J. Chilaiditi's sign in a blunt trauma patient: a case report and review of the literature. *J Trauma* 2008; **65**: 1540-1542 [PMID: 18349718 DOI: 10.1097/01.ta.0000208194.49228.03]
- 9 Jeng KS. Education and imaging. Hepatology: Chilaiditi sign after right hepatectomy for hepatocellular carcinoma. *J Gastroenterol Hepatol* 2015; **30**: 439 [PMID: 25707791 DOI: 10.1111/jgh.12850]
- 10 Gurvits GE, Lau N, Gualtieri N, Robilotti JG. Air under the right diaphragm: colonoscopy in the setting of Chilaiditi syndrome. *Gastrointest Endosc* 2009; **69**: 758-759; discussion 759 [PMID: 19251023 DOI: 10.1016/j.gie.2008.12.238]
- 11 Yamamoto K, Itoi T, Tsuchiya T, Tanaka R, Nagakawa Y. EUS-guided drainage of hepatic abscess in the right side of the liver of a patient with Chilaiditi syndrome. *VideoGIE* 2017; **2**: 299-300 [PMID: 30027128 DOI: 10.1016/j.vgie.2017.06.013]
- 12 Uyungul E, Uyungul D, Ayrik C, Narci H, Bozkurt S, Köse A. Chilaiditi sign: why are clinical findings more important in ED? *Am J Emerg Med* 2015; **33**: 733.e1-733.e2 [PMID: 25524359 DOI: 10.1016/j.ajem.2014.10.031]
- 13 Evrengül H, Yüksel S, Orpak S, Özhan B, Ağladioğlu K. Chilaiditi Syndrome. *J Pediatr* 2016; **173**: 260 [PMID: 27016047 DOI: 10.1016/j.jpeds.2016.02.060]
- 14 Saber AA, Boros MJ. Chilaiditi's syndrome: what should every surgeon know? *Am Surg* 2005; **71**: 261-263 [PMID: 15869145]
- 15 Kang D, Pan AS, Lopez MA, Buicko JL, Lopez-Viego M. Acute abdominal pain secondary to chilaiditi syndrome. *Case Rep Surg* 2013; **2013**: 756590 [PMID: 23936720 DOI: 10.1155/2013/756590]
- 16 Acar T, Kamer E, Acar N, Er A, Peşkersoy M. Chilaiditi's syndrome complicated by colon perforation: a case report. *Ulus Travma Acil Cerrahi Derg* 2015; **21**: 534-536 [PMID: 27054649 DOI: 10.5505/tjtes.2015.38464]
- 17 Sunkara T, Rawla P, Yarlagaadda KS, Baltazar GA, Gaduputi V. Chilaiditi Syndrome Complicated by Cecal Perforation in the Setting of Scleroderma. *J Investig Med High Impact Case Rep* 2018; **6**: 2324709618803387 [PMID: 30283808 DOI: 10.1177/2324709618803387]
- 18 Hussain S, Hussain S, Hussain S. Chilaiditi Syndrome-What's Air Doing There? *J Emerg Med* 2018; **55**: e131-e132 [PMID: 30181076 DOI: 10.1016/j.jemermed.2018.07.022]
- 19 Esperto H, Ruivo C, Ferreira E. Chilaiditi's sign. *Acta Med Port* 2013; **26**: 71 [PMID: 23697363]
- 20 Correa Jiménez O, Buendía De Ávila M, Parra Montes E, Davidson Córdoba J, De Vivero Camacho R. Chilaiditi's sign and syndrome: rare conditions but diagnostically important in pediatrics. Clinical cases. *Rev Chil Pediatr* 2017; **88**: 635-639 [PMID: 29546949 DOI: 10.4067/S0370-41062017000500010]
- 21 Williams A, Cox R, Palaniappan B, Woodward A. Chilaiditi's syndrome associated with colonic volvulus and intestinal malrotation-A rare case. *Int J Surg Case Rep* 2014; **5**: 335-338 [PMID: 24811427 DOI: 10.1016/j.ijscr.2014.03.011]
- 22 Mateo de Acosta Andino DA, Aberle CM, Ragauskaitė L, Khair G, Streicher A, Bartholomew J, Kacey D. Chilaiditi syndrome complicated by a closed-loop small bowel obstruction. *Gastroenterol Hepatol (N Y)* 2012; **8**: 274-276 [PMID: 22723762]
- 23 Takahashi K, Ito H, Katsube T, Tsuboi A, Hashimoto M, Ota E, Mita K, Asakawa H, Hayashi T, Fujino K. Treatment of Chilaiditi syndrome using laparoscopic surgery. *Asian J Endosc Surg* 2017; **10**: 63-65 [PMID: 27651120 DOI: 10.1111/ases.12319]
- 24 Garcia O, Rayhrer C. Surgical management of Chilaiditi syndrome with da Vinci® robotic system. *Int J Surg Case Rep* 2017; **41**: 450-452 [PMID: 29546014 DOI: 10.1016/j.ijscr.2017.10.066]

P- Reviewer: Chiba T, Contini S, Kakisaka Y, Majbar AM, Shimizu Y, Wang YP, Wani IA **S- Editor:** Dou Y
L- Editor: Filipodia **E- Editor:** Song H





Published by **Baishideng Publishing Group Inc**
7901 Stoneridge Drive, Suite 501, Pleasanton, CA 94588, USA
Telephone: +1-925-223-8242
Fax: +1-925-223-8243
E-mail: bpgoffice@wjgnet.com
Help Desk: <http://www.f6publishing.com/helpdesk>
<http://www.wjgnet.com>

