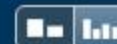

## Match Overview



**Name of Journal:** *World Journal of Orthopedics*

**Manuscript NO:** 42525

**Manuscript Type:** CASE REPORT

**Metallosis following a clip breakage in a total knee arthroplasty implant: A case report**

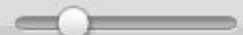
Ahmed Isam Saad, Shafiq Arif Shahban, Richard Fernandes

### Abstract

#### **BACKGROUND**

Metallosis describes the build-up of metal debris in the soft tissues after a period of metal on metal articulation. This debris can be asymptomatic or lead to catastrophic implant failure, which can present acutely, as in this case, or over a period of time. This report highlights how a metal clip used to hold the polyethylene liner to the tibial base plate broke 5 years after implantation, dislodged from its original position and went on to cause post-operative knee metallosis.

There are no matching sources for this report.



[全部](#)[图片](#)[新闻](#)[视频](#)[更多](#)[设置](#)[工具](#)

找到约 9 条结果 (用时 0.42 秒)

### Case Report: Metallosis in a total knee arthroplasty - NCBI - NIH

<https://www.ncbi.nlm.nih.gov/pmc/articles/PMC3962890/> - 翻译此页

作者: B Vivegananthan - 2014 - 被引用次数: 2 - 相关文章

2014年3月18日 - The prosthesis used was a Genesis **Total Knee** System with **implant** ...  
Indications for this include aseptic loosening, **joint** instability, periprosthetic **fracture** ... All  
**cases of metallosis following knee** arthroplasties described in the ...

缺少字词: clip

### Acute Metallosis Following Total Knee Replacement – A Case Report

<https://www.ncbi.nlm.nih.gov/pmc/articles/PMC4722561/> - 翻译此页

作者: KC Klontz - 2014 - 相关文章

**Metallosis** involving the **knee joint** most often results from metal-on-metal contact late in the  
life of a failing **implant following** polyethylene wear. We **report** a **case** ...

缺少字词: clip breakage

### (PDF) Unexpected wear of an unicompartmental knee arthroplasty in ...

[https://www.researchgate.net/.../293488476\\_Unexpected\\_wear\\_of\\_an\\_unico...](https://www.researchgate.net/.../293488476_Unexpected_wear_of_an_unico...) - 翻译此页

2016年2月8日 - **Metallosis after** unicompartmental **knee arthroplasty** is rarely reported and is  
most often related with polyethylene wear or **break**. We **report** on a **case of** rapid failure of  
unicompartmental **knee arthroplasty** in oxidized zirconium associated with **metallosis** ...  
related to the patient, the design of the **implant** and.

### Allergy to Surgical Implants - Journal of Allergy and Clinical ...

[https://www.jaci-inpractice.org/article/S2213-2198\(15\)00392-X/pdf](https://www.jaci-inpractice.org/article/S2213-2198(15)00392-X/pdf) - 翻译此页

作者: KA Pacheco - 2015 - 被引用次数: 19 - 相关文章

**after** his right **total knee replacement** was performed 15 months earlier. .... **metallosis** and  
pseudotumor formation from the toxic and necrotic effects of .... The allergenicity of MMA is

[全部](#)[图片](#)[新闻](#)[视频](#)[购物](#)[更多](#)[设置](#)[工具](#)

找到约 80,400 条结果（用时 0.71 秒）

### Case Report: Metallosis in a total knee arthroplasty - NCBI - NIH

<https://www.ncbi.nlm.nih.gov/pmc/articles/PMC3962890/> - 翻译此页

作者: B Vivegananthan - 2014 - 被引用次数: 2 - 相关文章

2014年3月18日 - The prosthesis used was a Genesis **Total Knee** System with **implant** ... Indications for this include aseptic loosening, **joint** instability, periprosthetic **fracture** and ... All **cases of metallosis following knee arthroplasties** described in the .... about the **Knee Joint: A Rare Sequela of Metallosis after Total Knee** ...

缺少字词: **clip**

### Acute Metallosis Following Total Knee Replacement – A Case Report

<https://www.ncbi.nlm.nih.gov/pmc/articles/PMC4722561/> ▼ 翻译此页

作者: KC Klontz - 2014 - 相关文章

We **report a case** of acute **metallosis following** knee arthroplasty in a previously ... metal contact late in the life of a failing **implant following** polyethylene wear (1 - 3). .... Early onset **metallosis following total knee replacement** is **rarely** described.

缺少字词: **clip breakage**

### Severe Metallosis After Total Elbow Arthroplasty—A Case Report

<https://www.ncbi.nlm.nih.gov/pmc/articles/PMC2820628/> ▼ 翻译此页

作者: AS Sayed-Noor - 2010 - 被引用次数: 11 - 相关文章

2009年5月15日 - We present a **case** of severe **metallosis after total** elbow **arthroplasty** in a female ...



[全部](#)[图片](#)[新闻](#)[视频](#)[购物](#)[更多](#)[设置](#)[工具](#)

找到约 30,300 条结果 (用时 0.59 秒)

### Case Report: Metallosis in a total knee arthroplasty - NCBI - NIH

<https://www.ncbi.nlm.nih.gov/pmc/articles/PMC3962890/> - 翻译此页

作者 : B Vivegananthan - 2014 - 被引用次数 : 2 - 相关文章

2014年3月18日 - The prosthesis used was a Genesis **Total Knee** System with **implant** ... Indications for this include aseptic loosening, **joint** instability, periprosthetic **fracture** ... All **cases of metallosis following knee** arthroplasties described in the ...

缺少字词 : clip

### Severe Metallosis After Total Elbow Arthroplasty—A Case Report

<https://www.ncbi.nlm.nih.gov/pmc/articles/PMC2820628/> - 翻译此页

作者 : AS Sayed-Noor - 2010 - 被引用次数 : 12 - 相关文章

2009年5月15日 - We present a **case** of severe **metallosis after** total elbow arthroplasty in a female ... with metal-on-metal arthroplasty or in patients with PE wear or **fracture** with ... Solomon L. Widespread dissemination of metal debris from **implants**. ... O. Osteolysis in revision **total knee arthroplasty**: a comparative **study** of ...

缺少字词 : clip

### (PDF) Unexpected wear of an unicompartmental knee arthroplasty in ...

[https://www.researchgate.net/.../293488476\\_Unexpected\\_wear\\_of\\_an\\_unico...](https://www.researchgate.net/.../293488476_Unexpected_wear_of_an_unico...) - 翻译此页

2016年2月8日 - **Metallosis after** unicompartmental **knee arthroplasty** is rarely reported and is most often related with polyethylene wear or **break**. We **report** on a **case of** rapid failure **of** unicompartmental **knee arthroplasty** in oxidized zirconium associated with **metallosis** ... related to the patient, the design **of** the **implant** and.

### Allergy to Surgical Implants - JACI: In Practice

[https://www.jaci-inpractice.org/article/S2213-2198\(15\)00392-X/pdf](https://www.jaci-inpractice.org/article/S2213-2198(15)00392-X/pdf) - 翻译此页

作者 : KA Pacheco - 2015 - 被引用次数 : 19 - 相关文章

Surgical **implants** have a wide array of therapeutic uses, most commonly in joint ... **after** his right **total knee replacement** was performed 15 months earlier ... **metallosis** and pseudotumor formation from the