


World Journal of *Clinical Cases*

World J Clin Cases 2019 March 6; 7(5): 548-690



**ORIGINAL ARTICLE****Retrospective Study**

- 548** Clinical presentation and early predictors for poor outcomes in pediatric myocarditis: A retrospective study
Rodriguez-Gonzalez M, Sanchez-Codez MI, Lubian-Gutierrez M, Castellano-Martinez A

Observational Study

- 562** Safety of an improved patent ductus arteriosus occluder for transcatheter closure of perimembranous ventricular septal defects with abnormally attached tricuspid chordae tendineae
He L, Du YJ, Cheng GS, Zhang YS

META-ANALYSIS

- 572** Adiponectin gene polymorphisms and risk of gestational diabetes mellitus: A meta-analysis
Huang LT, Wu SL, Liao X, Ma SJ, Tan HZ
- 585** Maternal serum level of resistin is associated with risk for gestational diabetes mellitus: A meta-analysis
Hu SM, Chen MS, Tan HZ
- 600** Docetaxel, cisplatin, and 5-fluorouracil compared with epirubicin, cisplatin, and 5-fluorouracil regimen for advanced gastric cancer: A systematic review and meta-analysis
Li B, Chen L, Luo HL, Yi FM, Wei YP, Zhang WX

CASE REPORT

- 616** Sustained complete response to erlotinib in squamous cell carcinoma of the head and neck: A case report
Thinn MM, Hsueh CT, Hsueh CT
- 623** Exercise-induced anaphylaxis with an Ayurvedic drug as cofactor: A case report
Losa F, Deidda M, Firinu D, Martino MLD, Barca MP, Giacco SD
- 628** Diagnostic detection with cardiac tomography and resonance of extremely rare coronary anomaly: A case report and review of literature
Schicchi N, Fogante M, Giuseppetti GM, Giovagnoni A
- 636** Fatal meningococcal meningitis in a 2-year-old child: A case report
Mularski A, Žaba C
- 642** Perioperative topical ascorbic acid for the prevention of phacoemulsification-related corneal endothelial damage: Two case reports and review of literature
Lee CY, Chen HT, Hsueh YJ, Chen HC, Huang CC, Meir YJJ, Cheng CM, Wu WC

- 650** Application of computer-assisted navigation in treating congenital maxillomandibular syngnathia: A case report
Lin LQ, Bai SS, Wei M
- 656** Concomitant paraganglioma and thyroid carcinoma: A case report
Lin B, Yang HY, Yang HJ, Shen SY
- 663** Rare empty sella syndrome found after postoperative hypotension and respiratory failure: A case report
Guo P, Xu ZJ, Hu CE, Zheng YY, Xu DF
- 668** Use of tunnel endoscopy for diagnosis of obscure submucosal esophageal adenocarcinoma: A case report and review of the literature with emphasis on causes of esophageal stenosis
Liu S, Wang N, Yang J, Yang JY, Shi ZH
- 676** Intrauterine cystic adenomyosis: Report of two cases
Fan YY, Liu YN, Li J, Fu Y
- 684** Melanotic Xp11-associated tumor of the sigmoid colon: A case report
Wang G, Li GG, Zhu SM, Cai BJ, Yu PJ, Zhang CW

ABOUT COVER

Editorial Board Member of *World Journal of Clinical Cases*, Manel Sabate, MD, PhD, Associate Professor, Interventional Cardiology Department, Clinic University Hospital, Barcelona 08036, Spain

AIMS AND SCOPE

World Journal of Clinical Cases (*World J Clin Cases*, *WJCC*, online ISSN 2307-8960, DOI: 10.12998) is a peer-reviewed open access academic journal that aims to guide clinical practice and improve diagnostic and therapeutic skills of clinicians.

The primary task of *WJCC* is to rapidly publish high-quality Case Report, Clinical Management, Editorial, Field of Vision, Frontier, Medical Ethics, Original Articles, Meta-Analysis, Minireviews, and Review, in the fields of allergy, anesthesiology, cardiac medicine, clinical genetics, clinical neurology, critical care, dentistry, dermatology, emergency medicine, endocrinology, family medicine, gastroenterology and hepatology, etc.

INDEXING/ABSTRACTING

The *WJCC* is now indexed in PubMed, PubMed Central, Science Citation Index Expanded (also known as SciSearch®), and Journal Citation Reports/Science Edition. The 2018 Edition of Journal Citation Reports cites the 2017 impact factor for *WJCC* as 1.931 (5-year impact factor: N/A), ranking *WJCC* as 60 among 154 journals in Medicine, General and Internal (quartile in category Q2).

RESPONSIBLE EDITORS FOR THIS ISSUE

Responsible Electronic Editor: Ying-Na Bian

Proofing Editorial Office Director: Jin-Lei Wang

NAME OF JOURNAL

World Journal of Clinical Cases

ISSN

ISSN 2307-8960 (online)

LAUNCH DATE

April 16, 2013

FREQUENCY

Semimonthly

EDITORS-IN-CHIEF

Dennis A Bloomfield, Sandro Vento

EDITORIAL BOARD MEMBERS

<https://www.wjgnet.com/2307-8960/editorialboard.htm>

EDITORIAL OFFICE

Jin-Lei Wang, Director

PUBLICATION DATE

March 6, 2019

COPYRIGHT

© 2019 Baishideng Publishing Group Inc

INSTRUCTIONS TO AUTHORS

<https://www.wjgnet.com/bpg/gerinfo/204>

GUIDELINES FOR ETHICS DOCUMENTS

<https://www.wjgnet.com/bpg/GerInfo/287>

GUIDELINES FOR NON-NATIVE SPEAKERS OF ENGLISH

<https://www.wjgnet.com/bpg/gerinfo/240>

PUBLICATION MISCONDUCT

<https://www.wjgnet.com/bpg/gerinfo/208>

ARTICLE PROCESSING CHARGE

<https://www.wjgnet.com/bpg/gerinfo/242>

STEPS FOR SUBMITTING MANUSCRIPTS

<https://www.wjgnet.com/bpg/GerInfo/239>

ONLINE SUBMISSION

<https://www.f6publishing.com>

Application of computer-assisted navigation in treating congenital maxillomandibular syngnathia: A case report

Li-Qin Lin, Shan-Shan Bai, Min Wei

ORCID number: Li-Qin Lin (0000-0003-0003-8722); Shan-Shan Bai (0000-0002-1065-7730); Min Wei (0000-0002-6974-6287).

Author contributions: Lin LQ and Bai SS are co-first authors and contributed equally to this work; all authors contributed to this work.

Supported by Ninth People's Hospital affiliated to Shanghai Jiao Tong University, School of Medicine "Multi-Disciplinary Team" Clinical Research Project, No. 201701011.

Informed consent statement: The relatives of the individual in this manuscript have provided informed written consent to publish this case.

Conflict-of-interest statement: The authors have no conflicts of interest to declare. None of the authors have received funding from any organization with a real or potential interest in the subject matter, materials, equipment, software, or devices discussed.

CARE Checklist (2016) statement: The authors have read the CARE Checklist (2016), and the manuscript was prepared and revised according to the CARE Checklist (2016).

Open-Access: This article is an open-access article which was selected by an in-house editor and fully peer-reviewed by external reviewers. It is distributed in accordance with the Creative Commons Attribution Non Commercial (CC BY-NC 4.0)

Li-Qin Lin, Shan-Shan Bai, Min Wei, Department of Plastic and Reconstructive Surgery, Shanghai Ninth People's Hospital, Shanghai Jiao Tong University School of Medicine, Shanghai 200011, China

Corresponding author: Min Wei, MD, PhD, Doctor, Full Professor, Surgeon, Department of Plastic and Reconstructive Surgery, Shanghai Ninth People's Hospital, Shanghai Jiao Tong University School of Medicine, 639 Zhizaoju Road, Shanghai 200011, China.

drwm1010@sina.com

Telephone: +86-137-01671615

Abstract

BACKGROUND

Congenital maxillomandibular syngnathia is an extremely rare disorder characterized by craniofacial malformations and inability to open the mouth adequately, which leads to problems with feeding, swallowing, and breathing as well as temporomandibular joint ankylosis. The main goal of the surgery is to release the ankylosis, establish functioning mandible, and prevent re-fusion. However, surgical procedures for this disease are rarely reported.

CASE SUMMARY

Here, we report a 7-mo-old girl with bilateral maxillomandibular syngnathia. The patient presented with difficulty in feeding, breathing, sounding, and swallowing and had developmental dysplasia. For treatment, we performed bone isolation by computer-assisted navigation and used silicone to fix the wound surface to prevent refusion of bone. To our knowledge, this is the only syngnathia case in the literature treated using computer-assisted navigation. With the guidance of precise navigation, we were able to minimize operation time by at least one hour, the patient's blood vessels, nerves, and tooth germs were well protected, and excessive bleeding was avoided. After six weeks, the patient showed improvement in mouth opening and no major issues of feeding.

CONCLUSION

Application of computer-assisted navigation can significantly improve accuracy, effectiveness, and surgical safety in correcting congenital maxillomandibular syngnathia.

Key words: Craniofacial abnormalities; Mandibular diseases; Maxilla; Computer-assisted navigation; Case report

©The Author(s) 2019. Published by Baishideng Publishing Group Inc. All rights reserved.

license, which permits others to distribute, remix, adapt, build upon this work non-commercially, and license their derivative works on different terms, provided the original work is properly cited and the use is non-commercial. See: <http://creativecommons.org/licenses/by-nc/4.0/>

Manuscript source: Unsolicited manuscript

Received: November 9, 2018

Peer-review started: November 13, 2018

First decision: December 29, 2018

Revised: January 28, 2019

Accepted: January 29, 2019

Article in press: January 30, 2019

Published online: March 6, 2019

Core tip: Congenital maxillomandibular fusion is a rare anomaly of the craniofacial region. We report a 7-mo-old girl with bilateral maxillomandibular syngnathia. We performed bony isolation by computer-assisted navigation, a first-of-its-kind treatment approach for syngnathia. The operation time was minimized by at least one hour, and the patient's blood vessels, nerves, and tooth germs were well protected, and bleeding was minimized. There were major improvements in the patient's status. We concluded that application of computer-assisted navigation can significantly improve accuracy, effectiveness, and surgical safety in difficult-to-treat deformity.

Citation: Lin LQ, Bai SS, Wei M. Application of computer-assisted navigation in treating congenital maxillomandibular syngnathia: A case report. *World J Clin Cases* 2019; 7(5): 650-655

URL: <https://www.wjgnet.com/2307-8960/full/v7/i5/650.htm>

DOI: <https://dx.doi.org/10.12998/wjcc.v7.i5.650>

INTRODUCTION

Congenital craniofacial disorders represent approximately 20% of all birth defects. Syngnathia, a rare craniofacial disorder, is characterized by fusion of the hard and soft tissues of the jaw. The first case of syngnathia was reported by Burket in 1936 in a patient who had multiple diagnoses, including temporomandibular joint (TMJ) ankyloses, fusion of gums, associated facial hemiatrophy, and Horner syndrome^[1]. A significant complication in syngnathia patients is restricted mouth opening, which results in feeding, swallowing, and respiration problems. Early recognition and treatment are critical for normal growth and development. The aim of the case report is to introduce the application of computer-assisted navigation during syngnathia corrective surgery.

CASE PRESENTATION

Chief complaints

A 7-month-old girl with a clinical diagnosis of congenital maxillomandibular fusion was referred to the Department of Plastic and Reconstructive Surgery, Shanghai Ninth People's Hospital, Shanghai Jiao Tong University School of Medicine for surgery. She was suffering from bilateral maxillomandibular syngnathia and inability to open mouth.

History of present illness

The patient was fed through a straw by his grandmother.

History of past illness

She had no past history of surgery and was not taking any medication.

Personal and family history

She was the first child of the parents (mother 28 years old, father 30 years old) and was born *via* an uncomplicated vaginal delivery. The parents did not have a history of consanguineous marriage. A similar symptom was not observed in other patient's family members.

Physical examination upon admission

Physical examination revealed severe retardation - she was 73 cm tall and weight 5.5 kg - but did not reveal any congenital or systemic problems. She also presented with difficulty in feeding, breathing, sounding, and swallowing. The patient had difficulty in opening her mouth more than 1 mm in diameter. In her oral cavity, the upper and lower gums were completely fused and two deciduous teeth in the mandible were visible (Figure 1). Otherwise no abnormalities were noted.

Laboratory examinations

No abnormality was seen in routine blood tests, biochemical tests, or ECG.

Imaging examinations

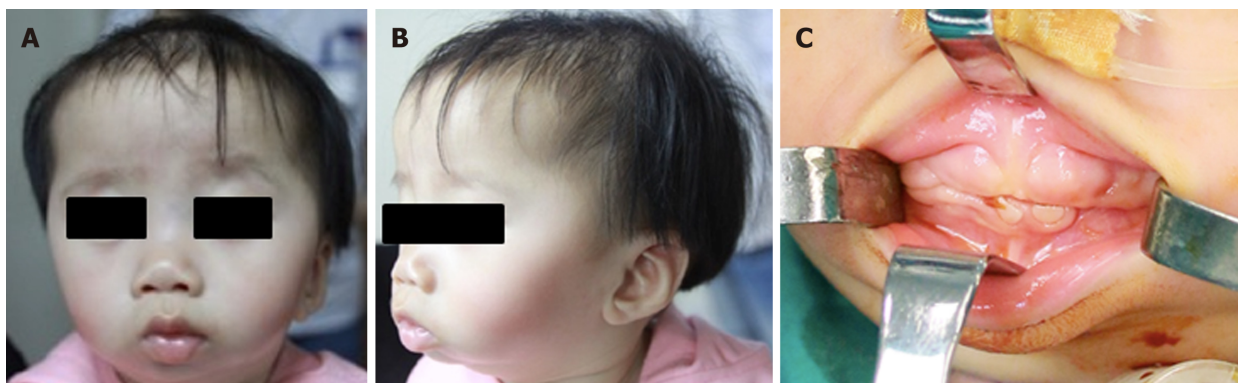

Figure 1 Facial features and preoperative intraoral view of the patient. A: Frontal view of the patient; B: Profile view of the patient; C: Intraoral view. Maxillary and mandibular arches were fused.

A three-dimensional CT scan showed bilateral maxillomandibular fusion and very little oral cavity (Figure 2). These observations are consistent with TMJ ankyloses, a typical clinical feature in syngnathia patients.

FINAL DIAGNOSIS

Congenital maxillomandibular syngnathia.

TREATMENT

The purpose of the surgery was to separate the fused mandible and maxilla to open the mouth, which would solve the patient's feeding issues. The patient underwent a prophylactic tracheostomy to prevent obstruction of airway during surgery 7 d in advance. Then, we prepared for computer-assisted navigation. Three-dimensional CT data were saved in the Dicom (digital imaging and communications in medicine) format and were imported into Mimics 10.0 software (Materialise, Leuven, Belgium) and the iPlan software of the VectorVision2 navigation system (BrainLAB, Feldkirchen, Germany). The anatomical landmarks were measured and analyzed on the basis of three-dimensional images. We chose the line from preauricular to marginal mandibular as the incision site. Operation simulations were performed to affirm the position of osteotomy line and the level of mandibular opening and its fixed position. The patient underwent general anaesthesia and the skin was sterilized. A navigation bracket was installed to the patient's head first, and then face scanning by a laser scanner was performed for surface registration. The surgical instrument was registered at last. Registration accuracy (0.8 mm) was verified using the navigation pointer. The tip position and orientation of the probe were viewed continuously on screen (Figure 3). The oral space was exposed by retractors, the skin and subcutaneous tissue of incision were cut open, and the bilateral jaw lateral surface was exposed by blunt separation. It was easy to detect and isolate the mandible using the navigation system. Real-time position was verified by the navigation probe to avoid damaging important nerves, vessels, and dental germs. After the mandible was sawed off, silicone was fixed on the wound surface to prevent refusion of bone. Negative pressure drainage was put in the bilateral mandibles prior to suturing the incision. Perioperative bleeding was 100 mL. The patient was admitted to SICU after surgery.

OUTCOME AND FOLLOW-UP

Immediately following surgery, the patient had difficulty swallowing, so we used a nasogastric tube for feeding. The patient was discharged from the hospital one week later and was instructed to perform mouth opening and swallowing exercises. Follow-up three-dimensional CT scans of the face confirmed separation and bony healing. After six months, there was no recurrence. After eight months, the patient was 91 cm in height, weighed 11 kg, and could pronounce several single words; thus, we concluded that the surgery was successful.

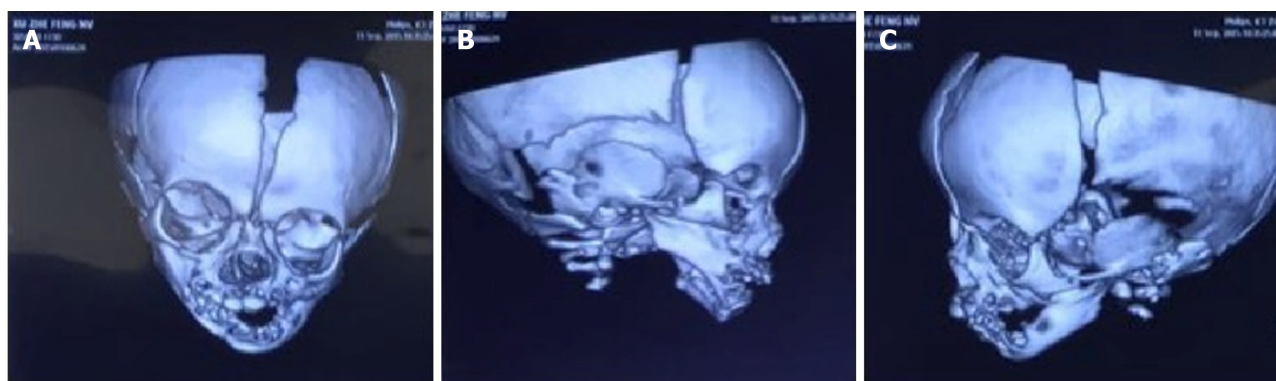


Figure 2 Three-dimensional computed tomography images demonstrating bony fusion of bilateral maxillaries to the mandibles. A: Frontal view; B: Right lateral view; C: Left lateral view.

DISCUSSION

Syngnathia is a rare human congenital condition. It involves connection between soft tissues or fusion between bony tissues and varies in severity from single mucosal bands (synechia) to complete bone fusion (synostosis)^[2]. Syngnathia is often accompanied by additional congenital defects, such as microglossia, micrognathia, and TMJ abnormalities. There are approximately 60 cases of congenital bony syngnathia reported in the literature^[3], which reveal a high degree of variability in the location and extent of jaw fusion, and indicate that bony syngnathia may be isolated or syndromic. It is estimated that only 18% of cases are associated with known syndromes, such as aglossia-adactylia syndrome or hemifacial microsomia^[4]. In the reported cases, women commonly display an isolated form of syngnathia, whereas men display a more complex pattern of disease. Syngnathia is usually detected immediately after birth because the baby is not able to open the mouth to feed normally. Notably, patients presenting with complete bilateral synostosis of the upper and lower jaw represent the least common and most severe form of syngnathia.

The etiology and pathogenesis of syngnathia remain unknown, and it is an extremely rare condition involving abnormal development of the splanchnocranium, which is the part of the skull that is derived from the branchial arches^[2]. Various etiologies have been proposed, including environmental insults, medications such as meclizine, persistence of the buccopharyngeal membrane, and amniotic constriction bands^[5,6]. Villanueva-García and colleagues have suggested the possibility of an autosomal recessive occurrence^[7]. Moreover, a recent molecular genetics study showed that the *Foxc1* and *Fgf8* genes play a role in regulating mammalian jaw patterning and mutations in these genes may underlie the pathogenesis of syngnathia^[4]. However, given that our patient had no other congenital abnormalities and there was no significant family history, a genetic or syndromic cause is unlikely.

Surgical division of the fusion must be carried out as soon as possible, which is necessary for normal feeding, removing airway obstruction, and allowing normal mandibular growth. Delay in surgical treatment increases the possibility of TMJ ankylosis, which leads to a lack of mandibular growth and facial deformities. The main goal of the surgery described in this care report was to release syngnathia and prevent recurrence. New management techniques, such as distraction, have been reported in congenital maxillomandibular^[8]. Since most syngnathia patients are infants, major surgical challenges are intraoperative blood loss and damage to nerves and dental germs. Another challenge stems from the lack of comprehensive guidelines to ensure patient safety during this type of surgery.

In the present case, we applied computer-assisted navigation to instruct our surgical approach. Computer navigation has emerged as an essential technology for guiding and verifying operations, such as reconstruction of mandible or orbital bone, orthognathia, and many other of craniofacial surgeries^[9,10]. We can understand the correlations among surgical devices, incisions, and peripheral anatomic sites in real-time easily *via* computer navigation, and also can check the distance between the operation positions to the position designed preoperatively. With the precise guidance of computer navigation, our operative time was minimized by at least one hour. Moreover, the patients' blood vessels, nerves, and tooth germs were all well protected and perioperative bleeding was minimized.

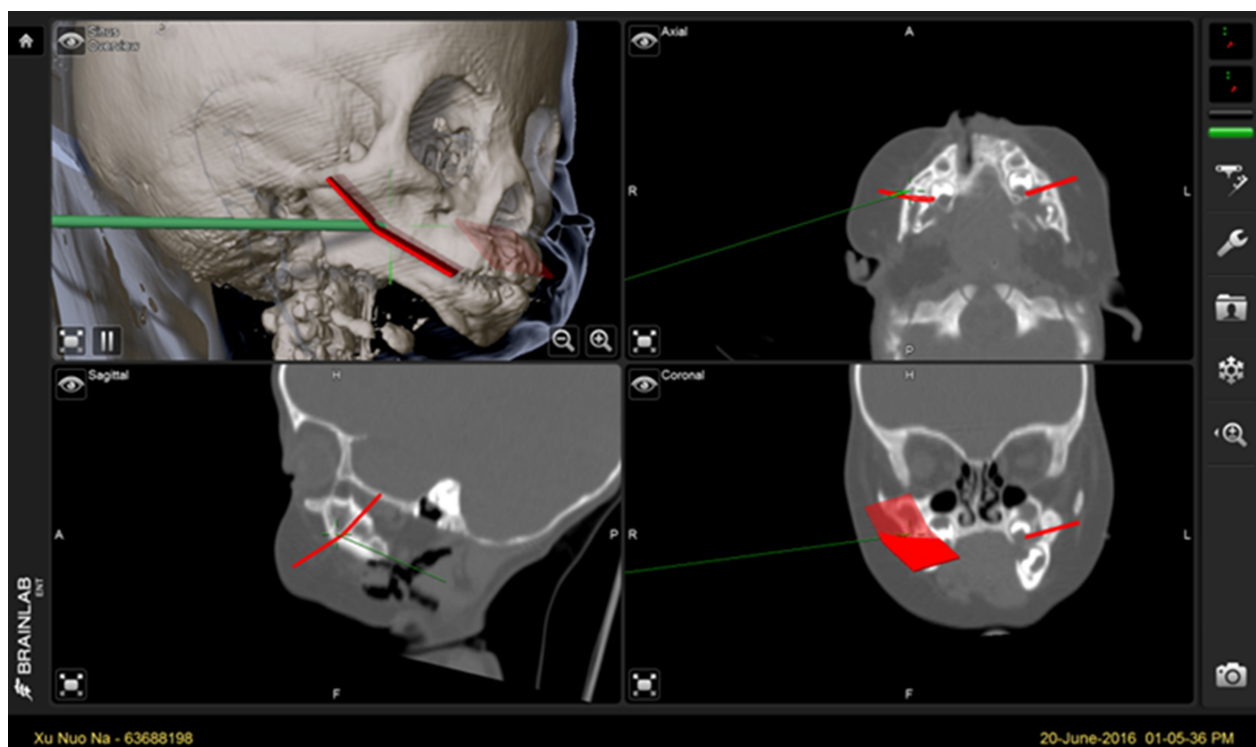


Figure 3 Screenshot of the navigation system. The pointer indicates arrival at the target site.

CONCLUSION

We have demonstrated a novel approach to treating complex zygomaticomandibular syngnathia. Distraction techniques, like the one used here, should prove useful in addressing other craniofacial malformations. To our knowledge, this is the only syngnathia case in the literature treated using distraction techniques. In the future, our approach could be optimized to manage and prevention recurrence in other syngnathia patients.

ACKNOWLEDGEMENTS

The authors would like to thank the research staff and clinical personnel of the Shanghai 9th People's Hospital for their outstanding performance and patient care.

REFERENCES

- 1 **Martín LP**, Pérez MM, García EG, Martín-Moro JG, González JI, García MB. Atypical case of congenital maxillomandibular fusion with duplication of the craniofacial midline. *Craniofacial Trauma Reconstr* 2011; **4**: 113-120 [PMID: 22655122 DOI: 10.1055/s-0031-1279674]
- 2 **Broome M**, Vial Y, Jacquemont S, Sergi C, Kamnasaran D, Giannoni E. Complete Maxillo-Mandibular Syngnathia in a Newborn with Multiple Congenital Malformations. *Pediatr Neonatol* 2016; **57**: 65-68 [PMID: 23778189 DOI: 10.1016/j.pedneo.2013.04.009]
- 3 **Al-Mahdi AH**, Koppel DA, Al-Jumaily HA, Mohammed AA, Boyd D. Congenital Bilateral Zygomatico-Maxillo-Mandibular Fusion Associated With Gum Fusion. *J Craniofac Surg* 2016; **27**: e20-e23 [PMID: 26703053 DOI: 10.1097/SCS.0000000000002293]
- 4 **Inman KE**, Purcell P, Kume T, Trainor PA. Interaction between Foxc1 and Fgf8 during mammalian jaw patterning and in the pathogenesis of syngnathia. *PLoS Genet* 2013; **9**: e1003949 [PMID: 24385915 DOI: 10.1371/journal.pgen.1003949]
- 5 **Fallahi HR**, Naeini M, Mahmoudi M, Javaherforoosh F. Congenital zygomatico-maxillo-mandibular fusion: a brief case report and review of literature. *Int J Oral Maxillofac Surg* 2010; **39**: 930-933 [PMID: 20466517 DOI: 10.1016/j.ijom.2010.04.003]
- 6 **Turksen Z**, Ozakpinar HR, Tellioglu AT. A case of syngnathia, cleft palate and hypospadias: an isolated case or syndromic syngnathism? *J Craniofacial Surg* 2012; **40**: 8-10 [PMID: 21501960 DOI: 10.1016/j.jcms.2011.02.004]
- 7 **Villanueva-García D**, Contreras-Masse G, Villa-Guillén M, Ramón-García G, Murguía-De Sierra T. Syngnathism in an infant born to consanguineous parents. *Am J Med Genet A* 2009; **149A**: 2303-2305 [PMID: 19725127 DOI: 10.1002/ajmg.a.32734]
- 8 **Konaş E**, Aliyev A, Tunçbilek G. Congenital maxillomandibular syngnathia: a new management

- technique using distraction techniques. *J Craniofac Surg* 2015; **26**: e68-e70 [PMID: [25569423](#) DOI: [10.1097/SCS.0000000000001239](#)]
- 9 **Rahimov CR**, Farzaliyev IM, Fathi HR, Davudov MM, Aliyev A, Hasanov E. The Application of Virtual Planning and Navigation Devices for Mandible Reconstruction and Immediate Dental Implantation. *Craniomaxillofac Trauma Reconstr* 2016; **9**: 125-133 [PMID: [27162568](#) DOI: [10.1055/s-0035-1566159](#)]
- 10 **Varley I**, White L, Salvi SM, Lee N. Digital import of orbital implants to enhance navigation in reconstruction of the deep orbit. *Orbit* 2016; **35**: 20-23 [PMID: [26679992](#) DOI: [10.3109/01676830.2015.1099691](#)]

P- Reviewer: Karatza AA; Rolle U

S- Editor: Dou Y **L- Editor:** Wang TQ **E- Editor:** Bian YN





Published By Baishideng Publishing Group Inc
7041 Koll Center Parkway, Suite 160, Pleasanton, CA 94566, USA
Telephone: +1-925-2238242
Fax: +1-925-2238243
E-mail: bpgoffice@wjgnet.com
Help Desk: <https://www.f6publishing.com/helpdesk>
<https://www.wjgnet.com>

