

World Journal of *Clinical Cases*

World J Clin Cases 2019 September 26; 7(18): 2658-2915



**OPINION REVIEW**

- 2658** Effective use of the Japan Narrow Band Imaging Expert Team classification based on diagnostic performance and confidence level
Hirata D, Kashida H, Iwatate M, Tochio T, Teramoto A, Sano Y, Kudo M

MINIREVIEWS

- 2666** Low fermentable oligosaccharides, disaccharides, monosaccharides, and polyols diet in children
Fodor I, Man SC, Dumitrascu DL
- 2675** High-resolution colonic manometry and its clinical application in patients with colonic dysmotility: A review
Li YW, Yu YJ, Fei F, Zheng MY, Zhang SW

ORIGINAL ARTICLE**Retrospective Study**

- 2687** Predictors of rebleeding and in-hospital mortality in patients with nonvariceal upper digestive bleeding
Lazăr DC, Ursoniu S, Goldiș A
- 2704** Analgesic effect of parecoxib combined with ropivacaine in patients undergoing laparoscopic hepatectomy
Huang SS, Lv WW, Liu YF, Yang SZ
- 2712** Prognostic significance of 14v-lymph node dissection to D2 dissection for lower-third gastric cancer
Zheng C, Gao ZM, Sun AQ, Huang HB, Wang ZN, Li K, Gao S

Observational Study

- 2722** Wall shear stress can improve prediction accuracy for transient ischemic attack
Liu QY, Duan Q, Fu XH, Jiang M, Xia HW, Wan YL

Prospective Study

- 2734** Characterization of microbiota in systemic-onset juvenile idiopathic arthritis with different disease severities
Dong YQ, Wang W, Li J, Ma MS, Zhong LQ, Wei QJ, Song HM

SYSTEMATIC REVIEWS

- 2746** Sinusoidal obstruction syndrome: A systematic review of etiologies, clinical symptoms, and magnetic resonance imaging features
Zhang Y, Jiang HY, Wei Y, Song B

META-ANALYSIS

- 2760** Respiratory training interventions improve health status of heart failure patients: A systematic review and network meta-analysis of randomized controlled trials
Wang MH, Yeh ML

CASE REPORT

- 2776** *Mycobacterium chimaera* infections following cardiac surgery in Treviso Hospital, Italy, from 2016 to 2019: Cases report
Inojosa WO, Giobbia M, Muffato G, Minniti G, Baldasso F, Carniato A, Farina F, Forner G, Rossi MC, Formentini S, Rigoli R, Scotton PG
- 2787** Giant squamous cell carcinoma of the gallbladder: A case report
Junior MAR, Favaro MDL, Santin S, Silva CM, Iamarino APM
- 2794** Liver re-transplantation for donor-derived neuroendocrine tumor: A case report
Mrzljak A, Kocman B, Skrtic A, Furac I, Popic J, Franusic L, Zunec R, Mayer D, Mikulic D
- 2802** Calcifying fibrous tumor originating from the gastrohepatic ligament that mimicked a gastric submucosal tumor: A case report
Kwan BS, Cho DH
- 2808** Pancreatitis, panniculitis, and polyarthritis syndrome caused by pancreatic pseudocyst: A case report
Jo S, Song S
- 2815** Glomus tumor of uncertain malignant potential of the brachial plexus: A case report
Thanindrarn P, Chobpenthai T, Phorkhar T, Nelson SD
- 2823** Conservative pulp treatment for Oehlers type III dens invaginatus: A case report
Lee HN, Chen YK, Chen CH, Huang CY, Su YH, Huang YW, Chuang FH
- 2831** Propofol pump controls nonconvulsive status epilepticus in a hepatic encephalopathy patient: A case report
Hor S, Chen CY, Tsai ST
- 2838** Teriparatide as nonoperative treatment for femoral shaft atrophic nonunion: A case report
Tsai MH, Hu CC
- 2843** Successful repair of acute type A aortic dissection during pregnancy at 16th gestational week with maternal and fetal survival: A case report and review of the literature
Chen SW, Zhong YL, Ge YP, Qiao ZY, Li CN, Zhu JM, Sun LZ
- 2851** Inferior pancreaticoduodenal artery pseudoaneurysm in a patient with calculous cholecystitis: A case report
Xu QD, Gu SG, Liang JH, Zheng SD, Lin ZH, Zhang PD, Yan J

- 2857** ALK-positive anaplastic large cell lymphoma of the thoracic spine occurring in pregnancy: A case report
Yang S, Jiang WM, Yang HL
- 2871** Multiple gastric adenocarcinoma of fundic gland type: A case report
Chen O, Shao ZY, Qiu X, Zhang GP
- 2879** Repair of the portal vein using a hepatic ligamentum teres patch for laparoscopic pancreaticoduodenectomy: A case report
Wei Q, Chen QP, Guan QH, Zhu WT
- 2899** Pleomorphic lipoma in the anterior mediastinum: A case report
Mao YQ, Liu XY, Han Y
- 2905** Guillain-Barré syndrome in a patient with multiple myeloma after bortezomib therapy: A case report
Xu YL, Zhao WH, Tang ZY, Li ZQ, Long Y, Cheng P, Luo J
- 2910** Bowen's disease on the palm: A case report
Yu SR, Zhang JZ, Pu XM, Kang XJ

ABOUT COVER

Editorial Board Member of *World Journal of Clinical Cases*, Shao-Ping Yu, MD, Associate Professor, Chief Doctor, Department of Gastroenterology and Hepatology, Dongguan Kanghua Hospital, Dongguan 523080, Guangdong Province, China

AIMS AND SCOPE

The primary aim of *World Journal of Clinical Cases* (*WJCC*, *World J Clin Cases*) is to provide scholars and readers from various fields of clinical medicine with a platform to publish high-quality clinical research articles and communicate their research findings online.

WJCC mainly publishes case reports, case series, and articles reporting research results and findings obtained in the field of clinical medicine and covering a wide range of topics including diagnostic, therapeutic, and preventive modalities.

INDEXING/ABSTRACTING

The *WJCC* is now indexed in PubMed, PubMed Central, Science Citation Index Expanded (also known as SciSearch®), and Journal Citation Reports/Science Edition. The 2019 Edition of Journal Citation Reports cites the 2018 impact factor for *WJCC* as 1.153 (5-year impact factor: N/A), ranking *WJCC* as 99 among 160 journals in Medicine, General and Internal (quartile in category Q3).

RESPONSIBLE EDITORS FOR THIS ISSUE

Responsible Electronic Editor: Ji-Hong Liu

Proofing Production Department Director: Yun-Xiaoqian Wu

NAME OF JOURNAL

World Journal of Clinical Cases

ISSN

ISSN 2307-8960 (online)

LAUNCH DATE

April 16, 2013

FREQUENCY

Semimonthly

EDITORS-IN-CHIEF

Dennis A Bloomfield, Bao-Gan Peng, Sandro Vento

EDITORIAL BOARD MEMBERS

<https://www.wjgnet.com/2307-8960/editorialboard.htm>

EDITORIAL OFFICE

Jin-Lei Wang, Director

PUBLICATION DATE

September 26, 2019

COPYRIGHT

© 2019 Baishideng Publishing Group Inc

INSTRUCTIONS TO AUTHORS

<https://www.wjgnet.com/bpg/gerinfo/204>

GUIDELINES FOR ETHICS DOCUMENTS

<https://www.wjgnet.com/bpg/GerInfo/287>

GUIDELINES FOR NON-NATIVE SPEAKERS OF ENGLISH

<https://www.wjgnet.com/bpg/gerinfo/240>

PUBLICATION MISCONDUCT

<https://www.wjgnet.com/bpg/gerinfo/208>

ARTICLE PROCESSING CHARGE

<https://www.wjgnet.com/bpg/gerinfo/242>

STEPS FOR SUBMITTING MANUSCRIPTS

<https://www.wjgnet.com/bpg/GerInfo/239>

ONLINE SUBMISSION

<https://www.f6publishing.com>

Teriparatide as nonoperative treatment for femoral shaft atrophic nonunion: A case report

Meng-Huan Tsai, Chih-Chien Hu

ORCID number: Meng-Huan Tsai (0000-0002-7614-5076); Chih-Chien Hu (0000-0002-4209-7977).

Author contributions: Tsai MH reviewed the literature and contributed to manuscript drafting; Hu CC was the patient's orthopedic doctor, reviewed the literature and contributed to manuscript drafting.

Informed consent statement: Informed written consent was obtained from the patient for publication of this report and any accompanying images.

Conflict-of-interest statement: The authors declare that they have no conflict of interest.

CARE Checklist (2016) statement: The authors have read the CARE Checklist (2013), and the manuscript was prepared and revised according to the CARE Checklist (2016).

Open-Access: This article is an open-access article which was selected by an in-house editor and fully peer-reviewed by external reviewers. It is distributed in accordance with the Creative Commons Attribution Non Commercial (CC BY-NC 4.0) license, which permits others to distribute, remix, adapt, build upon this work non-commercially, and license their derivative works on different terms, provided the original work is properly cited and the use is non-commercial. See: <http://creativecommons.org/licenses/by-nc/4.0/>

Manuscript source: Unsolicited

Meng-Huan Tsai, College of Medicine, Chang Gung University, Taoyuan 33305, Taiwan

Meng-Huan Tsai, Chih-Chien Hu, Department of Joint Reconstruction, Orthopedic Surgery, Bone and Joint Research Center, Chang Gung Memorial Hospital, Lin-Kou Medical Center, Taoyuan 33305, Taiwan

Corresponding author: Chih-Chien Hu, MD, Assistant Professor, Department of Joint Reconstruction, Orthopedic Surgery, Bone and Joint Research Center, Chang Gung Memorial Hospital, Lin-Kou Medical Center, No. 5, Fu-Hsin St. Kwei-Shan District, Taoyuan 33305, Taiwan. chihchienhu@hotmail.com
Telephone: +886-3-3281200

Abstract

BACKGROUND

Femoral shaft fractures are a common type of fracture among adults and have high union rates. However, clinical decisions are difficult to make because of the different types of nonunions. Atrophic nonunion usually requires revision surgery combined with bone grafting. Furthermore, no study of teriparatide administration for femoral atrophic nonunion have been previously reported.

CASE SUMMARY

A 60-year-old woman had a right femoral shaft fracture due to a traffic accident, and she immediately underwent closed reduction and internal fixation surgery with an intramedullary nailing. However, after 6 mo of rehabilitation, the fracture site showed no signs of healing, and her condition was diagnosed as atrophic nonunion. Subsequently, teriparatide was administered for 6 mo. Complete union was observed at the fracture site 6 mo after teriparatide discontinued.

CONCLUSION

The use of teriparatide can be a promising treatment to improve the healing of nonunion fractures.

Key words: Teriparatide; Nonunion; Femoral fractures; Case report

©The Author(s) 2019. Published by Baishideng Publishing Group Inc. All rights reserved.

Core tip: This is the first report describing the treatment of femoral shaft atrophic nonunion after an operative reduction and internal fixation procedure using only teriparatide administration instead of revision surgery. Our data provides an alternative

manuscript

Received: February 27, 2019**Peer-review started:** February 27, 2019**First decision:** July 30, 2019**Revised:** August 8, 2019**Accepted:** August 25, 2019**Article in press:** August 26, 2019**Published online:** September 26, 2019**P-Reviewer:** Francesco SM, Sahoo J, Yan SL, Vieyra JP**S-Editor:** Dou Y**L-Editor:** Wang TQ**E-Editor:** Qi LL

treatment option for patients with atrophic nonunion.

Citation: Tsai MH, Hu CC. Teriparatide as nonoperative treatment for femoral shaft atrophic nonunion: A case report. *World J Clin Cases* 2019; 7(18): 2838-2842**URL:** <https://www.wjgnet.com/2307-8960/full/v7/i18/2838.htm>**DOI:** <https://dx.doi.org/10.12998/wjcc.v7.i18.2838>

INTRODUCTION

Femoral shaft fractures are some of the most common fractures that account for 5%-6% of long bone fractures in adults. Reamed intramedullary nailing (RIN) is considered the gold standard treatment for femoral shaft fractures^[1]. Union rates as high as 98%-99% have been reported with RIN^[2-4].

The United States Food and Drug Administration (FDA) defines nonunion as a fractured bone that has not completely healed within 9 mo from injury and that has not shown progression towards healing over 3 consecutive months, as determined from serial radiographs^[5]. There are different types of nonunion. Hypertrophic nonunion develops as a result of insufficient mechanical stability and can lead to over-formation of a callus in the area of the fracture. Atrophic nonunion often involves insufficient vascularity of the defect gap and surrounding bone, leading to atrophy of the fracture ends^[6].

The multi-factorial causes of delayed fracture healing warrant a specific therapy for each patient. Consequently, the so-called diamond concept has been established. It is composed of five different factors, including osteoconductive scaffolds, vascularity, growth factors, osteogenic cells, and mechanical environment, all of which must be analyzed for therapy. Based on the diamond concept, the first priority for the management of hypertrophic nonunion is to optimize mechanical stability. In the case of unstable osteosynthesis, re-osteosynthesis is necessary to enhance mechanical stability. Furthermore, re-osteosynthesis and additional biological activation of bone regeneration are often necessary for the treatment of atrophic nonunion^[6,7]. Based on the current gold standard treatment for atrophic nonunion, revision of fixation with osteoconduction (scaffolds and mechanical environment) and osteoinduction (bone grafts, bone morphogenetic protein, and vascularity) is necessary. Nonetheless, we report a patient who was treated with teriparatide, which is a recombinant protein form of parathyroid hormone. It is an effective anabolic agent used in the treatment of some forms of osteoporosis. Teriparatide is also occasionally used off-label to speed fracture healing and has been reported to improve callus volume, mineralization, bone mineral content, rate of successful union, and strength at fracture sites^[8]. Furthermore, teriparatide treatment can aid fracture healing in osteoporotic women and people with atypical femoral fracture^[9,10].

CASE PRESENTATION

Chief complaints

A 60-year-old woman presented to Dr. Hu's clinic of our hospital and complaining of pain in her right lower extremity during weight-bearing.

History of present illness

The patient reported persistent pain for the past 6 mo since the operation in April 2016.

History of past illness

The patient was diagnosed with a right femoral shaft fracture due to a traffic accident, wherein she was the motorbike rider and was hit by a vehicle. She was immediately transported to the emergency room at a local hospital, where the femoral shaft fracture was identified without any other associated injuries; therefore, she underwent surgery consisting of closed reduction and internal fixation with an intramedullary nail (Fixion expandable nail, Disc-O-Tech, Tel Aviv, Israel) in April 2016 (Figure 1A and B).

Personal and family history

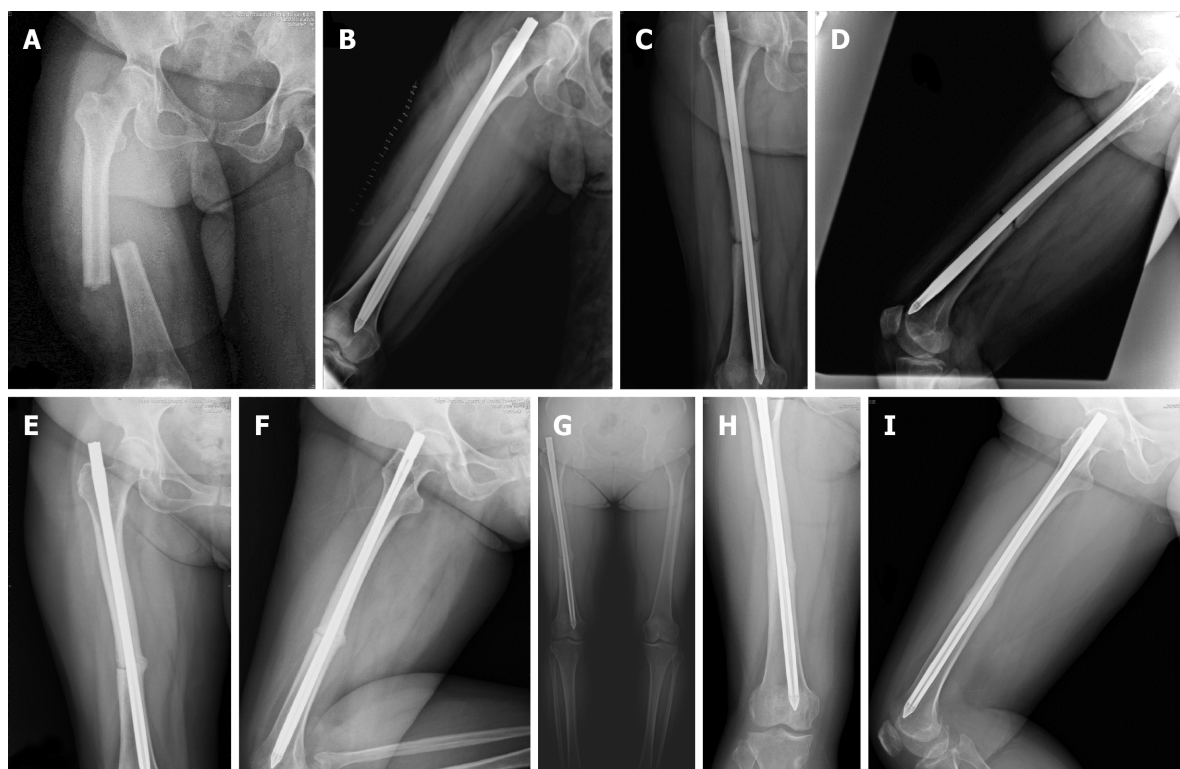


Figure 1 Radiographs of the femur. A: Anteroposterior view. Right femoral shaft fracture, middle third, simple transverse. Date: April/12/2016; B: Lateral view. Status after the closed reduction internal fixation with the Fixion nail. Date: April/13/2016; C: Anteroposterior view, 6 mo postoperatively, one month before the teriparatide treatment. No callus was observed. Date: Oct/20/2016; D: Lateral view. Date: Oct/20/2016; E: Anteroposterior view, 3 mo after teriparatide use. A callus was observed. Date: Feb/21/2017; F: Lateral view. Date: Feb/21/2017; G: Anteroposterior view, 5 mo after teriparatide use. Continuous improvement in fracture gap reduction and bone bridging was observed. Date: April/21/2017; H: Anteroposterior view, 6 mo after the discontinuation of teriparatide. A complete union was observed. Date: Nov/14/2017; I: Lateral view. Date: Nov/14/2017.

The patient had a free personal and family history. She also denied long term medication history or glucocorticoid exposure.

Physical examination

On physical examination, the only positive finding was pain in the right lower extremity during weight-bearing over the middle thigh and buttock.

Laboratory examinations

Laboratory examinations included white blood cell counts, C-reactive protein levels, erythrocyte sedimentation rate, serum alkaline phosphatase, parathyroid hormone, creatinine, albumin-corrected calcium, phosphate, and vitamin D level revealed all within normal range.

Imaging examinations

Radiography was performed 6 mo postoperatively because of the patient's persistent pain in her right lower extremity. The results showed no signs of healing in the fracture sites (Figure 1C and D).

FINAL DIAGNOSIS

The final diagnosis of the presented case was right femoral shaft atrophic nonunion.

TREATMENT

We carefully discussed treatment options with the patient; she refused to undergo further surgery, such as exchange nailing, augmentation plate fixation, or cancellous bone graft augmentation surgery. Instead, consent was given to an empirical therapy with teriparatide at approved doses for the treatment of osteoporosis (20 µg/d), as an attempt to treat the potential osteoporotic change and the atrophic nonunion of the

femur.

OUTCOME AND FOLLOW UP

After three months, X-ray images showed the presence of bone bridges and a decreased fracture gap between fragments. We also noticed that the treatment had increased the bone density at the fracture site (Figure 1E and F).

Five months after the initiation of the teriparatide treatment, radiographs revealed continuous improvements in fracture gap reduction and bone bridging at the circumferential fracture site (Figure 1G). Thus, the teriparatide treatment was discontinued 1 mo later.

Six months after the discontinuation of teriparatide, complete union was obtained, as observed in the radiographs, along with cortical remodeling (Figure 1H and I). The pain experienced by the patient disappeared, and she returned to normal activity, including returning to her job. No side effects attributable to the drug were observed during the treatment course.

DISCUSSION

Nonunion of femoral shaft fractures treated by RIN is uncommon. Union rates as high as 98%-99% have been reported with RIN, which is currently the standard management for closed fractures of the femoral shaft^[2-4].

Nevertheless, some risk factors have been reported to be related to femoral shaft nonunion, including inaccurate reduction, unstable fixation, infection, alcohol abuse, advanced age, smoking, diabetes mellitus, corticosteroid treatment, use of non-steroidal anti-inflammatory drugs, and osteoporosis^[6,11]. However, our patient did not have these risk factors.

Although teriparatide treatment has been reported as a successful treatment option for patients with nonunion of lower extremity fractures, those cases differed from ours in terms of some conditions. First, the patients reported by Lee *et al*^[12], Xiaofeng *et al*^[13] and Yu *et al*^[14] all had some callus formation, as seen in the radiographs; hence, their fractures were classified as hypertrophic nonunions. Furthermore, all of their patients were successfully treated with teriparatide and achieved bone union^[12-14]. Secondly, some patients received revision surgery before teriparatide use. One of the three patients reported by Lee *et al*^[12] underwent a reoperation, in which the original 11-mm diameter nail was exchanged for a larger 13-mm nail. The patient reported by Yu *et al*^[14] underwent another surgery, wherein the original intramedullary nail was exchanged for internal fixation using an anatomical plate together with autogenous bone graft. Two patients from Coppola *et al*^[15] also underwent revision surgery: One patient underwent open reduction, fixation, and stabilization of the fracture with a mono-axial fixator supplemented with Allomatrix (Wright Medical Technology, Inc, Arlington, TN, United States), followed by open reduction and internal fixation with a condylar plate; while the other patient underwent open reduction with RIN. Thirdly, the fracture location of some cases also differed from our case. The case from the study by Giannotti *et al*^[16] was an atrophic nonunion without revision surgery; however, the fracture location was over the distal femoral metaphysis. One of the three patients reported by Lee *et al*^[12] had femoral neck fractures. Two patients from Coppola *et al*^[15] experienced tibia and fibular fractures. Fourthly, the duration of teriparatide use also varied. The reported teriparatide treatments at 20 µg/d for 3-9 mo resulted in successful union in all 10 patients without further surgical intervention. All these reported cases showed adequate bone callus over the nonunion site and achieved clinical evidence of solid union^[12-16].

Compared to these reported cases, our patient had atrophic nonunion of a femoral shaft fracture at 6 mo post-RIN without revision surgery, and was treated with teriparatide at 20 µg/d for 6 mo. This differed from the other previously reported patients with hypertrophic nonunion, revision surgery, femoral metaphyseal, or neck fracture, all with varied durations of teriparatide treatment. Based on the present review and our case, teriparatide is useful for the treatment of atrophic and hypertrophic nonunion with therapy durations ranging from 3 to 9 mo, regardless of whether revision surgery was performed.

The standard treatment for atrophic nonunion due to failed RIN is augmented plating with transplantation of autologous cancellous bone, or reamer-irrigator-aspirator combined with BMPs^[6,17]. Nevertheless, not all cases of nonunion can be treated surgically because of either patient or technical factors. Thus, we reported the use of teriparatide as an alternative treatment to revision surgery for atrophic

nonunion of femoral shaft fractures.

CONCLUSION

Our case demonstrated that atrophic nonunion of simple transverse femoral shaft fracture can be successfully treated with teriparatide for 6 mo, instead of revision surgery. Teriparatide administration can aid in improving the healing of nonunion fractures in patients not willing to undergo surgical intervention. Further well-designed prospective randomized controlled trials with larger patient groups are needed to assess the efficacy of teriparatide for the treatment of patients with nonunion of fractures.

REFERENCES

- 1 **Li AB**, Zhang WJ, Guo WJ, Wang XH, Jin HM, Zhao YM. Reamed versus unreamed intramedullary nailing for the treatment of femoral fractures: A meta-analysis of prospective randomized controlled trials. *Medicine (Baltimore)* 2016; **95**: e4248 [PMID: 27442651 DOI: 10.1097/MD.0000000000004248]
- 2 **Brumback RJ**, Uwagie-Ero S, Lakatos RP, Poka A, Bathon GH, Burgess AR. Intramedullary nailing of femoral shaft fractures. Part II: Fracture-healing with static interlocking fixation. *J Bone Joint Surg Am* 1988; **70**: 1453-1462 [PMID: 3198669 DOI: 10.2106/00004623-198870100-00003]
- 3 **Winquist RA**, Hansen ST, Clawson DK. Closed intramedullary nailing of femoral fractures. A report of five hundred and twenty cases. 1984. *J Bone Joint Surg Am* 2001; **83**: 1912 [PMID: 11741073 DOI: 10.2106/00004623-200112000-00021]
- 4 **Xia L**, Zhou J, Zhang Y, Mei G, Jin D. A meta-analysis of reamed versus unreamed intramedullary nailing for the treatment of closed tibial fractures. *Orthopedics* 2014; **37**: e332-e338 [PMID: 24762836 DOI: 10.3928/01477447-20140401-52]
- 5 **Brinker M**, Bruce D. Nonunions: evaluation and treatment. Browner, Jesse B. Jupiter, Alan M. Levine, Trafton PG editors. Skeletal trauma: basic science, management, and reconstruction. 3 ed. Bruce D. Philadelphia, USA: Saunders; 2003;
- 6 **Moghaddam A**, Ermisch C, Schmidmaier G. Non-union current treatment concept. *Int J Med Educa* 2016; **3** [DOI: 10.17795/soj-4546]
- 7 **Moghaddam A**, Zietzschmann S, Bruckner T, Schmidmaier G. Treatment of atrophic tibia non-unions according to 'diamond concept': Results of one- and two-step treatment. *Injury* 2015; **46** Suppl 4: S39-S50 [PMID: 26542865 DOI: 10.1016/S0020-1383(15)30017-6]
- 8 **Babu S**, Sandiford NA, Vrahas M. Use of Teriparatide to improve fracture healing: What is the evidence? *World J Orthop* 2015; **6**: 457-461 [PMID: 26191492 DOI: 10.5312/wjo.v6.i6.457]
- 9 **Lou S**, Lv H, Wang G, Zhang L, Li M, Li Z, Zhang L, Tang P. The Effect of Teriparatide on Fracture Healing of Osteoporotic Patients: A Meta-Analysis of Randomized Controlled Trials. *Biomed Res Int* 2016; **2016**: 6040379 [PMID: 27429980 DOI: 10.1155/2016/6040379]
- 10 **Im GI**, Lee SH. Effect of Teriparatide on Healing of Atypical Femoral Fractures: A Systemic Review. *J Bone Metab* 2015; **22**: 183-189 [PMID: 26713309 DOI: 10.11005/jbm.2015.22.4.183]
- 11 **Bell A**, Templeman D, Weinlein JC. Nonunion of the Femur and Tibia: An Update. *Orthop Clin North Am* 2016; **47**: 365-375 [PMID: 26772945 DOI: 10.1016/j.ocl.2015.09.010]
- 12 **Lee YK**, Ha YC, Koo KH. Teriparatide, a nonsurgical solution for femoral nonunion? A report of three cases. *Osteoporos Int* 2012; **23**: 2897-2900 [PMID: 23076681 DOI: 10.1007/s00198-012-2172-x]
- 13 **Xiaofeng L**, Daxia X, Yunzhen C. Teriparatide as a nonoperative treatment for tibial and femoral fracture nonunion: A case report. *Medicine (Baltimore)* 2017; **96**: e6571 [PMID: 28422848 DOI: 10.1097/MD.00000000000006571]
- 14 **Yu W**, Guo X. Teriparatide treatment of femoral fracture nonunion that autogenous bone grafting failed to heal: a case report. *Arch Osteoporos* 2017; **12**: 15 [PMID: 28155140 DOI: 10.1007/s11657-017-0311-x]
- 15 **Coppola C**, Del Buono A, Maffulli N. Teriparatide in Fracture Non-Unions. *Transl Med UniSa* 2014; **12**: 47-53 [PMID: 26535187]
- 16 **Giannotti S**, Bottai V, Dell'Osso G, de Paola G, Pini E, Guido G. Atrophic femoral nonunion successfully treated with teriparatide. *Eur J Orthop Surg Traumatol* 2013; **23** Suppl 2: S291-S294 [PMID: 23412268 DOI: 10.1007/s00590-012-1143-4]
- 17 **Somford MP**, van den Bekerom MP, Kloen P. Operative treatment for femoral shaft nonunions, a systematic review of the literature. *Strategies Trauma Limb Reconstr* 2013; **8**: 77-88 [PMID: 23892497 DOI: 10.1007/s11751-013-0168-5]



Published By Baishideng Publishing Group Inc
7041 Koll Center Parkway, Suite 160, Pleasanton, CA 94566, USA
Telephone: +1-925-2238242
E-mail: bpgoffice@wjgnet.com
Help Desk: <https://www.f6publishing.com/helpdesk>
<https://www.wjgnet.com>

