

# World Journal of *Clinical Cases*

*World J Clin Cases* 2019 May 6; 7(9): 1006-1092





### REVIEW

- 1006** Evaluation and management of acute pancreatitis  
*Chatila AT, Bilal M, Guturu P*

### ORIGINAL ARTICLE

#### Retrospective Cohort Study

- 1021** Rituximab-induced IgG hypogammaglobulinemia in children with nephrotic syndrome and normal pre-treatment IgG values  
*Marzuillo P, Guarino S, Esposito T, Di Sessa A, Orsini SI, Capalbo D, Miraglia del Giudice E, La Manna A*

#### Retrospective Study

- 1028** Causes associated with recurrent choledocholithiasis following therapeutic endoscopic retrograde cholangiopancreatography: A large sample sized retrospective study  
*Deng F, Zhou M, Liu PP, Hong JB, Li GH, Zhou XJ, Chen YX*

### CASE REPORT

- 1038** Laparoscopic appendectomy for elemental mercury sequestration in the appendix: A case report  
*Norčič G, Čebren Ž, Sever P, Grosek J, Tomažič A*
- 1043** Sofosbuvir/Ribavirin therapy for patients experiencing failure of ombitasvir/paritaprevir/ritonavir + ribavirin therapy: Two cases report and review of literature  
*Sato K, Yamazaki Y, Kobayashi T, Takakusagi S, Horiguchi N, Kakizaki S, Andou M, Matsuda Y, Uraoka T, Ohnishi H, Okamoto H*
- 1053** Management of the late effects of disconnected pancreatic duct syndrome: A case report  
*Yamada R, Umeda Y, Shiono Y, Okuse H, Kuroda N, Tsuboi J, Inoue H, Hamada Y, Tanaka K, Horiki N, Takei Y*
- 1060** Nerve coblation for treatment of trigeminal neuralgia: A case report  
*Yang XH, Li Y, Yang LQ, Wu BS, Ni JX*
- 1066** Adult-onset mitochondrial encephalopathy in association with the MT-ND3 T10158C mutation exhibits unique characteristics: A case report  
*Fu XL, Zhou XX, Shi Z, Zheng WC*
- 1073** Rare variant of pancreaticobiliary maljunction associated with pancreas divisum in a child diagnosed and treated by endoscopic retrograde cholangiopancreatography: A case report  
*Cui GX, Huang HT, Yang JF, Zhang XF*

- 1080** Crizotinib-induced acute fatal liver failure in an Asian *ALK*-positive lung adenocarcinoma patient with liver metastasis: A case report  
*Zhang Y, Xu YY, Chen Y, Li JN, Wang Y*
- 1087** Coexistence of breakpoint cluster region-Abelson1 rearrangement and Janus kinase 2 V617F mutation in chronic myeloid leukemia: A case report  
*Shi XB, Jiang JF, Jin FX, Cheng W*

**ABOUT COVER**

Editorial Board Member of *World Journal of Clinical Cases*, Wilbert Aronow, MD, Professor, Statistical Worker, Department of Medicine, Dava, J (reprint author), Royal Free Hosp, Dept Cardiol, Carcinoid Heart Dis Clin, Pond St, London NW3 2QG, England., Valhalla, NY 10595, United States

**AIMS AND SCOPE**

*World Journal of Clinical Cases* (*World J Clin Cases*, *WJCC*, online ISSN 2307-8960, DOI: 10.12998) is a peer-reviewed open access academic journal that aims to guide clinical practice and improve diagnostic and therapeutic skills of clinicians.

The primary task of *WJCC* is to rapidly publish high-quality Case Report, Clinical Management, Editorial, Field of Vision, Frontier, Medical Ethics, Original Articles, Meta-Analysis, Minireviews, and Review, in the fields of allergy, anesthesiology, cardiac medicine, clinical genetics, clinical neurology, critical care, dentistry, dermatology, emergency medicine, endocrinology, family medicine, gastroenterology and hepatology, etc.

**INDEXING/ABSTRACTING**

The *WJCC* is now indexed in PubMed, PubMed Central, Science Citation Index Expanded (also known as SciSearch®), and Journal Citation Reports/Science Edition. The 2018 Edition of Journal Citation Reports cites the 2017 impact factor for *WJCC* as 1.931 (5-year impact factor: N/A), ranking *WJCC* as 60 among 154 journals in Medicine, General and Internal (quartile in category Q2).

**RESPONSIBLE EDITORS  
FOR THIS ISSUE**

Responsible Electronic Editor: Yun-Xiaojuan Wu Proofing Editorial Office Director: Jin-Lei Wang

**NAME OF JOURNAL**

*World Journal of Clinical Cases*

**ISSN**

ISSN 2307-8960 (online)

**LAUNCH DATE**

April 16, 2013

**FREQUENCY**

Semimonthly

**EDITORS-IN-CHIEF**

Dennis A Bloomfield, Sandro Vento

**EDITORIAL BOARD MEMBERS**

<https://www.wjgnet.com/2307-8960/editorialboard.htm>

**EDITORIAL OFFICE**

Jin-Lei Wang, Director

**PUBLICATION DATE**

May 6, 2019

**COPYRIGHT**

© 2019 Baishideng Publishing Group Inc

**INSTRUCTIONS TO AUTHORS**

<https://www.wjgnet.com/bpg/gerinfo/204>

**GUIDELINES FOR ETHICS DOCUMENTS**

<https://www.wjgnet.com/bpg/GerInfo/287>

**GUIDELINES FOR NON-NATIVE SPEAKERS OF ENGLISH**

<https://www.wjgnet.com/bpg/gerinfo/240>

**PUBLICATION MISCONDUCT**

<https://www.wjgnet.com/bpg/gerinfo/208>

**ARTICLE PROCESSING CHARGE**

<https://www.wjgnet.com/bpg/gerinfo/242>

**STEPS FOR SUBMITTING MANUSCRIPTS**

<https://www.wjgnet.com/bpg/GerInfo/239>

**ONLINE SUBMISSION**

<https://www.f6publishing.com>

# Adult-onset mitochondrial encephalopathy in association with the MT-ND3 T10158C mutation exhibits unique characteristics: A case report

Xiao-Li Fu, Xiang-Xue Zhou, Zhu Shi, Wei-Cheng Zheng

**ORCID number:** Xiao-Li Fu (0000-0001-9925-5182); Xiang-Xue Zhou (0000-0002-1267-8527); Zhu Shi (0000-0002-6677-3271); Wei-Cheng Zheng (0000-0002-4241-7520).

**Author contributions:** Fu XL, Zhou XX, Shi Z, and Zheng WC contributed to the acquisition of data, and writing and revision of this manuscript.

**Supported by** the Socioeconomic Development Project of Dongguan Science and Technology Bureau, No. 2016108101002.

**Informed consent statement:** The patient and her family members provided written informed consent.

**Conflict-of-interest statement:** All the authors declare no conflict of interest with this publication.

**CARE Checklist (2016) statement:** The authors have read the CARE Checklist (2016), and the manuscript was prepared and revised according to the CARE Checklist (2016).

**Open-Access:** This article is an open-access article which was selected by an in-house editor and fully peer-reviewed by external reviewers. It is distributed in accordance with the Creative Commons Attribution Non Commercial (CC BY-NC 4.0) license, which permits others to distribute, remix, adapt, build upon this work non-commercially, and license their derivative works on different terms, provided the

**Xiao-Li Fu, Zhu Shi, Wei-Cheng Zheng,** Department of Neurology, Dongguan Peoples' Hospital, Dongguan 523059, Guangdong Province, China

**Xiang-Xue Zhou,** Department of Neurology, First Affiliated Hospital, Sun Yat-sen University, Guangzhou 510080, Guangdong Province, China

**Corresponding author:** Zhu Shi, MD, PhD, Director, Professor, Deputy Director, Department of Neurology, Dongguan People's Hospital, No. 2, Wandaolu South Avenue, Dongguan 523059, Guangdong Province, China. [sound\\_shi@126.com](mailto:sound_shi@126.com)

**Telephone:** +86-769-22679351

**Fax:** +86-769-2222235

## Abstract

### BACKGROUND

Mitochondrial diseases are a heterogeneous group of multisystemic disorders caused by genetic mutations affecting mitochondrial oxidation function. Brain involvement is commonly found in most cases but rarely as the unique clinical manifestation. Since the knowledge of its clinical manifestation combined with genetic testing is important for preventing misdiagnosis and delay in treatment, we report here how we diagnosed and managed a very unusual case of mitochondrial encephalopathy.

### CASE SUMMARY

We report a 52-year-old woman with recurrent stroke-like episodes carrying the m.10158T>C mutation in the MT-ND3 gene, which is also responsible for fatal infant-onset Leigh syndrome. Despite the common mutation, the present case featured a distinct clinical and neuroimaging manifestation from Leigh syndrome. This patient presented with sudden onset of right-sided hemiparesis and hemilateral sensory disturbance accompanied by a left temporal cluster-like headache and later developed epilepsy during hospitalization, with no other signs suggestive of myopathy, lactate acidosis, or other systemic symptoms. Brain magnetic resonance imaging revealed variable lesions involving multiple cortical and subcortical regions. Furthermore, a negative genetic test obtained from peripheral blood delayed the diagnosis of mitochondrial disease, which was eventually established through second-generation DNA sequencing using biopsied muscle.

### CONCLUSION



original work is properly cited and the use is non-commercial. See: <http://creativecommons.org/licenses/by-nc/4.0/>

**Manuscript source:** Unsolicited manuscript

**Received:** January 3, 2019

**Peer-review started:** January 4, 2019

**First decision:** January 26, 2019

**Revised:** February 21, 2019

**Accepted:** March 26, 2019

**Article in press:** March 26, 2019

**Published online:** May 6, 2019

**P-Reviewer:** Razek AAKA

**S-Editor:** Wang JL

**L-Editor:** Wang TQ

**E-Editor:** Wu YXJ



Based on this report, we suggest that clinicians pursue proper genetic testing for patients when the clinical phenotype is suggestive of mitochondrial diseases.

**Key words:** Mitochondrial disease; Stroke-like episode; Magnetic resonance; diagnosis; Case report

©The Author(s) 2019. Published by Baishideng Publishing Group Inc. All rights reserved.

**Core tip:** An adult-onset stroke-like episode combined with a distinctive magnetic resonance imaging finding serves as a key diagnostic feature indicating mitochondrial disease. A negative peripheral blood genetic test does not necessarily exclude mitochondrial disease, and muscle biopsy is necessary, even with a lack of muscular symptoms.

**Citation:** Fu XL, Zhou XX, Shi Z, Zheng WC. Adult-onset mitochondrial encephalopathy in association with the *MT-ND3* T10158C mutation exhibits unique characteristics: A case report. *World J Clin Cases* 2019; 7(9): 1066-1072

**URL:** <https://www.wjnet.com/2307-8960/full/v7/i9/1066.htm>

**DOI:** <https://dx.doi.org/10.12998/wjcc.v7.i9.1066>

## INTRODUCTION

Diagnosis of mitochondrial disease is challenging. Symptoms such as a stroke-like episode, lactic acidosis, deafness, diabetes mellitus, short stature, and myopathy, often with a family history showing maternal inheritance, are the most common characteristics of a mitochondrial disease. Additionally, a stroke-like episode often occurs in childhood or adolescence. Nonetheless, a diagnosis of mitochondrial diseases in patients with adult onset is often delayed due to a lack of family history, atypical manifestations, and limited resources for functional, pathologic, and/or genetic testing in routine clinical practice<sup>[1]</sup>. We report an adult-onset patient with mitochondrial encephalopathy carrying the m.10158T >C mutation in the *MT-ND3* gene. The encephalopathy manifested as isolated recurrent stroke-like episodes without clinical myopathy or other organ dysfunction. In this paper, we focus on how we diagnosed this case and the distinct feature of the brain magnetic resonance imaging (MRI), which is important for preventing misdiagnosis and delay in treatment. Additionally, we summarize the clinical implications of such cases with this mutation.

## CASE PRESENTATION

### Chief complaints

A 52-year-old female presented with a sudden onset of right-sided numbness and weakness that was accompanied by a left temporal cluster-like headache. No fever or prodromal infection was found at disease onset.

### Personal and family history

The family and personal history was unremarkable.

### Physical examination upon admission

On physical examination, the height and weight of the patient were 154 cm and 56 kg, respectively. Vital signs were normal, as were heart, lung and abdominal examinations. Neurological examination showed intact mental status, with normal speech and comprehension. Mild 4/5 right-sided hemiparesis was present with normal tone in both the arm and leg, though no other focal neurological deficits were found. After admission, she complained of discomfort and tingling in the right leg, after which a generalized tonic-clonic seizure for 3 min occurred before it was stopped by a bolus of intravenous diazepam.

### Laboratory examinations

Laboratory tests, including D-dimer, lactic acid, and serum autoantibody levels, as

well as thyroid function and tumor markers indicated no apparent abnormalities. Glucose tolerance and lactic acid movement tolerance tests were normal. A lumbar puncture was performed, and her open intracranial pressure was 180 mm H<sub>2</sub>O. Cerebrospinal fluid (CSF) testing showed that cell counts and protein, glucose, chloride, monoclonal antibody, adenosine deaminase, and lactate dehydrogenase levels were within normal ranges.

### **Imaging examinations and history of present illness**

MRI demonstrated a lamellar left parietal lobe lesion predominantly involving the cortex, with hyperintensity on both diffusion-weighted imaging and fluid-attenuated inversion recovery (Figure 1). The apparent diffusion coefficient map revealed a preserved, isointense signal. No abnormalities were found by susceptibility weighted imaging or magnetic resonance angiography and venography (Figure 1). Due to the stroke-like onset pattern and MRI features, further thrombophilia screening was performed and showed decreased protein S activity. A diagnosis of cortical venous thrombosis was first proposed. Mitochondrial encephalomyopathy, lactic acidosis, and stroke-like episodes (MELAS) was also considered but temporarily excluded because of the incomplete manifestation and lack of genetic evidence. Anticoagulation therapy was initiated, and follow-up was performed to maintain the international normalized ratio (INR) within the target range.

Two months later, the patient was readmitted for subacute cognitive impairment. She was unable to identify and communicate with family members; she also had difficulty understanding questions or instructions and instead responded by repeating the word "nothing". During hospitalization, a secondary generalized seizure occurred, initially with eyes gazing to the right and then convulsion developing, which lasted for approximately 10 s before self-alleviation. Neurological examination suggested transcortical sensory aphasia, with fully covered limb strength. Blood tests and CSF examination were normal; INR was 2.21. On repeated MRI, new lesions were identified in the left temporal lobe and were also detected 10 days later in the right temporal lobe on radiological follow-up (Figures 1 and 2). Although the MRI signal characteristics are consistent with the initial findings, the original lesion in the left parietal lobe had been alleviated, with cortical atrophy. We further conducted magnetic resonance spectroscopy (MRS), which revealed markedly elevated lactate (Lac) concentrations in the regions of interest in the left temporal lesion (Figure 1). Mitochondrial encephalopathy was diagnosed, and genetic testing using peripheral blood was performed. However, DNA testing for frequent MELAS and myoclonic epilepsy with ragged red fibers syndrome mutations were negative. Because of the lack of symptoms of muscle weakness or pain, the patient declined our suggestion of performing a muscle biopsy. Anticoagulation therapy was terminated, and levetiracetam (1000 mg/d) was administered.

At 3 mo after her second admission, the patient was experiencing involuntary movement in her left limbs, with repetitive flexion/extension. An MRI scan showed a hyperintense signal abnormality in the right parietal lobe (Figure 2). Brachial biceps biopsy was performed. Histopathology revealed no abnormalities, and no necrotic or regenerating fibers were observed; ragged-red fibers and intense succinate dehydrogenase activity were not detected. Nonetheless, complete sequencing of mitochondrial DNA samples extracted from the biopsied muscle revealed a heteroplasmic m.10158T>C mutation, with a heteroplasmy level of 69.6%, in the mitochondrial complex I subunit gene *MT-ND3*. In contrast, this mutation was not found in her peripheral blood cells.

---

## **FINAL DIAGNOSIS**

---

The diagnosis was MELAS syndrome harboring the m.10158T>C mutation.

---

## **TREATMENT**

---

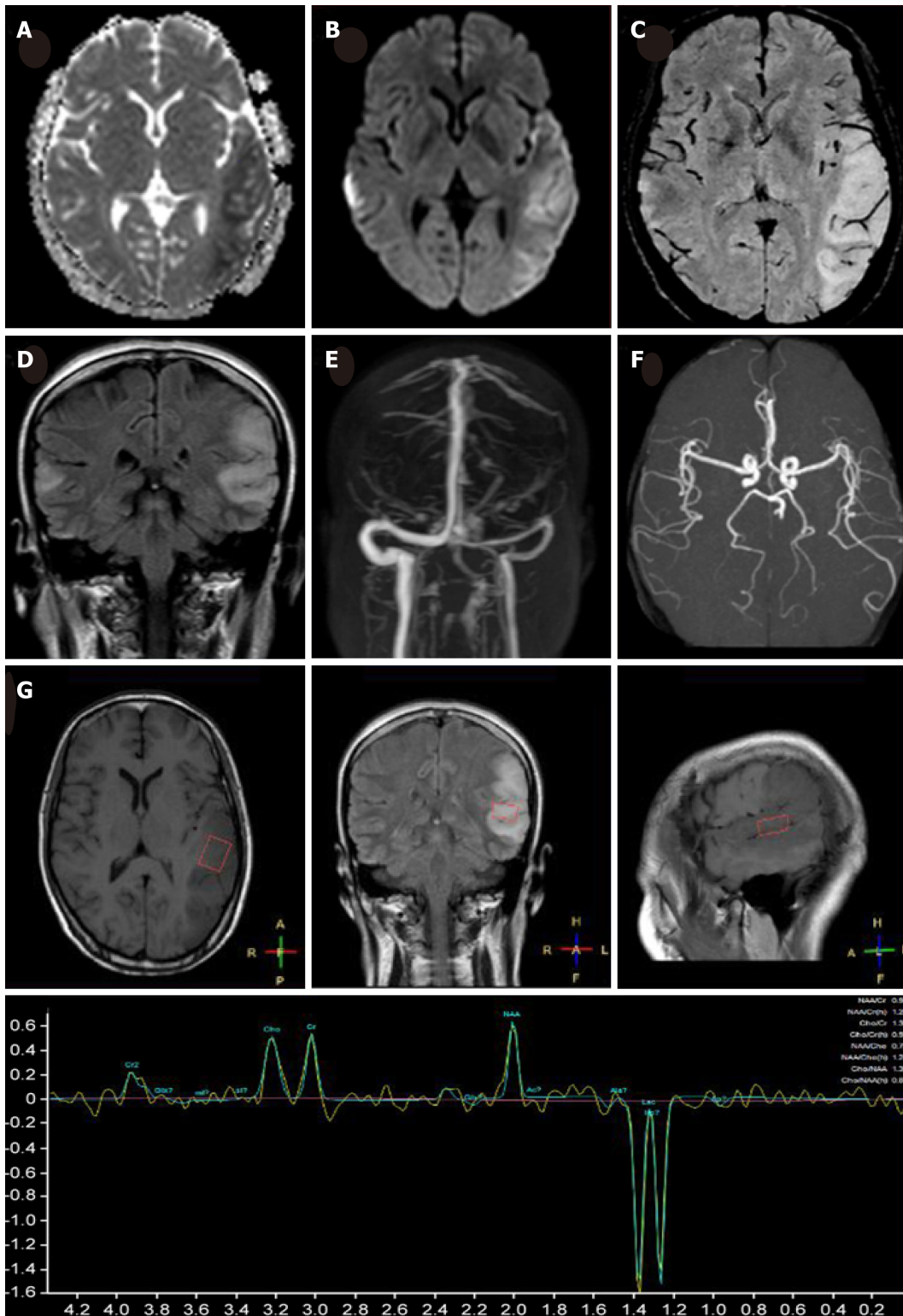
We administered levetiracetam (1000 mg/d) and oxcarbazepine (400 mg/d) to control epilepsy. Q10 and L-arginine were also administered.

---

## **OUTCOME AND FOLLOW-UP**

---

Over the next 6 mo, the present patient did not manifest any further stroke-like episodes.

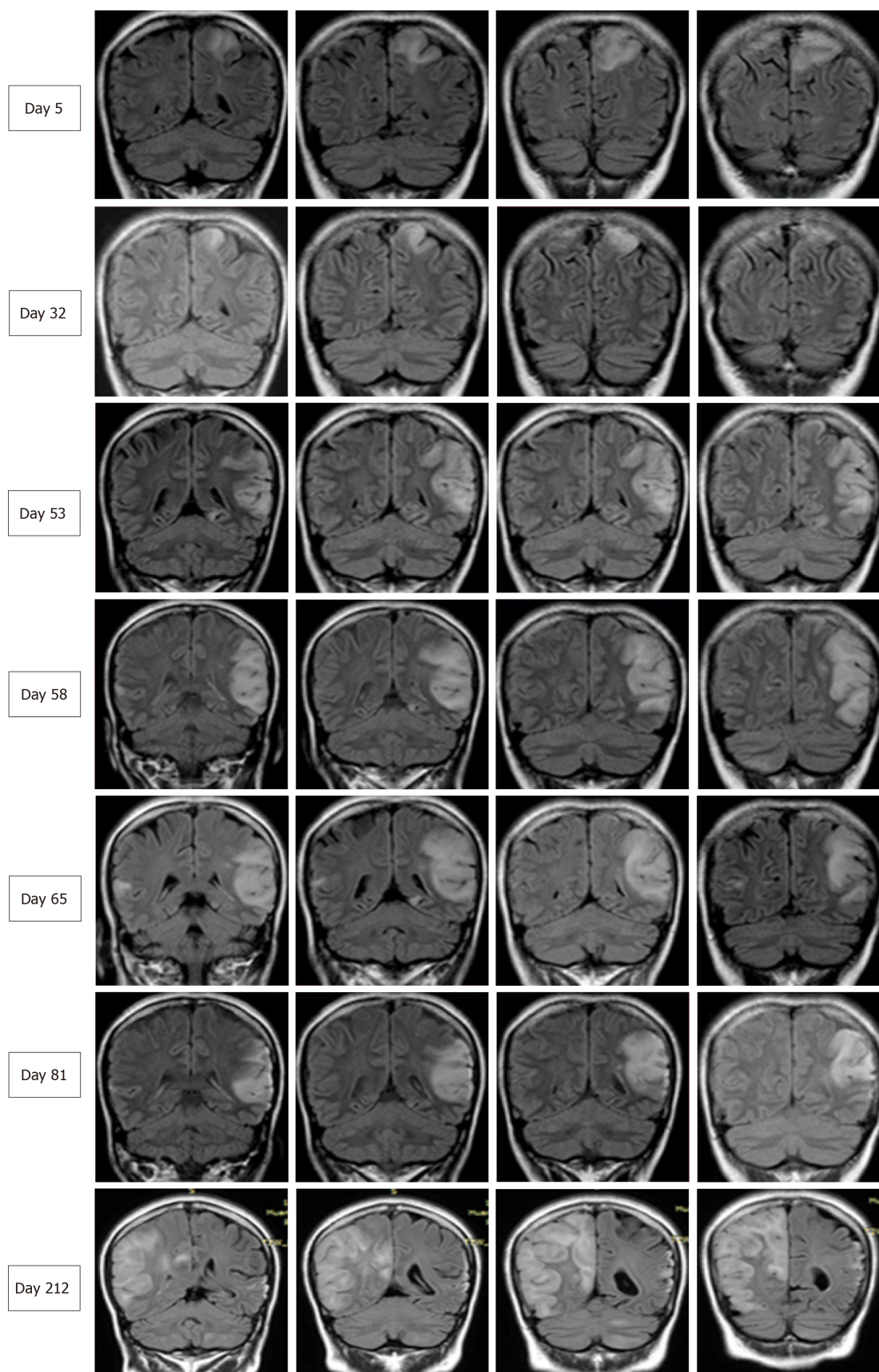


**Figure 1** Magnetic resonance imaging of the present patient during her second hospitalization. Axial brain magnetic resonance imaging showed marked hyperintensity on diffusion-weighted imaging (A), slight hypointensity on apparent diffusion coefficient maps (B) in the bilateral temporal cortical regions, predominantly on the left side, with hyperintensity in the corresponding region on coronal fluid-attenuated inversion recovery (D). No hypointensity of dilated intrasulcal venous structures was observed on susceptibility weighted imaging (C), and no abnormalities were observed on magnetic resonance angiography (E) or magnetic resonance venography (F). Magnetic resonance spectroscopy revealed an inverted lactate (Lac) doublet in the subcortical region of the left temporal lesion (G).

## DISCUSSION

We herein report a case of adult-onset mitochondrial encephalopathy, whereby the patient was admitted three times for similar stroke-like episodes before the definitive diagnosis was confirmed. Despite highly suggestive MRI features of MELAS syndrome, the diagnosis of mitochondrial encephalopathy was delayed due to the





**Figure 2** Serial brain images covering three recurrent stroke-like episodes in the present patient over a 7-mo period. Four representative coronal slices were serially shown in chronological order. Fluid-attenuated inversion recovery images on days 5, 32, 58, 65, 81, and 212 revealed hyperintensity signals appearing recurrently in various cortical and subcortical areas, mainly in the parietal and temporal lobes, and the progressive development of cortical atrophy.

following reasons: (1) Lack of family history showing maternal inheritance; (2) Isolated symptoms of CNS impairment, without myopathy, lactic acidosis, or other

systemic disorders; and (3) Negative mitochondrial genetic testing using peripheral blood. Although muscle biopsy revealed no abnormality, genetic testing using the biopsied muscle demonstrated a 69.6% heterozygous T10158C mutation in the *MT-ND3* gene.

Although MELAS is not uncommon in clinical practice, its diagnosis may be challenging because the clinical symptoms are highly variable and genetic findings may be absent. Our patient presented with a headache, seizure, and acute focal lesion observed by MRI, which fit the diagnostic criteria of supportive MELAS by Yatsuga *et al.*<sup>[2]</sup>. Although her level of lactic acid in blood was normal, the presence of an inverted lactate peak was detected in the temporal cortex by MRS, which is a useful tool to detect metabolic dysfunction in the brain<sup>[3]</sup>. Additionally, despite no obvious myopathy, the biopsied muscle showed a 69.6% heteroplasmic mutation, T10158C, in the *MT-ND3* gene.

The *MT-ND3* protein is a structural component of multimeric enzyme complex I of the mitochondrial respiratory chain, which drives ATP generation in mitochondria<sup>[4]</sup>. The *MT-ND3* T10158C mutation, which is located in the coding region of the loop domain of the ND3 subunit protein, has been identified in infants and pediatric patients with Leigh syndrome or Leigh-like disease<sup>[5]</sup>. However, the manifestation of late-onset stroke-like encephalopathy similar to MELAS in our patient harboring the *MT-ND3* T10158C mutation highlights the complicated genotype-phenotype relationship in mitochondrial diseases. In a literature review, we found four similar cases of *MT-ND3* T10158C mutation (in muscle)<sup>[6,7]</sup>, and all of these patients presented with adult-onset, isolated involvement of the central nervous system. Moreover, MRI revealed similar features among these five patients, with lesions predominately in the posterior cortex of the supratentorial region; in contrast, MRI typically shows involvement of the basal ganglia, brainstem, and cerebellum in Leigh syndrome. Thus, adult-onset patients harboring the *MT-ND3* T10158C mutation may exhibit unique clinical features. Although no myopathy symptoms were observed in any of these cases and genetic testing using peripheral blood was negative, muscle specimens should be obtained to establish a definitive diagnosis. This may be explained by heteroplasmic mtDNA mutations in various tissues, in which case, the mutation load in muscles is higher than that in blood<sup>[8]</sup>.

## CONCLUSION

Adult-onset mitochondrial encephalopathy in the presence of the *MT-ND3* T10158C mutation shows unique clinical characteristics. Despite a lack of lactic acidosis, myopathy, or other clinical implications, the diagnosis of MELAS needs to be considered for adult-onset patients with a stroke-like episode of encephalopathy. Due to the heteroplasmic mutation load, a negative genetic test obtained when using peripheral blood does not necessarily exclude the diagnosis of mitochondrial disease, and next-generation DNA sequencing using biopsied muscle should be considered.

## REFERENCES

- 1 Grier J, Hirano M, Karaa A, Shepard E, Thompson JLP. Diagnostic odyssey of patients with mitochondrial disease: Results of a survey. *Neurol Genet* 2018; 4: e230 [PMID: 29600276 DOI: 10.1212/NXG.0000000000000230]
- 2 Yatsuga S, Povalko N, Nishioka J, Katayama K, Kakimoto N, Matsuishi T, Kakuma T, Koga Y, Taro Matsuoka for MELAS Study Group in Japan. MELAS: a nationwide prospective cohort study of 96 patients in Japan. *Biochim Biophys Acta* 2012; 1820: 619-624 [PMID: 21443929 DOI: 10.1016/j.bbagen.2011.03.015]
- 3 El-Mewafy ZMH, Razek AAKA, El-Eshrawy MM, El-Eneen NRA, El-Biaomy AAB. Magnetic resonance spectroscopy of the frontal region in patients with metabolic syndrome: correlation with anthropometric measurement. *Pol J Radiol* 2018; 83: e215-e219 [PMID: 30627238 DOI: 10.5114/pjr.2018.76024]
- 4 Galkin A, Meyer B, Wittig I, Karas M, Schägger H, Vinogradov A, Brandt U. Identification of the mitochondrial ND3 subunit as a structural component involved in the active/deactive enzyme transition of respiratory complex I. *J Biol Chem* 2008; 283: 20907-20913 [PMID: 18502755 DOI: 10.1074/jbc.M803190200]
- 5 Bugiani M, Invernizzi F, Alberio S, Briem E, Lamantea E, Carrara F, Moroni I, Farina L, Spada M, Donati MA, Uziel G, Zeviani M. Clinical and molecular findings in children with complex I deficiency. *Biochim Biophys Acta* 2004; 1659: 136-147 [PMID: 15576045 DOI: 10.1016/j.bbabo.2004.09.006]
- 6 Mukai M, Nagata E, Mizuma A, Yamano M, Sugaya K, Nishino I, Goto YI, Takizawa S. Adult-onset Mitochondrial Myopathy, Encephalopathy, Lactic Acidosis, and Stroke (MELAS)-like Encephalopathy Diagnosed Based on the Complete Sequencing of Mitochondrial DNA Extracted from Biopsied Muscle without any Myopathic Changes. *Intern Med* 2017; 56: 95-99 [PMID: 28050007 DOI: 10.2169/intermedicine.56.7301]
- 7 Mezuki S, Fukuda K, Matsushita T, Fukushima Y, Matsuo R, Goto YI, Yasukawa T, Uchiumi T, Kang D,

- Kitazono T, Ago T. Isolated and repeated stroke-like episodes in a middle-aged man with a mitochondrial ND3 T10158C mutation: a case report. *BMC Neurol* 2017; **17**: 217 [PMID: [29237403](#) DOI: [10.1186/s12883-017-1001-4](#)]
- 8 **Rossignol R**, Faustin B, Rocher C, Malgat M, Mazat JP, Letellier T. Mitochondrial threshold effects. *Biochem J* 2003; **370**: 751-762 [PMID: [12467494](#) DOI: [10.1042/BJ20021594](#)]



Published By Baishideng Publishing Group Inc  
7041 Koll Center Parkway, Suite 160, Pleasanton, CA 94566, USA  
Telephone: +1-925-2238242  
Fax: +1-925-2238243  
E-mail: [bpgoffice@wjgnet.com](mailto:bpgoffice@wjgnet.com)  
Help Desk: <https://www.f6publishing.com/helpdesk>  
<https://www.wjgnet.com>

