

# World Journal of *Cardiology*

*World J Cardiol* 2019 August 26; 11(8): 195-212



**EDITORIAL**

- 195** Cardiovascular magnetic resonance: Stressing the future  
*Merinopoulos I, Gunawardena T, Eccleshall SC, Vassiliou VS*

**ORIGINAL ARTICLE****Retrospective Study**

- 200** One-year outcomes of a NeoHexa sirolimus-eluting coronary stent system with a biodegradable polymer in all-comers coronary artery disease patients: Results from NeoRegistry in India  
*Jambunathan R, Basavanna D, Vani P, Neuss M, Janbandhu P*

**CASE REPORT**

- 209** Successful minimal approach transcatheter aortic valve replacement in an allograft heart recipient 19 years post transplantation for severe aortic stenosis: A case report  
*Avula S, Munjee S, Barzallo MA*

**ABOUT COVER**

Editorial Board of *World Journal of Cardiology*, Alexander Weymann, MD, PhD, Associate Professor, Consultant Cardiac Surgeon, Department of Cardiac Surgery, University Hospital Oldenburg, Oldenburg 26133, Germany

**AIMS AND SCOPE**

*World Journal of Cardiology* (*World J Cardiol*, *WJC*, online ISSN 1949-8462, DOI: 10.4330) is a peer-reviewed open access journal that aims to guide clinical practice and improve diagnostic and therapeutic skills of clinicians.

The *WJC* covers topics concerning arrhythmia, heart failure, vascular disease, stroke, hypertension, prevention and epidemiology, dyslipidemia and metabolic disorders, cardiac imaging, pediatrics, etc. Priority publication will be given to articles concerning diagnosis and treatment of cardiology diseases. The following aspects are covered: Clinical diagnosis, laboratory diagnosis, differential diagnosis, imaging tests, pathological diagnosis, molecular biological diagnosis, immunological diagnosis, genetic diagnosis, etc. We encourage authors to submit their manuscripts to *WJC*.

We will give priority to manuscripts that are supported by major national and international foundations and those that are of great basic and clinical significance.

**INDEXING/ABSTRACTING**

The *WJC* is now abstracted and indexed in Emerging Sources Citation Index (Web of Science), PubMed, PubMed Central, Scopus, China National Knowledge Infrastructure (CNKI), China Science and Technology Journal Database (CSTJ), and Superstar Journals Database.

**RESPONSIBLE EDITORS FOR THIS ISSUE**

Responsible Electronic Editor: Bao-Xia Zhou

Proofing Production Department Director: Yun-Xiao Jian Wu

**NAME OF JOURNAL**

*World Journal of Cardiology*

**ISSN**

ISSN 1949-8462 (online)

**LAUNCH DATE**

December 31, 2009

**FREQUENCY**

Monthly

**EDITORS-IN-CHIEF**

Marco Matteo Ciccone, Ramdas G Pai, Dimitrios Tousoulis

**EDITORIAL BOARD MEMBERS**

<https://www.wjnet.com/1949-8462/editorialboard.htm>

**EDITORIAL OFFICE**

Jin-Lei Wang, Director

**PUBLICATION DATE**

August 26, 2019

**COPYRIGHT**

© 2019 Baishideng Publishing Group Inc

**INSTRUCTIONS TO AUTHORS**

<https://www.wjnet.com/bpg/gerinfo/204>

**GUIDELINES FOR ETHICS DOCUMENTS**

<https://www.wjnet.com/bpg/GerInfo/287>

**GUIDELINES FOR NON-NATIVE SPEAKERS OF ENGLISH**

<https://www.wjnet.com/bpg/gerinfo/240>

**PUBLICATION MISCONDUCT**

<https://www.wjnet.com/bpg/gerinfo/208>

**ARTICLE PROCESSING CHARGE**

<https://www.wjnet.com/bpg/gerinfo/242>

**STEPS FOR SUBMITTING MANUSCRIPTS**

<https://www.wjnet.com/bpg/GerInfo/239>

**ONLINE SUBMISSION**

<https://www.f6publishing.com>

# Successful minimal approach transcatheter aortic valve replacement in an allograft heart recipient 19 years post transplantation for severe aortic stenosis: A case report

Sravani Avula, Sudhir Mungee, Marco A Barzallo

**ORCID number:** Sravani Avula (0000-0001-9371-2426); Sudhir Mungee (0000-0003-3753-7701); Marco A Barzallo (0000-0003-4149-357X).

**Author contributions:** Avula S, Mungee S and Barzallo MA contributed equally to this work.

**Informed consent statement:** Informed consent to publish was obtained from the patient.

**Conflict-of-interest statement:** All the authors of this article declare that there is no conflict of interest regarding the publication of this article.

**CARE Checklist (2016) statement:** The authors have read the CARE Checklist (2016), and the manuscript was prepared and revised according to the CARE Checklist (2016).

**Open-Access:** This article is an open-access article which was selected by an in-house editor and fully peer-reviewed by external reviewers. It is distributed in accordance with the Creative Commons Attribution Non Commercial (CC BY-NC 4.0) license, which permits others to distribute, remix, adapt, build upon this work non-commercially, and license their derivative works on different terms, provided the original work is properly cited and the use is non-commercial. See: <http://creativecommons.org/licenses/by-nc/4.0/>

**Manuscript source:** Unsolicited

**Sravani Avula, Sudhir Mungee,** Department of Cardiovascular Medicine, University of Illinois College of Medicine at Peoria, Peoria, IL 61637, United States

**Marco A Barzallo,** Key Clinical Faculty, Department of Cardiovascular Medicine, University of Illinois College of Medicine at Peoria, Peoria, IL 61637, United States

**Corresponding author:** Sravani Avula, MD, Cardiology Fellow, Division of Cardiology, Department of Internal Medicine, University of Illinois College of Medicine at Peoria, 530 NE Glen Oak Ave, Peoria, IL 61637, United States. [sravani.avula@osfhealthcare.org](mailto:sravani.avula@osfhealthcare.org)  
**Telephone:** +1-309-6557257

## Abstract

### BACKGROUND

Aortic stenosis is one of the rare valvular complications in a transplanted heart. Over the past 8 years, transcatheter approach for aortic valve replacement (TAVR) has been slowly evolving to be the preferred approach in these patient population when compared to the surgical approach. We report a second case in the United States with successful transfemoral minimal approach with minimal sedation for TAVR in a heart transplant recipient 19 years post transplantation for severe symptomatic calcified aortic stenosis.

### CASE SUMMARY

We present a case of 73-year-old male who has undergone successful minimal approach transcatheter aortic valve replacement in an allograft heart. Patient had received orthotopic heart transplantation 19 years ago for non-ischemic cardiomyopathy. Follow up transthoracic echocardiograms as per routine protocol did not show any aortic valve disease until 15 years post transplantation. Aortic valve was noted to be mildly sclerotic at that time and gradually progressed to severe symptomatic aortic stenosis over the next 4 years. Patient had complaints of worsening shortness of breath that limited his functional capacity. Overall his post heart transplantation period has been mostly uneventful except for allograft non occlusive vasculopathy and aortic stenosis. His Society of Thoracic Surgery risk score was 12.205% and he was considered to be a high-risk surgical candidate by surgeon. Decision was made to undergo transcatheter aortic valve replacement.

### CONCLUSION

With the improved survival of these patients, we think it is time to look into

manuscript

**Received:** January 18, 2019

**Peer-review started:** January 18, 2019

**First decision:** January 26, 2019

**Revised:** August 2, 2019

**Accepted:** August 6, 2019

**Article in press:** August 7, 2019

**Published online:** August 26, 2019

**P-Reviewer:** Kaypakli O, Erkut B

**S-Editor:** Dou Y

**L-Editor:** A

**E-Editor:** Zhou BX



pathophysiology of valvular disease in transplant heart recipients. Some other unanswered questions include, underlying donor and recipient risk factors for valvular diseases in heart transplant recipients.

**Key words:** Transcatheter aortic valve replacement; Heart transplant; Minimal approach valve replacement; Severe aortic stenosis; Case report

©The Author(s) 2019. Published by Baishideng Publishing Group Inc. All rights reserved.

**Core tip:** We report a second case in the United States with successful transfemoral minimal approach with minimal sedation for transcatheter approach for aortic valve replacement in a heart transplant recipient. We believe, with the increase of number of reported cases with valvular diseases in heart transplant patients, it is time for further research in valvular disease in allograft heart recipients.

**Citation:** Avula S, Mungee S, Barzallo MA. Successful minimal approach transcatheter aortic valve replacement in an allograft heart recipient 19 years post transplantation for severe aortic stenosis: A case report. *World J Cardiol* 2019; 11(8): 209-212

**URL:** <https://www.wjnet.com/1949-8462/full/v11/i8/209.htm>

**DOI:** <https://dx.doi.org/10.4330/wjc.v11.i8.209>

## INTRODUCTION

The survival of heart transplant recipients has significantly improved over the past few decades with advanced surgical techniques and immunosuppressive therapies. Valvular diseases like aortic stenosis is seen as one of the late complications in cardiac allograft recipients given improved long-term survival in these patient population<sup>[1-3]</sup>. Aortic valve replacement through median or partial sternotomy has been considered to be the standard treatment of choice<sup>[4-6]</sup>. Over the past decade transcatheter aortic valve replacement has been evolving given that it is less invasive in these high risk transplant recipients<sup>[6-10]</sup>. On review of literature, only 6 case reports have been reported thus far, of which one has been reported in the United States<sup>[2,7]</sup>. Most of the case reports comment only on immediate post-operative outcomes.

## CASE PRESENTATION

### Chief complaints

Progressive shortness of breath.

### History of present illness

A 73-year-old male with history of hypertension, orthotopic heart transplantation 19 years ago has been followed closely for symptoms of worsening shortness of breath in the setting of severe aortic stenosis. His functional capacity has been gradually declined to NYHA Class IV (New York Heart Association).

### History of past illness

Hypertension, status post heart transplantation, allograft non occlusive vasculopathy and aortic stenosis.

### Personal and family history

Included above.

### Physical examination

Physical examination upon admission: He was noted to have elevated jugular venous pulse, bibasilar lung crackles and bilateral pedal edema.

### Laboratory examination

None.

### Imaging examinations

Follow up transthoracic echocardiograms as per routine protocol did not show any aortic valve disease until 15 years post transplantation when the aortic valve was noted to be mildly sclerotic at that time and gradually progressed to symptomatic severe aortic stenosis over the next 4 years.

---

## FINAL DIAGNOSIS

---

Symptomatic severe aortic stenosis.

---

## TREATMENT

---

Transcatheter aortic valve replacement.

---

## OUTCOME AND FOLLOW-UP

---

Patient had tolerated the procedure well and was discharged home on post procedure day 2. His symptoms of shortness of breath and functional capacity were noted to be significantly improved during post procedure follow up in the clinic.

---

## DISCUSSION

---

Patient was minimally sedated with subcutaneous lidocaine in bilateral groin sites along with small dose of versed and fentanyl pushes per anesthesia protocol.

The left groin was accessed with a 6 French sheath. A pigtail was advanced for aortoiliac angiography and contralateral access guidance. Aortic root angiography was performed for guidance of valve deployment. A 6 French venous sheath was obtained in the left common femoral vein and a temporary pacemaker was advanced into the right ventricle. With contralateral guidance, a 6 French sheath was placed into the right common femoral artery. Two Preclose devices were deployed and a 16 French sheath was placed. An Amplatz catheter and a Newton wire was advanced, across the aortic valve into the left ventricle followed by advancing a preshaped stiff amplatz wire. Later, the prosthetic aortic valve was advanced across the aortic valve. Once the valve was noted to be in proper position, a 29-mm Sapien 3 valve was deployed in the usual sequence of rapid pacing, balloon inflation and balloon deflation. Once the valve was deployed, transthoracic echocardiography was done that confirmed adequate valve function. No aortic regurgitation was noted. The delivery system and the 16 French sheath and hemostasis was achieved successfully. The left common femoral access sheath was removed and a 6 French Mynx device was placed. No immediate complications were seen. Patient did tolerate the procedure well and was discharged on post op day 2 ([Figure 1](#)).

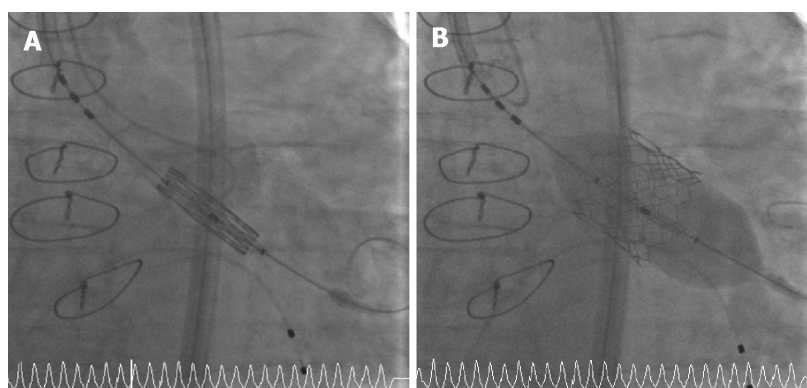
---

## CONCLUSION

---

Minimal approach transcatheter aortic valve replacement has proven to have good outcomes in high risk patients. Its use in allograft heart is also showing to have good immediate post-operative outcomes. All the case reports thus far have commented on immediate post-operative outcomes, but more data is needed in regard to long-term prognosis. There is inadequate data in regard to valvular diseases in heart transplant recipients. Vasculopathy is a well-known complication in this patient population. With the improved survival of these patients, we think it is time to look into pathophysiology of valvular disease in transplant heart recipients. Some other unanswered questions include, underlying donor and recipient risk factors for valvular diseases in heart transplant recipients.





**Figure 1 Fluoroscopic pictures.** A: The fluoroscopic pictures of pre deployment of the Transcatheter Aortic Valve B: The fluoroscopic pictures of post deployment of the TAVR valve.

## REFERENCES

- 1 **Bruschi G**, De Marco F, Oreglia J, Colombo P, Moreo A, De Chiara B, Paino R, Frigerio M, Martinelli L, Klugmann S. Transcatheter aortic valve implantation after heart transplantation. *Ann Thorac Surg* 2010; **90**: e66-e68 [PMID: [20971222](#) DOI: [10.1016/j.athoracsur.2010.08.021](#)]
- 2 **De Praetere H**, Ciarka A, Dubois C, Herijgers P. Transapical transcatheter aortic valve implantation in a heart transplant recipient with severely depressed left ventricular function. *Interact Cardiovasc Thorac Surg* 2013; **16**: 906-908 [PMID: [23460597](#) DOI: [10.1093/icvts/ivt048](#)]
- 3 **Vistarini N**, D'Armini AM, Pellegrini C, Aiello M, Toscano M, Minzioni G, Viganò M. Minimally invasive aortic valve replacement in a transplanted heart. *Ann Thorac Surg* 2010; **90**: 1688-1690 [PMID: [20971292](#) DOI: [10.1016/j.athoracsur.2010.08.013](#)]
- 4 **Ross J**, Braunwald E. Aortic stenosis. *Circulation* 1968; **38**: 61-67 [PMID: [4894151](#) DOI: [10.1161/01.CIR.38.1S5.V-61](#)]
- 5 **Schwarz F**, Baumann P, Manthey J, Hoffmann M, Schuler G, Mehmel HC, Schmitz W, Kübler W. The effect of aortic valve replacement on survival. *Circulation* 1982; **66**: 1105-1110 [PMID: [7127696](#) DOI: [10.1161/01.CIR.66.5.1105](#)]
- 6 **Seiffert M**, Meyer S, Franzen O, Conradi L, Baldus S, Schirmer J, Deuse T, Costard-Jaeckle A, Reichenspurner H, Treede H. Transcatheter aortic valve implantation in a heart transplant recipient: a case report. *Transplant Proc* 2010; **42**: 4661-4663 [PMID: [21168756](#) DOI: [10.1016/j.transproceed.2010.09.148](#)]
- 7 **Zanuttini D**, Armellini I, Bisceglia T, Spedicato L, Bernardi G, Muzzi R, Proclemer A, Livi U. Transcatheter aortic valve implantation for degenerative aortic valve regurgitation long after heart transplantation. *Ann Thorac Surg* 2013; **96**: 1864-1866 [PMID: [24182478](#) DOI: [10.1016/j.athoracsur.2013.03.040](#)]
- 8 **Margale S**, Natani S. Anesthetic Management of Transfemoral Transcatheter Aortic Valve Replacement (TAVR) in a Heart Transplant Recipient With Severely Depressed Left Ventricular Function and Renal Failure. *J Cardiothorac Vasc Anesth* 2017; **31**: 1032-1036 [PMID: [27693207](#) DOI: [10.1053/j.jvca.2016.07.026](#)]
- 9 **Leon MB**, Smith CR, Mack M, Miller DC, Moses JW, Svensson LG, Tuzcu EM, Webb JG, Fontana GP, Makkar RR, Brown DL, Block PC, Guyton RA, Pichard AD, Bavaria JE, Herrmann HC, Douglas PS, Petersen JL, Akin JJ, Anderson WN, Wang D, Pocock S; PARTNER Trial Investigators. Transcatheter aortic-valve implantation for aortic stenosis in patients who cannot undergo surgery. *N Engl J Med* 2010; **363**: 1597-1607 [PMID: [20961243](#) DOI: [10.1056/NEJMoa1008232](#)]
- 10 **Smith CR**, Leon MB, Mack MJ, Miller DC, Moses JW, Svensson LG, Tuzcu EM, Webb JG, Fontana GP, Makkar RR, Williams M, Dewey T, Kapadia S, Babaliaros V, Thourani VH, Corso P, Pichard AD, Bavaria JE, Herrmann HC, Akin JJ, Anderson WN, Wang D, Pocock SJ; PARTNER Trial Investigators. Transcatheter versus surgical aortic-valve replacement in high-risk patients. *N Engl J Med* 2011; **364**: 2187-2198 [PMID: [21639811](#) DOI: [10.1056/NEJMoa1103510](#)]



Published By Baishideng Publishing Group Inc  
7041 Koll Center Parkway, Suite 160, Pleasanton, CA 94566, USA  
Telephone: +1-925-2238242  
Fax: +1-925-2238243  
E-mail: [bpgoffice@wjgnet.com](mailto:bpgoffice@wjgnet.com)  
Help Desk: <https://www.f6publishing.com/helpdesk>  
<https://www.wjgnet.com>

