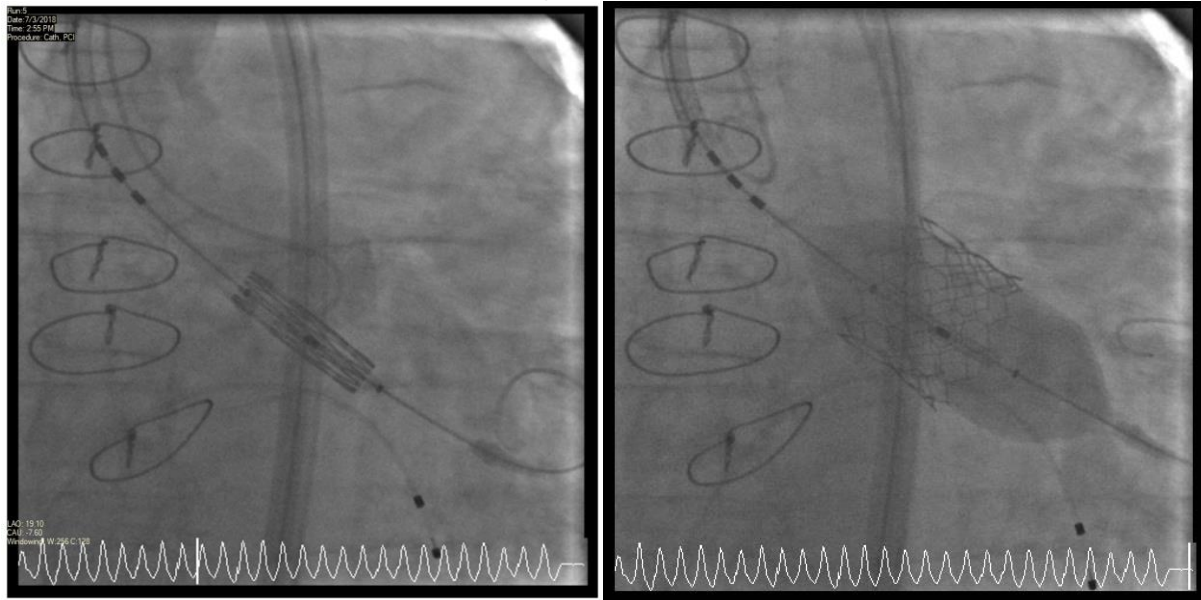


ANSWERING REVIEWERS

Reviewer 1: The article is interesting, difficult and important. It can be acceptable, but a case-related image is required (at least 2 images)

ANSWER: We have added two images.



The above figures show a fluoroscopic pictures of pre (left) and post (right) deployment of the TAVR valve.

Reviewer 2: Authors report an interesting case report of successful minimal approach transcatheter aortic valve replacement in an allograft heart recipient 19 years post transplantation. The paper is well written, however one or two figures about the operation will be useful. Authors should also define the exact STS score for surgery.

ANSWER: Thank you very much and we have added it.