

# World Journal of *Clinical Cases*

*World J Clin Cases* 2019 June 26; 7(12): 1367-1534





### REVIEW

- 1367 Biomarkers *vs* imaging in the early detection of hepatocellular carcinoma and prognosis  
*Balaceanu LA*

### ORIGINAL ARTICLE

#### Basic Study

- 1383 Study on gene expression patterns and functional pathways of peripheral blood monocytes reveals potential molecular mechanism of surgical treatment for periodontitis  
*Ma JJ, Liu HM, Xu XH, Guo LX, Lin Q*

#### Case Control Study

- 1393 Clinical differentiation of acute appendicitis and right colonic diverticulitis: A case-control study  
*Sasaki Y, Komatsu F, Kashima N, Sato T, Takemoto I, Kijima S, Maeda T, Ishii T, Miyazaki T, Honda Y, Shimada N, Urita Y*

#### Retrospective Study

- 1403 Feasibility of prostatectomy without prostate biopsy in the era of new imaging technology and minimally invasive techniques  
*Xing NZ, Wang MS, Fu Q, Yang FY, Li CL, Li YJ, Han SJ, Xiao ZJ, Ping H*
- 1410 Safety and efficacy of transfemoral intrahepatic portosystemic shunt for portal hypertension: A single-center retrospective study  
*Zhang Y, Liu FQ, Yue ZD, Zhao HW, Wang L, Fan ZH, He FL*

#### Observational Study

- 1421 Impact of gastroesophageal reflux disease on the quality of life of Polish patients  
*Gorczyca R, Pardak P, Pękala A, Filip R*

### SYSTEMATIC REVIEWS

- 1430 Non-*albicans* *Candida* prosthetic joint infections: A systematic review of treatment  
*Koutserimpas C, Zervakis SG, Maraki S, Alpantaki K, Ioannidis A, Kofteridis DP, Samonis G*

### META-ANALYSIS

- 1444 Relationship between circulating irisin levels and overweight/obesity: A meta-analysis  
*Jia J, Yu F, Wei WP, Yang P, Zhang R, Sheng Y, Shi YQ*

### CASE REPORT

- 1456 Cirrhosis complicating Shwachman-Diamond syndrome: A case report  
*Camacho SM, McLoughlin L, Nowicki MJ*

- 1461** Robot-assisted trans-gastric drainage and debridement of walled-off pancreatic necrosis using the EndoWrist stapler for the da Vinci Xi: A case report  
*Morelli L, Furbetta N, Gianardi D, Palmeri M, Di Franco G, Bianchini M, Stefanini G, Guadagni S, Di Candio G*
- 1467** Fulminant liver failure following a marathon: Five case reports and review of literature  
*Figiel W, Morawski M, Grąt M, Kornasiewicz O, Niewiński G, Raszeja-Wyszomirska J, Krasnodębski M, Kowalczyk A, Holówko W, Patkowski W, Zieniewicz K*
- 1475** Gaucher disease in Montenegro - genotype/phenotype correlations: Five cases report  
*Vujosevic S, Medenica S, Vujicic V, Dapcevic M, Bakic N, Yang R, Liu J, Mistry PK*
- 1483** Longitudinal observation of ten family members with idiopathic basal ganglia calcification: A case report  
*Kobayashi S, Utsumi K, Tateno M, Iwamoto T, Murayama T, Sohma H, Ukai W, Hashimoto E, Kawanishi C*
- 1492** Secondary lymphoma develops in the setting of heart failure when treating breast cancer: A case report  
*Han S, An T, Liu WP, Song YQ, Zhu J*
- 1499** Removal of pediatric stage IV neuroblastoma by robot-assisted laparoscopy: A case report and literature review  
*Chen DX, Hou YH, Jiang YN, Shao LW, Wang SJ, Wang XQ*
- 1508** Premonitory urges located in the tongue for tic disorder: Two case reports and review of literature  
*Li Y, Zhang JS, Wen F, Lu XY, Yan CM, Wang F, Cui YH*
- 1515** Female genital tract metastasis of lung adenocarcinoma with EGFR mutations: Report of two cases  
*Yan RL, Wang J, Zhou JY, Chen Z, Zhou JY*
- 1522** Novel heterozygous missense mutation of *SLC12A3* gene in Gitelman syndrome: A case report  
*Wang CL*
- 1529** Thoracotomy of an asymptomatic, functional, posterior mediastinal paraganglioma: A case report  
*Yin YY, Yang B, Ahmed YA, Xin H*

**ABOUT COVER**

Editorial Board Member of *World Journal of Clinical Cases*, Amirhossein Sahebkar, PharmD, PhD, Associate Professor, Biotechnology Research Center, Mashhad University of Medical Sciences, Mashhad 9177948564, Khorasan-Razavi, Iran

**AIMS AND SCOPE**

*World Journal of Clinical Cases* (*World J Clin Cases*, *WJCC*, online ISSN 2307-8960, DOI: 10.12998) is a peer-reviewed open access academic journal that aims to guide clinical practice and improve diagnostic and therapeutic skills of clinicians.

The primary task of *WJCC* is to rapidly publish high-quality Case Report, Clinical Management, Editorial, Field of Vision, Frontier, Medical Ethics, Original Articles, Meta-Analysis, Minireviews, and Review, in the fields of allergy, anesthesiology, cardiac medicine, clinical genetics, clinical neurology, critical care, dentistry, dermatology, emergency medicine, endocrinology, family medicine, gastroenterology and hepatology, *etc.*

**INDEXING/ABSTRACTING**

The *WJCC* is now indexed in PubMed, PubMed Central, Science Citation Index Expanded (also known as SciSearch®), and Journal Citation Reports/Science Edition. The 2018 Edition of Journal Citation Reports cites the 2017 impact factor for *WJCC* as 1.931 (5-year impact factor: N/A), ranking *WJCC* as 60 among 154 journals in Medicine, General and Internal (quartile in category Q2).

**RESPONSIBLE EDITORS FOR THIS ISSUE**

Responsible Electronic Editor: *Jie Wang*

Proofing Production Department Director: *Yun-Xiaojuan Wu*

**NAME OF JOURNAL**

*World Journal of Clinical Cases*

**ISSN**

ISSN 2307-8960 (online)

**LAUNCH DATE**

April 16, 2013

**FREQUENCY**

Semimonthly

**EDITORS-IN-CHIEF**

Dennis A Bloomfield, Sandro Vento

**EDITORIAL BOARD MEMBERS**

<https://www.wjgnet.com/2307-8960/editorialboard.htm>

**EDITORIAL OFFICE**

Jin-Lei Wang, Director

**PUBLICATION DATE**

June 26, 2019

**COPYRIGHT**

© 2019 Baishideng Publishing Group Inc

**INSTRUCTIONS TO AUTHORS**

<https://www.wjgnet.com/bpg/gerinfo/204>

**GUIDELINES FOR ETHICS DOCUMENTS**

<https://www.wjgnet.com/bpg/GerInfo/287>

**GUIDELINES FOR NON-NATIVE SPEAKERS OF ENGLISH**

<https://www.wjgnet.com/bpg/gerinfo/240>

**PUBLICATION MISCONDUCT**

<https://www.wjgnet.com/bpg/gerinfo/208>

**ARTICLE PROCESSING CHARGE**

<https://www.wjgnet.com/bpg/gerinfo/242>

**STEPS FOR SUBMITTING MANUSCRIPTS**

<https://www.wjgnet.com/bpg/GerInfo/239>

**ONLINE SUBMISSION**

<https://www.f6publishing.com>

## Non-*albicans* *Candida* prosthetic joint infections: A systematic review of treatment

Christos Koutserimpas, Stylianos G Zervakis, Sofia Maraki, Kalliopi Alpantaki, Argyrios Ioannidis, Diamantis P Kofteridis, George Samonis

**ORCID number:** Christos

Koutserimpas (0000-0002-1398-9626); Stylianos G Zervakis (0000-0002-8785-3780); Sofia Maraki (0000-0002-8553-0849); Kalliopi Alpantaki (0000-0003-0185-8474); Argyrios Ioannidis (0000-0003-0230-5302); Diamantis P Kofteridis (0000-0001-7603-2592); George Samonis (0000-0001-5857-9703).

**Author contributions:**

Koutserimpas C, Zervakis SG, Alpantaki K and Samonis G designed the research; Zervakis SG, Maraki S and Kofteridis DP performed the research; Koutserimpas C and Ioannidis A contributed new reagents/analytic tools; Koutserimpas C and Ioannidis A analyzed the data; Koutserimpas C, Zervakis SG, Alpantaki K and Samonis G wrote the paper.

**Conflict-of-interest statement:** The authors declare no conflict of interest.

**PRISMA 2009 Checklist statement:** PRISMA 2009 Checklist statement is provided.

**Open-Access:** This article is an open-access article that was selected by an in-house editor and fully peer-reviewed by external reviewers. It is distributed in accordance with the Creative Commons Attribution Non Commercial (CC BY-NC 4.0) license, which permits others to distribute, remix, adapt, build upon this work non-commercially, and license their derivative works on different terms, provided the

**Christos Koutserimpas**, Department of Orthopaedics and Traumatology, "251" Hellenic Air Force General Hospital of Athens, Athens 11525, Greece

**Stylianos G Zervakis, Diamantis P Kofteridis, George Samonis**, Department of Internal Medicine, University Hospital of Heraklion, Crete, Heraklion 71110, Greece

**Sofia Maraki**, Department of Clinical Microbiology and Microbial Pathogenesis, University Hospital of Heraklion, Crete, Heraklion 71110, Greece

**Kalliopi Alpantaki**, Department of Materials Science and Technology, University of Crete, Heraklion, Heraklion 71110, Greece

**Argyrios Ioannidis**, Department of General Surgery, "Sismanoglion" General Hospital of Athens, Athens 15126, Greece

**Corresponding author:** Christos Koutserimpas, MD, Doctor, Department of Orthopaedics and Traumatology, "251" Hellenic Air Force General Hospital of Athens, P. Kanelloupolou Av., Athens 11525, Greece. [chrisku91@hotmail.com](mailto:chrisku91@hotmail.com)

**Telephone:** +30-694-8712130

### Abstract

#### BACKGROUND

Non-*albicans Candida* prosthetic joint infections (PJIs) are rare. Optimal treatment involves a two-stage revision surgery in combination with an antifungal agent. However, no clear guidelines have been developed regarding the agent or treatment duration. Hence, a broad range of antifungal and surgical treatments have been reported so far.

#### AIM

To clarify treatment of non-*albicans Candida* PJIs.

#### METHODS

A literature review of all existing non-*albicans Candida* PJIs cases through April 2018 was conducted. Information was extracted about demographics, comorbidities, responsible species, duration and type of antifungal treatment, type of surgical treatment, time between initial arthroplasty and symptom onset, time between symptom onset and definite diagnosis, outcome of the infection and follow-up.

#### RESULTS

A total of 83 cases, with a mean age of 66.3 years, were located. The causative



original work is properly cited and the use is non-commercial. See: <http://creativecommons.org/licenses/by-nc/4.0/>

**Manuscript source:** Invited manuscript

**Received:** January 22, 2019

**Peer-review started:** January 23, 2019

**First decision:** March 10, 2019

**Revised:** March 16, 2019

**Accepted:** April 19, 2019

**Article in press:** April 19, 2019

**Published online:** June 26, 2019

**P-Reviewer:** Li J

**S-Editor:** Ji FF

**L-Editor:** Filipodia

**E-Editor:** Xing YX



yeast isolated in most cases was *C. parapsilosis* (45 cases; 54.2%), followed by *C. glabrata* (18 cases; 21.7%). The mean Charlson comorbidity index was  $4.4 \pm 1.5$ . The mean time from arthroplasty to symptom onset was  $27.2 \pm 43$  mo, while the mean time from symptom onset to culture-confirmed diagnosis was  $7.5 \pm 12.5$  mo. A two stage revision arthroplasty (TSRA), when compared to one stage revision arthroplasty, had a higher success rate (96% vs 73%,  $P = 0.023$ ). Fluconazole was the preferred antifungal agent (59; 71%), followed by amphotericin B (41; 49.4%).

## CONCLUSION

The combination of TSRA and administration of prolonged antifungal therapy after initial resection arthroplasty is suggested on the basis of limited data.

**Key words:** Fungal prosthetic joint infection; Knee arthroplasty infection; Hip arthroplasty infection; Antifungal treatment; Non-*albicans* *Candida* prosthetic joint infections

©The Author(s) 2019. Published by Baishideng Publishing Group Inc. All rights reserved.

**Core tip:** Non-*albicans* *Candida* prosthetic joint infections (PJIs) are rare, and no clear guidelines exist regarding the treatment of these infections. The purpose of this study was to clarify, by reviewing current published cases, the treatment options of non-*albicans* *Candida* PJIs and, possibly, to improve the medical and surgical care of such cases. A literature review of all existing non-*albicans* *Candida* PJIs cases through April 2018 was conducted. The combination of two stage revision arthroplasty and administration of prolonged antifungal therapy after initial resection arthroplasty is suggested on the basis of limited data.

**Citation:** Koutserimpas C, Zervakis SG, Maraki S, Alpantaki K, Ioannidis A, Kofteridis DP, Samonis G. Non-*albicans* *Candida* prosthetic joint infections: A systematic review of treatment. *World J Clin Cases* 2019; 7(12): 1430-1443

**URL:** <https://www.wjgnet.com/2307-8960/full/v7/i12/1430.htm>

**DOI:** <https://dx.doi.org/10.12998/wjcc.v7.i12.1430>

## INTRODUCTION

Prosthetic joint infection (PJI) is a severe complication of joint surgery, involving the joint prostheses and contiguous tissue, representing a main cause of total arthroplasty failure<sup>[1]</sup>. A plethora of microorganisms have been held responsible for these infections, such as Gram-positive and negative bacteria, while fungal microorganisms are considered rare causes. Fungal PJIs occur in about 1-2% of all cases, while the most common spread type seems to be hematogenous<sup>[2]</sup>.

Optimal treatment is considered the two stage revision surgery in combination with an antifungal agent. However, no clear guidelines have yet been developed regarding the agent and treatment duration. Hence, a broad range of antifungal and surgical treatments have been reported so far<sup>[3,4]</sup>.

*Candida* spp represent the most common fungal pathogens for PJIs, with *Candida albicans* being the most prevalent species. However, over the last years, the incidence of non-*albicans* *Candida* PJIs has increased<sup>[4,5]</sup>. The purpose of this study was to clarify, by reviewing current published cases, the treatment options of non-*albicans* *Candida* PJIs in order to potentially improve the medical and surgical care of such cases.

## MATERIALS AND METHODS

A search of PubMed and MEDLINE databases was performed to identify all existing articles reporting the management of non-*albicans* *Candida* PJIs cases through April 2018. Isolated and combined terms of "fungal prosthetic joint infection", "fungal arthroplasty infection", "fungal hip arthroplasty infection", "fungal knee arthroplasty infection", "fungal shoulder arthroplasty infection", as well as terms including each non-*albicans* *Candida* species (e.g., "*candida glabrata* joint infection", "*candida parapsilosis* joint infection, etc) were used. The citations in each article were reviewed to locate

additional references that were not retrieved during the initial search.

The present review is limited to papers published in English, peer-reviewed journals. Furthermore, cases without information about management and treatment were excluded. The data extracted from these studies included age, gender, affected joint, responsible non-*albicans* *Candida* species, duration and type of antifungal treatment, type of surgical treatment, time between initial arthroplasty and symptom onset, time between symptom onset and definite diagnosis (culture), outcome of the infection and follow-up of each case. Charlson Comorbidity score was calculated, when possible, by two independent investigators based on the information provided from each report.

Data were recorded and analyzed using Microsoft Excel 2010 (Microsoft Corporation, Redmond, Washington). Two-sided Fisher's exact tests were used to compare success rates between groups. Statistical analyses were carried out at the 5% level of significance.

## RESULTS

**Table 1** highlights the findings from the electronic search, covering a 39 year period ending in 2018. A total of 83 non-*albicans* *Candida* PJIs were identified<sup>[4,6-47]</sup>. A total of 46 cases (55.4%) were female patients, thirty-six male (43.4%), while in one case the gender was not clarified. The mean age of the study population was 66.3 years [standard deviation (SD) = 10.2]. The affected joint was the knee in 52 cases (62.6%), the hip in 29 (35%) and the shoulder in two (2.4%). Two of the knee prosthetic joint cases were bilateral. The mean Charlson comorbidity index of patients was 4.4 (SD = 1.5).

The mean time from initial arthroplasty implantation surgery to symptom onset was 27.2 mo (SD = 43), while the mean time from symptom onset to culture-confirmed diagnosis was 7.5 mo (SD = 12.5). Regarding the causative non-*albicans* *Candida* species, the most frequently isolated one was *C. parapsilosis*, found in 45 cases (54.2%), followed by *C. glabrata* in 18 (21.7%), *C. tropicalis* in ten (12%), *C. pelliculosa* in three (3.6%) and *C. lusitanae* in two (2.4%), while *C. famata*, *C. lipolytica*, *C. utilis*, *C. guilliermondii* and *C. freyschussii* had caused one case each (1.2%) (**Figure 1**).

Regarding surgical treatment, in the majority of the described cases (44 cases; 53%) a two stage revision arthroplasty (TSRA) was performed, followed by resection arthroplasty (RA) (18 cases; 22%), one stage revision arthroplasty (OSRA) (eight cases; 9.6%), arthrodesis (five cases; 6%), debridement (three cases; 3.6%) and amputation (two cases; 2.4%). In three cases (3.6%), there was no surgical treatment (**Figure 2**). TSRA exhibited a success rate of 96%, RA a rate of  $\geq 61\%$  [in 7 cases information about the infection outcome was not provided (studies 8, 31, 32, 46, 60, 62, 66 in **Table 1**)], OSRA a rate of 73%, debridement a rate of 75%, amputation a rate of 100%, while no surgical treatment has shown a success rate of 60%. TSRA when compared to OSRA had a higher success rate (96% *vs* 73%; *P*-value = 0.023).

Regarding the preferred antifungal agent, 38 cases (45.8%) were treated with a single drug, 29 (34.9%) with two, 12 (14.5%) with more than two, while one case did not receive antifungal treatment [(1.2%); case 17 in **Table 1**; the antifungal agent was not reported in case 32].

Fluconazole was used in most cases [59; (71%), in 31 of them (52.5%) as monotherapy], followed by amphotericin B [41; (49.4%), in 4 (9.8%) as monotherapy], flucytosine [13; (15.7%), in 1 (7.7%) as monotherapy], caspofungin [7; (8.4%), in 1 (14.3%) as monotherapy], voriconazole [7; (8.4%), in 2 (28.6%) as monotherapy], ketoconazole [5; (6%), none as monotherapy], itraconazole [3; (3.6%), none as monotherapy] and anidulafungin [1; (1.2%), not as monotherapy]. The final outcome was successful in 74 cases (89.2%).

The majority of patients with *C. parapsilosis* PJIs were treated with fluconazole [30 cases; (66.7%), in 22 (73.3%) as monotherapy], followed by amphotericin B [19; (42.2%), none as monotherapy], flucytosine [8; (17.8%), in 1 (12.5%) as monotherapy], ketoconazole [3; (6.7%), none as monotherapy], while voriconazole and itraconazole were used in 1 case each (none as monotherapy). Outcome was successful in 40 cases (88.9%).

The majority of cases with *C. glabrata* PJIs were treated with amphotericin B [8; (44.4%), in 1 (12.5%) as monotherapy], followed by fluconazole [7; (38.9%), in 3 (42.9%) as monotherapy]. Caspofungin and voriconazole were used in 5 cases (27.8%) each, in 1 (20%) case each as monotherapy. Furthermore, three (16.7%) patients received flucytosine (none as monotherapy), two (11.1%) itraconazole (none as monotherapy) and one (5.6%) anidulafungin (not as monotherapy). Outcome was successful in 17 cases (94.4%), while one patient (case number 11 in **Table 1**) passed

Table 1 Non-albicans Candida prosthetic joint infection cases

Ref.	Year	Fungus	Gender	Age	Joint	Char- lson comor- bidity index	Anti- fungal treat- ment	Surgical treat- ment	Treat- ment duration	Out- come	Follow- up in mo	Time from implan- tation to symp- toms onset in mo	Time from symp- toms onset to definite diagno- sis by culture, in mo
Kout- serimpa s et al <sup>[6]</sup>	2018	<i>C. glabrata</i>	Female	68	Knee	4	Anidula- fungin / Vorico- nazole	TSRA	28 wk	Suc- cessful	-	180	0.5
Geng et al <sup>[7]</sup>	2016	<i>C. glabrata</i>	Male	78	Hip	4	Fluco- nazole / Ampho- tericin B / Caspo- fungin	Spacer implan- tation (failure)/ RA	26 wk	Suc- cessful		11	34.8
Klatte et al <sup>[8]</sup>	2014	<i>C. glabrata</i>	Female	81	Hip	4	Flucyto- sine / Ampho- tericin. B / Fluco- nazole	OSRA	-	Suc- cessful		8	-
Zhu et al <sup>[9]</sup>	2014	<i>C. glabrata</i>	Male	44	Hip	-	Ampho- tericin B / Vorico- nazole	No	6 wk	Suc- cessful	3	-	5
Anagno- stakos et al <sup>[10]</sup>	2012	<i>C. glabrata</i>	Female	51	Hip	6	Fluco- nazole	TSRA	6 wk	Suc- cessful	70	-	-
Anagno- stakos et al <sup>[10]</sup>	2012	<i>C. glabrata</i>	Male	78	Hip	6	Fluco- nazole	TSRA	6 wk	Suc- cessful	15	-	-
Bartalesi et al <sup>[11]</sup>	2012	<i>C. glabrata</i>	Female	60	Hip	-	Vorico- nazole / Caspo- fungin + Ampho- tericin B	TSRA	6 wk	Suc- cessful	48	-	-
Hall et al <sup>[12]</sup>	2012	<i>C. glabrata</i>	Female	60	Hip	4	Caspo- fungin	RA	6 wk	-	-	< 0.5	0.2
Du- maine et al <sup>[13]</sup>	2008	<i>C. glabrata</i>	-	72	Knee	5	Caspo- fungin + Flucyto- sine / Fluco- nazole + Flucyto- sine	Ar- throdesis	16 wk	Suc- cessful	15	-	-
Lejko- Zupanc et al <sup>[14]</sup>	2005	<i>C. glabrata</i>	Male	74	Hip	5	Ampho- tericin B + Fluco- nazole / Caspo- fungin	RA	→ 3 wk	Suc- cessful	36	72	-
Fabry et al <sup>[15]</sup>	2005	<i>C. glabrata</i>	Female	74	Knee	6	Vorico- nazole	2x Debride- ment	32 wk	Death from unrelated causes while on therapy	24	72	-
Gaston et al <sup>[16]</sup>	2004	<i>C. glabrata</i>	Female	42	Knee	4	Vorico- nazole / Ampho- tericin B	Ampu- tation (above knee)	8 wk	Suc- cessful	6	264	-



Açikgöz <i>et al</i> <sup>[17]</sup>	2002	<i>C. glabrata</i>	Female	70	Knee	-	Fluconazole	Arthrodesis	-	Successful	7.5	9	6
Ramamo-han <i>et al</i> <sup>[18]</sup>	2001	<i>C. glabrata</i>	Female	65	Hip	-	Amphotericin B + Flucytosine	TSRA	7 wk	Successful	24	48	-
Selmon <i>et al</i> <sup>[19]</sup>	1998	<i>C. glabrata</i>	Female	75	Knee	5	Amphotericin B/Itracozazole + Fluconazole	OSRA	> 8 wk	Successful	48	84	-
Nayeri <i>et al</i> <sup>[20]</sup>	1997	<i>C. glabrata</i>	Female	62	Hip	4	Amphotericin B+ Flucytosine / Itracozazole + Flucytosine	OSRA	11 wk	Successful	22	60	-
Darouiche <i>et al</i> <sup>[21]</sup>	1989	<i>C. glabrata</i>	Female	69	Hip	-	Amphotericin B	RA	1 wk	Successful	-	27	0.5
Goodman <i>et al</i> <sup>[22]</sup>	1983	<i>C. glabrata</i>	Female	69	Hip	3	-	RA	-	Successful	12	27	-
Geng <i>et al</i> <sup>[7]</sup>	2016	<i>C. parapsilosis</i>	Male	67	Knee	3	Fluconazole	TSRA	10 wk	Successful	48	3	-
Wang <i>et al</i> <sup>[23]</sup>	2015	<i>C. parapsilosis</i>	Female	67	Knee	4	Fluconazole	TSRA	10 wk	Successful	27	-	-
Wang <i>et al</i> <sup>[23]</sup>	2015	<i>C. parapsilosis</i>	Male	74	Knee	5	Fluconazole	TSRA	8 wk	Successful	30	-	-
Wang <i>et al</i> <sup>[23]</sup>	2015	<i>C. parapsilosis</i>	Female	71	Knee	4	Fluconazole	TSRA	6 wk	Successful	62	-	-
Klatte <i>et al</i> <sup>[8]</sup>	2014	<i>C. parapsilosis</i>	Male	69	Knee	8	Flucytosine+ Amphotericin. B	OSRAx3 (Failure the first 2 times)	-	Successful	19	1	-
Klatte <i>et al</i> <sup>[8]</sup>	2014	<i>C. parapsilosis</i>	Female	82	Knee	4	Flucytosine+ Amphotericin. B	OSRA	-	Successful	-	2	-
Klatte <i>et al</i> <sup>[8]</sup>	2014	<i>C. parapsilosis</i>	Male	46	Knee	1	Flucytosine+ Amphotericin. B	OSRA	-	Successful	-	6	-
Ueng <i>et al</i> <sup>[24]</sup>	2013	<i>C. parapsilosis</i>	Male	62	Knee	4	Fluconazole	TSRA	-	Successful	≥ 24	4.5	1.5
Ueng <i>et al</i> <sup>[24]</sup>	2013	<i>C. parapsilosis</i>	Male	77	Knee	-	Fluconazole	TSRA	-	Successful	≥ 24	4	3
Ueng <i>et al</i> <sup>[24]</sup>	2013	<i>C. parapsilosis</i>	Male	66	Hip	-	Fluconazole	TSRA	-	Successful	≥ 24	2	1
Ueng <i>et al</i> <sup>[24]</sup>	2013	<i>C. parapsilosis</i>	Male	76	Knee	8	Fluconazole	TSRA	-	Successful	≥ 24	33	2
Ueng <i>et al</i> <sup>[24]</sup>	2013	<i>C. parapsilosis</i>	Male	36	Knee	-	Fluconazole	TSRA	-	Successful	≥ 24	74	2
Ueng <i>et al</i> <sup>[24]</sup>	2013	<i>C. parapsilosis</i>	Male	66	Hip	4	Fluconazole	RA	-	-	-	2	2
Kuiper <i>et al</i> <sup>[25]</sup>	2013	<i>C. parapsilosis</i>	Male	58	Hip	-	None	RA/re-fused further treatment	-	Refused further treatment	8	-	-
Chiu <i>et al</i> <sup>[26]</sup>	2013	<i>C. parapsilosis</i>	Male	71	Hip	5	Fluconazole	RA	40 wk	Successful	24	48	-
Hwang <i>et al</i> <sup>[4]</sup>	2012	<i>C. parapsilosis</i>	Female	71	Knee	-	Amphotericin B / Fluconazole	TSRA	≥ 6 wk	Successful	46	-	-

Hwang <i>et al</i> <sup>[4]</sup>	2012	<i>C. parapsilosis</i>	Female	76	Knee	-	Amphotericin B / Flucanazole	TSRA	≥ 6 wk	Successful	56	-	-
Hwang <i>et al</i> <sup>[4]</sup>	2012	<i>C. parapsilosis</i>	Female	76	Knee	-	Amphotericin B / Flucanazole	TSRA	≥ 6 wk	Successful	67	-	-
Hwang <i>et al</i> <sup>[4]</sup>	2012	<i>C. parapsilosis</i>	Female	72	Knee	-	Flucanazole	TSRA	≥ 6 wk	Successful	73	-	-
Hwang <i>et al</i> <sup>[4]</sup>	2012	<i>C. parapsilosis</i>	Female <sup>1</sup>	61 <sup>1</sup>	Bilateral Knee	-	Amphotericin B / Flucanazole	TSRA	≥ 6 wk	Successful	65	-	-
Hwang <i>et al</i> <sup>[4]</sup>	2012	<i>C. parapsilosis</i>	Female <sup>1</sup>	61 <sup>1</sup>	Bilateral Knee	-	Amphotericin B / Flucanazole	TSRA	≥ 6 wk	Successful	46	-	-
Hwang <i>et al</i> <sup>[4]</sup>	2012	<i>C. parapsilosis</i>	Female	67	Knee	-	Amphotericin B / Flucanazole	TSRA	≥ 6 wk	Successful	65	-	-
Hwang <i>et al</i> <sup>[4]</sup>	2012	<i>C. parapsilosis</i>	Female	68	Knee	-	Flucanazole,	TSRA	≥ 6 wk	Successful	69	-	-
Hwang <i>et al</i> <sup>[4]</sup>	2012	<i>C. parapsilosis</i>	Female	68	Knee	-	Flucanazole,	TSRA	≥ 6 wk	Successful	42	-	-
Hwang <i>et al</i> <sup>[4]</sup>	2012	<i>C. parapsilosis</i>	Female	67	Knee	-	Amphotericin B / Flucanazole	TSRA	≥ 6 wk	Successful	49	-	-
Hwang <i>et al</i> <sup>[4]</sup>	2012	<i>C. parapsilosis</i>	Female	60	Knee	-	Amphotericin B / Flucanazole	TSRA	≥ 6 wk	Successful	41	-	-
Hwang <i>et al</i> <sup>[4]</sup>	2012	<i>C. parapsilosis</i>	Female	73	Knee	-	Amphotericin B / Flucanazole	TSRA	≥ 6 wk	Successful	52	-	-
Anagnostakos <i>et al</i> <sup>[10]</sup>	2012	<i>C. parapsilosis</i>	Male	67	Knee	-	Flucanazole	RA	6 wk	-	-	-	-
Dutronic <i>et al</i> <sup>[27]</sup>	2010	<i>C. parapsilosis</i>	Male	66	Hip	5	Flucanazole	TSRA	24 wk	Successful	-	0	-
Dutronic <i>et al</i> <sup>[27]</sup>	2010	<i>C. parapsilosis</i>	Female	77	Hip	4	Amphotericin B + fluorocytosine / Flucanazole	RA	38 wk	Successful	-	5	-
Antony <i>et al</i> <sup>[28]</sup>	2008	<i>C. parapsilosis</i>	Female	67	Shoulder	3	Voriconazole / Flucanazole	TSRA	-	Successful	6	-	-
Antony <i>et al</i> <sup>[28]</sup>	2008	<i>C. parapsilosis</i>	Female	67	Hip	3	Flucanazole	TSRA	-	Successful	-	-	-
Yang <i>et al</i> <sup>[29]</sup>	2001	<i>C. parapsilosis</i>	Female	68	Knee	3	Flucanazole	TSRA	10 wk	Successful	48	0	16
Bruce <i>et al</i> <sup>[30]</sup>	2001	<i>C. parapsilosis</i>	Female	51	Hip	-	Flucanazole	TSRA	-	Successful	84	36	36
Brooks <sup>[3]</sup>	1998	<i>C. parapsilosis</i>	Male	64	Knee	5	Amphotericin B/Flucanazole	Debridement	28 wk	Successful	24	15	4
Wada <i>et al</i> <sup>[32]</sup>	1998	<i>C. parapsilosis</i>	Male	77	Knee	4	Flucanazole	Debridement	28 wk	Successful	36	0.5	0.5
Cushing <i>et al</i> <sup>[33]</sup>	1997	<i>C. parapsilosis</i>	Female	73	Knee	-	Flucanazole	No	> 24 wk	Successful	12	1	-
Fukasawa <i>et al</i> <sup>[34]</sup>	1997	<i>C. parapsilosis</i>	Female	80	Knee	-	Flucanazole	Debridement	53 wk	Successful	24		2

White <i>et al</i> <sup>[35]</sup>	1995	<i>C. parapsilosis</i>	Female	64	Knee	-	Fluconazole / Amphotericin B / Itracozazole	RA	20 wk	Successful	-	0	9
Tunkel <i>et al</i> <sup>[36]</sup>	1993	<i>C. parapsilosis</i>	Male	37	Knee	6	Amphotericin B / Ketocozazole / Fluconazole	TSRA (Failure) / Amputation (Successful)	-	Successful	7	4	0
Paul <i>et al</i> <sup>[37]</sup>	1992	<i>C. parapsilosis</i>	Male	63	Knee	-	Amphotericin + fluorocytosine / ketocozazole	Arthrodesis	9 wk	Successful	24	3	4
Lim <i>et al</i> <sup>[38]</sup>	1986	<i>C. parapsilosis</i>	Male	35	Knee	-	Fluorocytosine	Arthrodesis	-	-	-	0	6
Younkin <i>et al</i> <sup>[39]</sup>	1984	<i>C. parapsilosis</i>	Female	75	Hip	-	Fluorocytosine + Amphotericin B	TSRA	6 wk	Successful	24	0	60
Lichtman <sup>[40]</sup>	1983	<i>C. parapsilosis</i>	Male	59	Shoulder	-	Amphotericin B / ketocozazole	RA	Indefinite (> 58 d)	-	-	20	9
MacGregor <i>et al</i> <sup>[41]</sup>	1979	<i>C. parapsilosis</i>	Male	64	Knee	-	Amphotericin B + Fluorocytosine	Non-surgical (failure) / then RA	21 wk	Successful	12	27	5
Sebastian <i>et al</i> <sup>[42]</sup>	2017	<i>C. tropicalis</i>	Male	53	Hip	3	Fluconazole	TSRA	28 wk	Successful	NR	24	0
Reddy <i>et al</i> <sup>[43]</sup>	2013	<i>C. tropicalis</i>	Female	62	Knee	3	Fluconazole	TSRA	30 wk	Successful	24	22.5	1.5
Ueng <i>et al</i> <sup>[24]</sup>	2013	<i>C. tropicalis</i>	Male	67	Hip	-	Fluconazole	RA	-	-	-	15	1
Lidder <i>et al</i> <sup>[44]</sup>	2013	<i>C. tropicalis</i>	Female	76	Hip	-	Amphotericin B	RA	24 wk	Successful	24	36	15
Azam <i>et al</i> <sup>[45]</sup>	2008	<i>C. tropicalis</i>	Male	73	Hip	6	Caspofungin / Fluconazole	TSRA	≥ 9 wk, (Caspofungin 1 wk, fluconazole ≥ 8 wk)	Successful	12	108	-
Wyman <i>et al</i> <sup>[46]</sup>	2002	<i>C. tropicalis</i>	Male	62	Knee	-	Fluconazole / Amphotericin B	TSRA	18 wk	Successful	36	0.25	6
Darouiche <i>et al</i> <sup>[21]</sup>	1989	<i>C. tropicalis</i>	Male	72	Hip	4	Amphotericin B / ketocozazole	Debridement (failure) / RA	12 wk	Successful	36	0.5	1
Lambertus <i>et al</i> <sup>[47]</sup>	1988	<i>C. tropicalis</i>	Male	61	Hip	3	Amphotericin B	RA	-	Successful	24	6	6
Lambertus <i>et al</i> <sup>[47]</sup>	1988	<i>C. tropicalis</i>	Male	65	Hip	-	Amphotericin B / ketocozazole	RA / arthrodesis	>24 wk	Successful	14	4	4
Goodman <i>et al</i> <sup>[30]</sup>	1983	<i>C. tropicalis</i>	Female	59	Knee	-	Amphotericin B	TSRA (failure) / RA	6 wk	Successful	12	3	6
Hwang <i>et al</i> <sup>[4]</sup>	2012	<i>C. pelliculosa</i>	Female	67	Knee	-	Fluconazole	TSRA	≥ 6 wk	Successful	56	-	-
Hwang <i>et al</i> <sup>[4]</sup>	2012	<i>C. pelliculosa</i>	Female	64	Knee	-	Amphotericin B / fluconazole	TSRA	≥ 6 wk	Successful	35	-	-

Hwang et al <sup>[4]</sup>	2012	<i>C. pelliculosa</i>	Male	75	Knee	-	Amphotericin B / fluconazole	TSRA	≥ 6 wk	Successful	34	-	-
Klatte et al <sup>[8]</sup>	2014	<i>C. lusitaniae</i>	Male	74	Knee	6	Voriconazole	OSRA	-	Successful		12	-
Hwang et al <sup>[4]</sup>	2012	<i>C. lusitaniae</i>	Female	66	Knee	-	Amphotericin B / fluconazole	TSRA	≥ 6 wk	Successful	43	-	-
Hwang et al <sup>[4]</sup>	2012	<i>C. famata</i>	Female	83	Knee	-	Amphotericin B / fluconazole	TSRA	≥ 6 wk	Successful	33	-	-
Anagno-stakos et al <sup>[10]</sup>	2012	<i>C. lipolytica</i>	Male	77	Hip	7	Fluconazole	TSRA	6 wk	Successful	22	-	-
Wang et al <sup>[23]</sup>	2015	<i>C. utilis</i>	Female	56	Knee	2	Fluconazole	TSRA	6 wk	Successful	24	-	5
Dutronic et al <sup>[27]</sup>	2010	<i>C. guilliermondii</i>	Male	76	Knee	4	Amphotericin B+ fluorocytosine / Fluconazole	None	14 wk (2 wkAMB+ 5FC, then 3 mo FZ)	Failure	-	0	-
Geng et al <sup>[7]</sup>	2016	<i>C. freyschussii</i>	Female	58	Knee	2	Fluconazole / Caspofungin	TSRA	10 wk	Successful	55	<0.25	

Patient demographics, antifungal treatment, its duration, as well as infection outcome and follow-up period are presented.

<sup>1</sup>Bilateral PJI in the same patient; -: Not reported or unclear. TSRA: Two stage revision arthroplasty; OSRA: One stage revision arthroplasty; RA: Resection arthroplasty.

away from unrelated causes.

The majority of *C. tropicalis* PJIs were treated with amphotericin B [6; (60%), in 3 (50%) as monotherapy], followed by fluconazole [5; (50%), in 3 (60%) as monotherapy], ketoconazole [2; (20%), none as monotherapy] and caspofungin [1; (10%), not as monotherapy]. Outcome was successful in 9 cases (90%; case number 66 in Table 1, treated with fluconazole as monotherapy, did not provide information about outcome).

All patients suffering from *C. pelliculosa* PJI received fluconazole [3 cases; (100%), 1 (33.3%) as monotherapy], while 2 of them (66.7%) received amphotericin B (none as monotherapy). All patients (100%) were treated successfully. Both patients suffering from *C. lusitaniae* were treated successfully. Voriconazole was used as monotherapy in 1 case (50%), while amphotericin B and fluconazole were used in the other.

One patient suffering from *C. famata* was successfully treated with amphotericin B and fluconazole, while fluconazole as monotherapy was successfully used for the treatment of each case of *C. lipolytica* and *C. utilis* PJI. One case of *C. freyschussii* was successfully treated with fluconazole and caspofungin. A case of *C. guilliermondii* infection received amphotericin B, fluorocytosine and fluconazole, however, the result was failure. The mean antifungal treatment duration was 12.8 wk (SD = 10.9), while the mean follow-up of these cases was 33.3 mo (SD = 19.6).

## DISCUSSION

Fungal invasive infections, such as PJIs, due to *Candida* species have been acknowledged as a major cause of morbidity and mortality. These infections have been associated with progress in medical modalities, and in some cases have been considered iatrogenic<sup>[3,4]</sup>. *Candida* PJIs are relative rare, since only case reports or small case series have been reported so far. *Candida albicans* is the most prevalent species. However, the incidence of invasive candidiasis and PJIs due to non-albicans *Candida* is increasing<sup>[5,48]</sup>. Optimal treatment of these infections remains unclear, since no certain guidelines exist for the antifungal, as well as for the surgical treatments<sup>[48]</sup>. It is, therefore, of paramount importance to report such cases and to obtain a better understanding of treatment options and outcomes of these infections. The present study is an effort to review, in a systematic way, the non-albicans *Candida* PJI cases

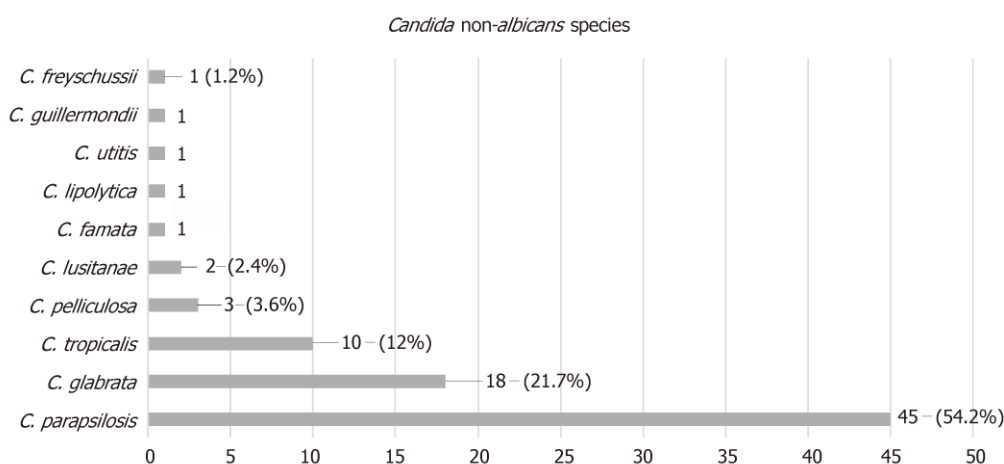


Figure 1 Prosthetic joint infection causative non-albicans *Candida* species.

## DISCUSSION

Fungal invasive infections, such as PJIs, due to *Candida* species have been acknowledged as a major cause of morbidity and mortality. These infections have been associated with progress in medical modalities, and in some cases have been considered iatrogenic<sup>[3,4]</sup>. *Candida* PJIs are relative rare, since only case reports or small case series have been reported so far. *Candida albicans* is the most prevalent species. However, the incidence of invasive candidiasis and PJIs due to non-albicans *Candida* is increasing<sup>[5,48]</sup>. Optimal treatment of these infections remains unclear, since no certain guidelines exist for the antifungal, as well as for the surgical treatments<sup>[48]</sup>. It is, therefore, of paramount importance to report such cases and to obtain a better understanding of treatment options and outcomes of these infections. The present study is an effort to review, in a systematic way, the non-albicans *Candida* PJI cases described in the literature. The study focuses on the preferred antifungal agent, the optimal surgical treatment, and the duration of therapy.

The electronic search has revealed a total of 83 patients with non-albicans *Candida* PJI. Their mean age was 66.3 years. Although *Candida* PJI is still considered rare, its incidence is expected to rise, due to the increasing number of joint arthroplasty surgeries performed worldwide<sup>[2,48]</sup>.

Several risk factors have been identified for invasive candidiasis, such as immunosuppression, long-term antimicrobial use and systemic disease<sup>[3,4,5,48]</sup>. Such a patient profile has been illustrated by the relatively high mean Charlson comorbidity index of the present study's population, found to be 4.4.

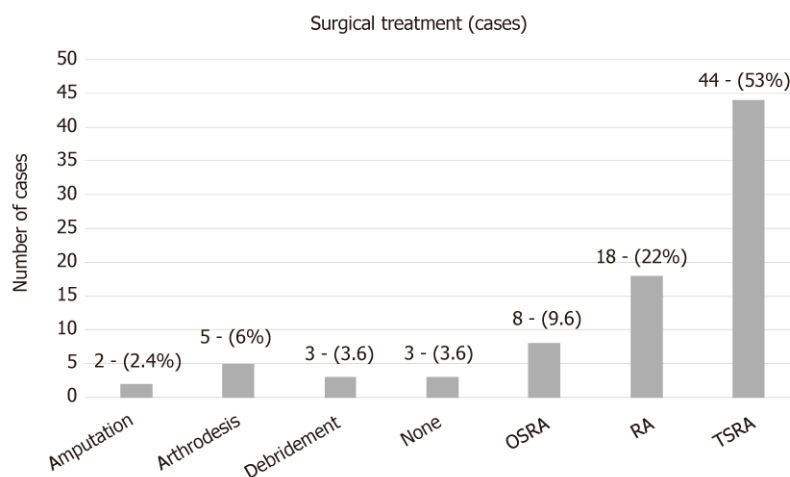
*Candida* PJI is most commonly considered of hematogenous origin<sup>[2,6,48]</sup>. The mean time between initial arthroplasty surgery and symptomatology onset in the study population was 27.2 mo, while it ranged from immediately after surgery to 264 mo. It is of note that in 13 cases [15.7%; cases 8, 23, 47, 51, 54, 55, 57, 60, 61, 69, 70, 82, 83 (Table 1)] this time was found to be less than 1 mo. Therefore, in these cases the spread should be considered perioperative.

It is also of interest that the mean time between symptomatology onset and definite (culture-based) diagnosis was 7.5 mo, ranging from immediately after onset to 60 mo. This could be attributed to the fact that the main symptoms of *Candida* PJI are non-specific, which mainly include pain and swelling<sup>[1-5,48]</sup>. The symptomatology onset may be mild, insidious and slowly progressive. Therefore, diagnosis may be delayed due to low suspicion index.

The most frequently isolated non-albicans *Candida* spp was *C. parapsilosis*, found in 45 cases (54.2%), followed by *C. glabrata* in 18 (21.7%), *C. tropicalis* in 10 (12%), *C. pelliculosa* in 3 (3.6%), *C. lusitanae* in 2 (2.4%) and 1 case each (1.2%) of PJI caused by *C. famata*, *C. lipolytica*, *C. utitis*, *C. guilliermondii* and *C. freyschussii*.

In the present study, *C. parapsilosis* was found to be the predominant pathogen causing PJIs, as compared to other non-albicans *Candida* species. *C. parapsilosis* prevalence has dramatically increased over the last 3 decades. Infections due to this pathogen are more frequently associated with prosthetic devices, indwelling catheters and hyperalimentation solutions. The pathogenesis of the infection depends on the expression of virulence factors, including adherence to host cells and tissues, biofilm formation and secretion of extracellular hydrolytic enzymes<sup>[5,49]</sup>.

The treatment of *C. parapsilosis* PJIs has proven to be successful in 88.9% of the



**Figure 2** Surgical treatment for non-albicans *Candida* prosthetic joint infection. TSRA: Two stage revision arthroplasty; OSRA: One stage revision arthroplasty; RA: Resection arthroplasty.

studied cases. This is probably due to the fact that echinocandins were not used for the treatment of such cases, taking into account that *C. parapsilosis* MICs are usually elevated to echinocandins, as compared to other *Candida* spp<sup>[50]</sup>.

Treatment of *C. glabrata* PJIs has been successful in 94.4% of the studied cases. This is probably due to the fact that an azole compound has rarely been used for treatment and, in the limited number of cases when an azole was used, the drug has been given in combination with another antifungal, taking into account that *C. glabrata* is often resistant to azoles<sup>[50]</sup>. In most cases of *C. tropicalis* PJIs, treatment has been successful, since either single antifungal agents or combinations are known to be effective against this *Candida* spp.

All cases of *C. pelliculosa* PJIs have been treated successfully due to the use of effective agents. *C. lusitanae* is intrinsically resistant to amphotericin B<sup>[50,51]</sup>. One case received this agent in combination with fluconazole, while the other one was treated with voriconazole as monotherapy. Hence, finally, the 2 cases caused by *C. lusitanae* were successfully treated.

The cases of *C. famata*, *C. lypholitica* and *C. utilis* were successfully treated with the antifungals given. It is of note that the single case of *C. guilliermondii*, although treated with a combination of antifungals, resulted in failure. For successful treatment, it is of the utmost importance to carry out susceptibility testing to obtain accurate MIC values following *Candida* isolation, taking into account that different *Candida* species are characterized by intrinsic resistance to certain antifungal compounds. Regarding the preferred antifungal agent, fluconazole was used in most cases [59; (71%), in 31 of them (52.5%) as monotherapy], followed by amphotericin B [41; (49.4%), in 4 (9.8%) as monotherapy]. Fluconazole has been rarely associated with severe hepatotoxicity. Therefore, liver function tests should be performed regularly during prolonged fluconazole therapy<sup>[50,51]</sup>. Amphotericin B is an effective broad spectrum agent. However, it is relatively toxic and its side effects, including renal dysfunction, may restrict its long-term use, which is essential in PJI cases<sup>[6]</sup>. Echinocandins are the most recently developed anti-*Candida* agents. Although *C. parapsilosis* strains mostly exhibit high MICs, these agents can often be clinically effective due to their immunomodulatory properties and the fact that they successfully penetrate biofilms<sup>[52]</sup>.

The mean duration of antifungal treatment in the study population was 12.8 wk, while it ranged from 1 to 53 wk. One case (case 32 in Table 1) did not receive any antifungal treatment. Guidelines for the treatment of osteoarticular infections from *Candida* spp exist. However, no clear recommendations are available for the treatment of such PJIs<sup>[6,48]</sup>. Therefore, the treatment duration is mainly based on the clinical and laboratory findings of each case.

Several options for surgical treatment have also been described. In the study population, in most cases (44 cases; 53%) a TSRA was performed, followed by RA (18 cases; 22%), OSRA (8 cases; 9.6%), arthrodesis (5 cases; 6%), debridement (3 cases; 3.6%) and amputation (2 cases; 2.4%). Three cases did not receive surgical treatment (3.6%; case 4, 55 and 82 in Table 1). RA, arthrodesis, amputation and debridement are usually considered alternative options to arthroplasty exchange. TSRA had a statistically significant higher success rate when compared to OSRA (96% vs 73%; *P*-



value = 0.023). Therefore, it seems more proper that TSRA should be considered as the optimal surgical intervention.

The present review has shown that non-*albicans Candida* PJIs represent a dangerous reality. Optimal management consists of a combination of the proper medical antifungal treatment based on susceptibility testing and surgical intervention. Although there have been reports of successful treatment of such cases with OSRA and debridement only, TSRA should be strongly recommended. The combination of TSRA separated by 3–6 mo and a prolonged period of antifungal therapy is suggested on the basis of limited data. Additional issues, such as the duration of antifungal therapy after prosthesis implantation (second stage of the TSRA), as well as the role of antifungal-loaded cement spacers, need to be addressed in order to determine the optimal treatment combinations.

## ARTICLE HIGHLIGHTS

### Research background

Prosthetic joint infection (PJI) represents a severe complication of joint reconstruction surgery, causing total arthroplasty failure. Many pathogens have been identified in PJIs, such as Gram-positive and negative bacteria, while fungal microorganisms are considered rare causes, occurring in 1–2% of cases. *Candida* spp represent the most common fungal pathogens in these infections, with *Candida albicans* being the most prevalent species. However, the incidence of non-*albicans Candida* PJIs has increased over the last years. Hence, regarding non-*albicans Candida* PJIs, only case reports or small series have been reported so far. Optimal treatment is considered the two stage revision surgery in combination with an antifungal agent. However, no clear guidelines have yet been developed regarding the agent and treatment duration. Hence, a broad range of antifungal and surgical treatments has been reported so far. The present review article represents the first effort of evaluating the reported non-*albicans Candida* PJIs, aiming to clarify the treatment options of these infections and, possibly, to improve the medical and surgical care of such cases.

### Research motivation

The absence of clear guidelines regarding fungal PJIs represents a primary issue in managing these infections in clinical practice. A broad range of antifungal and surgical treatments have been reported, while treatment duration remains unclear. Furthermore, due to the limited data regarding these infections, information about patient demographics, responsible non-*albicans Candida* species, time between initial arthroplasty and symptom onset, time between symptom onset and definite diagnosis (culture), and outcome of the infection has not been reported in a systematic way. Hence, it is of utmost importance in the future to report such cases in order to obtain a better understanding about this devastating arthroplasty complication.

### Research objectives

The main objective of this study was to clarify, by systematically reviewing current published cases in the literature, the treatment options of non-*albicans Candida* PJIs and, possibly, to improve the medical and surgical care of such cases. During the process of reviewing the literature, it became apparent that information about patient demographics, fungal species, time between initial arthroplasty and symptom onset, time between symptom onset and definite diagnosis (culture), as well as outcome of the infection should also be reported, due to the absence of a systematic review regarding this topic.

### Research methods

A meticulous electronic search of PubMed and MEDLINE databases was performed to identify all articles reporting the management of non-*albicans Candida* PJIs cases through April 2018 by two independent investigators. The citations in each article were reviewed to locate additional references that were not retrieved during the initial search. The evaluated parameters were patient demographics and comorbidities, affected joints, responsible non-*albicans Candida* species, duration and type of antifungal treatment, type of surgical treatment, time between initial arthroplasty and symptom onset, time between symptom onset and definite diagnosis (culture), and outcome of the infection. Data were recorded and analyzed using Microsoft Excel 2010 (Microsoft Corporation, Redmond, Washington). Two-sided Fisher's exact tests were used to compare success rates between groups. Statistical analyses were carried out at the 5% level of significance.

### Research results

A total of 83 non-*albicans Candida* PJIs were located, with a mean age of 66.3 years (SD = 10.2). The knee was the affected joint in 52 cases (62.6%), the hip in 29 (35%) and the shoulder in 2 (2.4%). The mean time from arthroplasty to symptoms onset was found to be 27.2 mo (SD = 43), while the mean time from symptoms onset to culture-confirmed diagnosis was 7.5 mo (SD = 12.5). The most commonly isolated non-*albicans Candida* species was *C. parapsilosis*, found in 45 cases (54.2%), followed by *C. glabrata* in 18 (21.7%), *C. tropicalis* in 10 (12%), *C. pelliculosa* in 3 (3.6%) and *C. lusitanae* in 2 (2.4%), while *C. famata*, *C. lipolytica*, *C. utilis*, *C. guilliermondii* and *C. freyschussii* had caused one case each (1.2%). A two stage revision arthroplasty (TSRA) was performed in most cases (44 cases; 53%), followed by RA (18 cases; 22%), OSRA (8 cases; 9.6%),

arthrodesis (5 cases; 6%), debridement (3 cases; 3.6%) and amputation (2 cases; 2.4%), while 3 cases (3.6%) received no surgical treatment. TSRA when compared to OSRA had a higher success rate (96% vs 73%;  $P$ -value = 0.023). Fluconazole was used in most cases as antifungal treatment [59; (71%), in 31 of them (52.5%) as monotherapy], followed by amphotericin B [41; (49.4%), in 4 (9.8%) as monotherapy], flucytosine [13; (15.7%), in 1 (7.7%) as monotherapy], caspofungin [7; (8.4%), in 1 (14.3%) as monotherapy], voriconazole [7; (8.4%), in 2 (28.6%) as monotherapy], ketoconazole [5; (6%), none as monotherapy], itraconazole [3; (3.6%), none as monotherapy] and anidulafungin [1; (1.2%), none as monotherapy]. The final outcome was successful in 74 cases (89.2%). The mean antifungal treatment duration was 12.8 wk (SD = 10.9), while the mean follow-up of these cases was 33.3 mo (SD = 19.6). The present review has shown that the optimal management of non-*albicans* *Candida* consists of a combination of the proper medical antifungal treatment and surgical intervention. Although there have been reports of the successful treatment of such cases with OSRA and debridement only, TSRA should be strongly recommended. The combination of TSRA and a prolonged period of antifungal therapy based on susceptibility testing is suggested on the basis of limited data. Additional issues, such as the duration of antifungal therapy after prosthesis implantation (second stage of the TSRA) and the role of antifungal-loaded cement spacers need to be addressed in order to determine an optimal treatment combination.

### Research conclusions

The present study is an effort to review, in a systematic way, the non-*albicans* *Candida* PJI cases described in the literature. The study focuses on the preferred antifungal agent, the optimal surgical treatment, and the duration of therapy. *C. parapsilosis* was found to be the predominant pathogen causing PJIs, as compared to other non-*albicans* *Candida* species. For successful management of non-*albicans* *Candida* PJI, susceptibility testing to obtain accurate MIC values should always be performed following the *Candida* isolation, considering that different *Candida* species are characterized by intrinsic resistance to certain antifungal compounds. The mean duration of antifungal treatment in the present review was 12.8 wk, while it ranged from 1 to 53 wk. Although, guidelines for the treatment of osteoarticular infections from *Candida* spp are available, no clear recommendations exist for the treatment of such PJIs. Therefore, the treatment duration is mostly based upon clinical and laboratory findings. In most cases (44 cases; 53%) a TSRA was performed, followed by RA (18 cases; 22%), OSRA (8 cases; 9.6%), arthrodesis (5 cases; 6%), debridement (3 cases; 3.6%) and amputation (2 cases; 2.4%). Three cases did not receive surgical treatment (3.6%). RA, arthrodesis, amputation and debridement are usually considered alternative options to arthroplasty exchange. TSRA when compared to OSRA had a statistically significant higher success rate (96% vs 73%;  $P$ -value= 0.023). Therefore, it seems more proper that TSRA should be considered as the optimal surgical intervention. The present review has shown that the optimal management of non-*albicans* *Candida* PJIs consists of a combination of the proper medical antifungal treatment based on susceptibility testing and a surgical intervention, while TSRA should be strongly recommended. The combination of TSRA separated by 3–6 mo, in addition to a prolonged period of antifungal therapy, is suggested.

### Research perspectives

Non-*albicans* *Candida* PJIs represent a dangerous reality. The combination of TSRA separated by 3–6 mo and a prolonged period of antifungal therapy is suggested on the basis of limited data. It is of paramount importance to report the treatment of such cases, even the failed ones, in order to obtain a better understanding of these infections and to determine the optimum treatment combination.

## REFERENCES

1. Pulido L, Ghanem E, Joshi A, Purtill JJ, Parvizi J. Periprosthetic joint infection: the incidence, timing, and predisposing factors. *Clin Orthop Relat Res* 2008; **466**: 1710-1715 [PMID: 18421542 DOI: 10.1007/s11999-008-0209-4]
2. Schoof B, Jakobs O, Schmidl S, Klatte TO, Frommelt L, Gehrke T, Gebauer M. Fungal periprosthetic joint infection of the hip: a systematic review. *Orthop Rev (Pavia)* 2015; **7**: 5748 [PMID: 25874063 DOI: 10.4081/or.2015.5748]
3. Azzam K, Parvizi J, Jungkind D, Hanssen A, Fehring T, Springer B, Bozic K, Della Valle C, Pulido L, Barrack R. Microbiological, clinical, and surgical features of fungal prosthetic joint infections: a multi-institutional experience. *J Bone Joint Surg Am* 2009; **91** Suppl 6: 142-149 [PMID: 19884422 DOI: 10.2106/JBJS.1.00574]
4. Hwang BH, Yoon JY, Nam CH, Jung KA, Lee SC, Han CD, Moon SH. Fungal peri-prosthetic joint infection after primary total knee replacement. *J Bone Joint Surg Br* 2012; **94**: 656-659 [PMID: 22529086 DOI: 10.1302/0301-620X.94B5.28125]
5. Deorukhkar SC, Saini S, Mathew S. Virulence Factors Contributing to Pathogenicity of *Candida tropicalis* and Its Antifungal Susceptibility Profile. *Int J Microbiol* 2014; **2014**: 456878 [PMID: 24803934 DOI: 10.1155/2014/456878]
6. Koutserimpas C, Samonis G, Velivassakis E, Iliopoulou-Kosmadaki S, Kontakis G, Kofteridis DP. *Candida glabrata* prosthetic joint infection, successfully treated with anidulafungin: A case report and review of the literature. *Mycoses* 2018; **61**: 266-269 [PMID: 29272049 DOI: 10.1111/myc.12736]
7. Geng L, Xu M, Yu L, Li J, Zhou Y, Wang Y, Chen J. Risk factors and the clinical and surgical features of fungal prosthetic joint infections: A retrospective analysis of eight cases. *Exp Ther Med* 2016; **12**: 991-999 [PMID: 27446310 DOI: 10.3892/etm.2016.3353]
8. Klatte TO, Kendoff D, Kamath AF, Jonen V, Rueger JM, Frommelt L, Gebauer M, Gehrke T. Single-stage revision for fungal peri-prosthetic joint infection: a single-centre experience. *Bone Joint J* 2014; **96**

- B: 492-496 [PMID: 24692616 DOI: 10.1302/0301-620X.96B4.32179]
- 9 **Zhu Y**, Yue C, Huang Z, Pei F. Candida glabrata infection following total hip arthroplasty: A case report. *Exp Ther Med* 2014; **7**: 352-354 [PMID: 24396403 DOI: 10.3892/etm.2013.1420]
  - 10 **Anagnostakos K**, Kelm J, Schmitt E, Jung J. Fungal periprosthetic hip and knee joint infections clinical experience with a 2-stage treatment protocol. *J Arthroplasty* 2012; **27**: 293-298 [PMID: 21752583 DOI: 10.1016/j.arth.2011.04.044]
  - 11 **Bartalesi F**, Fallani S, Salomoni E, Marcucci M, Meli M, Pecile P, Cassetta MI, Latella L, Bartoloni A, Novelli A. Candida glabrata prosthetic hip infection. *Am J Orthop (Belle Mead NJ)* 2012; **41**: 500-505 [PMID: 23431513]
  - 12 **Hall RL**, Frost RM, Vasukutty NL, Minhas H. Candida glabrata: an unusual fungal infection following a total hip replacement. *BMJ Case Rep* 2012; **2012** [PMID: 23008369 DOI: 10.1136/bcr-2012-006491]
  - 13 **Dumaine V**, Eyrolle L, Baixench MT, Paugam A, Larousserie F, Padoin C, Tod M, Salmon D. Successful treatment of prosthetic knee Candida glabrata infection with caspofungin combined with flucytosine. *Int J Antimicrob Agents* 2008; **31**: 398-399 [PMID: 18242959 DOI: 10.1016/j.ijantimicag.2007.12.001]
  - 14 **Lejko-Zupanc T**, Mozina E, Vrevc F. Caspofungin as treatment for Candida glabrata hip infection. *Int J Antimicrob Agents* 2005; **25**: 273-274 [PMID: 15737527 DOI: 10.1016/j.ijantimicag.2005.01.005]
  - 15 **Fabry K**, Verheyden F, Nelen G. Infection of a total knee prosthesis by Candida glabrata: a case report. *Acta Orthop Belg* 2005; **71**: 119-121 [PMID: 15792220]
  - 16 **Gaston G**, Ogden J. Candida glabrata periprosthetic infection: a case report and literature review. *J Arthroplasty* 2004; **19**: 927-930 [PMID: 15483812 DOI: 10.1016/j.arth.2004.04.012]
  - 17 **Açikgöz ZC**, Sayli U, Avci S, Doğruel H, Gamberzade S. An extremely uncommon infection: Candida glabrata arthritis after total knee arthroplasty. *Scand J Infect Dis* 2002; **34**: 394-396 [PMID: 12069030 DOI: 10.1080/00365540110080232]
  - 18 **Ramamohan N**, Zeineh N, Grigoris P, Butcher I. Candida glabrata infection after total hip arthroplasty. *J Infect* 2001; **42**: 74-76 [PMID: 11243760 DOI: 10.1053/jinf.2000.0763]
  - 19 **Selmon GP**, Slater RN, Shepperd JA, Wright EP. Successful 1-stage exchange total knee arthroplasty for fungal infection. *J Arthroplasty* 1998; **13**: 114-115 [PMID: 9493549 DOI: 10.1016/S0883-5403(98)90086-9]
  - 20 **Nayeri F**, Cameron R, Chrysanthou E, Johansson L, Söderström C. Candida glabrata prosthesis infection following pyelonephritis and septicemia. *Scand J Infect Dis* 1997; **29**: 635-638 [PMID: 9571751 DOI: 10.3109/00365549709035912]
  - 21 **Darouiche RO**, Hamill RJ, Musher DM, Young EJ, Harris RL. Periprosthetic candidal infections following arthroplasty. *Rev Infect Dis* 1989; **11**: 89-96 [PMID: 2916098 DOI: 10.1093/clinids/11.1.89]
  - 22 **Goodman JS**, Seibert DG, Reahl GE, Geckler RW. Fungal infection of prosthetic joints: a report of two cases. *J Rheumatol* 1983; **10**: 494-495 [PMID: 6684169]
  - 23 **Wang QJ**, Shen H, Zhang XL, Jiang Y, Wang Q, Chen YS, Shao JJ. Staged reimplantation for the treatment of fungal peri-prosthetic joint infection following primary total knee arthroplasty. *Orthop Traumatol Surg Res* 2015; **101**: 151-156 [PMID: 25676891 DOI: 10.1016/j.otsr.2014.11.014]
  - 24 **Ueng SW**, Lee CY, Hu CC, Hsieh PH, Chang Y. What is the success of treatment of hip and knee candidal periprosthetic joint infection? *Clin Orthop Relat Res* 2013; **471**: 3002-3009 [PMID: 23633184 DOI: 10.1007/s11999-013-3007-6]
  - 25 **Kuiper JW**, van den Bekerom MP, van der Stapen J, Nolte PA, Colen S. 2-stage revision recommended for treatment of fungal hip and knee prosthetic joint infections. *Acta Orthop* 2013; **84**: 517-523 [PMID: 24171675 DOI: 10.3109/17453674.2013.859422]
  - 26 **Chiu WK**, Chung KY, Cheung KW, Chiu KH. Candida parapsilosis total hip arthroplasty infection: case report and literature review. *J Orthop Trauma* 2013; **17**: 33-36 [DOI: 10.1016/j.jotr.2012.04.008]
  - 27 **Dutrone H**, Dauchy FA, Cazanave C, Rougie C, Lafarie-Castet S, Couprie B, Fabre T, Dupon M. Candida prosthetic infections: case series and literature review. *Scand J Infect Dis* 2010; **42**: 890-895 [PMID: 20608769 DOI: 10.3109/00365548.2010.498023]
  - 28 **Antony S**, Dominguez D C, Jackson J, Misenheimer G. *Evaluation and treatment of candida species in prosthetic joint infections*. *Infect Dis Clin Pract* 2008; 354-359 [DOI: 10.1097/IPC.0b013e31817cfdb7]
  - 29 **Yang SH**, Pao JL, Hang YS. Staged reimplantation of total knee arthroplasty after Candida infection. *J Arthroplasty* 2001; **16**: 529-532 [PMID: 11402423 DOI: 10.1054/arth.2001.21458]
  - 30 **Bruce AS**, Kerry RM, Norman P, Stockley I. Fluconazole-impregnated beads in the management of fungal infection of prosthetic joints. *J Bone Joint Surg Br* 2001; **83**: 183-184 [PMID: 11284561 DOI: 10.1302/0301-620X.83B2.0830183]
  - 31 **Brooks DH**, Puppato F. Successful salvage of a primary total knee arthroplasty infected with Candida parapsilosis. *J Arthroplasty* 1998; **13**: 707-712 [PMID: 9741450 DOI: 10.1016/S0883-5403(98)80017-X]
  - 32 **Wada M**, Baba H, Imura S. Prosthetic knee Candida parapsilosis infection. *J Arthroplasty* 1998; **13**: 479-482 [PMID: 9645532 DOI: 10.1016/S0883-5403(98)90019-5]
  - 33 **Cushing RD**, Fulgenzi WR. Synovial fluid levels of fluconazole in a patient with Candida parapsilosis prosthetic joint infection who had an excellent clinical response. *J Arthroplasty* 1997; **12**: 950 [PMID: 9458262 DOI: 10.1016/S0883-5403(97)90166-2]
  - 34 **Fukasawa N**, Shirakura K. Candida arthritis after total knee arthroplasty--a case of successful treatment without prosthesis removal. *Acta Orthop Scand* 1997; **68**: 306-307 [PMID: 9247001 DOI: 10.3109/17453679708996709]
  - 35 **White A**, Goetz MB. Candida parapsilosis prosthetic joint infection unresponsive to treatment with fluconazole. *Clin Infect Dis* 1995; **20**: 1068-1069 [PMID: 7795057 DOI: 10.1093/clinids/20.4.1068]
  - 36 **Tunkel AR**, Thomas CY, Wispelwey B. Candida prosthetic arthritis: report of a case treated with fluconazole and review of the literature. *Am J Med* 1993; **94**: 100-103 [PMID: 8420285 DOI: 10.1016/0002-9343(93)90127-B]
  - 37 **Paul J**, White SH, Nicholls KM, Crook DW. Prosthetic joint infection due to Candida parapsilosis in the UK: case report and literature review. *Eur J Clin Microbiol Infect Dis* 1992; **11**: 847-849 [PMID: 1468427 DOI: 10.1007/BF01960889]
  - 38 **Lim EV**, Stern PJ. Candida infection after implant arthroplasty. A case report. *J Bone Joint Surg Am* 1986; **68**: 143-145 [PMID: 3510212 DOI: 10.2106/00004623-198668010-00020]
  - 39 **Younkin S**, Evarts CM, Steigbigel RT. Candida parapsilosis infection of a total hip-joint replacement: successful reimplantation after treatment with amphotericin B and 5-fluorocytosine. A case report. *J Bone Joint Surg Am* 1984; **66**: 142-143 [PMID: 6690437 DOI: 10.2106/00004623-198466010-00023]
  - 40 **Lichtman EA**. Candida infection of a prosthetic shoulder joint. *Skeletal Radiol* 1983; **10**: 176-177 [PMID: 6635692 DOI: 10.1007/BF00357775]

- 41 **MacGregor RR**, Schimmer BM, Steinberg ME. Results of combined amphotericin B-5-fluorocytosine therapy for prosthetic knee joint infected with Candida parapsilosis. *J Rheumatol* 1979; **6**: 451-455 [PMID: [392095](#)]
- 42 **Sebastian S**, Malhotra R, Pande A, Gautam D, Xess I, Dhawan B. Staged Reimplantation of a Total Hip Prosthesis After Co-infection with Candida tropicalis and Staphylococcus haemolyticus: A Case Report. *Mycopathologia* 2018; **183**: 579-584 [PMID: [28735470](#) DOI: [10.1007/s11046-017-0177-x](#)]
- 43 **Reddy KJ**, Shah JD, Kale RV, Reddy TJ. Fungal prosthetic joint infection after total knee arthroplasty. *Indian J Orthop* 2013; **47**: 526-529 [PMID: [24133317](#) DOI: [10.4103/0019-5413.118213](#)]
- 44 **Lidder S**, Tasleem A, Masterson S, Carrington RW. Candida tropicalis: diagnostic dilemmas for an unusual prosthetic hip infection. *J R Army Med Corps* 2013; **159**: 123-125 [PMID: [23720596](#) DOI: [10.1136/jramc-2013-000053](#)]
- 45 **Azam A**, Singh PK, Singh VK, Siddiqui A. A Rare Case of Candida Tropicalis Infection of a Total Hip Arthroplasty: A Case Report and Review of Literature. *MOJ* 2008; **2**: 43-46 [DOI: [10.5704/MOJ.0811.011](#)]
- 46 **Wyman J**, McGough R, Limbird R. Fungal infection of a total knee prosthesis: successful treatment using articulating cement spacers and staged reimplantation. *Orthopedics* 2002; **25**: 1391-4; discussion 1394 [PMID: [12502204](#) DOI: [10.1007/s00132-002-0391-0](#)]
- 47 **Lambertus M**, Thordarson D, Goetz MB. Fungal prosthetic arthritis: presentation of two cases and review of the literature. *Rev Infect Dis* 1988; **10**: 1038-1043 [PMID: [3055186](#) DOI: [10.1093/clinids/10.5.1038](#)]
- 48 **Pappas PG**, Kauffman CA, Andes DR, Clancy CJ, Marr KA, Ostrosky-Zeichner L, Reboli AC, Schuster MG, Vazquez JA, Walsh TJ, Zaoutis TE, Sobel JD. Executive Summary: Clinical Practice Guideline for the Management of Candidiasis: 2016 Update by the Infectious Diseases Society of America. *Clin Infect Dis* 2016; **62**: 409-417 [PMID: [26810419](#) DOI: [10.1093/cid/civ1194](#)]
- 49 **Trofa D**, Gácser A, Nosanchuk JD. Candida parapsilosis, an emerging fungal pathogen. *Clin Microbiol Rev* 2008; **21**: 606-625 [PMID: [18854483](#) DOI: [10.1128/CMR.00013-08](#)]
- 50 **Sanguinetti M**, Posteraro B, Lass-Flörl C. Antifungal drug resistance among Candida species: mechanisms and clinical impact. *Mycoses* 2015; **58** Suppl 2: 2-13 [PMID: [26033251](#) DOI: [10.1111/myc.12330](#)]
- 51 **Pasternak B**, Wintzell V, Furu K, Engeland A, Neovius M, Stephansson O. Oral Fluconazole in Pregnancy and Risk of Stillbirth and Neonatal Death. *JAMA* 2018; **319**: 2333-2335 [PMID: [29896619](#) DOI: [10.1001/jama.2018.6237](#)]
- 52 **Dimopoulou D**, Hamilos G, Tzardi M, Lewis RE, Samonis G, Kontoyiannis DP. Anidulafungin versus caspofungin in a mouse model of candidiasis caused by anidulafungin-susceptible Candida parapsilosis isolates with different degrees of caspofungin susceptibility. *Antimicrob Agents Chemother* 2014; **58**: 229-236 [PMID: [24145540](#) DOI: [10.1128/AAC.01025-13](#)]



Published By Baishideng Publishing Group Inc  
7041 Koll Center Parkway, Suite 160, Pleasanton, CA 94566, USA  
Telephone: +1-925-2238242  
Fax: +1-925-2238243  
E-mail: [bpgoffice@wjgnet.com](mailto:bpgoffice@wjgnet.com)  
Help Desk: <https://www.f6publishing.com/helpdesk>  
<https://www.wjgnet.com>

