


# World Journal of *Clinical Cases*

*World J Clin Cases* 2019 July 26; 7(14): 1732-1907



**REVIEW**

- 1732** Diagnostic-therapeutic management of bile duct cancer  
*Huguet JM, Lobo M, Labrador JM, Boix C, Albert C, Ferrer-Barceló L, Durá AB, Suárez P, Iranzo I, Gil-Raga M, Burgos CBD, Sempere J*

**MINIREVIEWS**

- 1753** Current status of the adjuvant therapy in uterine sarcoma: A literature review  
*Rizzo A, Pantaleo MA, Saponara M, Nannini M*
- 1764** New treatment modalities in Alzheimer's disease  
*Koseoglu E*
- 1775** Endoscopic ultrasound-guided fine-needle aspiration biopsy - Recent topics and technical tips  
*Matsumoto K, Takeda Y, Onoyama T, Kawata S, Kurumi H, Koda H, Yamashita T, Isomoto H*
- 1784** Antiviral treatment for chronic hepatitis B: Safety, effectiveness, and prognosis  
*Wu YL, Shen CL, Chen XY*

**ORIGINAL ARTICLE****Retrospective Cohort Study**

- 1795** Prevalence of anal fistula in the United Kingdom  
*Hokkanen SR, Boxall N, Khalid JM, Bennett D, Patel H*

**Retrospective Study**

- 1805** Predictors of dehydration and acute renal failure in patients with diverting loop ileostomy creation after colorectal surgery  
*Vergara-Fernández O, Trejo-Avila M, Santes O, Solórzano-Vicuña D, Salgado-Nesme N*

**Prospective Study**

- 1814** Desimplification to multi-tablet antiretroviral regimens in human immunodeficiency virus-type 1 infected adults: A cohort study  
*Rossi MC, Inojosa WO, Battistella G, Carniato A, Farina F, Giobbia M, Fuser R, Scotton PG*

**SYSTEMATIC REVIEWS**

- 1825** Cost-analysis of inpatient and outpatient parenteral antimicrobial therapy in orthopaedics: A systematic literature review  
*Boese CK, Lechler P, Frink M, Hackl M, Eysel P, Ries C*

## CASE REPORT

- 1837** Primary gastric choriocarcinoma - a rare and aggressive tumor with multilineage differentiation: A case report  
*Gurzu S, Copotoiu C, Tugui A, Kwizera C, Szodorai R, Jung I*
- 1844** Adrenal metastasis from endometrial cancer: A case report  
*Da Dalt G, Friziero A, Grego A, Serafini S, Fassina A, Blandamura S, Sperti C*
- 1850** Open reduction of a total talar dislocation: A case report and review of the literature  
*Yapici F, Coskun M, Arslan MC, Ulu E, Akman YE*
- 1857** Duodenal intussusception secondary to ampullary adenoma: A case report  
*Hirata M, Shirakata Y, Yamanaka K*
- 1865** Colorectal neuroendocrine carcinoma: A case report and review of the literature  
*Yoshida T, Kamimura K, Hosaka K, Doumori K, Oka H, Sato A, Fukuhara Y, Watanabe S, Sato T, Yoshikawa A, Tomidokoro T, Terai S*
- 1876** Noteworthy effects of a long-pulse Alexandrite laser for treatment of high-risk infantile hemangioma: A case report and literature review  
*Su WT, Xue JX, Ke YH*
- 1884** Primary neuroendocrine tumor in the presacral region: A case report  
*Zhang R, Zhu Y, Huang XB, Deng C, Li M, Shen GS, Huang SL, Huangfu SH, Liu YN, Zhou CG, Wang L, Zhang Q, Deng YP, Jiang B*
- 1892** Pulmonary Langerhans cell histiocytosis in adults: A case report  
*Wang FF, Liu YS, Zhu WB, Liu YD, Chen Y*
- 1899** Multiline treatment of advanced squamous cell carcinoma of the lung: A case report and review of the literature  
*Yang X, Peng P, Zhang L*

**ABOUT COVER**

Editorial Board Member of *World Journal of Clinical Cases*, Byung-Wook Kim, MD, PhD, Professor, Division of Gastroenterology, Department of Internal Medicine, Incheon St. Mary's Hospital, the Catholic University of Korea, Incheon 21431, South Korea

**AIMS AND SCOPE**

*World Journal of Clinical Cases* (*World J Clin Cases*, *WJCC*, online ISSN 2307-8960, DOI: 10.12998) is a peer-reviewed open access academic journal that aims to guide clinical practice and improve diagnostic and therapeutic skills of clinicians.

The primary task of *WJCC* is to rapidly publish high-quality Case Report, Clinical Management, Editorial, Field of Vision, Frontier, Medical Ethics, Original Articles, Meta-Analysis, Minireviews, and Review, in the fields of allergy, anesthesiology, cardiac medicine, clinical genetics, clinical neurology, critical care, dentistry, dermatology, emergency medicine, endocrinology, family medicine, gastroenterology and hepatology, *etc.*

**INDEXING/ABSTRACTING**

The *WJCC* is now indexed in PubMed, PubMed Central, Science Citation Index Expanded (also known as SciSearch®), and Journal Citation Reports/Science Edition. The 2019 Edition of Journal Citation Reports cites the 2018 impact factor for *WJCC* as 1.153 (5-year impact factor: N/A), ranking *WJCC* as 99 among 160 journals in Medicine, General and Internal (quartile in category Q3).

**RESPONSIBLE EDITORS FOR THIS ISSUE**

Responsible Electronic Editor: *Jie Wang*

Proofing Production Department Director: *Yun-Xiaojuan Wu*

**NAME OF JOURNAL**

*World Journal of Clinical Cases*

**ISSN**

ISSN 2307-8960 (online)

**LAUNCH DATE**

April 16, 2013

**FREQUENCY**

Semimonthly

**EDITORS-IN-CHIEF**

Dennis A Bloomfield, Sandro Vento

**EDITORIAL BOARD MEMBERS**

<https://www.wjgnet.com/2307-8960/editorialboard.htm>

**EDITORIAL OFFICE**

Jin-Lei Wang, Director

**PUBLICATION DATE**

July 26, 2019

**COPYRIGHT**

© 2019 Baishideng Publishing Group Inc

**INSTRUCTIONS TO AUTHORS**

<https://www.wjgnet.com/bpg/gerinfo/204>

**GUIDELINES FOR ETHICS DOCUMENTS**

<https://www.wjgnet.com/bpg/GerInfo/287>

**GUIDELINES FOR NON-NATIVE SPEAKERS OF ENGLISH**

<https://www.wjgnet.com/bpg/gerinfo/240>

**PUBLICATION MISCONDUCT**

<https://www.wjgnet.com/bpg/gerinfo/208>

**ARTICLE PROCESSING CHARGE**

<https://www.wjgnet.com/bpg/gerinfo/242>

**STEPS FOR SUBMITTING MANUSCRIPTS**

<https://www.wjgnet.com/bpg/GerInfo/239>

**ONLINE SUBMISSION**

<https://www.f6publishing.com>



## Open reduction of a total talar dislocation: A case report and review of the literature

Furkan Yapici, Mehmet Coskun, Muhammet Coskun Arslan, Erman Ulu, Yunus Emre Akman

**ORCID number:** Furkan Yapici (0000-0002-5349-4580); Mehmet Coskun (0000-0002-9691-1751); Muhammet Coskun Arslan (0000-0002-4791-231X); Erman Ulu (0000-0002-2757-953X); Yunus Emre Akman (0000-0003-2939-0519).

**Author contributions:** Akman YE and Yapici F were the patient's orthopedic surgeons, and they reviewed the literature and contributed to drafting the manuscript; Coskun M, Ulu E, and Arslan MC reviewed the literature and drafted the manuscript; Akman YE and Yapici F were responsible for the revision of the manuscript for important intellectual content; all authors gave final approval for the version to be submitted.

**Informed consent statement:** Informed written consent was obtained from the patient for publication of this report and any accompanying images.

**Conflict-of-interest statement:** The authors declare that they have no conflict of interest.

**CARE Checklist (2016) statement:** The authors have read the CARE Checklist (2013), and the manuscript was prepared and revised according to the CARE Checklist (2016).

**Open-Access:** This article is an open-access article which was selected by an in-house editor and fully peer-reviewed by external reviewers. It is distributed in accordance with the Creative Commons Attribution Non Commercial (CC BY-NC 4.0)

**Furkan Yapici, Mehmet Coskun, Muhammet Coskun Arslan, Erman Ulu,** Department of Orthopedics and Traumatology, Metin Sabancı Baltalimanı Bone and Joint Diseases Education and Research Hospital, Istanbul 34470, Turkey

**Yunus Emre Akman,** Department of Orthopedics and Traumatology, Demiroğlu Bilim University Faculty of Medicine, Istanbul 34387, Turkey

**Corresponding author:** Furkan Yapici, MD, Doctor, Surgeon, Department of Orthopedics and Traumatology, Metin Sabancı Baltalimanı Bone and Joint Diseases Education and Research Hospital, No. 62, Rumeli Hisarı Street, 34470 Baltalimanı, Sariyer, Istanbul 34470, Turkey. [furkanyapici@hotmail.com](mailto:furkanyapici@hotmail.com)  
**Telephone:** +90-212-3237075  
**Fax:** +90-212-3237095

### Abstract

#### BACKGROUND

Total talar dislocation (TTD) is very uncommon for many orthopedic surgeons and emergency/trauma specialists. Scarce cases of TTD have been reported, mainly in the form of open fracture-dislocation injury.

#### CASE SUMMARY

We report a very rare injury of closed TTD with a follow-up period of 36 mo. Initial closed reduction was not successful because of a fractured highly unstable medial malleolus displaced into the ankle mortise, blocking the relocation of the talus. The patient was able to walk pain-free after the 3<sup>rd</sup> month of surgery. At the 36-mo follow-up, there were 10 degrees of flexion loss and 10 degrees of extension loss in the tibiotalar joint. Furthermore, 5 degrees of subtalar joint inversion-eversion loss was present.

#### CONCLUSION

Open reduction should be performed for closed TTDs unless closed reduction is successful.

**Key words:** Total talar dislocation; Pan-talar dislocation; Talus; Case report

©The Author(s) 2019. Published by Baishideng Publishing Group Inc. All rights reserved.

**Core tip:** Total talar dislocation occurs as a result of high energy trauma and may lead to permanent disability or amputation. A non-displaced medial malleolus may prevent closed reduction of the talus if it displaces in the ankle mortise. Therefore, open

license, which permits others to distribute, remix, adapt, build upon this work non-commercially, and license their derivative works on different terms, provided the original work is properly cited and the use is non-commercial. See: <http://creativecommons.org/licenses/by-nc/4.0/>

**Manuscript source:** Unsolicited manuscript

**Received:** February 2, 2019

**Peer-review started:** February 11, 2019

**First decision:** April 18, 2019

**Revised:** May 2, 2019

**Accepted:** May 23, 2019

**Article in press:** May 23, 2019

**Published online:** July 26, 2019

**P-Reviewer:** El Ghoch M, Vidal EIO

**S-Editor:** Ji FF

**L-Editor:** Wang TQ

**E-Editor:** Wu YXJ



reduction may be needed. Successful results are possible, ensuring that the remaining vascular supply is not harmed. Additionally, a negative Hawkins sign might not indicate talar avascular necrosis with certainty.

**Citation:** Yapici F, Coskun M, Arslan MC, Ulu E, Akman YE. Open reduction of a total talar dislocation: A case report and review of the literature. *World J Clin Cases* 2019; 7(14): 1850-1856

**URL:** <https://www.wjgnet.com/2307-8960/full/v7/i14/1850.htm>

**DOI:** <https://dx.doi.org/10.12998/wjcc.v7.i14.1850>

## INTRODUCTION

The body weight is transferred to the foot by the talus, which is vulnerable to injuries because of the absence of muscular attachments. The shape of the talus and its strong ligamentous support holds it in the ankle mortise.

Total talar dislocation (TTD; dislocation of the tibiotalar, subtalar, and talonavicular joints) with or without an accompanying fracture is an extremely rare type of injury<sup>[1]</sup>. TTD accounts for 0.06% of all dislocations and 2% of all talar injuries<sup>[2]</sup>. TTD treatment is subject to complications such as avascular necrosis (AVN), osteoarthritis, and infection due to the limited talar blood supply and frequency of open injury<sup>[3-8]</sup>. The incidence of open injury among reported TTDs was reportedly to be 84.9% (73 of 86 cases) in the latest systematic review by Weston *et al*<sup>[9]</sup>; only three patients (3.5%) were able to be treated by closed reduction, and 50% of TTDs were associated with fractures, especially talus fracture (37.3%).

The tenuous blood supply of the talus is provided by the dorsalis pedis artery, peroneal arteries, tarsal canal and sinus arteries, deltoid artery, and their branches or anastomoses<sup>[6,10,11]</sup>. However, given the rarity of TTD, many aspects of this injury are not fully understood, and there is no established treatment protocol. Many surgeons may have never treated this type of injury in their surgical careers<sup>[12]</sup>. We aim to share our clinical experience and outcomes of this rare dislocation in order to improve the clinical understanding of TTD.

## CASE PRESENTATION

### Chief complaint

A 32-year-old man presented to the Emergency Department of our hospital after falling from a 3-meter ladder onto his feet.

### History of past illness

The patient's past medical history was unremarkable.

### Physical examination

Physical examination revealed no open wounds but gross swelling and pain of either ankle. The skin was intact bilaterally. The dislocated talar head was prominent under the lateral border of the foot but did not lead to pressure necrosis or blisters. There was no neurovascular compromise bilaterally. Dorsalis pedis and tibialis posterior artery pulses were palpable. Our clinical considerations were, first, a talar dislocation and, second, a pilon fracture of the tibia.

### Laboratory examinations

The blood biochemistries, chest X-ray films, and arterial blood gases were normal.

### Imaging examinations

Plain films and computed tomography scans revealed anterolateral TTD and fracture of the medial malleolus on the right side and a pilon fracture on the left side (Figure 1). Plain films of the dorsolumbar vertebrae, pelvis, bilateral knee, and femur were also obtained because of the possibility of axial load fracture during the fall.

## FINAL DIAGNOSIS



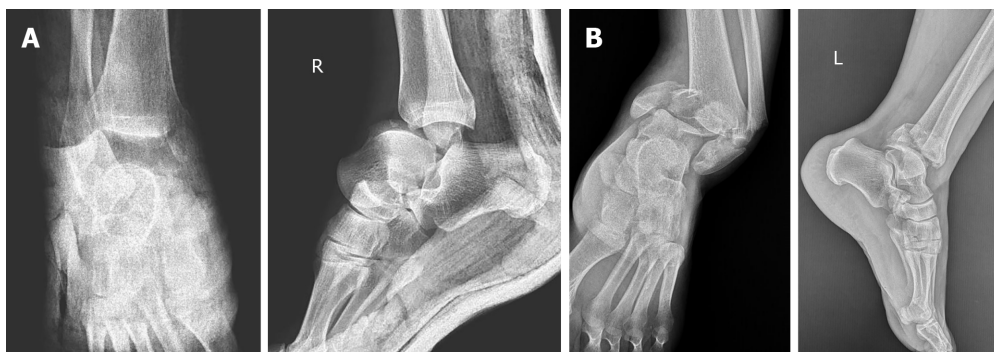


Figure 1 Anteroposterior and lateral ankle radiographs of the right ankle (A) showing anterolateral total talus dislocation accompanied by a fracture of the medial malleolus and pilon fracture of the left ankle (B).

The final diagnosis was anterolateral dislocation of the talus and non-displaced medial malleolus fracture of the right ankle, and pilon fracture of the left tibia.

## TREATMENT

Closed reduction of the right TTD in the emergency room was not successful. During the reduction by simple traction with the knee flexed 90 degrees, the fractured highly unstable medial malleolus displaced into the ankle mortise, blocking the relocation of the talus (Figure 2). Therefore, open reduction by the medial and lateral approach was performed.

After reduction of the medial malleolus and the talus, the medial malleolus was fixed using the tension band technique (Figure 3). Next, subtalar, tibiotalar, talonavicular, and calcaneocuboid joints were checked for the tendency to dislocate. Tibiotalar and talonavicular joints were unstable. Therefore, two Kirschner (K) wires were inserted horizontally from the lateral malleolus to the talus in order to increase the stability of the tibiotalar joint. A K-wire for the talonavicular joint was used for maintenance of the reduction. A short-leg cast was placed after surgery. Due to the swelling in the left ankle, external fixation was performed in order to restore the alignment, and open reduction and internal fixation with locking anatomical plates and screws using anterolateral and posterolateral approaches were performed two weeks after the initial surgery (Figure 4).

## OUTCOME AND FOLLOW-UP

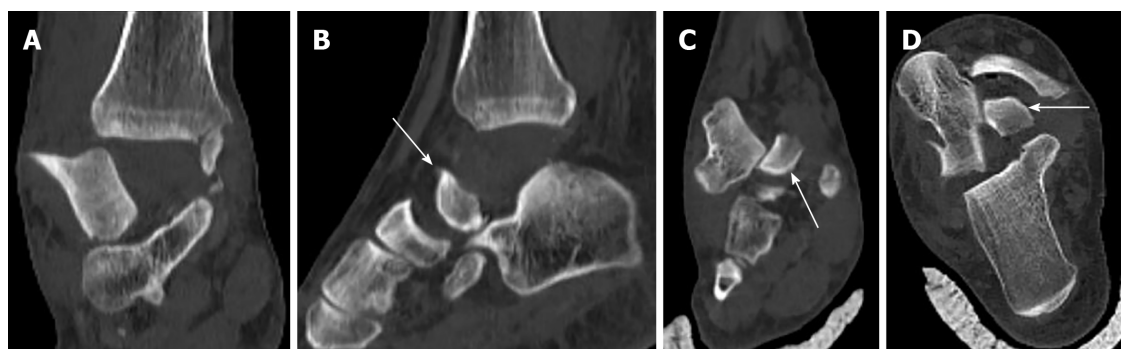The K-wires were removed at the 6<sup>th</sup> postoperative week. After surgery, any weight-bearing was avoided for six weeks. Postoperative radiographs obtained in the 6<sup>th</sup> postoperative week revealed no Hawkins sign (Figure 5).

Hawkins sign is a subchondral radiolucent band in the talar dome that can be observed on anteroposterior ankle radiographs. This radiolucent band is formed by an increase in bone reabsorption and accompanied by active hyperemia of the talus. Therefore, the blood supply of the talus must be preserved. Hawkins sign is a good prognostic factor suggesting that the blood supply to the talus has been preserved and AVN will likely not occur<sup>[13]</sup>. The sensitivity and specificity of Hawkins sign are reported to be 100% and 57.7%, respectively, and it is present between the 6<sup>th</sup> and 9<sup>th</sup> weeks after trauma. In contrast, the absence of the Hawkins sign is not a reliable factor for predicting AVN or the development of talar collapse. In the absence of the Hawkins sign, magnetic resonance imaging (MRI) should be performed if there is any clinical or radiographic suspicion of AVN<sup>[14]</sup>.

The patient was able to walk with crutches with mild pain during the 6<sup>th</sup> postoperative week and was pain-free at the third month. At 36-month follow-up, there were 10 degrees of flexion loss and 10 degrees of extension loss in the tibiotalar joint. Furthermore, 5 degrees of subtalar joint inversion-eversion loss was present.

## DISCUSSION

One of the significant findings of this study is that an initially non-displaced medial



**Figure 2** Computed tomography images after unsuccessful closed reduction showing fractured highly unstable medial malleolus displaced into the ankle mortise, blocking the relocation of the talus. A: Coronal view demonstrating the extent of extrusion of the talus under the tibial plafond; B: Sagittal view demonstrating the medial malleolus in the ankle mortise (arrow); C and D: Coronal and axial views demonstrating the displaced medial malleolus blocking the talus (arrows).

malleolus may prevent closed reduction of the talus if it displaces in the ankle mortise. Therefore, open reduction may become a necessity. We speculate that closed reduction should always be the first choice of reduction to prevent disruption of the remaining tenuous vascular supply. It is possible to achieve good results even by open reduction and fixation with the necessary sensitivity to the soft tissue around talus. Another main finding is that despite the absence of Hawkins sign, a good prognosis and result are possible.

The talus has no muscular or tendinous attachments, and 60% of its surface is articular. Maintaining the position of the talus is only possible with its unique ligamentous support: The heavy talocalcaneal interosseous ligament, the anterior/posterior tibiotalar deltoid components medially, and the anterior/posterior talofibular ligaments laterally<sup>[1]</sup>.

TTD is generally due to a car/motorcycle accident or a fall from a height. A rarer clinical entity called “missing talus” may occur if the talus is completely extruded out of the skin<sup>[1]</sup>. In the present case, the talus was dislocated out of the mortise but did not extrude out of the skin after the fall from a height.

Talar dislocations may be subtalar or total. Subtalar dislocation involves the talocalcaneal and talonavicular joints, whereas TTD involves tibiotalar dislocation in addition to subtalar dislocation. There are three types of TTD: anterolateral (common), medial, and posterior. This case had an anterolateral TTD involving the tibiotalar, talonavicular, and talocalcaneal joints.

TTD is generally an open-type injury. Closed TTD is an extremely infrequent injury<sup>[2]</sup>. Surgical debridement and open reduction are necessary for open TTDs. Furthermore, external fixation may be needed because of wounds, injury, and concomitant fracture. Closed reduction with sedation in the emergency room and a short-leg cast may be sufficient for closed TTDs without fracture.

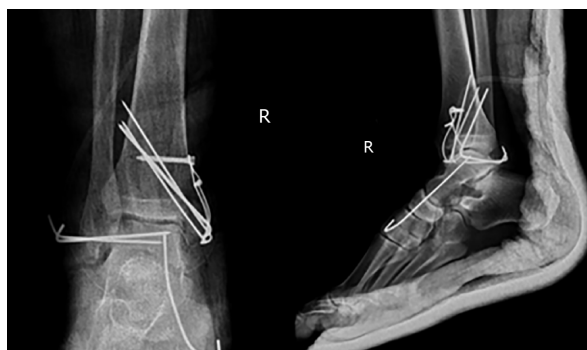
Neurovascular, capsular, and ligamentous injuries and pressure necrosis are early concomitant injuries related to TTD. Late complications are more worrisome, including AVN, infection, and post-traumatic degenerative arthritis. Post-traumatic arthritis may occur even after several years. No neurovascular injuries were encountered in this case. There was an anterolateral capsular tear treated by primary suturing, and an anterior talofibular ligament sprain treated conservatively.

Good prognosis and clinical outcome without AVN or arthritis have been reported<sup>[7]</sup>. However, according to some authors, the reported prognosis was very poor<sup>[3]</sup>, and the risk of post-traumatic talar AVN is as high as 90%, especially in the first year after the injury<sup>[15]</sup>. AVN is the most common complication (26%) of TTD, followed by radiographic osteoarthritis (22%), clinical osteoarthritis (16%), and infection (12%), as reported in the latest systematic review<sup>[9]</sup>.

In our patient, six-week radiographs revealed no Hawkins sign. The six-week MRI revealed only talar bone bruising and edema, but no signs of AVN (Figure 6). Patients should be monitored by MRI for early AVN. Hawkins sign can be seen in serial radiographs as well. All reported closed anterolateral TTDs, as in this case, were treated by closed reduction and showed no signs of AVN at follow-up<sup>[10]</sup>.

One of the major TTD series is reported by Detenbeck and Kelly<sup>[3]</sup>, with the majority of cases being the open type. In Detenbeck's mini-series of nine patients, there were seven open, and two closed TTDs. Eight developed sepsis. Seven of nine were treated by talectomy. Five patients required tibiocalcaneal arthrodesis and one required amputation.





**Figure 3 Anteroposterior and lateral ankle radiographs of the right ankle after surgery.** After the reduction of the medial malleolus and the talus, the medial malleolus was fixed using the tension band technique because of instability of the tibiotalar and talonavicular joints. Two Kirschner (K) wires were inserted horizontally from the lateral malleolus to the talus in order to increase the stability of the tibiotalar joint and a K-wire for the talonavicular joint was used for the maintenance of the reduction.

Various treatment procedures exist, including debridement, fracture fixations if necessary, closed/open reductions, and talectomy with or without tibiocalcaneal arthrodesis for open TTDs<sup>[16]</sup>. In the Palomo-Traver's review, closed reduction was recommended except in cases of gross contamination or complete extrusion<sup>[16]</sup>. Furthermore, there is no consensus for closed TTD treatment, such as open<sup>[7]</sup> or closed reduction<sup>[17]</sup>; however, in recent years, closed reduction has become the treatment of choice<sup>[17]</sup>. Some authors reported favorable outcomes after closed reduction<sup>[18]</sup>.

Although Detenbeck and Kelly reported that total or partial talectomy might be necessary even in closed TTD<sup>[3]</sup>, only two of nine patients had closed TTD, both of whom had talar fractures and the treatment was delayed because of head injury in one of them. The first closed TTD patient in Detenbeck and Kelly's mini-series had a talus neck and body fracture treated by open reduction, internal fixation, and subtalar fusion. Two days later, the ankle joint became infected and was revised by talectomy, open drainage, and tibiocalcaneal arthrodesis. Their second patient with closed TTD also had a talar body fracture, and because of the head injury, only a compression dressing was applied for initial treatment. Septicemia developed because of hematogenous seeding of the ankle infection and draining sinuses. The second patient was also treated by talectomy and tibiocalcaneal arthrodesis.

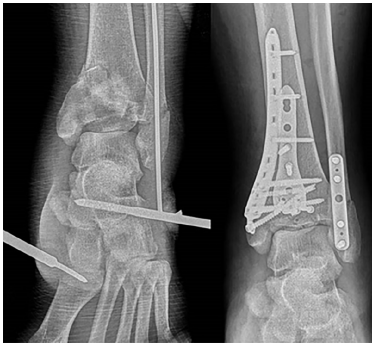
Fixation with the K-wire may be performed in cases of with a tendency for dislocation, and cast or external fixator immobilization is recommended for six to eight weeks<sup>[7]</sup>. In the present case, we inserted two K-wires through the lateral malleolus and one K-wire through the navicular to the talus in order to maintain reduction temporarily for six weeks. Few high-level studies have reported the superiority of either closed or open reduction. Therefore, closed or open reduction appears to be a treatment of choice<sup>[7]</sup>.

### **Strengths and limitations of the study**

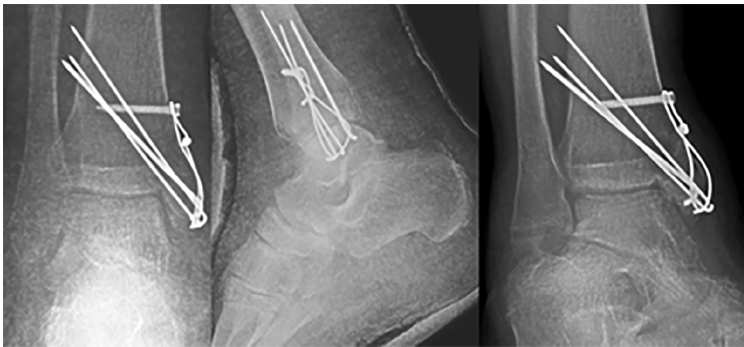
We believe that our study makes a significant contribution to the literature because this combination of injuries is extremely rare, and the illustration of our case will help orthopedic surgeons who encounter similar cases in the future. Nevertheless, more studies with a higher level of evidence and higher number of cases are needed to gain a better clinical understanding and treatment protocol for TTD.

## **CONCLUSION**

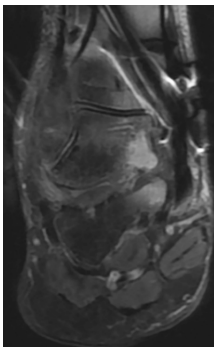
In our opinion, for closed TTDs, the closed reduction should be performed first not to jeopardize the remaining vascular supply of the talus if possible. If closed reduction is unsuccessful, open reduction should be performed, as in this case. In terms of life-threatening conditions such as sepsis, talectomy with or without tibiocalcaneal fusion and amputation are the procedures to be undertaken as a last resort. Positive Hawkins sign is a good prognostic factor in terms of AVN, but absence of the sign does not indicate that AVN will likely occur.



**Figure 4** Anteroposterior ankle radiographs of the left ankle after surgery on the left and after two weeks on the right. Due to the swelling in the left ankle, external fixation was performed in order to restore the alignment and open reduction, and internal fixation with locking anatomical plates and screws using anterolateral and posterolateral approaches was performed two weeks after the initial surgery.



**Figure 5** AP, mortise, and lateral ankle radiographs of the right ankle after removal of the talofibular and talonavicular K-wires at the 6<sup>th</sup> postoperative week. Note that there was no Hawkins sign.



**Figure 6** Magnetic resonance imaging at 6 weeks revealing only talar bone bruising and edema but no signs of avascular necrosis.

## REFERENCES

- 1 **Hiraizumi Y**, Hara T, Takahashi M, Mayehiyo S. Open total dislocation of the talus with extrusion (missing talus): report of two cases. *Foot Ankle* 1992; **13**: 473-477 [PMID: [1483609](#) DOI: [10.1177/107110079201300808](#)]
- 2 **El Ibrahim A**, Shimi M, Elidrissi M, Daoudi A, Elmrini A. A case of closed total dislocation of talus and literature review. *Am J Emerg Med* 2011; **29**: 475.e1-475.e3 [PMID: [20674234](#) DOI: [10.1016/j.ajem.2010.04.021](#)]
- 3 **Detenbeck LC**, Kelly PJ. Total dislocation of the talus. *J Bone Joint Surg Am* 1969; **51**: 283-288 [PMID: [4975068](#) DOI: [10.1002/\(SICI\)1099-0690\(199812\)1998:12<2855::AID-EJOC2855>3.0.CO](#)]
- 4 **Jaffe KA**, Conlan TK, Sardis L, Meyer RD. Traumatic talectomy without fracture: four case reports and review of the literature. *Foot Ankle Int* 1995; **16**: 583-587 [PMID: [8563929](#) DOI: [10.1177/107110079501600913](#)]
- 5 **Kleiger B**. Injuries of the talus and its joints. *Clin Orthop Relat Res* 1976; 243-262 [PMID: [991510](#) DOI: [10.1097/00003086-197611000-00039](#)]
- 6 **Rammelt S**, Zwipp H. Talar neck and body fractures. *Injury* 2009; **40**: 120-135 [PMID: [18439608](#) DOI: [10.1016/j.injury.2008.01.021](#)]

- 7 **Wagner R**, Blattert TR, Weckbach A. Talar dislocations. *Injury* 2004; **35** Suppl 2: SB36-SB45 [PMID: 15315877 DOI: 10.1016/j.injury.2004.07.010]
- 8 **Pereles TR**, Koval KJ, Feldman DS. Fracture-dislocation of the neck of the talus in a ten-year-old child: a case report and review of the literature. *Bull Hosp Jt Dis* 1996; **55**: 88-91 [PMID: 8879745]
- 9 **Weston JT**, Liu X, Wandtke ME, Liu J, Ebraheim NE. A systematic review of total dislocation of the talus. *Orthop Surg* 2015; **7**: 97-101 [PMID: 26033988 DOI: 10.1111/os.12167]
- 10 **Schiffer G**, Jubel A, Elsner A, Andermahr J. Complete talar dislocation without late osteonecrosis: clinical case and anatomic study. *J Foot Ankle Surg* 2007; **46**: 120-123 [PMID: 17331872 DOI: 10.1053/j.jfas.2006.11.004]
- 11 **Katz BE**, Yang E. Complete closed posterior talus dislocation without fracture. *Orthopedics* 2000; **23**: 846-848 [PMID: 10952049 DOI: 10.1007/s001320050520]
- 12 **Maffulli N**, Francobandiera C, Lepore L, Cifarelli V. Total dislocation of the talus. *J Foot Surg* 1989; **28**: 208-212 [PMID: 2696744]
- 13 **Donnelly EF**. The Hawkins sign. *Radiology* 1999; **210**: 195-196 [PMID: 9885607 DOI: 10.1148/radiology.210.1.r99ja08195]
- 14 **Tezval M**, Dumont C, Stürmer KM. Prognostic reliability of the Hawkins sign in fractures of the talus. *J Orthop Trauma* 2007; **21**: 538-543 [PMID: 17805020 DOI: 10.1097/BOT.0b013e318148c665]
- 15 **Sarabia Condes JM**, De Casas Fernández E, Salmerón Martínez EJ. Subtotal talus dislocation. *Foot Ankle Surg* 2003; **9**: 45-49 [DOI: 10.1016/S1268-7731(02)00007-3]
- 16 **Palomo-Traver JM**, Cruz-Renovell E, Granell-Beltran V, Monzonis-García J. Open total talus dislocation: case report and review of the literature. *J Orthop Trauma* 1997; **11**: 45-49 [PMID: 8990034 DOI: 10.1097/00005131-199701000-00014]
- 17 **Vick J**. [Total dislocation of the talus]. *Zentralbl Chir* 1967; **92**: 184-188 [PMID: 5584727 DOI: 10.1007/s00590-011-0881-z]
- 18 **Xarchas KC**, Psillakis IG, Kazakos KJ, Pelekas S, Ververidis AN, Verettas DA. Total Dislocation of the Talus without a Fracture. Open or Closed Treatment? Report of Two Cases and Review of the Literature. *Open Orthop J* 2009; **3**: 52-55 [PMID: 19590615 DOI: 10.2174/1874325000903010052]



Published By Baishideng Publishing Group Inc  
7041 Koll Center Parkway, Suite 160, Pleasanton, CA 94566, USA  
Telephone: +1-925-2238242  
Fax: +1-925-2238243  
E-mail: [bpgoffice@wjgnet.com](mailto:bpgoffice@wjgnet.com)  
Help Desk: <https://www.f6publishing.com/helpdesk>  
<https://www.wjgnet.com>

