

World Journal of *Gastrointestinal Surgery*

World J Gastrointest Surg 2019 April 27; 11(4): 198-246





REVIEW

- 198 Pancreatic necrosis: Complications and changing trend of treatment
Rashid MU, Hussain I, Jehanzeb S, Ullah W, Ali S, Jain AG, Khetpal N, Ahmad S

ORIGINAL ARTICLE

Retrospective Cohort Study

- 218 Preoperative bowel preparation does not favor the management of colorectal anastomotic leak
Zorbas KA, Yu D, Choudhry A, Ross HM, Philp M

CASE REPORT

- 229 Malignant transformation of hepatocellular adenoma in a young female patient after ovulation induction fertility treatment: A case report
Glinka J, Clariá RS, Fratanoni E, Spina J, Mullen E, Ardiles V, Mazza O, Pekolj J, de Santibañes M, de Santibañes E
- 237 Management of infected pancreatic necrosis in the setting of concomitant rectal cancer: A case report and review of literature
Choi K, Flynn DE, Karunairajah A, Hughes A, Bhasin A, Devereaux B, Chandrasegaram MD

ABOUT COVER

Associate Editor of *World Journal of Gastrointestinal Surgery*, Ying-Bin Liu, MD, Professor, Department of General Surgery, Xinhua Hospital Affiliated to Shanghai Jiao Tong University School of Medicine, Shanghai; Institute of Biliary Tract Disease, Shanghai Jiao Tong University School of Medicine, Shanghai 200092, China

AIMS AND SCOPE

World Journal of Gastrointestinal Surgery (*World J Gastrointest Surg*, *WJGS*, online ISSN 1948-9366, DOI: 10.4240) is a peer-reviewed open access academic journal that aims to guide clinical practice and improve diagnostic and therapeutic skills of clinicians.

The *WJGS* covers topics concerning micro-invasive surgery; laparoscopy; hepatic, biliary, pancreatic and splenic surgery; surgical nutrition; portal hypertension, as well as associated subjects. The current columns of *WJGS* include editorial, frontier, diagnostic advances, therapeutics advances, field of vision, mini-reviews, review, original articles, case report, etc.

We encourage authors to submit their manuscripts to *WJGS*. We will give priority to manuscripts that are supported by major national and international foundations and those that are of great basic and clinical significance.

INDEXING/ABSTRACTING

The *WJGS* is now abstracted and indexed in PubMed, PubMed Central, Emerging Sources Citation Index (Web of Science), China National Knowledge Infrastructure (CNKI), China Science and Technology Journal Database (CSTJ), and Superstar Journals Database.

RESPONSIBLE EDITORS FOR THIS ISSUE

Responsible Electronic Editor: Yun-Xiaojuan Wu Proofing Editorial Office Director: Jin-Lei Wang

NAME OF JOURNAL

World Journal of Gastrointestinal Surgery

ISSN

ISSN 1948-9366 (online)

LAUNCH DATE

November 30, 2009

FREQUENCY

Monthly

EDITORS-IN-CHIEF

Varut Lohsiriwat, Shu-You Peng

EDITORIAL BOARD MEMBERS

<https://www.wjgnet.com/1948-9366/editorialboard.htm>

EDITORIAL OFFICE

Jin-Lei Wang, Director

PUBLICATION DATE

April 27, 2019

COPYRIGHT

© 2019 Baishideng Publishing Group Inc

INSTRUCTIONS TO AUTHORS

<https://www.wjgnet.com/bpg/gerinfo/204>

GUIDELINES FOR ETHICS DOCUMENTS

<https://www.wjgnet.com/bpg/GerInfo/287>

GUIDELINES FOR NON-NATIVE SPEAKERS OF ENGLISH

<https://www.wjgnet.com/bpg/gerinfo/240>

PUBLICATION MISCONDUCT

<https://www.wjgnet.com/bpg/gerinfo/208>

ARTICLE PROCESSING CHARGE

<https://www.wjgnet.com/bpg/gerinfo/242>

STEPS FOR SUBMITTING MANUSCRIPTS

<https://www.wjgnet.com/bpg/GerInfo/239>

ONLINE SUBMISSION

<https://www.f6publishing.com>



Management of infected pancreatic necrosis in the setting of concomitant rectal cancer: A case report and review of literature

Kihoon Choi, David E Flynn, Anitha Karunairajah, Andrew Hughes, Ambika Bhasin, Benedict Devereaux, Manju D Chandrasegaram

ORCID number: Kihoon Choi (0000-0003-3197-031X); David E Flynn (0000-0003-2150-3849); Anitha Karunairajah (0000-0002-9430-8326); Andrew Hughes (0000-0001-5637-1669); Ambika Bhasin (0000-0003-0194-6095); Benedict Devereaux (0000-0003-1795-5690); Manju D Chandrasegaram (0000-0002-4826-5038).

Author contributions: Choi K, Karunairajah A and Flynn DE were involved in the manuscript drafting, editing and revision and performed literature reviews; Bhasin A interpreted and reported on the radiographic findings within the case and was involved in the editing and drafting of the manuscript; Devereaux B, Chandrasegaram MF, Hughes A were consultants involved in the care of the patient and were involved in editing and reviewing the manuscript.

Informed consent statement: Informed signed consent was obtained from the patient for publication of this report and any accompanying images.

Conflict-of-interest statement: The authors declare that they have no conflict of interest.

CARE Checklist (2016) statement: The authors have read the CARE Checklist (2016), and the manuscript was prepared and revised according to the CARE Checklist (2016).

Open-Access: This article is an

Kihoon Choi, Department of Surgery, Gold Coast University Hospital, Southport, QLD 4215, Australia

David E Flynn, Anitha Karunairajah, Andrew Hughes, Manju D Chandrasegaram, Department of General Surgery, the Prince Charles Hospital, Brisbane, QLD 4032, Australia

Ambika Bhasin, Department of Radiology, the Prince Charles Hospital, Brisbane, QLD 4032, Australia

Benedict Devereaux, Department of Gastroenterology, Royal Brisbane and Women's Hospital, Brisbane, QLD 4029, Australia

Corresponding author: Manju D Chandrasegaram, FRCS, MBChB, Surgeon, Department of General Surgery, the Prince Charles Hospital, Rode Road, Chermside, QLD 4032, Australia. m.chandrasegaram@uq.edu.au
Telephone: +61-7-31393268
Fax: +61-7-31394651

Abstract

BACKGROUND

Pancreatitis with infected necrosis is a severe complication of acute pancreatitis and carries with it high rates of morbidity and mortality. The management of infected pancreatic necrosis alongside concomitant colorectal cancer has never been described in literature.

CASE SUMMARY

A 77 years old gentleman presented to the Emergency Department of our hospital complaining of ongoing abdominal pain for 8 h. The patient had clinical features of pancreatitis with a raised lipase of 3810 U/L. A computed tomography (CT) abdomen confirmed pancreatitis with extensive peri-pancreatic edema. During the course of his admission, the patient had persistent high fevers and delirium thought secondary to infected necrosis, prompting the commencement of broad-spectrum antibiotic therapy with Piperacillin/Tazobactam. Subsequent CT abdomen confirmed extensive pancreatic necrosis (over 70%). Patient was managed with supportive therapy, nutritional support and gut rest initially and improved over the course of his admission and was discharged 42 d post admission. He represented 24 d following his discharge with fever and chills and a repeat CT abdomen scan noted gas bubbles within the necrotic pancreatic tissue thereby confirming

open-access article which was selected by an in-house editor and fully peer-reviewed by external reviewers. It is distributed in accordance with the Creative Commons Attribution Non Commercial (CC BY-NC 4.0) license, which permits others to distribute, remix, adapt, build upon this work non-commercially, and license their derivative works on different terms, provided the original work is properly cited and the use is non-commercial. See: <http://creativecommons.org/licenses/by-nc/4.0/>

Manuscript source: Unsolicited manuscript

Received: March 2, 2019

Peer-review started: March 4, 2019

First decision: March 19, 2019

Revised: March 24, 2019

Accepted: April 9, 2019

Article in press: April 9, 2019

Published online: April 27, 2019

P-Reviewer: Granero-Castro B

S-Editor: Ji FF

L-Editor: A

E-Editor: Wu YXJ



infected necrotic pancreatitis. This CT scan also revealed asymmetric thickening of the rectal wall suspicious for malignancy. A rectal cancer was confirmed on flexible sigmoidoscopy. The patient underwent two endoscopic necrosectomies and was treated with intravenous antibiotics and was discharged after 28 d. Within 1 wk post discharge, the patient commenced a course of neoadjuvant radiotherapy and subsequently underwent concomitant chemotherapy prior to undergoing a successful Hartmann's procedure for treatment of his colorectal cancer.

CONCLUSION

This case highlights the efficacy of endoscopic necrosectomy, early enteral feeding and targeted antibiotic therapy for timely management of infected necrotic pancreatitis. The prompt resolution of pancreatitis permitted the patient to undergo neoadjuvant treatment and resection for his concomitant colorectal cancer.

Key words: Necrotizing pancreatitis; Rectal cancer; Enteral nutrition; Endoscopy; Case report

©The Author(s) 2019. Published by Baishideng Publishing Group Inc. All rights reserved.

Core tip: Early identification of infected pancreatic necrosis is critical to minimizing the associated high morbidity and mortality of this disease. A high index of clinical suspicion combined with radiological evidence will guide the discerning clinician towards instituting targeted antibiotic therapy and enteral feeding in a timely manner. As soon as it is clinically feasible, minimally invasive necrosectomy should be considered to achieve definitive source control. Efficient resolution of infection is especially important for patients who require urgent treatment for other life-threatening conditions, such as colorectal cancer.

Citation: Choi K, Flynn DE, Karunairajah A, Hughes A, Bhasin A, Devereaux B, Chandrasegaram MD. Management of infected pancreatic necrosis in the setting of concomitant rectal cancer: A case report and review of literature. *World J Gastrointest Surg* 2019; 11(4): 237-246

URL: <https://www.wjgnet.com/1948-9366/full/v11/i4/237.htm>

DOI: <https://dx.doi.org/10.4240/wjgs.v11.i4.237>

INTRODUCTION

Acute pancreatitis is a common and potentially deadly disease. Up to one in five patients diagnosed with acute pancreatitis will develop infected necrosis of the pancreatic parenchyma^[1]. Infection of the necrotic area may lead to sepsis and multi-organ failure and is associated with a high mortality^[2,3]. Early enteral feeding, targeted antibiotics and drainage of the necrotic area have been shown to improve outcomes. Colorectal cancer is similarly a common and potentially deadly disease that requires prompt intervention. There have been no published reports of these two conditions being managed concomitantly. Concurrent management of both conditions requires timely stabilization and treatment of the necrotizing pancreatitis prior to commencing treatment of colorectal cancer. We present herein, the first case of a patient with simultaneous infected necrotizing pancreatitis and colorectal cancer.

CASE PRESENTATION

Chief complaints

A 77 years old male presented to the emergency department complaining of lower abdominal pain with associated nausea and vomiting.

History of presenting illness

The patient described sudden onset severe, cramping lower abdominal pain that continued for 8 h prior to presentation. The patient also experienced several bouts of

nausea and vomiting since onset of the pain.

History of past illness, social history and family history

The patient previously had a L3-5 laminectomy and a right total knee replacement. He was a non-smoker with a history of occasional social alcohol intake, but reported abstaining from alcohol for the preceding 6 mo. He also reported no previous episodes of pancreatitis and no contributory family history.

Medication history

The patient was taking Oxycodone/Naloxone (5/2.5 mg) twice daily for lower back pain, prior to presentation.

Physical examination

On examination the patient had a heart rate of 65 beats per minute and a blood pressure of 175/78. His respiratory rate was 16 with saturations of 99% on room air. The patient was afebrile at 37.6 °C. The patient's abdomen was mildly distended and diffusely tender across the lower abdomen.

Initial laboratory examinations

Blood analysis showed an elevated lipase of 3810 U/L (< 60) and derangement of liver function tests. Bilirubin was 56 mmol/L (< 20 mmol/L), ALP 128 U/L (30-110 U/L), GGT 326 U/L (< 55 U/L), ALT 341 U/L (< 45 U/L) and AST 412 U/L (< 35 U/L). Hemoglobin was 139 g/L (120-180 g/L) and white blood count was raised at 16.7×10^9 /L ($3.5\text{--}11.0 \times 10^9$ /L). The patient's serum C-reactive protein (CRP) was 6.2 (< 5).

Initial imaging examinations

The initial computed tomography (CT) abdomen scan showed extensive peripancreatic edema involving the neck and body of the pancreas. An abdominal ultrasound showed multiple mobile calculi within the gallbladder, measuring up to 7 mm. The common bile duct was dilated to a diameter of 9.6 mm however a calculus was unable to be visualized.

Further management of the patient

Throughout the first week of admission, the patient continued to have severe abdominal pain, fevers up to 39.4 °C and periods of delirium. Broad spectrum antibiotic therapy, *i.e.*, IV Piperacillin/Tazobactam 4.5 g tds, was continued for the first 5 d. During this time the white cell count continued to rise and peaked at 20.4×10^9 /L on day 4. Numerous blood cultures were also acquired during this period, but all samples demonstrated no growth.

A CT abdomen scan on day 5 showed extensive necrosis involving over 70% of the pancreas (Figure 1). This significant degree of necrosis combined with worsening inflammatory markers and continuing fevers with delirium prompted suspicion for infected necrotic pancreatitis. Consequently, the antibiotic regimen was changed from IV Piperacillin/Tazobactam 4.5 g tds to IV Meropenem 1 g tds and IV Fluconazole 400 mg daily, on day 5 of admission.

Enteral feeding was also commenced via nasogastric tube on day 5, but had to be discontinued on day 6 due to development of ileus. Enteral feeds were reinstated on day 11 and continued until discharge without further complication.

On day 10 of admission, the patient experienced one episode of small volume, painless bright red rectal bleeding. There was no palpable rectal mass on digital rectal examination. At this point in time, the rectal bleeding was presumed to be secondary to splenic flexure colitis or inflammatory changes in the mesocolon which were evident on CT abdomen scan (Figure 2).

On day 19, antibiotic therapy was ceased due to clinical and biochemical improvement. However, 4 d later the patient developed worsening abdominal pain and fevers. The patient was re-started on IV Meropenem and IV Fluconazole. A progress CT abdomen scan was suggestive of infected necrosis around the pancreatic body as evidenced by an interval increase in size and peripheral enhancement, despite the absence of gas (Figure 3).

The antibiotic regime was continued for a further 17 d. During this time, the patient's delirium resolved, he tolerated all enteral feeds, and he progressed to independent mobilisation. After maintaining a stable clinical status for 2 d post cessation of antibiotic therapy, the patient was discharged home on day 42. On discharge the patient's serum CRP was 8.2. He was due to be followed up in clinic 4-6 wk following his discharge in the outpatient department. Our plan was to allow the pancreatic necrosis sufficient time to mature and wall off adequately, in order to facilitate drainage either endoscopically or surgically.

Unfortunately, 22 d following his discharge the patient represented to the

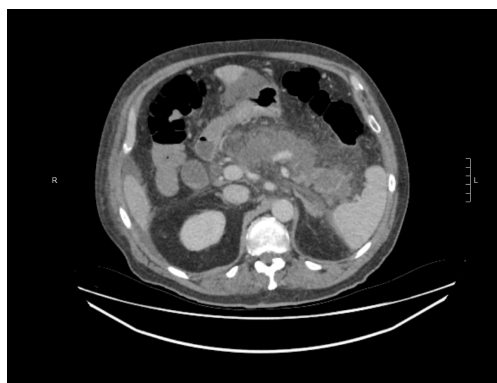


Figure 1 Axial contrast enhanced computed tomography scan showing extensive pancreatic necrosis with non-enhancement of the pancreas.

Emergency Department with fever and rigors before he was seen in the outpatient department. He was hemodynamically stable, and his abdomen was non-tender, however the serum CRP had increased to 142 mg/L and white cell count was $14.6 \times 10^9/L$. Repeat CT abdomen revealed infected necrosis with the presence of gas locules within a large walled off cavity (Figure 4). Subsequently, the patient was admitted and commenced on IV Piperacillin/Tazobactam 4.5 g tds.

The CT scan of his abdomen on readmission raised a new concern of a possible rectal malignancy with thickening of the rectal wall, which had not been appreciated on previous imaging. The patient underwent a flexible sigmoidoscopy on day 4 of his second admission, which revealed a fungating but non-obstructing 8 cm lesion in the rectum. Biopsy of the mass, magnetic resonance imaging of the rectum and staging CT confirmed a T3bN1aM0 adenocarcinoma of rectum (Figure 5). This finding led to an increased level of urgency to definitively manage the infected pancreatic necrosis to facilitate treatment of the rectal cancer.

The decision to drain the infected necrosis at this stage was driven primarily because he had presented with clinical features of infection and had developed new radiological features of infected necrosis with gas locules within the area of walled off necrosis. It was also an appropriate time for intervention given the collection was sufficiently mature and walled off making it a safe time to do so. The rectal cancer made it crucial for us to adequately drain his collection but the decision to intervene at this stage was driven primarily by his clinical features of infection and radiological features which supported this being an appropriate time to intervene.

By this stage (approximately 10 wk post-presentation), the patient had developed a sufficiently mature and walled off collection on imaging. This could have been approached endoscopically or surgically *via* a transgastric route. The authors preferred the endoscopic approach over surgery as this was less invasive and would have avoided the added insult of surgery and inherent morbidity associated with this. Surgery was reserved at this stage only if the endoscopic approach failed consistent with a step-up approach.

The patient was referred for endoscopic drainage and debridement of his walled off necrosis by the therapeutic gastroenterology team. On day 11 of his second admission he underwent endoscopic ultrasound guided Hot-AXIOS stent placement (Boston Scientific, Marlborough, MA, United States) and insertion (Figure 6). Further endoscopic debridement and removal of the nasocystic catheter was performed on day 18. At this procedure, pulsations of an arterial vessel were visible in the center of the necrotic cavity raising concern of possible arterial erosion and major hemorrhage. The AXIOS stent was therefore removed and two plastic, double-pigtail stents were positioned across the cyst-gastrostomy to ensure patency and ongoing drainage.

The patient's recovery post-endoscopic necrosectomy was uncomplicated and he was discharged on day 28. Notably, he had received IV antibiotic therapy for the entire admission. The case was discussed at the oncology multidisciplinary meeting where it was initially decided to commence neoadjuvant radiotherapy without chemotherapy due to the presence of infected pancreatic necrosis.

The patient started neoadjuvant radiotherapy (50 Gy in 25 fractions) for his rectal cancer one week following his discharge. Given that he tolerated this without adverse effects and with effective ongoing drainage of his walled off pancreatic necrosis, he was then trialed on chemotherapy (Capecitabine) 10 d following his radiotherapy. He also tolerated the chemotherapy well.

Ten weeks post completion of chemoradiotherapy, the patient underwent a

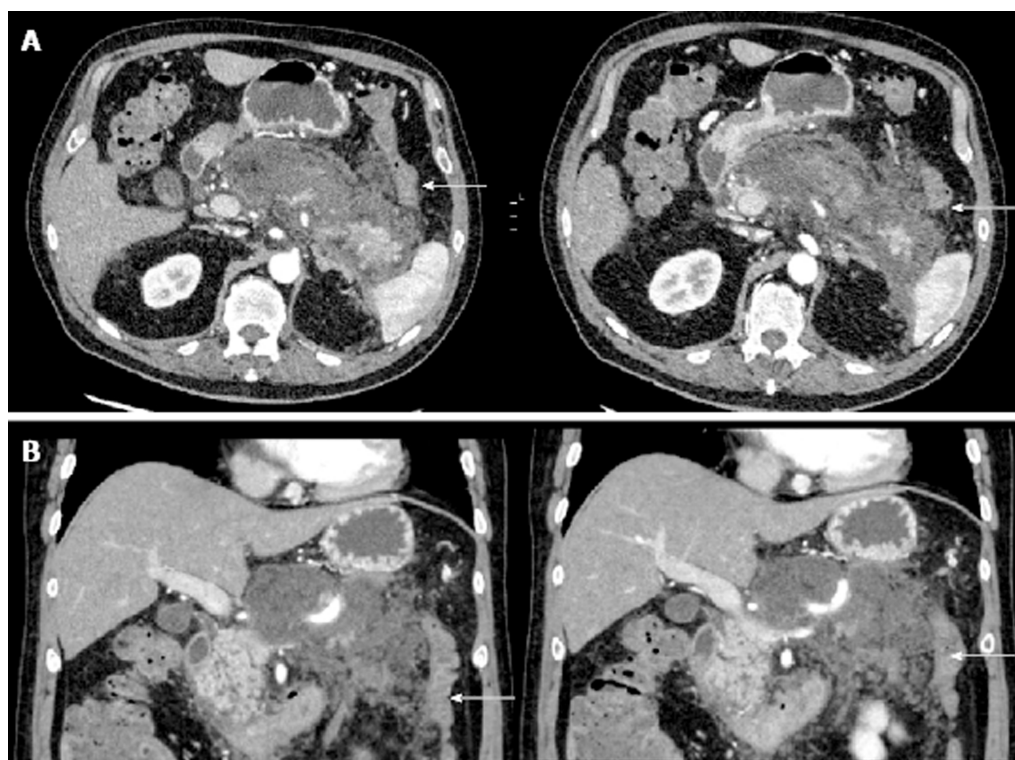


Figure 2 Contrast enhanced computed tomography scan showing peripancreatic oedema and mesocolic inflammatory change. A: Axial contrast enhanced computed tomography (CT) scan showing marked peripancreatic oedema extending into the lesser sac and to the splenic flexure (arrow showing splenic flexure of colon); B: Coronal contrast enhanced CT scan showing colon (arrow) with adjacent mesocolic inflammatory change secondary to pancreatitis.

laparoscopic ultra-low Hartmann's procedure and cholecystectomy. At the time of surgery, both the splenic flexure and mesocolon were fixed secondary to the inflammatory change from pancreatitis. These operative findings reinforced the decision to perform a non-restorative procedure, which had been discussed with the patient prior to surgery. Post-operative recovery was uneventful.

Histopathology revealed a T3 N0 low grade rectal adenocarcinoma with Grade 1 (moderate response) to neoadjuvant treatment. There was no lymphatic, vascular or perineural invasion and the margins of excision were clear. The patient attended regular general surgical outpatient appointments for review of his pancreatic necrosis as well as his rectal cancer. At 1 year follow up, there were no complications from the pancreatitis or evidence of rectal cancer recurrence.

FINAL DIAGNOSIS

Infected pancreatic necrosis and concomitant T3bN1aM0 adenocarcinoma of rectum adenocarcinoma of rectum.

TREATMENT

The patient had endoscopic drainage of their infected pancreatic necrosis and stabilization of this in order to enable receipt of neoadjuvant chemoradiotherapy prior to resection of their rectal cancer.

OUTCOME AND FOLLOW-UP

The patient has recovered well and remains disease free at one year follow-up.

DISCUSSION

Pancreatic necrosis occurs in up to 30% of patients with acute pancreatitis and carries

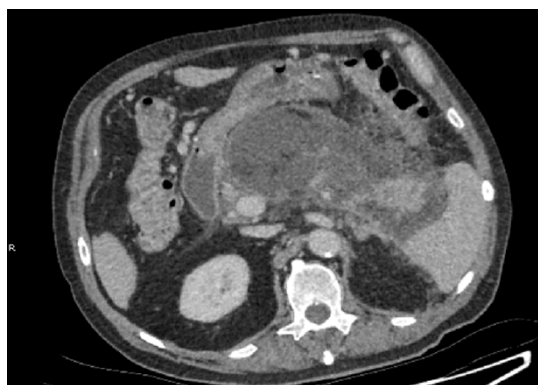

Figure 3 Axial contrast enhanced computed tomography scan showing interval increase in size and peripheral enhancement of wall of pancreatic necrosis.

a high morbidity and mortality^[3-8]. Our patient developed extensive necrosis of over 70% his pancreas. Necrosis of greater than 30% of the pancreas is associated with a morbidity of greater than 70% and a mortality rate of 11%–25%^[9].

Infection of the necrotic area may lead to sepsis and multi-organ failure thereby compounding morbidity and mortality. The management of necrotizing pancreatitis has changed drastically over the past several decades, with an associated improvement in morbidity and mortality rates^[10-12].

Interestingly, management of necrotizing pancreatitis with concomitant colorectal cancer has never been described in literature and presents several unique challenges in order to facilitate stabilization of pancreatitis, timely therapy and surgical resection of the colorectal cancer. In this case, several factors contributed to shortening the clinical course of the infected necrotizing pancreatitis, namely: Use of endoscopic step up procedure for necrosectomy management, early enteral feeding, early antibiotic treatment and staged chemotherapy and resection. Swift resolution of pancreatitis permitted the patient to undergo prompt neoadjuvant chemotherapy and surgical resection of the colorectal cancer.

The use of a minimally invasive endoscopic “step up approach” for management of infected necrosis consists of endoscopic transluminal drainage followed by endoscopic necrosectomy if the initial drainage doesn’t result in clinical improvement. This technique has been performed since the early 2000’s^[13] and has been shown in several trials^[14,15] be superior to outcomes of surgical necrosectomy with regards to major complications and mortality. Our patient’s case was amenable to endoscopic debridement given the stable, walled off necrosis surrounding the pancreas and was undertaken to facilitate a quicker recovery than if the patient had undergone a surgical necrosectomy. The endoscopic approach also helped to avoid further complications from general anesthesia and surgical intervention which would prolong progression onto chemoradiotherapy and colorectal resection.

Nutritional support is an essential component in the treatment of patients with severe pancreatitis due to the hyper-catabolic state and negative nitrogen balance associated with the disease^[16-19]. Furthermore acute malnutrition secondary to acute pancreatitis has been shown to result in immunological disturbances, septic complications, and delayed healing of wounds^[20]. Multiple randomized control trials (RCTs) and meta analyses have demonstrated the benefit of early enteral nutrition in necrotizing pancreatitis^[18,21-24]. Early enteral feeding is associated with beneficial outcomes in necrotizing pancreatitis, lower rates of mortality, systemic infections and multi-organ failure^[25]. This is thought to be due to enteral nutrition maintaining the integrity of the gut barrier as a means of preventing bacterial translocation, which is the most likely cause of the systemic inflammatory response seen in necrotizing pancreatitis^[26-30]. Our patient developed an ileus shortly after institution of enteral nutrition. Following resolution of the ileus, the patient was restarted on enteral feeds and tolerated them well throughout the remainder of his admission. The early enteral feeding helped to maintain gut wall integrity, possibly delaying superinfection in our patient.

Prophylactic antibiotic use in severe pancreatitis has been a contentious issue since the 1970’s. Death from infected necrosis ensues in anywhere from 20%-80% of patients and occurs in approximately 40%-70% of patients with acute necrotizing pancreatitis^[28,31]. Although the mechanism is unclear, clinical data suggests that organism transmission from GI tract to the pancreas is the most likely source of infection^[32]. Within the past decade, several RCTs and meta-analyses have examined

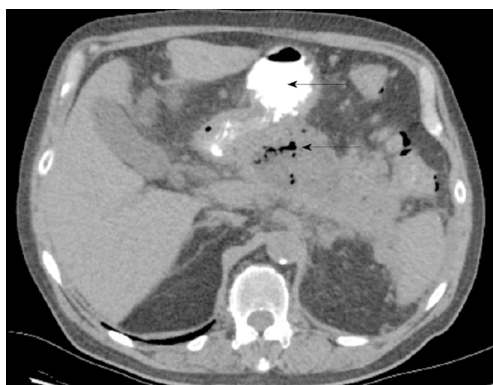

Figure 4 Walled of necrosis with locules of gas. Oral contrast seen within the stomach (solid arrow).

the use of prophylactic antibiotics in the context of acute necrotising pancreatitis and have shown no statistically significant reduction in rates of infected necrosis or mortality^[33-35]. With our case, antibiotics and anti-fungal agents were commenced early in the course as there was significant clinical suspicion of active infective necrosis given the patients consistently high temperatures, persistent periods of delirium and areas of enlarging necrotic tissue on imaging.

The implementation of the endoscopic step up procedure, early enteral support and antibiotics facilitated our patient's recovery to a point where he was able to undergo therapy for his colorectal cancer. Definitive source control achieved by debridement of the infected necrotic tissue facilitated his neoadjuvant radiotherapy treatment. The success of this treatment then facilitated progression onto neoadjuvant chemotherapy (which was initially withheld) and finally on to surgical resection. Due to scarring from the inflammatory process around the splenic flexure and the difficulty in mobilizing the bowel, a Hartmann's procedure was performed. This was deemed the most appropriate long term solution for the patient in view of the significant intraabdominal scarring.

CONCLUSION

The management of infected pancreatic necrosis with concomitant rectal cancer has not been described and presents unique challenges. Management of infected pancreatic necrosis with adequate nutritional support, antimicrobial therapy and ultimately a minimally invasive endoscopic necrosectomy, facilitated resolution and adequate drainage of the infected pancreatic necrosis. This enabled the patient to go on to receive neoadjuvant treatment for his rectal cancer prior to surgical resection.

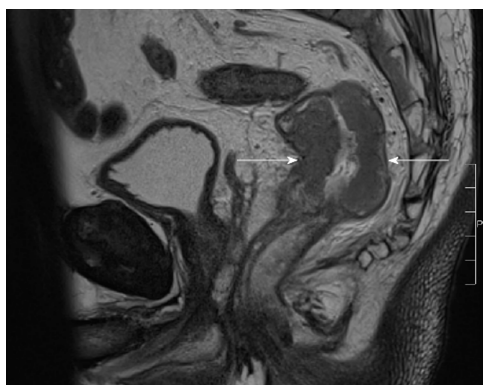


Figure 5 T2 sagittal view of magnetic resonance imaging rectum. Arrows showing rectal cancer.

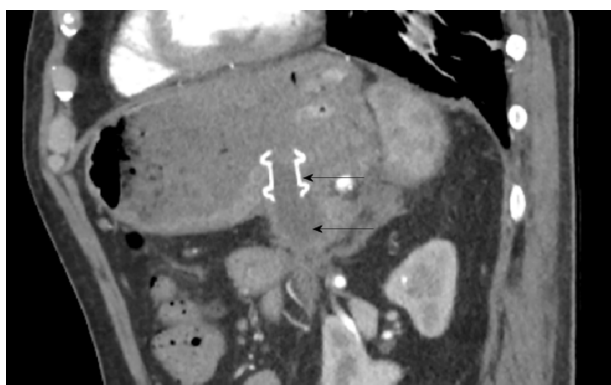


Figure 6 Sagittal computed tomography exam. AXIOS cystogastrostomy stent Solid arrow showing stent. Hollow arrow delineating small residual cyst.

REFERENCES

- 1 **van Brunschot S**, Fockens P, Bakker OJ, Besselink MG, Voermans RP, Poley JW, Gooszen HG, Bruno M, van Santvoort HC. Endoscopic transluminal necrosectomy in necrotising pancreatitis: a systematic review. *Surg Endosc* 2014; **28**: 1425-1438 [PMID: 24399524 DOI: 10.1007/s00464-013-3382-9]
- 2 **van Santvoort HC**, Bakker OJ, Bollen TL, Besselink MG, Ahmed Ali U, Schrijver AM, Boermeester MA, van Goor H, Dejong CH, van Eijck CH, van Ramshorst B, Schaapherder AF, van der Harst E, Hofker S, Nieuwenhuijs VB, Brink MA, Kruyt PM, Manusama ER, van der Schelling GP, Karsten T, Hesselink EJ, van Laarhoven CJ, Rosman C, Bosscha K, de Wit RJ, Houdijk AP, Cuesta MA, Wahab PJ, Gooszen HG; Dutch Pancreatitis Study Group. A conservative and minimally invasive approach to necrotizing pancreatitis improves outcome. *Gastroenterology* 2011; **141**: 1254-1263 [PMID: 21741922 DOI: 10.1053/j.gastro.2011.06.073]
- 3 **Besselink MG**, van Santvoort HC, Buskens E, Boermeester MA, van Goor H, Timmerman HM, Nieuwenhuijs VB, Bollen TL, van Ramshorst B, Witteman BJ, Rosman C, Ploeg RJ, Brink MA, Schaapherder AF, Dejong CH, Wahab PJ, van Laarhoven CJ, van der Harst E, van Eijck CH, Cuesta MA, Akkermans LM, Gooszen HG; Dutch Acute Pancreatitis Study Group. Probiotic prophylaxis in predicted severe acute pancreatitis: a randomised, double-blind, placebo-controlled trial. *Lancet* 2008; **371**: 651-659 [PMID: 18279948 DOI: 10.1016/S0140-6736(08)60207-X]
- 4 **Baron TH**, Morgan DE. Acute necrotizing pancreatitis. *N Engl J Med* 1999; **340**: 1412-1417 [PMID: 10228193 DOI: 10.1056/nejm199905063401807]
- 5 **Beger HG**, Rau B, Mayer J, Pralle U. Natural course of acute pancreatitis. *World J Surg* 1997; **21**: 130-135 [PMID: 8995067 DOI: 10.1007/s002689900204]
- 6 **Kokosis G**, Perez A, Pappas TN. Surgical management of necrotizing pancreatitis: an overview. *World J Gastroenterol* 2014; **20**: 16106-16112 [PMID: 25473162 DOI: 10.3748/wjg.v20.i43.16106]
- 7 **El Boukili I**, Boschetti G, Belkhdja H, Kepenekian V, Rousset P, Passot G. Update: Role of surgery in acute necrotizing pancreatitis. *J Visc Surg* 2017; **154**: 413-420 [PMID: 29113713 DOI: 10.1016/j.jvisc-surg.2017.06.008]
- 8 **Banks PA**, Freeman ML; Practice Parameters Committee of the American College of Gastroenterology. Practice guidelines in acute pancreatitis. *Am J Gastroenterol* 2006; **101**: 2379-2400 [PMID: 17032204 DOI: 10.1111/j.1572-0241.2006.00856.x]
- 9 **Balthazar EJ**, Robinson DL, Megibow AJ, Ranson JH. Acute pancreatitis: value of CT in establishing prognosis. *Radiology* 1990; **174**: 331-336 [PMID: 2296641 DOI: 10.1148/radiology.174.2.2296641]
- 10 **Boumitri C**, Brown E, Kahaleh M. Necrotizing Pancreatitis: Current Management and Therapies. *Clin Endosc* 2017; **50**: 357-365 [PMID: 28516758 DOI: 10.5946/ce.2016.152]
- 11 **Zerem E**. Treatment of severe acute pancreatitis and its complications. *World J Gastroenterol* 2014; **20**: 13879-13892 [PMID: 25320523 DOI: 10.3748/wjg.v20.i38.13879]
- 12 **van Brunschot S**, van Grinsven J, van Santvoort HC, Bakker OJ, Besselink MG, Boermeester MA, Bollen

- TL, Bosscha K, Bouwense SA, Bruno MJ, Cappendijk VC, Consten EC, Dejong CH, van Eijck CH, Erkelens WG, van Goor H, van Grevenstein WMU, Haveman JW, Hofker SH, Jansen JM, Laméris JS, van Lienden KP, Meijssens MA, Mulder CJ, Nieuwenhuijs VB, Poley JW, Quispel R, de Ridder RJ, Römkens TE, Scheepers JJ, Schepers NJ, Schwartz MP, Seerden T, Spanier BMW, Straathof JWA, Strijker M, Timmer R, Venneman NG, Vleggaar FP, Voermans RP, Witteman BJ, Gooszen HG, Dijkgraaf MG, Fockens P; Dutch Pancreatitis Study Group. Endoscopic or surgical step-up approach for infected necrotising pancreatitis: a multicentre randomised trial. *Lancet* 2018; **391**: 51-58 [PMID: [29108721](#) DOI: [10.1016/S0140-6736\(17\)32404-2](#)]
- 13 **van Santvoort HC**, Besselink MG, Bakker OJ, Hofker HS, Boermeester MA, Dejong CH, van Goor H, Schaapherder AF, van Eijck CH, Bollen TL, van Ramshorst B, Nieuwenhuijs VB, Timmer R, Laméris JS, Kruij PM, Manusama ER, van der Harst E, van der Schelling GP, Karsten T, Hesselink EJ, van Laarhoven CJ, Rosman C, Bosscha K, de Wit RJ, Houdijk AP, van Leeuwen MS, Buskens E, Gooszen HG; Dutch Pancreatitis Study Group. A step-up approach or open necrosectomy for necrotizing pancreatitis. *N Engl J Med* 2010; **362**: 1491-1502 [PMID: [20410514](#) DOI: [10.1056/NEJMoa0908821](#)]
- 14 **Haghsheenasakshani A**, Laurence JM, Kwan V, Johnston E, Hollands MJ, Richardson AJ, Pleass HC, Lam VW. Endoscopic necrosectomy of pancreatic necrosis: a systematic review. *Surg Endosc* 2011; **25**: 3724-3730 [PMID: [21656324](#) DOI: [10.1007/s00464-011-1795-x](#)]
- 15 **Kumar N**, Conwell DL, Thompson CC. Direct endoscopic necrosectomy versus step-up approach for walled-off pancreatic necrosis: comparison of clinical outcome and health care utilization. *Pancreas* 2014; **43**: 1334-1339 [PMID: [25083997](#) DOI: [10.1097/MPA.0000000000000213](#)]
- 16 **Zhao G**, Wang CY, Wang F, Xiong JX. Clinical study on nutrition support in patients with severe acute pancreatitis. *World J Gastroenterol* 2003; **9**: 2105-2108 [PMID: [12970916](#) DOI: [10.1007/s00535-012-0737-2](#)]
- 17 **Shaw JH**, Wolfe RR. Glucose, fatty acid, and urea kinetics in patients with severe pancreatitis. The response to substrate infusion and total parenteral nutrition. *Ann Surg* 1986; **204**: 665-672 [PMID: [3098198](#)]
- 18 **Gupta R**, Patel K, Calder PC, Yaqoob P, Primrose JN, Johnson CD. A randomised clinical trial to assess the effect of total enteral and total parenteral nutritional support on metabolic, inflammatory and oxidative markers in patients with predicted severe acute pancreatitis (APACHE II > or =6). *Pancreatol* 2003; **3**: 406-413 [PMID: [14526151](#) DOI: [10.1159/000073657](#)]
- 19 **Chandrasegaram MD**, Plank LD, Windsor JA. The impact of parenteral nutrition on the body composition of patients with acute pancreatitis. *JPEN J Parenter Enteral Nutr* 2005; **29**: 65-73 [PMID: [15772382](#) DOI: [10.1177/014860710502900265](#)]
- 20 **Wereszczynska-Siemiatkowska U**, Swidnicka-Siergiejko A, Siemiatkowski A, Dabrowski A. Early enteral nutrition is superior to delayed enteral nutrition for the prevention of infected necrosis and mortality in acute pancreatitis. *Pancreas* 2013; **42**: 640-646 [PMID: [23508012](#) DOI: [10.1097/MPA.0b013e318271bb61](#)]
- 21 **Petrov MS**, van Santvoort HC, Besselink MG, van der Heijden GJ, Windsor JA, Gooszen HG. Enteral nutrition and the risk of mortality and infectious complications in patients with severe acute pancreatitis: a meta-analysis of randomized trials. *Arch Surg* 2008; **143**: 1111-1117 [PMID: [19015471](#) DOI: [10.1001/archsurg.143.11.1111](#)]
- 22 **Petrov MS**, Whelan K. Comparison of complications attributable to enteral and parenteral nutrition in predicted severe acute pancreatitis: a systematic review and meta-analysis. *Br J Nutr* 2010; **103**: 1287-1295 [PMID: [20370944](#) DOI: [10.1017/S0007114510000887](#)]
- 23 **Quan H**, Wang X, Guo C. A meta-analysis of enteral nutrition and total parenteral nutrition in patients with acute pancreatitis. *Gastroenterol Res Pract* 2011; **2011**: 698248 [PMID: [21687619](#) DOI: [10.1155/2011/698248](#)]
- 24 **Petrov MS**, Kukosh MV, Emelyanov NV. A randomized controlled trial of enteral versus parenteral feeding in patients with predicted severe acute pancreatitis shows a significant reduction in mortality and in infected pancreatic complications with total enteral nutrition. *Dig Surg* 2006; **23**: 336-344; discussion 344-345 [PMID: [17164546](#) DOI: [10.1159/000097949](#)]
- 25 **Al-Omran M**, Albalawi ZH, Tashkandi MF, Al-Ansary LA. Enteral versus parenteral nutrition for acute pancreatitis. *Cochrane Database Syst Rev* 2010; CD002837 [PMID: [20091534](#) DOI: [10.1002/14651858.CD002837.pub2](#)]
- 26 **Eatock FC**, Chong P, Menezes N, Murray L, McKay CJ, Carter CR, Imrie CW. A randomized study of early nasogastric versus nasojejunal feeding in severe acute pancreatitis. *Am J Gastroenterol* 2005; **100**: 432-439 [PMID: [15667504](#) DOI: [10.1111/j.1572-0241.2005.40587.x](#)]
- 27 **Wang G**, Wen J, Xu L, Zhou S, Gong M, Wen P, Xiao X. Effect of enteral nutrition and ecoinmunonutrition on bacterial translocation and cytokine production in patients with severe acute pancreatitis. *J Surg Res* 2013; **183**: 592-597 [PMID: [23726433](#) DOI: [10.1016/j.jss.2012.12.010](#)]
- 28 **Mazaki T**, Ishii Y, Takayama T. Meta-analysis of prophylactic antibiotic use in acute necrotizing pancreatitis. *Br J Surg* 2006; **93**: 674-684 [PMID: [16703633](#) DOI: [10.1002/bjs.5389](#)]
- 29 **Piciucchi M**, Merola E, Marignani M, Signoretti M, Valente R, Cocomello L, Baccini F, Panzuto F, Capurso G, Delle Fave G. Nasogastric or nasointestinal feeding in severe acute pancreatitis. *World J Gastroenterol* 2010; **16**: 3692-3696 [PMID: [20677342](#) DOI: [10.3748/wjg.v16.i29.3692](#)]
- 30 **Singh N**, Sharma B, Sharma M, Sachdev V, Bhardwaj P, Mani K, Joshi YK, Saraya A. Evaluation of early enteral feeding through nasogastric and nasojejunal tube in severe acute pancreatitis: a noninferiority randomized controlled trial. *Pancreas* 2012; **41**: 153-159 [PMID: [21775915](#) DOI: [10.1097/MPA.0b013e318221c4a8](#)]
- 31 **Swaroop VS**, Chari ST, Clain JE. Severe acute pancreatitis. *JAMA* 2004; **291**: 2865-2868 [PMID: [15199038](#) DOI: [10.1001/jama.291.23.2865](#)]
- 32 **Runkel NS**, Moody FG, Smith GS, Rodriguez LF, LaRocco MT, Miller TA. The role of the gut in the development of sepsis in acute pancreatitis. *J Surg Res* 1991; **51**: 18-23 [PMID: [2067354](#) DOI: [10.1016/0022-4804\(91\)90064-S](#)]
- 33 **Pederzoli P**, Bassi C, Vesentini S, Campedelli A. A randomized multicenter clinical trial of antibiotic prophylaxis of septic complications in acute necrotizing pancreatitis with imipenem. *Surg Gynecol Obstet* 1993; **176**: 480-483 [PMID: [8480272](#) DOI: [10.1055/s-2007-1018835](#)]
- 34 **Sainio V**, Kempainen E, Puolakkainen P, Taavitsainen M, Kivisaari L, Valtonen V, Haapiainen R, Schröder T, Kivilaakso E. Early antibiotic treatment in acute necrotising pancreatitis. *Lancet* 1995; **346**: 663-667 [PMID: [7658819](#) DOI: [10.1016/S0140-6736\(95\)92280-6](#)]
- 35 **Nordback I**, Sand J, Saaristo R, Paajanen H. Early treatment with antibiotics reduces the need for surgery

in acute necrotizing pancreatitis--a single-center randomized study. *J Gastrointest Surg* 2001; **5**: 113-8; discussion 118-20 [PMID: [11331472](#) DOI: [10.1016/S1091-255X\(01\)80021-4](#)]



Published By Baishideng Publishing Group Inc
7041 Koll Center Parkway, Suite 160, Pleasanton, CA 94566, USA
Telephone: +1-925-2238242
Fax: +1-925-2238243
E-mail: bpgoffice@wjgnet.com
Help Desk: <https://www.f6publishing.com/helpdesk>
<https://www.wjgnet.com>

