

World Journal of *Clinical Cases*

World J Clin Cases 2019 August 6; 7(15): 1908-2133



**REVIEW**

- 1908** Bone alterations in inflammatory bowel diseases
Sgambato D, Gimigliano F, De Musis C, Moretti A, Toro G, Ferrante E, Miranda A, De Mauro D, Romano L, Iolascon G, Romano M

MINIREVIEWS

- 1926** Extrahepatic hepcidin production: The intriguing outcomes of recent years
Daher R, Lefebvre T, Puy H, Karim Z
- 1937** Neoadjuvant endocrine therapy: A potential strategy for ER-positive breast cancer
Yao LT, Wang MZ, Wang MS, Yu XT, Guo JY, Sun T, Li XY, Xu YY

ORIGINAL ARTICLE**Basic Study**

- 1954** Vestigial like family member 3 is a novel prognostic biomarker for gastric cancer
Zhang LH, Wang Z, Li LH, Liu YK, Jin LF, Qi XW, Zhang C, Wang T, Hua D

Retrospective Study

- 1964** HER2 heterogeneity is a poor prognosticator for HER2-positive gastric cancer
Kaito A, Kuwata T, Tokunaga M, Shitara K, Sato R, Akimoto T, Kinoshita T

Case Control Study

- 1978** Changes in corneal endothelial cell density in patients with primary open-angle glaucoma
Yu ZY, Wu L, Qu B

Observational Study

- 1986** Myocardial bridge-related coronary heart disease: Independent influencing factors and their predicting value
Zhao DH, Fan Q, Ning JX, Wang X, Tian JY
- 1996** Clinical significance and role of up-regulation of SERPINA3 expression in endometrial cancer
Zhou ML, Chen FS, Mao H
- 2003** Evaluation of right ventricular volume and systolic function in normal fetuses using intelligent spatiotemporal image correlation
Sun JX, Cai AL, Xie LM

- 2013** Correlation between intracoronary thrombus components and coronary blood flow after percutaneous coronary intervention for acute myocardial infarction at different onset time
Zhang MJ, Liu X, Liu LH, Li N, Zhang N, Wang YQ, Sun XJ, Huang PH, Yin HM, Liu YH, Zheng H

META-ANALYSIS

- 2022** Performance of common imaging techniques *vs* serum biomarkers in assessing fibrosis in patients with chronic hepatitis B: A systematic review and meta-analysis
Xu XY, Wang WS, Zhang QM, Li JL, Sun JB, Qin TT, Liu HB

CASE REPORT

- 2038** Acute bleeding after argon plasma coagulation for weight regain after gastric bypass: A case report
Moura DTHD, Sachdev AH, Lu PW, Ribeiro IB, Thompson CC
- 2044** Left colonic metastasis from primary hepatocellular carcinoma: A case report
Tagliabue F, Burati M, Chiarelli M, Marando A, Simone MD, Cioffi U
- 2049** ALK-positive anaplastic large cell lymphoma presenting multiple lymphomatous polyposis: A case report and literature review
Saito M, Izumiyama K, Ogasawara R, Mori A, Kondo T, Tanaka M, Morioka M, Miyashita K, Tanino M
- 2058** Modified Tong Xie Yao Fang relieves solitary rectal ulcer syndrome: A case report
Zhang LL, Hao WS, Xu M, Li C, Shi YY
- 2065** Hydrogen gas therapy induced shrinkage of metastatic gallbladder cancer: A case report
Chen JB, Pan ZB, Du DM, Qian W, Ma YY, Mu F, Xu KC
- 2075** Giant nonfunctional ectopic adrenocortical carcinoma on the anterior abdominal wall: A case report
Zhou DK, Liu ZH, Gao BQ, Wang WL
- 2081** Oncogenic osteomalacia caused by a phosphaturic mesenchymal tumor of the femur: A case report
Tang D, Wang XM, Zhang YS, Mi XX
- 2087** Gastric duplication cyst mimicking large cystic lymphangioma in an adult: A rare case report and review of the literature
Xu FY, Sun A, Gan Y, Hu HJ
- 2094** Endometriosis of the duplex appendix: A case report and review of the literature
Zhu MY, Fei FM, Chen J, Zhou ZC, Wu B, Shen YY
- 2103** Fever and neck pain after pacemaker lead extraction: A case report
Wang SX, Bai J, Ma R, Lan RF, Zheng J, Xu W

- 2110** c.753_754delAG, a novel *CFTR* mutation found in a Chinese patient with cystic fibrosis: A case report and review of the literature
Wang YQ, Hao CL, Jiang WJ, Lu YH, Sun HQ, Gao CY, Wu M
- 2120** Common iliac artery occlusion with small intestinal transection caused by blunt abdominal trauma: A case report and review of the literature
Zhou YX, Ji Y, Chen J, Yang X, Zhou Q, Lv J
- 2128** Percutaneous coronary intervention for ostial lesions of the left main stem in a patient with congenital single left coronary artery: A case report
Wu Q, Li ZZ, Yue F, Wei F, Zhang CY

ABOUT COVER

Editorial Board Member of *World Journal of Clinical Cases*, Shu-Pin Huang, MD, Associate Professor, Attending Doctor, Director, Department of Urology, Kaohsiung Medical University, Kaohsiung 807, Taiwan

AIMS AND SCOPE

World Journal of Clinical Cases (*World J Clin Cases*, *WJCC*, online ISSN 2307-8960, DOI: 10.12998) is a peer-reviewed open access academic journal that aims to guide clinical practice and improve diagnostic and therapeutic skills of clinicians.

The primary task of *WJCC* is to rapidly publish high-quality Case Report, Clinical Management, Editorial, Field of Vision, Frontier, Medical Ethics, Original Articles, Meta-Analysis, Minireviews, and Review, in the fields of allergy, anesthesiology, cardiac medicine, clinical genetics, clinical neurology, critical care, dentistry, dermatology, emergency medicine, endocrinology, family medicine, gastroenterology and hepatology, etc.

INDEXING/ABSTRACTING

The *WJCC* is now indexed in PubMed, PubMed Central, Science Citation Index Expanded (also known as SciSearch®), and Journal Citation Reports/Science Edition. The 2019 Edition of Journal Citation Reports cites the 2018 impact factor for *WJCC* as 1.153 (5-year impact factor: N/A), ranking *WJCC* as 99 among 160 journals in Medicine, General and Internal (quartile in category Q3).

RESPONSIBLE EDITORS FOR THIS ISSUE

Responsible Electronic Editor: *Yan-Xia Xing*

Proofing Production Department Director: *Yun-Xiaojuan Wu*

NAME OF JOURNAL

World Journal of Clinical Cases

ISSN

ISSN 2307-8960 (online)

LAUNCH DATE

April 16, 2013

FREQUENCY

Semimonthly

EDITORS-IN-CHIEF

Dennis A Bloomfield, Sandro Vento

EDITORIAL BOARD MEMBERS

<https://www.wjnet.com/2307-8960/editorialboard.htm>

EDITORIAL OFFICE

Jin-Lei Wang, Director

PUBLICATION DATE

August 6, 2019

COPYRIGHT

© 2019 Baishideng Publishing Group Inc

INSTRUCTIONS TO AUTHORS

<https://www.wjnet.com/bpg/gerinfo/204>

GUIDELINES FOR ETHICS DOCUMENTS

<https://www.wjnet.com/bpg/GerInfo/287>

GUIDELINES FOR NON-NATIVE SPEAKERS OF ENGLISH

<https://www.wjnet.com/bpg/gerinfo/240>

PUBLICATION MISCONDUCT

<https://www.wjnet.com/bpg/gerinfo/208>

ARTICLE PROCESSING CHARGE

<https://www.wjnet.com/bpg/gerinfo/242>

STEPS FOR SUBMITTING MANUSCRIPTS

<https://www.wjnet.com/bpg/GerInfo/239>

ONLINE SUBMISSION

<https://www.f6publishing.com>

Performance of common imaging techniques vs serum biomarkers in assessing fibrosis in patients with chronic hepatitis B: A systematic review and meta-analysis

Xue-Ying Xu, Wu-Sheng Wang, Qi-Meng Zhang, Jun-Ling Li, Jin-Bin Sun, Tian-Tian Qin, Hong-Bo Liu

ORCID number: Xue-Ying Xu (0000-0001-5379-0550); Wu-Sheng Wang (0000-0002-1678-4749); Qi-Meng Zhang (0000-0003-3722-5214); Jun-Ling Li (0000-0002-3790-3591); Jin-Bin Sun (0000-0003-4101-0638); Tian-Tian Qin (0000-0001-5355-2261); Hong-Bo Liu (0000-0002-7404-4271).

Author contributions: Xu XY, Wang WS, Zhang QM, Li JL, and Liu HB designed the research; Xu XY, Zhang QM, Li JL, Sun JB, and Qin TT performed the research; Sun JB and Qin TT contributed new analytic tools; Xu XY, Wang WS, and Zhang QM analyzed the data; Xu XY, Wang WS, Zhang QM, and Liu HB wrote the paper.

Supported by Social Science Foundation of Liaoning Province, No. L18ATJ001.

Conflict-of-interest statement: The corresponding author attests that all listed authors meet authorship criteria and that no others meeting the criteria have been omitted. All authors declare that they have no conflicts of interest.

PRISMA 2009 Checklist statement: The authors have read the PRISMA 2009 checklist, and the manuscript was prepared and revised according to the PRISMA 2009 checklist.

Open-Access: This article is an open-access article which was selected by an in-house editor and fully peer-reviewed by external reviewers. It is distributed in accordance with the Creative

Xue-Ying Xu, Wu-Sheng Wang, Qi-Meng Zhang, Jun-Ling Li, Jin-Bin Sun, Tian-Tian Qin, Hong-Bo Liu, Department of Epidemiology and Health Statistics, School of Public Health, China Medical University, Shenyang 110122, Liaoning Province, China

Corresponding author: Hong-Bo Liu, PhD, Professor, Research Fellow, Research Scientist, Statistician, Department of Epidemiology and Health Statistics, School of Public Health, China Medical University, No. 77, Puhe Road, Shenyang North New Area, Shenyang 110122, Liaoning Province, China. hbliu@cmu.edu.cn

Abstract

BACKGROUND

Noninvasive biomarkers have been developed to predict hepatitis B virus (HBV) related fibrosis owing to the significant limitations of liver biopsy. Both serum biomarkers and imaging techniques have shown promising results and may improve the evaluation of liver fibrosis. However, most of the previous studies focused on the diagnostic effects of various imaging techniques on fibrosis in all chronic liver diseases.

AIM

To compare the performance of common imaging methods and serum biomarkers for prediction of significant fibrosis caused only by HBV infection.

METHODS

A systematic review was conducted on the records available in PubMed, EMBASE, and the Cochrane Library electronic databases until December 2018. We systematically assessed the effectiveness of two serum biomarkers and three imaging techniques in predicting significant fibrosis solely caused by HBV infection. The serum biomarkers included aspartate aminotransferase-to-platelet ratio index (APRI) and fibrosis index based on the 4 factors (FIB-4). The three imaging techniques included acoustic radiation force impulse (ARFI), FibroScan, and magnetic resonance elastography (MRE). Three parameters, the area under the summary receiver operating characteristic curve (AUSROC), the summary diagnostic odds ratio, and the summary sensitivity and specificity, were used to examine the accuracy of all tests for liver fibrosis.

RESULTS

Out of 2831 articles evaluated for eligibility, 204 satisfied the predetermined inclusion criteria for this current meta-analysis. Eventually, our final data

Commons Attribution Non Commercial (CC BY-NC 4.0) license, which permits others to distribute, remix, adapt, build upon this work non-commercially, and license their derivative works on different terms, provided the original work is properly cited and the use is non-commercial. See: <http://creativecommons.org/licenses/by-nc/4.0/>

Manuscript source: Invited manuscript

Received: March 4, 2019

Peer-review started: March 4, 2019

First decision: May 31, 2019

Revised: June 25, 2019

Accepted: July 3, 2019

Article in press: July 3, 2019

Published online: August 6, 2019

P-Reviewer: Tsuchiya A, El-Bendary M, Tai DI

S-Editor: Dou Y

L-Editor: Wang TQ

E-Editor: Wang J



contained 81 studies. The AUSROCs of serum biomarkers of APRI and FIB-4 were both 0.75. For imaging techniques (ARFI, FibroScan, and MRE), the areas were 0.89, 0.83, and 0.97, respectively. The heterogeneities of ARFI and FibroScan were statistically significant ($I^2 > 50\%$). The publication bias was not observed in any of the serum biomarkers or imaging methods.

CONCLUSION

These five methods have attained an acceptable level of diagnostic accuracy. Imaging techniques, MRE in particular, demonstrate significant advantages in accurately predicting HBV-related significant fibrosis, while serum biomarkers are admissible methods.

Key words: Hepatitis B virus; Diagnostic test; Imaging technology; Liver fibrosis; Meta-analysis

©The Author(s) 2019. Published by Baishideng Publishing Group Inc. All rights reserved.

Core tip: Many researchers compared the diagnostic effects for liver fibrosis by new techniques within the domain of imaging techniques separately or focused on fibrosis in all chronic liver diseases. We perform a meta-analysis to compare the effectiveness of both some common imaging methods and serum biomarkers for prediction of significant fibrosis among hepatitis B virus (HBV)-monoinfected patients. The results reveal that imaging techniques have significant advantages in prediction of HBV-related significant fibrosis.

Citation: Xu XY, Wang WS, Zhang QM, Li JL, Sun JB, Qin TT, Liu HB. Performance of common imaging techniques vs serum biomarkers in assessing fibrosis in patients with chronic hepatitis B: A systematic review and meta-analysis. *World J Clin Cases* 2019; 7(15): 2022-2037

URL: <https://www.wjgnet.com/2307-8960/full/v7/i15/2022.htm>

DOI: <https://dx.doi.org/10.12998/wjcc.v7.i15.2022>

INTRODUCTION

Liver fibrosis is a consequence of the accumulation of extracellular matrix components, caused by persistent liver damage and consequent wound healing reaction^[1,2]. It can develop to cirrhosis, even hepatic failure and hepatocellular carcinoma^[3]. Approximately one-third of cirrhosis cases worldwide are caused by hepatitis B virus (HBV) infection^[2]. It is estimated that about 450 million people are chronically infected with HBV around the world^[1], resulting in 600000 to 1000000 deaths annually^[4]. Therefore, the accurate diagnosis of the degree of liver fibrosis is essential for the management of chronic hepatitis B (CHB) patients and making clinical decision for doctors.

Liver biopsy is the current reference standard for the evaluation and staging of fibrosis, which is an invasive technique. However, it has several disadvantages, such as patients' reluctance, pain, hemoperitoneum^[5], intra- and interobserver variations, and sampling errors^[6]. Therefore, several noninvasive methods, including serum biomarkers combining indices/scores and imaging techniques like magnetic resonance imaging (MRI), have been investigated for their potential in assessment of liver fibrosis.

There has been a dramatic increase in developing various noninvasive tests since 1991^[7]. There are direct serum noninvasive tests such as hepascore and hyaluronic acid, indirect serum markers which consist of the combination of routine biochemical or haematological tests such as fibrosis index based on the 4 factors (FIB-4), aspartate aminotransferase-to-platelet ratio index (APRI), or Forns index and Fibrotest combined direct and indirect tests^[8]. Among all of these tests, APRI and FIB-4, being extensively investigated in numerous studies, demonstrated the greatest potential.

On the other side, with the development of imaging technology, several imaging devices have been developed for the diagnosis and staging of liver fibrosis, which are truly noninvasive methods when compared with serum biomarkers. Historically, radiologists and clinicians have relied on the assessment of morphological changes

associated with liver fibrosis. Other imaging methods depend on changes in physical properties that can be assessed by quantification techniques. These include mechanical properties, texture, $T_1\rho$ lengthening, perfusion, diffusion, and hepatocellular function^[9]. Ultrasound (US)-based elastography techniques are portable, relatively inexpensive, fast to acquire, and do not require postprocessing^[10]. In particular, 1D transient elastography, commercialized as FibroScan (Echosens, Paris, France), has been widely validated in clinical trials, adopted clinically, and used by clinicians at point of service^[9]. Moreover, focal point shear-wave elastography, commercialized as acoustic radiation force impulse (ARFI) (Siemens Medical Solutions, Mountain View, CA), is mapped in 2D using US tracking pulses, and the resulting tissue displacement is measured^[11]. It is integrated in a conventional US machine that can be performed with conventional US probes during an abdominal US scan^[12,13]. In addition, many MRI techniques for imaging of liver fibrosis are being developed. They typically cover a larger liver volume than US elastography techniques, which may reduce sampling variability and technical failure rate.

These methods have exhibited promising results and may improve the management of liver fibrosis. However, most previous studies compared the diagnostic effects of these new imaging techniques alone and focused on fibrosis in all chronic liver diseases, which might underestimate or overestimate the role of the biomarkers. Therefore, we performed a meta-analysis to compare the pooled performance of some common imaging methods and serum biomarkers for prediction of significant fibrosis among HBV-monoinfected patients.

MATERIALS AND METHODS

Search strategy and selection criteria

Online database search was performed on EMBASE, PubMed, and the Cochrane Library (01/2008-12/2018) for the following terms: Diagnosis test, liver stiffness measurement, LSM, transient elastography, FibroScan, MR elastography, MRE, ARFI, acoustic radiation force impulse, point shear-wave elastography, imaging techniques, hepatitis B virus, HBV, chronic hepatitis B, CHB, and fibrosis. Other studies were identified by a manual search for referenced studies or review articles. EndNote X9 software was used to manage the references.

Studies should be included if they conformed all of the following five criteria: (a) The study evaluated the performance of the APRI and/or ARFI and/or FIB-4 and/or FibroScan and/or MRE for the prediction of fibrosis in HBV infected patients. Studies on patients with other etiologies of liver diseases were also included if data for HBV-infected patients could be independently extracted. Special populations of HBV-infected patients [e.g., HBV/HIV, HBV/ hepatitis C virus (HCV), or HBV/ hepatitis D virus (HDV) coinfection] were excluded; (b) Liver biopsy was used to diagnose liver fibrosis as a golden standard; (c) Data could be extracted to construct at least one 2×2 table of test performance, based on some cutoff points of the five biomarkers for the significant fibrosis stage; (d) The study assessed the diagnostic accuracy for fibrosis stage $F \geq 2$ according to METAVIR or a comparable staging system; and (e) The study included at least 50 patients. Studies of smaller sample sizes were excluded due to concerns on their applicability.

Data extraction and quality assessment

Two reviewers (WWS and XYX) evaluated study eligibility, extracted data from the study, and graded the study quality independently. Any disagreements between the reviewers were resolved by detailed discussions together with a third reviewer (LHB). The parameters in our literature search included author, year of publication, region, age, patient gender, body mass index (BMI), histological scoring system, number of patients, average length of liver specimen, time interval between biopsy and other diagnostic tests, diagnostic method, prevalence of the fibrosis stage, as well as cutoff values to identify the fibrosis stage^[14].

XYX and ZQM independently appraised the quality of included studies using the quality assessment of diagnostic accuracy studies questionnaire (QUADAS-2)^[15]. It could estimate the internal and external validity of diagnostic accuracy of studies used in systematic reviews.

Statistical analysis and data synthesis

We extracted and tabulated the data in a series of 2×2 tables that included sensitivity, specificity, positive predictive value (PPV), and negative predictive value (NPV) at each threshold value. The primary target was to identify significant fibrosis, defined by METAVIR^[16], Batts and Ludwig^[17], Scheuer^[18], and Chinese Hospital system^[19], for

stages F2 to F4, and Ishak^[20] for stages F3 to F6. This gauge was chosen because significant fibrosis is often considered a threshold for the initiation of antiviral therapy^[21]. The method of diagnostic test accuracy was examined in order to provide clinically meaningful results. We examined the area under the summary receiver operating characteristic curve (AUSROC) curve, the summary diagnostic odds ratio (DOR), and the summary sensitivity and specificity to further examine the accuracy of all tests for liver fibrosis.

The heterogeneity of the results between studies was assessed statistically using the Cochran-Q and the quantity I^2 . I^2 value can describe the percentage of total variation across studies that is attributable to heterogeneity rather than chance^[22]. If there was significant heterogeneity, a meta-regression was conducted to explore the covariates that may induce heterogeneity, according to the following predefined characteristics: (1) Study design (prospective or retrospective); (2) Length of liver specimen (≥ 10 mm, ≥ 15 mm, ≥ 20 mm, or not); (3) Liver biopsy scoring system; (4) Number of centers (single or multicenter); (5) Sample size; (6) Publication year (2014-2018 or 2008-2013); (7) Time interval between biopsy and tests (same day or not); (8) Prevalence of significant fibrosis; (9) BMI; and (10) Location of study.

The potential publication bias was assessed using the Deeks funnel plots^[23]. All analyses were performed with Meta-Disc software (v. 1.4) and Stata15.0.

RESULT

Search results

The study selection process is shown in Figure 1. A total of 2831 studies were searched by the described search strategies, of which 2627 were excluded following title and abstract screening. Of those, 81 papers were included in the review following full-text screening (Text S5); 47 studies were related to the APRI^[24-70], 11 to the ARFI^[29,42,69-77], 32 to the FIB-4^[24,25,27,30,35,36,39,40,43-46,48-55,57,58,60,62,63,65-69,78-79], 29 to the FibroScan^[28,38,42,52,53,58,60,61,71,73,80-98], and 6 to the MRE^[99-104].

Characteristics of the included studies

In the 47 studies of APRI, there were 13725 patients (median age, 37 years; 68.9% of males). The total prevalence of significant fibrosis was 55.9% (range: 16.7%-83.7%). Most studies were conducted in Asia (42 studies). Three studies were from Europe, one from North America, and another from Africa. We did not restrict study participants to any age, but only one study was conducted on children and adolescents exclusively^[59]. Twenty-nine studies used the METAVIR score, ten used the Scheuer score, six utilized the Ishak score, and two used the Chinese Hospital System. There were 11179 patients (median age, 37 years; 68.7% of males) in 32 studies evaluating the performance of FIB-4. The total prevalence of significant fibrosis was 57.5% (range: 16.7%-83.7%). Twenty-nine studies were conducted in Asia, two in Europe, and one in North America. All studies included adults only. Seventeen studies used the METAVIR score, nine used the Scheuer score, four utilized the Ishak score, and two used the Chinese Hospital System.

A total of 1527 patients (median age, 36 years; 67.5% of males) were contained in 11 studies on ARFI. The total prevalence of F2 was 54.2% (range: 23.9%-74.3%). Ten studies were conducted in Asia and one in Germany. All the subjects were adults. Six studies used the METAVIR score, two used the Chinese Hospital System, and one used each of the Scheuer score, the Ishak score, and the Batts and Ludwig score.

In the 29 FibroScan studies, a total of 5035 patients (median age, 39 years; 71.4% of males) were included. The overall prevalence of significant fibrosis was 49.4% (range: 14.8%-85%). Twenty-one studies were from Asia, six from Europe, one from Africa, and another from North America. Twenty studies used the METAVIR score, five utilized the Batts and Ludwig score, three utilized the Scheuer score, and one used the Chinese Hospital System.

There were 1228 patients (median age, 49 years; 71.0% of males) used to evaluate the performance of MRE in six studies. The total prevalence of significant fibrosis was 61.4% (range: 45.2%-77.4%). One MRE study was from America and the other five were conducted in Asia. The results of methodological quality assessment according to the QUADAS-2 scale are described for all studies (Figure 2, Text S5).

Performance of serum biomarkers for prediction of significant liver fibrosis

In the 47 studies evaluating the APRI, the area under the ROC curve (AUROC) ranged from 0.54 to 0.87. The AUSROC and the pooled sensitivity, specificity, and DOR are presented in Table 1 and Figure 3. The Cochran-Q was 1199.4 and $I^2 > 50\%$, which indicated significant heterogeneity across the included studies ($P < 0.001$). Meta-

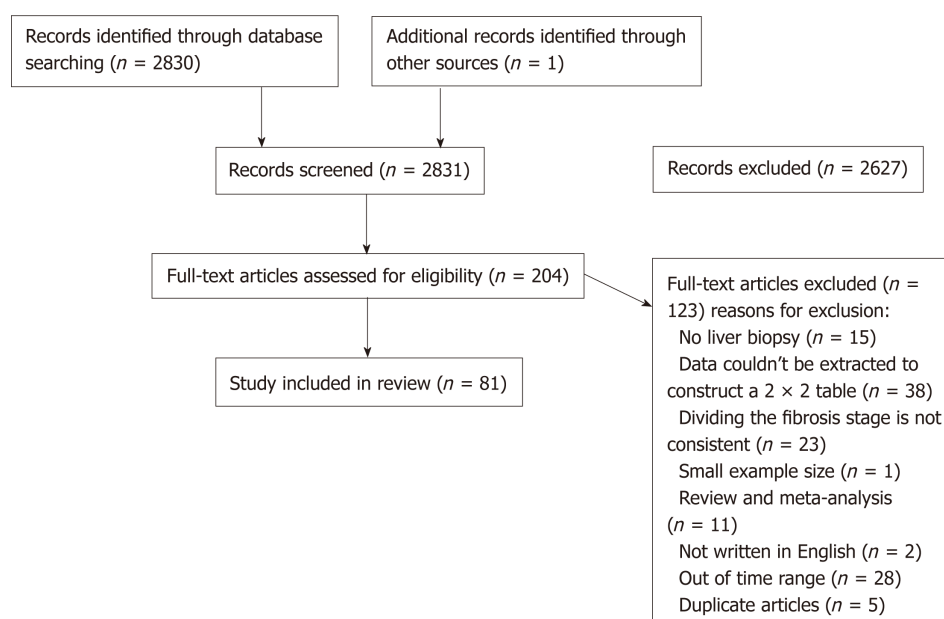


Figure 1 Flow diagram of article selection.

regression analysis was used to explore the heterogeneity of the APRI accuracy for predicting significant fibrosis, which was affected by BMI and prevalence of significant fibrosis with regard to sensitivity and only prevalence of significant fibrosis with regard to specificity (Figure S1). In the 32 studies evaluating the FIB-4 for the prediction of fibrosis stage of F2, the AUROC ranged from 0.56 to 0.85. The AUSROC was 0.75 (0.71-0.78) (Figure 3). The summary sensitivity, specificity, and DOR are shown in Table 1. The score of Cochran-Q was 488.9 ($P < 0.05$) and heterogeneity was statistically significant. The heterogeneity of FIB-4 accuracy was mainly affected by prevalence of significant fibrosis with regard to sensitivity, and prevalence of significant fibrosis and study design with regard to specificity according to the meta-regression analysis (Figure S2). The summary sensitivity and specificity of serum indicators by BMI and prevalence of significant fibrosis are listed in Tables 2 and 3.

Performance of imaging techniques for prediction of liver significant fibrosis

The AUROC ranged from 0.72 to 0.96 in 11 studies evaluating the ARFI. When combined, the AUSROC was 0.89 (0.86-0.91). The summary DOR was 23 (95%CI: 15-38), and the score of Cochran-Q was 27.8 and $I^2 > 50\%$, indicating significant heterogeneity across the included studies ($P < 0.05$). In meta-regression analysis, we found that the causes of the heterogeneity were publishing year and sample size for sensitivity, and prevalence of significant fibrosis and BMI for specificity (Figure S3). In the 29 studies evaluating the FibroScan, the AUROC ranged from 0.61 to 0.94. The AUSROC and the pooled sensitivity, specificity, and DOR are also shown in Table 1 and Figure 3. There was significant heterogeneity across the included studies ($I^2 > 50\%$, $P < 0.001$). The heterogeneity of the FibroScan was mainly affected by prevalence of significant fibrosis and BMI with regard to sensitivity or specificity (Figure S4). In the six studies evaluating the MRE for the prediction of significant fibrosis, the AUROC ranged from 0.98 to 0.99. The AUSROC was 0.97 (0.96-0.98) (Figure 3). The summary sensitivity, specificity, and DOR are listed in Table 1, and the Cochran-Q and I^2 of this measure were 0.44 ($P > 0.05$) and 0, respectively. The result of the heterogeneity was statistically insignificant. The subgroup analysis of imaging methods by BMI and prevalence of significant fibrosis are listed in Tables 2 and 3, respectively.

Publication bias

Funnel plots of these markers are illustrated in Figure S5. Symmetry was noted in the funnel plots and publication bias was not observed in any of the serum biomarkers or the imaging methods.

DISCUSSION

Liver fibrosis progression is common in people infected with HBV. Patients with

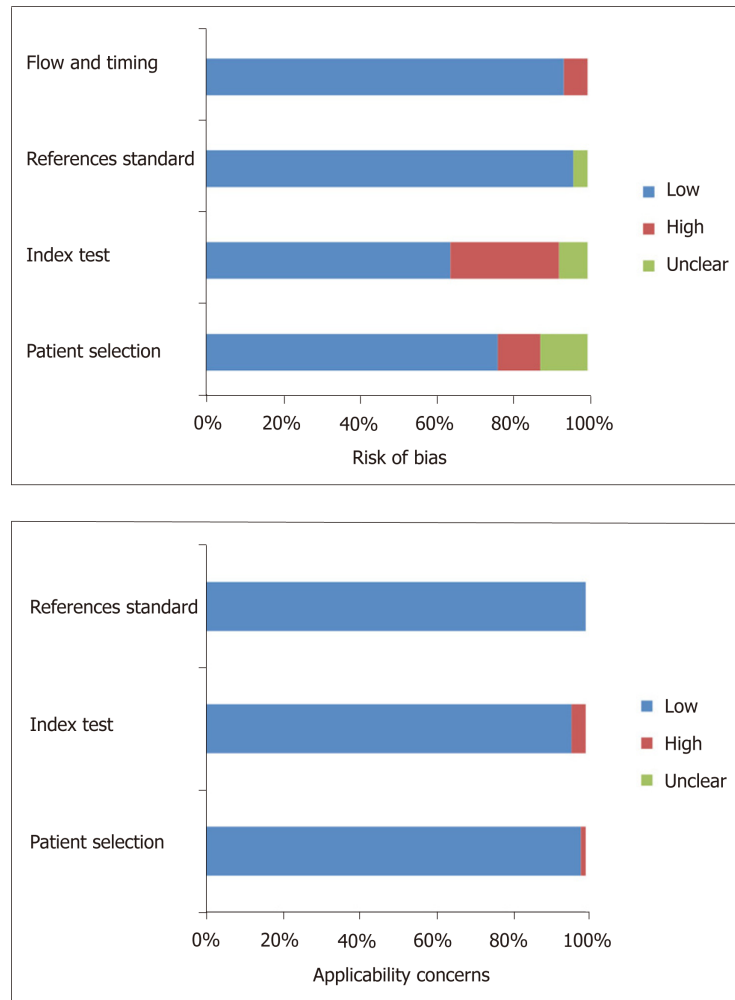


Figure 2 Summary of methodological quality of studies according to QUADAS-2.

significant fibrosis should be considered for clinical therapy, which can potentially reduce and even reverse complications^[105]. Considering the risks and limitations of biopsy, researchers should make persistent efforts in researching some noninvasive methods to more conveniently and securely identify patients with significant fibrosis. FIB-4 and APRI are such noninvasive serum biomarkers that they have been gaining increasing acceptance in clinical practice. FibroScan, ARFI, and MRE gradually reveal an advantage with the development of US-based or MRI elastography techniques. These methods may reduce the demand for liver biopsy and also help to monitor the efficacy of treatments^[62].

Many scholars have researched the diagnostic effect of APRI and FIB-4 and usually compared them with other new methods. In addition, the World Health Organization (WHO) recommends APRI as the preferred noninvasive test to assess significant fibrosis or cirrhosis and FIB-4 to detect fibrosis stages \geq F3, considering lower cost, routinely available methods, and untrained staff^[106]. Therefore, among all serum biomarkers, only APRI and FIB-4 were singled out in our analysis. Based on the results from an increasing number of studies, the difference between APRI and FIB-4 is not significant in relative diagnostic outcomes, although some articles described that FIB-4 had a higher diagnostic accuracy for cirrhosis when compared with APRI^[107]. If only APRI and FIB-4 are available, APRI based on AST, ULN, and platelet count is suggested to diagnose liver significant fibrosis considering resource-limited settings.

With the development of imaging technology, US imaging and MRI devices have been explored to diagnose and stage liver fibrosis, which are truly noninvasive methods. In our meta-analysis, the AUSROCs of imaging techniques are generally bigger than those of APRI and FIB-4. Of these tests, transient elastography performed with FibroScan (Echosens, Paris) has been evaluated widely and has a good performance in predicting cirrhosis, which is corroborated by the Guidelines Development Group. They considered it the most useful test for the assessment of

Table 1 Meta-analysis of hepatitis B-related significant fibrosis

	SEN (95%CI)	SPE (95%CI)	DOR (95%CI)
APRI	0.69 (0.63-0.73)	0.71 (0.66-0.75)	5 (4-6)
FIB-4	0.62 (0.57-0.67)	0.75 (0.71-0.78)	5 (4-5)
ARFI	0.77 (0.70-0.83)	0.87 (0.81-0.92)	23 (15-38)
FibroScan	0.72 (0.68-0.76)	0.82 (0.77-0.86)	12 (9-16)
MRE	0.94 (0.91-0.96)	0.96 (0.93-0.97)	348 (185-656)

SEN: Sensitivity; SPE: Specificity; DOR: Diagnostic odds ratio; CI: Confidence interval; APRI: Aminotransferase-to-platelet ratio index; FIB-4: Fibrosis index based on the 4 factors; ARFI: Acoustic radiation force impulse.

cirrhosis in middle-income countries^[106]. In addition, FibroScan acquires information from a much larger portion of the liver tissue compared to biopsy, and therefore, the risk of sampling error is significantly lowered. However, its performance is mediocre for diagnosing moderate liver fibrosis, and the AUSROC ranked in the middle of the five methods. Morbid obesity (BMI > 30), narrow intercostal spaces, and food intake may diminish the accuracy of FibroScan^[107]. Because of the limitation of US technology, some researchers advocated that the accuracy of ARFI is similar if not superior to FibroScan for the diagnosis of liver fibrosis^[108,109]. Our meta-analysis reveals that ARFI has a higher diagnostic accuracy than FibroScan in identifying HBV-related significant fibrosis. In contrast to FibroScan that has a fixed region of interest box at a fixed insertion depth, ARFI could be performed at variable depths. Furthermore, it can also be performed in obese patients and patients with ascites and integrated in a conventional US system^[13]. MRE, the only MRI index, had the best result in prediction of significant fibrosis. The AUSROC of MRE reaches the standard of “best” and even closes to “1”^[110]. And the summary sensitivity and specificity have reached 94% and 96%, respectively. It typically covers larger liver tissue than US elastography techniques, which may reduce sampling variability. While MRE has been incorporated into MRI devices, it might be more expensive and require more operator training and expertise. Therefore, it is not widely applied at present, and the number of research articles is limited.

Meta-regression method is a convenient and reliable way for heterogeneity screening. In our study, BMI, prevalence of significant fibrosis, sample size, publishing year, and study design provide heterogeneity in summarizing test results. This is consistent with a range of previous studies^[38,111,112]. Some researchers suggested that BMI may reduce the accuracy of ultrasonic technique for detecting significant fibrosis^[9,38]. Our results reveal that BMI may affect predicting outcomes of either serum biomarkers or imaging techniques. Imaging technology shows a better predictive effect in the normal weight group, while serum indicators reflect their superiorities in overweight HBV patients (Table 2). The high proportion of fibrosis stage ≥ 2 will reduce the accuracy of evaluating fibrosis by all methods (Table 3). Furthermore, publishing year and sample size are the main contributors to the heterogeneity of ARFI. The AUSROC of ARFI was 0.89 when we excluded the only one article before 2014, the AUSROC of which was 0.75. Therefore, the technology of ARFI, a new diagnostic method, is progressing gradually, and the evaluation effect is increasingly improved. Besides, the AUSROCs in subgroups of sample size between 100 and 300 were much more than others in most cases (Text S6). Although other methods showed no significant differences in the AUSROC among subgroups of sample size, there was a general pattern that the areas were larger in the middle while smaller on both sides (Text S6). This phenomenon is more prominent if the group was changed into three subgroups ($n < 100$, $100 \leq n \leq 300$, and $n > 300$) (Table 4). A few years ago, our team observed that when the sample size was larger than 150, the diagnostic accuracy of predicting fibrosis was noticeably enhanced^[111]. Therefore, the sample size of 150-300 will be beneficial to the accuracy of diagnostic tests.

However, there are several limitations in our systematic review. First of all, the cut-off value was not considered due to the absence of threshold effect in all tests (Text S7). Second, the ALT levels were not considered because only a limited number of studies calculated the results by the subgroup of ALT. Third, only the studies published in English and Chinese languages were included. Lastly, other methods, though we have retrieved them, were not considered in this meta-analysis, because the number of articles was not adequate.

In conclusion, these five methods have attained an acceptable level of diagnostic accuracy in our meta-analysis. Imaging techniques are generally better than serum

Table 2 Subgroup analysis of body mass index in prediction of significant fibrosis

Diagnostic test	BMI	Number of studies (n)	AUSROC (95%CI)	SEN (95%CI)	SPE (95%CI)
APRI	Overweight	7 (985)	0.78 (0.74-0.81)	0.78 (0.59-0.90)	0.71 (0.61-0.79)
	Normal	13 (2598)	0.75 (0.71-0.79)	0.63 (0.55-0.71)	0.77 (0.68-0.84)
	NA	27 (10142)	0.74 (0.70-0.77)	0.69 (0.62-0.74)	0.68 (0.61-0.74)
FIB-4	Overweight	5 (717)	0.76 (0.72-0.79)	0.58 (0.47-0.70)	0.80 (0.67-0.89)
	Normal	6 (1367)	0.70 (0.66-0.74)	0.58 (0.46-0.69)	0.75 (0.60-0.85)
	NA	21 (9095)	0.75 (0.71-0.79)	0.64 (0.57-0.70)	0.74 (0.69-0.78)
ARFI	Overweight	5 (679)	0.85 (0.82-0.88)	0.76 (0.64-0.85)	0.86 (0.80-0.91)
	Normal ^a	3 (481)	0.91 (0.88-0.95)	0.84 (0.80-0.88)	0.76 (0.64-0.85)
	NA ^a	3 (367)	0.93 (0.85 - 0.99)	0.72 (0.63-0.80)	0.95 (0.91-0.97)
Fibroscan	Overweight	12 (1927)	0.81 (0.77-0.84)	0.68 (0.62-0.74)	0.85 (0.76-0.91)
	Normal	11 (2103)	0.83 (0.79-0.86)	0.73 (0.66-0.79)	0.82 (0.73-0.88)
	NA	6 (1005)	0.85 (0.81-0.88)	0.79 (0.69-0.87)	0.78 (0.72-0.83)

^aThe results were calculated with Meta-Disc software (v. 1.4). BMI: Body mass index; NA: Not assessable; SEN: Sensitivity; SPE: Specificity; CI: Confidence interval; AUSROC: The area under the summary receiver operating characteristic curve; APRI: Aminotransferase-to-platelet ratio index; FIB-4: Fibrosis index based on the 4 factors; ARFI: Acoustic radiation force impulse.

biomarkers in prediction of HBV-related liver significant fibrosis. MRE is a promising indicator and will surprise us with the development of global economy and popularization of technology. If condition allows, ARFI could be a better choice, than FibroScan, for assessment of liver fibrosis in HBV-monoinfected patients with obesity or ascites. The prediction effects of serum markers are generally admissible. Their low cost and easiness in operation make them attractive especially in areas with limited resources and access to imaging technology.

Table 3 Subgroup analysis of prevalence of F2 in prediction of significant fibrosis

Diagnostic test	F2%	Number of studies (n)	AUSROC (95%CI)	SEN (95%CI)	SPE (95%CI)
APRI	F2% < 50	16 (4566)	0.72 (0.68-0.76)	0.68 (0.59-0.76)	0.66 (0.57-0.75)
	F2% ≥ 50	31 (9159)	0.77 (0.73-0.81)	0.69 (0.62-0.75)	0.73 (0.68-0.78)
FIB-4	F2% < 50	9 (3234)	0.75 (0.71-0.79)	0.60 (0.47-0.72)	0.76 (0.68-0.83)
	F2% ≥ 50	23 (7945)	0.75 (0.71-0.78)	0.63 (0.57-0.68)	0.74 (0.69-0.78)
ARFI	F2% < 50	4 (554)	0.89 (0.85-0.91)	0.73 (0.62-0.82)	0.93 (0.68-0.97)
	F2% ≥ 50	7 (973)	0.88 (0.85-0.91)	0.80 (0.72-0.87)	0.82 (0.74-0.88)
Fibroscan	F2% < 50	12 (2272)	0.85 (0.81-0.88)	0.77 (0.70-0.83)	0.80 (0.71-0.86)
	F2% ≥ 50	17 (2763)	0.82 (0.78-0.85)	0.69 (0.64-0.74)	0.84 (0.78-0.88)

SEN: Sensitivity; SPE: Specificity; CI: Confidence interval; AUSROC: The area under the summary receiver operating characteristic curve; APRI: Aminotransferase-to-platelet ratio index; FIB-4: Fibrosis index based on the 4 factors; ARFI: Acoustic radiation force impulse.

Table 4 Subgroup analysis of sample size in prediction of significant fibrosis

Diagnostic test	Sample size	Number of studies (N)	AUSROC (95%CI)	SEN (95%CI)	SPE (95%CI)
APRI	$n < 100$	8 (588)	0.73 (0.69-0.77)	0.67 (0.60-0.74)	0.68 (0.61-0.75)
	$100 \leq n < 300$	27 (5286)	0.77 (0.73-0.80)	0.69 (0.62-0.76)	0.72 (0.65-0.78)
	$n \geq 300$	12 (7851)	0.73 (0.69-0.77)	0.67 (0.57-0.76)	0.69 (0.58-0.78)
FIB-4	$n < 100$	6 (411)	0.77 (0.73-0.80)	0.64 (0.54-0.73)	0.77 (0.67-0.85)
	$100 \leq n < 300$	14 (2917)	0.76 (0.72-0.80)	0.62 (0.53-0.71)	0.77 (0.69-0.83)
	$n \geq 300$	12 (7851)	0.74 (0.70-0.77)	0.62 (0.53-0.69)	0.74 (0.67-0.79)
ARFI	$n < 100$	2 (173)	0.72/0.75	0.83/0.50	0.65/0.90
	$100 \leq n < 300$	9 (1354)	0.90 (0.87-0.92)	0.78 (0.71-0.84)	0.88 (0.82-0.93)
	$n \geq 300$	0	-	-	-
Fibroscan	$n < 100$	6 (445)	0.80 (0.76-0.83)	0.70 (0.57-0.80)	0.76 (0.68-0.83)
	$100 \leq n < 300$	20 (3659)	0.84 (0.81-0.87)	0.74 (0.69-0.79)	0.83 (0.77-0.87)
	$n \geq 300^a$	3 (931)	0.82 (0.69-0.95)	0.62 (0.57-0.66)	0.88 (0.84-0.90)

^a The results were calculated with Meta-Disc software (v. 1.4). SEN: Sensitivity; SPE: Specificity; CI: Confidence interval; AUSROC: The area under the summary receiver operating characteristic curve; APRI: Aminotransferase-to-platelet ratio index; FIB-4: Fibrosis index based on the 4 factors; ARFI: Acoustic radiation force impulse.

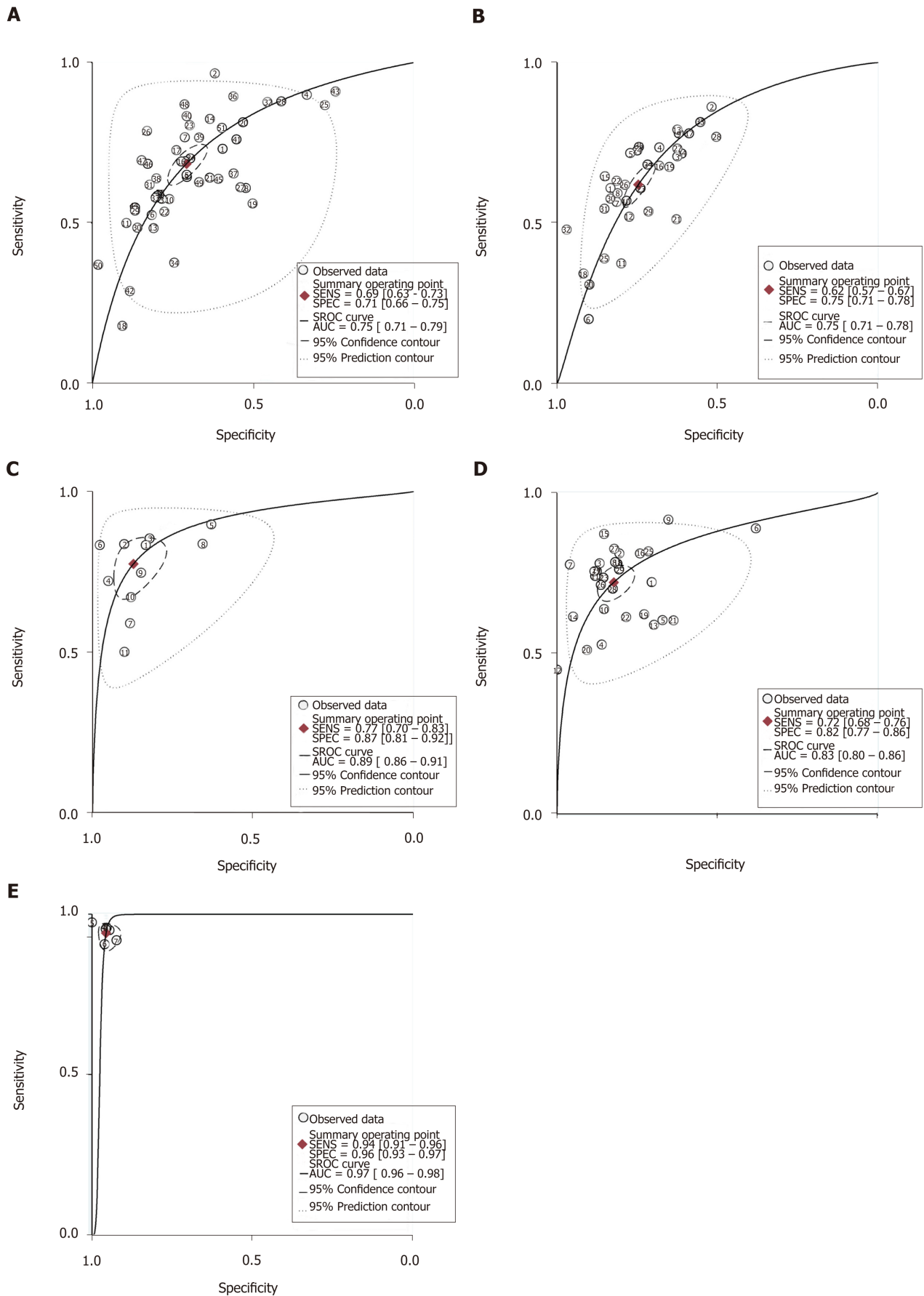


Figure 3 Meta-analysis of hepatitis B-related significant fibrosis. A: Summary receiver operating characteristic (SROC) curve of the aminotransferase-to-platelet ratio index; B: SROC curve of the fibrosis index based on the 4 factors; C: SROC curve of the acoustic radiation force impulse; D: SROC curve of the FibroScan; E: SROC curve of the MRE. SROC: Summary receiver operating characteristic; APRI: Aminotransferase-to-platelet ratio index; FIB-4: Fibrosis index based on the 4 factors; ARFI: Acoustic radiation force impulse.

ARTICLE HIGHLIGHTS

Research background

Liver fibrosis can develop to cirrhosis and even hepatic failure and hepatocellular carcinoma. Approximately one-third of cirrhosis cases worldwide are caused by HBV infection. Therefore, the accurate diagnosis of the extent of liver fibrosis for chronic hepatitis B patients is essential. Many serum biomarkers combining indices/scores and imaging or magnetic resonance imaging techniques have been undergoing dramatic development because of several drawbacks of liver biopsy. These methods have promising results and may improve the management of liver fibrosis. However, most of the previous studies compared the diagnostic effects of these new techniques within the domain of imaging techniques or focused on fibrosis in all chronic liver diseases, which might misestimate the role of these biomarkers. Therefore, we performed a meta-analysis to compare the pooled performance of some common imaging methods with serum biomarkers for prediction of significant fibrosis among HBV-monoinfected patients.

Research motivation

We aimed to assess the accuracy of diagnostic tests for predicting significant fibrosis among patients monoinfected with HBV. Most studies are centered on the domain of imaging techniques and serum biomarkers separately or focused on fibrosis in all chronic liver diseases. Therefore, the key points are that data for HBV infected patients could be extracted independently and we want to integrate and compare the performance of methods of different fields. With the development of medicine and technology, more innovative methods could be invented in the near future. It will provide a boost to precision medicine that chooses a more appropriate and effective method to evaluate liver fibrosis for different populations of patients.

Research objectives

We aimed to compare the pooled performance of some common imaging methods with serum biomarkers for prediction of significant fibrosis among HBV-monoinfected patients. Some serum biomarkers have been calculated and imaging techniques have been developed for the diagnosis of liver fibrosis, respectively. Integrating and comparing the performance of methods of different fields could provide a basis for future research and clinical application and a boost to precision medicine.

Research methods

We examined the areas under the summary receiver operating characteristic curves, the summary diagnostic odds ratios, as well as the summary sensitivities and specificities to further examine the accuracy of all tests for liver fibrosis. Then, we assessed the heterogeneity between studies using the Cochran-Q and I^2 . And the Deeks funnel plots were used to assess publication bias. Meta-regression was conducted to further accurately explore the covariates that may induce heterogeneity.

Research results

Our meta-analysis revealed that ARFI showed a higher diagnostic accuracy than FibroScan in identifying HBV-related significant fibrosis. Furthermore, it can also be performed in obese patients and in patients with ascites and be integrated in a conventional ultrasound system. MRE, the only MRI index, had the best result in prediction of significant fibrosis. The area under the SROC curve of MRE reaches the standard of "best" and even closes to "1". The performances of APRI and FIB-4 are poorer than imaging techniques. However, the cut-off value should be considered in future studies.

Research perspectives

Imaging techniques are better than serum biomarkers in prediction of HBV-related liver significant fibrosis in general. MRE is a promising indicator and other serum biomarkers are general.

ACKNOWLEDGEMENTS

We thank Prof. Li-Jin Xu for comments that greatly improved the manuscript. And we also thank all participants for their contribution of time to this study.

REFERENCES

- 1 **Friedman SL.** Evolving challenges in hepatic fibrosis. *Nat Rev Gastroenterol Hepatol* 2010; **7**: 425-436 [PMID: 20585339 DOI: 10.1038/nrgastro.2010.97]
- 2 **Kawada N.** Evolution of hepatic fibrosis research. *Hepatol Res* 2011; **41**: 199-208 [PMID: 21338451 DOI: 10.1111/j.1872-034X.2011.00776.x]
- 3 **Bosch FX,** Ribes J, Cléries R, Diaz M. Epidemiology of hepatocellular carcinoma. *Clin Liver Dis* 2005; **9**: 191-211, v [PMID: 15831268 DOI: 10.1016/j.cld.2004.12.009]
- 4 **Custer B,** Sullivan SD, Hazlet TK, Iloeje U, Veenstra DL, Kowdley KV. Global epidemiology of hepatitis B virus. *J Clin Gastroenterol* 2004; **38**: S158-S168 [PMID: 15602165 DOI: 10.1097/00004836-200411003-00008]
- 5 **Bravo AA,** Sheth SG, Chopra S. Liver biopsy. *N Engl J Med* 2001; **344**: 495-500 [PMID: 11172192 DOI: 10.1056/NEJM200108063440801]

- 10.1056/NEJM200102153440706]
- 6 **Colloredo G**, Guido M, Sonzogni A, Leandro G. Impact of liver biopsy size on histological evaluation of chronic viral hepatitis: the smaller the sample, the milder the disease. *J Hepatol* 2003; **39**: 239-244 [PMID: 12873821 DOI: 10.1016/S0168-8278(03)00191-0]
- 7 **Poynard T**, Aubert A, Bedossa P, Abella A, Naveau S, Paraf F, Chaput JC. A simple biological index for detection of alcoholic liver disease in drinkers. *Gastroenterology* 1991; **100**: 1397-1402 [PMID: 1672859 DOI: 10.1016/0016-5085(91)90795-M]
- 8 **Crossan C**, Tsochatzis EA, Longworth L, Gurusamy K, Davidson B, Rodríguez-Perálvarez M, Mantzoukis K, O'Brien J, Thalassinou E, Papastergiou V, Burroughs A. Cost-effectiveness of non-invasive methods for assessment and monitoring of liver fibrosis and cirrhosis in patients with chronic liver disease: systematic review and economic evaluation. *Health Technol Assess* 2015; **19**: 1-409, v-vi [PMID: 25633908 DOI: 10.3310/hta19090]
- 9 **Pettilerc L**, Sebastiani G, Gilbert G, Cloutier G, Tang A. Liver fibrosis: Review of current imaging and MRI quantification techniques. *J Magn Reson Imaging* 2017; **45**: 1276-1295 [PMID: 27981751 DOI: 10.1002/jmri.25550]
- 10 **Zhang E**, Wartelle-Bladou C, Lepanto L, Lachaine J, Cloutier G, Tang A. Cost-utility analysis of nonalcoholic steatohepatitis screening. *Eur Radiol* 2015; **25**: 3282-3294 [PMID: 25994191 DOI: 10.1007/s00330-015-3731-2]
- 11 **Nightingale K**, Soo MS, Nightingale R, Trahey G. Acoustic radiation force impulse imaging: in vivo demonstration of clinical feasibility. *Ultrasound Med Biol* 2002; **28**: 227-235 [PMID: 11937286 DOI: 10.1016/S0301-5629(01)00499-9]
- 12 **Wang L**, Wang M, Zhao W, Shi Y, Sun Y, Wu X, You H, Jia J. [Key points of 2015 EASL-ALEH clinical practice guidelines: non invasive tests for evaluation of liver severity and prognosis]. *Zhonghua Gan Zang Bing Za Zhi* 2015; **23**: 488-492 [PMID: 26629574]
- 13 **Frulio N**, Trillaud H, Perez P, Asselineau J, Vandenhende M, Hessamfar M, Bonnet F, Maire F, Delaune J, De Ledinghen V, Morlat P. Acoustic Radiation Force Impulse (ARFI) and Transient Elastography (TE) for evaluation of liver fibrosis in HIV-HCV co-infected patients. *BMC Infect Dis* 2014; **14**: 405 [PMID: 25041708 DOI: 10.1186/1471-2334-14-405]
- 14 **Adebajo CO**, Talwalkar JA, Poterucha JJ, Kim WR, Charlton MR. Ultrasound-based transient elastography for the detection of hepatic fibrosis in patients with recurrent hepatitis C virus after liver transplantation: a systematic review and meta-analysis. *Liver Transpl* 2012; **18**: 323-331 [PMID: 22140010 DOI: 10.1002/lt.22460]
- 15 **Whiting PF**, Rutjes AW, Westwood ME, Mallett S, Deeks JJ, Reitsma JB, Leeflang MM, Sterne JA, Bossuyt PM; QUADAS-2 Group. QUADAS-2: a revised tool for the quality assessment of diagnostic accuracy studies. *Ann Intern Med* 2011; **155**: 529-536 [PMID: 22007046 DOI: 10.7326/0003-4819-155-8-201110180-00009]
- 16 **Intraobserver and interobserver variations in liver biopsy interpretation in patients with chronic hepatitis C**. The French METAVIR Cooperative Study Group. *Hepatology* 1994; **20**: 15-20 [PMID: 8020885 DOI: 10.1002/hep.1840200104]
- 17 **Batts KP**, Ludwig J. Chronic hepatitis. An update on terminology and reporting. *Am J Surg Pathol* 1995; **19**: 1409-1417 [PMID: 7503362 DOI: 10.1097/00000478-199512000-00007]
- 18 **Scheuer PJ**. Classification of chronic viral hepatitis: a need for reassessment. *J Hepatol* 1991; **13**: 372-374 [PMID: 1808228 DOI: 10.1016/0168-8278(91)90084-O]
- 19 **Diseases CSoHaCSol**. Chinese medical association: Chinese program of prevention and cure for viral hepatitis. *Chin J Intern Med* 2001; **40**: 62-68
- 20 **Ishak K**, Baptista A, Bianchi L, Callea F, De Groote J, Gudat F, Denk H, Desmet V, Korb G, MacSween RN. Histological grading and staging of chronic hepatitis. *J Hepatol* 1995; **22**: 696-699 [PMID: 7560864 DOI: 10.1016/0168-8278(95)80226-6]
- 21 **Strader DB**, Wright T, Thomas DL, Seeff LB; American Association for the Study of Liver Diseases. Diagnosis, management, and treatment of hepatitis C. *Hepatology* 2004; **39**: 1147-1171 [PMID: 15057920 DOI: 10.1002/hep.20119]
- 22 **Higgins JP**, Thompson SG, Deeks JJ, Altman DG. Measuring inconsistency in meta-analyses. *BMJ* 2003; **327**: 557-560 [PMID: 12958120 DOI: 10.1136/bmj.327.7414.557]
- 23 **Deeks JJ**, Macaskill P, Irwig L. The performance of tests of publication bias and other sample size effects in systematic reviews of diagnostic test accuracy was assessed. *J Clin Epidemiol* 2005; **58**: 882-893 [PMID: 16085191 DOI: 10.1016/j.jclinepi.2005.01.016]
- 24 **Wang K**, Lu X, Zhou H, Gao Y, Zheng J, Tong M, Wu C, Liu C, Huang L, Jiang T, Meng F, Lu Y, Ai H, Xie XY, Yin LP, Liang P, Tian J, Zheng R. Deep learning Radiomics of shear wave elastography significantly improved diagnostic performance for assessing liver fibrosis in chronic hepatitis B: a prospective multicentre study. *Gut* 2019; **68**: 729-741 [PMID: 29730602 DOI: 10.1136/gutjnl-2018-316204]
- 25 **Chen YP**, Hu XM, Liang XE, Huang LW, Zhu YF, Hou JL. Stepwise application of fibrosis index based on four factors, red cell distribution width-platelet ratio, and aspartate aminotransferase-platelet ratio for compensated hepatitis B fibrosis detection. *J Gastroenterol Hepatol* 2018; **33**: 256-263 [PMID: 28452125 DOI: 10.1111/jgh.13811]
- 26 **Celikbilek M**, Dogan S, Gursoy S, Zararsiz G, Yurci A, Ozbakir O, Guven K, Yucsey M. Noninvasive assessment of liver damage in chronic hepatitis B. *World J Hepatol* 2013; **5**: 439-445 [PMID: 24023983 DOI: 10.4254/wjh.v5.i8.439]
- 27 **Gümüsay O**, Ozenirler S, Atak A, Sönmez C, Ozkan S, Tuncel AF, Yılmaz G, Akyol G. Diagnostic potential of serum direct markers and non-invasive fibrosis models in patients with chronic hepatitis B. *Hepatol Res* 2013; **43**: 228-237 [PMID: 22734888 DOI: 10.1111/j.1872-034X.2012.01057.x]
- 28 **Li Q**, Chen L, Zhou Y. Diagnostic accuracy of liver stiffness measurement in chronic hepatitis B patients with normal or mildly elevated alanine transaminase levels. *Sci Rep* 2018; **8**: 5224 [PMID: 29588489 DOI: 10.1038/s41598-018-23646-2]
- 29 **Chen X**, Wen H, Zhang X, Dong C, Lin H, Guo Y, Shan L, Yao S, Yang M, Le X, Liu Y. Development of a Simple Noninvasive Model to Predict Significant Fibrosis in Patients with Chronic Hepatitis B: Combination of Ultrasound Elastography, Serum Biomarkers, and Individual Characteristics. *Clin Transl Gastroenterol* 2017; **8**: e84 [PMID: 28383564 DOI: 10.1038/ctg.2017.11]
- 30 **Zhang Z**, Wang G, Kang K, Wu G, Wang P. The Diagnostic Accuracy and Clinical Utility of Three Noninvasive Models for Predicting Liver Fibrosis in Patients with HBV Infection. *PLoS One* 2016; **11**: e0152757 [PMID: 27050531 DOI: 10.1371/journal.pone.0152757]

- 31 **Liang B**, Li Y, Zhao A, Xie F, Guo Z. Clinical utility of serum matrix metalloproteinase-2 and tissue inhibitor of metalloproteinase-2 concentrations in the assessment of liver fibrosis due to chronic hepatitis B. *J Int Med Res* 2012; **40**: 631-639 [PMID: 22613424 DOI: 10.1177/147323001204000225]
- 32 **Zhou K**, Gao CF, Zhao YP, Liu HL, Zheng RD, Xian JC, Xu HT, Mao YM, Zeng MD, Lu LG. Simpler score of routine laboratory tests predicts liver fibrosis in patients with chronic hepatitis B. *J Gastroenterol Hepatol* 2010; **25**: 1569-1577 [PMID: 20796157 DOI: 10.1111/j.1440-1746.2010.06383.x]
- 33 **Güzelbulut F**, Sezıklı M, Akkan-Çetinkaya Z, Yaşar B, Özkara S, Kurdaş-Övünç AO. AST-platelet ratio index in the prediction of significant fibrosis and cirrhosis in patients with chronic hepatitis B. *Turk J Gastroenterol* 2012; **23**: 353-358 [PMID: 22965506 DOI: 10.4318/tjg.2012.0348]
- 34 **Eminler AT**, Ayyıldız T, Irak K, Kiyici M, Gurel S, Dolar E, Gulen M, Nak SG. AST/ALT ratio is not useful in predicting the degree of fibrosis in chronic viral hepatitis patients. *Eur J Gastroenterol Hepatol* 2015; **27**: 1361-1366 [PMID: 26352130 DOI: 10.1097/MEG.0000000000000468]
- 35 **Liu J**, Zhao J, Zhang Y, Ji Y, Lin S, Dun G, Guo S. Noninvasive Assessment of Liver Fibrosis Stage Using Ultrasound-Based Shear Wave Velocity Measurements and Serum Algorithms in Patients With Viral Hepatitis B: A Retrospective Cohort Study. *J Ultrasound Med* 2017; **36**: 285-293 [PMID: 28039877 DOI: 10.7863/ultra.16.01069]
- 36 **Yang L**, Ding Y, Rao S, Chen C, Wu L, Sheng R, Fu C, Zeng M. Staging liver fibrosis in chronic hepatitis B with T1 relaxation time index on gadoxetic acid-enhanced MRI: Comparison with aspartate aminotransferase-to-platelet ratio index and FIB-4. *J Magn Reson Imaging* 2017; **45**: 1186-1194 [PMID: 27563840 DOI: 10.1002/jmri.25440]
- 37 **Li Q**, Li W, Huang Y, Chen L. The gamma-glutamyl transpeptidase-to-platelet ratio predicts liver fibrosis and cirrhosis in HBeAg-positive chronic HBV infection patients with high HBV DNA and normal or mildly elevated alanine transaminase levels in China. *J Viral Hepat* 2016; **23**: 912-919 [PMID: 27375134 DOI: 10.1111/jvh.12563]
- 38 **Lemoine M**, Shimakawa Y, Nayagam S, Khalil M, Suso P, Lloyd J, Goldin R, Njai HF, Ndow G, Taal M, Cooke G, D'Alessandro U, Vray M, Mbaye PS, Njie R, Mallet V, Thursz M. The gamma-glutamyl transpeptidase to platelet ratio (GPR) predicts significant liver fibrosis and cirrhosis in patients with chronic HBV infection in West Africa. *Gut* 2016; **65**: 1369-1376 [PMID: 26109530 DOI: 10.1136/gutjnl-2015-309260]
- 39 **Zhou QQ**, Hu YB, Zhou K, Zhang WW, Li MH, Dong P, Ding JG, Hong L, Du QW, Xie Y, Sun QF. Value of non-invasive models of liver fibrosis in judgment of treatment timing in chronic hepatitis b patients with ALT < 2x upperlimit ofnormal. *Zhonghua Gan Zang Bing Za Zhi* 2016; **24**: 665-670
- 40 **Li Q**, Song J, Huang Y, Li X, Zhuo Q, Li W, Chen C, Lu C, Qi X, Chen L. The Gamma-Glutamyl-Transpeptidase to Platelet Ratio Does not Show Advantages than APRI and Fib-4 in Diagnosing Significant Fibrosis and Cirrhosis in Patients With Chronic Hepatitis B: A Retrospective Cohort Study in China. *Medicine (Baltimore)* 2016; **95**: e3372 [PMID: 27100421 DOI: 10.1097/MD.0000000000000372]
- 41 **Shin WG**, Park SH, Jang MK, Hahn TH, Kim JB, Lee MS, Kim DJ, Jun SY, Park CK. Aspartate aminotransferase to platelet ratio index (APRI) can predict liver fibrosis in chronic hepatitis B. *Dig Liver Dis* 2008; **40**: 267-274 [PMID: 18055281 DOI: 10.1016/j.dld.2007.10.011]
- 42 **Liu Y**, Dong CF, Yang G, Liu J, Yao S, Li HY, Yuan J, Li S, Le X, Lin Y, Zeng W, Lin H, Zhang X, Chen X. Optimal linear combination of ARFI, transient elastography and APRI for the assessment of fibrosis in chronic hepatitis B. *Liver Int* 2015; **35**: 816-825 [PMID: 24751289 DOI: 10.1111/liv.12564]
- 43 **Salkic NN**, Cickusic E, Jovanovic P, Denjagic MB, Iljazovic-Topcic S, Bevanda M, Ahmetagic S. Online combination algorithm for non-invasive assessment of chronic hepatitis B related liver fibrosis and cirrhosis in resource-limited settings. *Eur J Intern Med* 2015; **26**: 628-634 [PMID: 26194460 DOI: 10.1016/j.ejim.2015.07.005]
- 44 **Erdogan S**, Dogan HO, Sezer S, Uysal S, Ozhamam E, Kayacetin S, Koca Y. The diagnostic value of non-invasive tests for the evaluation of liver fibrosis in chronic hepatitis B patients. *Scand J Clin Lab Invest* 2013; **73**: 300-308 [PMID: 23514016 DOI: 10.3109/00365513.2013.773592]
- 45 **Kim WR**, Berg T, Asselah T, Flisiak R, Fung S, Gordon SC, Janssen HL, Lampertico P, Lau D, Bornstein JD, Schall RE, Dinh P, Yee LJ, Martins EB, Lim SG, Loomba R, Petersen J, Buti M, Marcellin P. Evaluation of APRI and FIB-4 scoring systems for non-invasive assessment of hepatic fibrosis in chronic hepatitis B patients. *J Hepatol* 2016; **64**: 773-780 [PMID: 26626497 DOI: 10.1016/j.jhep.2015.11.012]
- 46 **Başar O**, Yılmaz B, Ekiz F, Giniş Z, Altınbaş A, Aktaş B, Tuna Y, Çoban S, Delibaş N, Yüksel O. Non-invasive tests in prediction of liver fibrosis in chronic hepatitis B and comparison with post-antiviral treatment results. *Clin Res Hepatol Gastroenterol* 2013; **37**: 152-158 [PMID: 23391746 DOI: 10.1016/j.clinre.2012.07.003]
- 47 **Dong C**, Feng LY, Li HY, Lu PX, Yao SM, Shan LB, Zhang XY, Chen X. Virtual touch tissue quantification and aspartate aminotransferase to platelet ratio for staging hepatic fibrosis in patients with chronic hepatitis B. *Zhongguo Yixue Yingxiang Jishu* 2016; **32**: 398-402
- 48 **Li Q**, Lu C, Li W, Huang Y, Chen L. Impact of age on the diagnostic performances and cut-offs of APRI and FIB-4 for significant fibrosis and cirrhosis in chronic hepatitis B. *Oncotarget* 2017; **8**: 45768-45776 [PMID: 28514753 DOI: 10.18632/oncotarget.17470]
- 49 **Wang J**, Yan X, Yang Y, Chang H, Jia B, Zhao XA, Chen G, Xia J, Liu Y, Chen Y, Wang G, Wang L, Zhang Z, Ding W, Huang R, Wu C. A novel predictive model using routinely clinical parameters to predict liver fibrosis in patients with chronic hepatitis B. *Oncotarget* 2017; **8**: 59257-59267 [PMID: 28938634 DOI: 10.18632/oncotarget.19501]
- 50 **Lin CL**, Liu CH, Wang CC, Liang CC, Su TH, Liu CJ, Kao JH. Serum Biomarkers Predictive of Significant Fibrosis and Cirrhosis in Chronic Hepatitis B. *J Clin Gastroenterol* 2015; **49**: 705-713 [PMID: 25319739 DOI: 10.1097/MCG.0000000000000250]
- 51 **Ma XH**, Zang X, You Y, Jiang LL, Zhao J, Ayiguli A, Nie ZG. Diagnostic value of apri combined with fib-4 for significant liver fibrosis in patients with chronic hepatitis b. *Chin J Gastroenterol* 2017; **22**: 544-547 [DOI: 10.3969/j.issn.1008-7125.2017.09.007]
- 52 **Cao Z**, Li Z, Wang H, Liu Y, Xu Y, Mo R, Ren P, Chen L, Lu J, Li H, Zhuang Y, Liu Y, Wang X, Zhao G, Tang W, Xiang X, Cai W, Liu L, Bao S, Xie Q. Algorithm of Golgi protein 73 and liver stiffness accurately diagnoses significant fibrosis in chronic HBV infection. *Liver Int* 2017; **37**: 1612-1621 [PMID: 28772348 DOI: 10.1111/liv.13536]
- 53 **Li Y**, Cai Q, Zhang Y, Xie Q, Xu N, Jiang X, Li J, Li X, Zhang Z. Development of algorithms based on serum markers and transient elastography for detecting significant fibrosis and cirrhosis in chronic hepatitis B patients: Significant reduction in liver biopsy. *Hepatol Res* 2016; **46**: 1367-1379 [PMID: 26970087 DOI: 10.1111/hepr.12696]

- 54 **Liu DP**, Lu W, Zhang ZQ, Wang YB, Ding RR, Zhou XL, Huang D, Li XF. Comparative evaluation of GPR versus APRI and FIB-4 in predicting different levels of liver fibrosis of chronic hepatitis B. *J Viral Hepat* 2018; **25**: 581-589 [PMID: [29230907](#) DOI: [10.1111/jvh.12842](#)]
- 55 **Noguchi R**, Kaji K, Namisaki T, Moriya K, Kitade M, Takeda K, Kawaratani H, Okura Y, Aihara Y, Furukawa M, Mito A, Yoshiji H. Serum angiotensin-converting enzyme level for evaluating significant fibrosis in chronic hepatitis B. *World J Gastroenterol* 2017; **23**: 6705-6714 [PMID: [29085215](#) DOI: [10.3748/wjg.v23.i36.6705](#)]
- 56 **Ren T**, Wang H, Wu R, Niu J. Gamma-Glutamyl Transpeptidase-to-Platelet Ratio Predicts Significant Liver Fibrosis of Chronic Hepatitis B Patients in China. *Gastroenterol Res Pract* 2017; **2017**: 7089702 [PMID: [28831282](#) DOI: [10.1155/2017/7089702](#)]
- 57 **Wu X**, Cai B, Su Z, Li Y, Xu J, Deng R, Wang L. Aspartate transaminase to platelet ratio index and gamma-glutamyl transpeptidase-to-platelet ratio outweigh fibrosis index based on four factors and red cell distribution width-platelet ratio in diagnosing liver fibrosis and inflammation in chronic hepatitis B. *J Clin Lab Anal* 2018; **32**: e22341 [PMID: [29251384](#) DOI: [10.1002/jcla.22341](#)]
- 58 **Yan LB**, Zhang QB, Zhu X, He M, Tang H. Serum S100 calcium binding protein A4 improves the diagnostic accuracy of transient elastography for assessing liver fibrosis in hepatitis B. *Clin Res Hepatol Gastroenterol* 2018; **42**: 64-71 [PMID: [28688902](#) DOI: [10.1016/j.clinre.2017.05.013](#)]
- 59 **Zhijian Y**, Hui L, Weiming Y, Zhazhou L, Zhong C, Jinxin Z, Hongyan W, Xiangbin D, Weizhi Y, Duoyun L, Xiaojun L, Qiwen D. Role of the Aspartate Transaminase and Platelet Ratio Index in Assessing Hepatic Fibrosis and Liver Inflammation in Adolescent Patients with HBeAg-Positive Chronic Hepatitis B. *Gastroenterol Res Pract* 2015; **2015**: 906026 [PMID: [26236336](#) DOI: [10.1155/2015/906026](#)]
- 60 **Bonnard P**, Sombié R, Lescure FX, Bougouma A, Guiard-Schmid JB, Poynard T, Calès P, Housset C, Callard P, Le Pendeven C, Drabo J, Carrat F, Pialoux G. Comparison of elastography, serum marker scores, and histology for the assessment of liver fibrosis in hepatitis B virus (HBV)-infected patients in Burkina Faso. *Am J Trop Med Hyg* 2010; **82**: 454-458 [PMID: [20207872](#) DOI: [10.4269/ajtmh.2010.09-0088](#)]
- 61 **Lesmana CR**, Salim S, Hasan I, Sulaiman AS, Gani RA, Pakasi LS, Lesmana LA, Krisnuhoni E, Budihusodo U. Diagnostic accuracy of transient elastography (FibroScan) versus the aspartate transaminase to platelet ratio index in assessing liver fibrosis in chronic hepatitis B: the role in primary care setting. *J Clin Pathol* 2011; **64**: 916-920 [PMID: [21670074](#) DOI: [10.1136/jclinpath-2011-200044](#)]
- 62 **Liu HB**, Zhou JP, Zhang Y, Lv XH, Wang W. Prediction on liver fibrosis using different APRI thresholds when patient age is a categorical marker in patients with chronic hepatitis B. *Clin Chim Acta* 2011; **412**: 33-37 [PMID: [20828546](#) DOI: [10.1016/j.cca.2010.08.032](#)]
- 63 **Liu XD**, Wu JL, Liang J, Zhang T, Sheng QS. Globulin-platelet model predicts minimal fibrosis and cirrhosis in chronic hepatitis B virus infected patients. *World J Gastroenterol* 2012; **18**: 2784-2792 [PMID: [22719186](#) DOI: [10.3748/wjg.v18.i22.2784](#)]
- 64 **Sebastiani G**, Castera L, Halfon P, Pol S, Mangia A, Di Marco V, Pirisi M, Voiculescu M, Bourliere M, Alberti A. The impact of liver disease aetiology and the stages of hepatic fibrosis on the performance of non-invasive fibrosis biomarkers: an international study of 2411 cases. *Aliment Pharmacol Ther* 2011; **34**: 1202-1216 [PMID: [21981787](#) DOI: [10.1111/j.1365-2036.2011.04861.x](#)]
- 65 **Ucar F**, Sezer S, Ginis Z, Ozturk G, Albayrak A, Basar O, Ekiz F, Coban S, Yuksel O, Armutcu F, Akbal E. APRI, the FIB-4 score, and Forns index have noninvasive diagnostic value for liver fibrosis in patients with chronic hepatitis B. *Eur J Gastroenterol Hepatol* 2013; **25**: 1076-1081 [PMID: [23510962](#) DOI: [10.1097/MEG.0b013e32835fd699](#)]
- 66 **Wang H**, Xue L, Yan R, Zhou Y, Wang MS, Cheng MJ, Huang HJ. Comparison of FIB-4 and APRI in Chinese HBV-infected patients with persistently normal ALT and mildly elevated ALT. *J Viral Hepat* 2013; **20**: e3-10 [PMID: [23490387](#) DOI: [10.1111/jvh.12010](#)]
- 67 **Wang Y**, Xu MY, Zheng RD, Xian JC, Xu HT, Shi JP, Li SB, Qu Y, Dong YW, Lu LG. Prediction of significant fibrosis and cirrhosis in hepatitis B e-antigen negative patients with chronic hepatitis B using routine parameters. *Hepatol Res* 2013; **43**: 441-451 [PMID: [23006433](#) DOI: [10.1111/j.1872-034X.2012.01094.x](#)]
- 68 **Wu SD**, Wang JY, Li L. Staging of liver fibrosis in chronic hepatitis B patients with a composite predictive model: a comparative study. *World J Gastroenterol* 2010; **16**: 501-507 [PMID: [20101779](#) DOI: [10.3748/wjg.v16.i4.501](#)]
- 69 **Li J**, Yu J, Peng XY, Du TT, Wang JJ, Tong J, Lu GL, Wu XW. Acoustic Radiation Force Impulse (ARFI) Elastography and Serological Markers in Assessment of Liver Fibrosis and Free Portal Pressure in Patients with Hepatitis B. *Med Sci Monit* 2017; **23**: 3585-3592 [PMID: [28735336](#) DOI: [10.12659/msm.905896](#)]
- 70 **Dong CF**, Xiao J, Shan LB, Li HY, Xiong YJ, Yang GL, Liu J, Yao SM, Li SX, Le XH, Yuan J, Zhou BP, Tipoe GL, Liu YX. Combined acoustic radiation force impulse, aminotransferase to platelet ratio index and Forns index assessment for hepatic fibrosis grading in hepatitis B. *World J Hepatol* 2016; **8**: 616-624 [PMID: [27190578](#) DOI: [10.4254/wjh.v8.i14.616](#)]
- 71 **Dong DR**, Hao MN, Li C, Peng Z, Liu X, Wang GP, Ma AL. Acoustic radiation force impulse elastography, FibroScan®, Forns' index and their combination in the assessment of liver fibrosis in patients with chronic hepatitis B, and the impact of inflammatory activity and steatosis on these diagnostic methods. *Mol Med Rep* 2015; **11**: 4174-4182 [PMID: [25651500](#) DOI: [10.3892/mmr.2015.3299](#)]
- 72 **Friedrich-Rust M**, Buggisch P, de Knegt RJ, Dries V, Shi Y, Matschenz K, Schneider MD, Herrmann E, Petersen J, Schulze F, Zeuzem S, Sarrazin C. Acoustic radiation force impulse imaging for non-invasive assessment of liver fibrosis in chronic hepatitis B. *J Viral Hepat* 2013; **20**: 240-247 [PMID: [23490368](#) DOI: [10.1111/j.1365-2893.2012.01646.x](#)]
- 73 **Zhang D**, Chen M, Wang R, Liu Y, Zhang D, Liu L, Zhou G. Comparison of acoustic radiation force impulse imaging and transient elastography for non-invasive assessment of liver fibrosis in patients with chronic hepatitis B. *Ultrasound Med Biol* 2015; **41**: 7-14 [PMID: [25308941](#) DOI: [10.1016/j.ultrasmedbio.2014.07.018](#)]
- 74 **Ozturker C**, Karagoz E, Sivrioglu AK, Kara K. Clinical usefulness and performance of acoustic radiation force impulse in patients with chronic hepatitis B. *Eur J Gastroenterol Hepatol* 2017; **29**: 663-668 [PMID: [28151749](#) DOI: [10.1097/MEG.0000000000000842](#)]
- 75 **Park MS**, Kim SW, Yoon KT, Kim SU, Park SY, Tak WY, Kweon YO, Cho M, Kim BK, Park JY, Kim DY, Ahn SH, Han KH. Factors Influencing the Diagnostic Accuracy of Acoustic Radiation Force Impulse Elastography in Patients with Chronic Hepatitis B. *Gut Liver* 2016; **10**: 275-282 [PMID: [26087790](#) DOI: [10.5009/gnl14391](#)]

- 76 **Liu J**, Ji Y, Ai H, Ning B, Zhao J, Zhang Y, Dun G. Liver Shear-Wave Velocity and Serum Fibrosis Markers to Diagnose Hepatic Fibrosis in Patients with Chronic Viral Hepatitis B. *Korean J Radiol* 2016; **17**: 396-404 [PMID: [27134527](#) DOI: [10.3348/kjr.2016.17.3.396](#)]
- 77 **Liu F**, Wei L, Wang S, Huang B. Comparison of FibroTouch and acoustic radiation force impulse in diagnosis of liver fibrosis in patients with chronic hepatitis B. *Zhejiang Da Xue Xue Bao Yi Xue Ban* 2016; **45**: 416-421 [PMID: [27868416](#)]
- 78 **Coskun BD**, Altinkaya E, Sevinc E, Ozen M, Karaman H, Karaman A, Poyrazoglu O. The diagnostic value of a globulin/platelet model for evaluating liver fibrosis in chronic hepatitis B patients. *Rev Esp Enferm Dig* 2015; **107**: 740-744 [PMID: [26671586](#) DOI: [10.17235/reed.2015.3851/2015](#)]
- 79 **Zhang YF**, Shi H, Chen LB, Xu QH. [Value of FIB-4 for the diagnosis of liver fibrosis in chronic hepatitis B]. *Zhonghua Shi Yan He Lin Chuang Bing Du Xue Za Zhi* 2010; **24**: 215-217 [PMID: [21186531](#)]
- 80 **Zhao J**, Zhai F, Cheng J, He Q, Luo J, Yang X, Shao J, Xing H. Evaluating the Significance of Viscoelasticity in Diagnosing Early-Stage Liver Fibrosis with Transient Elastography. *PLoS One* 2017; **12**: e0170073 [PMID: [28107385](#) DOI: [10.1371/journal.pone.0170073](#)]
- 81 **Zeng X**, Xu C, He D, Li M, Zhang H, Wu Q, Xiang D, Wang Y. Performance of several simple, noninvasive models for assessing significant liver fibrosis in patients with chronic hepatitis B. *Croat Med J* 2015; **56**: 272-279 [PMID: [26088852](#) DOI: [10.3325/cmj.2015.56.272](#)]
- 82 **Leung VY**, Shen J, Wong VW, Abrigo J, Wong GL, Chim AM, Chu SH, Chan AW, Choi PC, Ahuja AT, Chan HL, Chu WC. Quantitative elastography of liver fibrosis and spleen stiffness in chronic hepatitis B carriers: comparison of shear-wave elastography and transient elastography with liver biopsy correlation. *Radiology* 2013; **269**: 910-918 [PMID: [23912619](#) DOI: [10.1148/radiol.13130128](#)]
- 83 **Degos F**, Perez P, Roche B, Mahmoudi A, Asselineau J, Voitot H, Bedossa P; FIBROSTIC study group. Diagnostic accuracy of FibroScan and comparison to liver fibrosis biomarkers in chronic viral hepatitis: a multicenter prospective study (the FIBROSTIC study). *J Hepatol* 2010; **53**: 1013-1021 [PMID: [20850886](#) DOI: [10.1016/j.jhep.2010.05.035](#)]
- 84 **Cho HJ**, Seo YS, Lee KG, Hyun JJ, An H, Keum B, Kim JH, Yim HJ, Jeon YT, Lee HS, Chun HJ, Um SH, Kim CD, Ryu HS. Serum aminotransferase levels instead of etiology affects the accuracy of transient elastography in chronic viral hepatitis patients. *J Gastroenterol Hepatol* 2011; **26**: 492-500 [PMID: [21332545](#) DOI: [10.1111/j.1440-1746.2010.06419.x](#)]
- 85 **Kim BK**, Kim HS, Park JY, Kim DY, Ahn SH, Chon CY, Park YN, Han KH, Kim SU. Prospective validation of ELF test in comparison with Fibroscan and FibroTest to predict liver fibrosis in Asian subjects with chronic hepatitis B. *PLoS One* 2012; **7**: e41964 [PMID: [22848675](#) DOI: [10.1371/journal.pone.0041964](#)]
- 86 **Huang R**, Jiang N, Yang R, Geng X, Lin J, Xu G, Liu D, Chen J, Zhou G, Wang S, Luo T, Wu J, Liu X, Xu K, Yang X. Fibroscan improves the diagnosis sensitivity of liver fibrosis in patients with chronic hepatitis B. *Exp Ther Med* 2016; **11**: 1673-1677 [PMID: [27168788](#) DOI: [10.3892/etm.2016.3135](#)]
- 87 **Kumar M**, Rastogi A, Singh T, Bihari C, Gupta E, Sharma P, Garg H, Kumar R, Bhatia V, Tyagi P, Sarin SK. Analysis of discordance between transient elastography and liver biopsy for assessing liver fibrosis in chronic hepatitis B virus infection. *Hepatol Int* 2013; **7**: 134-143 [PMID: [26201627](#) DOI: [10.1007/s12072-012-9380-5](#)]
- 88 **Kongtawelert P**, Chanmee T, Pothaeharoen P, Wisedopa N, Kranokpiruk P, Poovorawan K, Poovorawan Y, Tangkijvanich P. Diagnostic accuracy of liver stiffness measurement and serum hyaluronic acid for detecting liver fibrosis in chronic hepatitis B with respect to alt levels. *Asian Biomed* 2013; **7**: 609-617
- 89 **Kim BK**, Kim SU, Kim HS, Park JY, Ahn SH, Chon CY, Cho IR, Joh DH, Park YN, Han KH, Kim DY. Prospective validation of FibroTest in comparison with liver stiffness for predicting liver fibrosis in Asian subjects with chronic hepatitis B. *PLoS One* 2012; **7**: e35825 [PMID: [22536445](#) DOI: [10.1371/journal.pone.0035825](#)]
- 90 **Goyal R**, Mallick SR, Mahanta M, Kedia S, Shalimar, Dhingra R, Sharma H, Das P, Datta Gupta S, Panda S, Acharya SK. Fibroscan can avoid liver biopsy in Indian patients with chronic hepatitis B. *J Gastroenterol Hepatol* 2013; **28**: 1738-1745 [PMID: [23808910](#) DOI: [10.1111/jgh.12318](#)]
- 91 **Cardoso AC**, Carvalho-Filho RJ, Stern C, Dipumpo A, Giuily N, Ripault MP, Asselah T, Boyer N, Lada O, Castelnau C, Martinot-Peignoux M, Valla DC, Bedossa P, Marcellin P. Direct comparison of diagnostic performance of transient elastography in patients with chronic hepatitis B and chronic hepatitis C. *Liver Int* 2012; **32**: 612-621 [PMID: [22103765](#) DOI: [10.1111/j.1478-3231.2011.02660.x](#)]
- 92 **Gaia S**, Carenzi S, Barilli AL, Bugianesi E, Smedile A, Brunello F, Marzano A, Rizzetto M. Reliability of transient elastography for the detection of fibrosis in non-alcoholic fatty liver disease and chronic viral hepatitis. *J Hepatol* 2011; **54**: 64-71 [PMID: [20932598](#) DOI: [10.1016/j.jhep.2010.06.022](#)]
- 93 **Fung J**, Lai CL, Chan SC, But D, Seto WK, Cheng C, Wong DK, Lo CM, Fan ST, Yuen MF. Correlation of liver stiffness and histological features in healthy persons and in patients with occult hepatitis B, chronic active hepatitis B, or hepatitis B cirrhosis. *Am J Gastroenterol* 2010; **105**: 1116-1122 [PMID: [19920809](#) DOI: [10.1038/ajg.2009.665](#)]
- 94 **Lee HJ**, Seo YS, Kim DJ, Kang HS, An H, Kim JH, Cheong JY, Yim HJ, Yeon JE, Lee HS, Byun KS, Cho SW, Kim DJ, Um SH, Kim CD, Ryu HS. Application of the HALF index obviates the need for liver biopsy in half of all patients with chronic hepatitis B. *J Gastroenterol Hepatol* 2011; **26**: 987-995 [PMID: [21198828](#) DOI: [10.1111/j.1440-1746.2010.06609.x](#)]
- 95 **Myers RP**, Elkashab M, Ma M, Crotty P, Pomier-Layrargues G. Transient elastography for the noninvasive assessment of liver fibrosis: a multicentre Canadian study. *Can J Gastroenterol* 2010; **24**: 661-670 [PMID: [21157581](#) DOI: [10.1155/2010/153986](#)]
- 96 **Sporea I**, Sirli R, Deleanu A, Tudora A, Popescu A, Curescu M, Bota S. Liver stiffness measurements in patients with HBV vs HCV chronic hepatitis: a comparative study. *World J Gastroenterol* 2010; **16**: 4832-4837 [PMID: [20939112](#) DOI: [10.3748/wjg.v16.i38.4832](#)]
- 97 **Marcellin P**, Ziol M, Bedossa P, Douvin C, Poupon R, de Ledinghen V, Beaugrand M. Non-invasive assessment of liver fibrosis by stiffness measurement in patients with chronic hepatitis B. *Liver Int* 2009; **29**: 242-247 [PMID: [18637064](#) DOI: [10.1111/j.1478-3231.2008.01802.x](#)]
- 98 **Dong H**, Xu C, Zhou W, Liao Y, Cao J, Li Z, Hu B. The combination of 5 serum markers compared to FibroScan to predict significant liver fibrosis in patients with chronic hepatitis B virus. *Clin Chim Acta* 2018; **483**: 145-150 [PMID: [29709450](#) DOI: [10.1016/j.cca.2018.04.036](#)]
- 99 **Hennedige TP**, Wang G, Leung FP, Alsaif HS, Teo LL, Lim SG, Wee A, Venkatesh SK. Magnetic Resonance Elastography and Diffusion Weighted Imaging in the Evaluation of Hepatic Fibrosis in Chronic Hepatitis B. *Gut Liver* 2017; **11**: 401-408 [PMID: [27965475](#) DOI: [10.5009/gnl16079](#)]
- 100 **Lee JE**, Lee JM, Lee KB, Yoon JH, Shin CI, Han JK, Choi BI. Noninvasive assessment of hepatic fibrosis

- in patients with chronic hepatitis B viral infection using magnetic resonance elastography. *Korean J Radiol* 2014; **15**: 210-217 [PMID: 24643284 DOI: 10.3348/kjr.2014.15.2.210]
- 101 **Wu WP**, Chou CT, Chen RC, Lee CW, Lee KW, Wu HK. Non-Invasive Evaluation of Hepatic Fibrosis: The Diagnostic Performance of Magnetic Resonance Elastography in Patients with Viral Hepatitis B or C. *PLoS One* 2015; **10**: e0140068 [PMID: 26469342 DOI: 10.1371/journal.pone.0140068]
- 102 **Venkatesh SK**, Wang G, Lim SG, Wee A. Magnetic resonance elastography for the detection and staging of liver fibrosis in chronic hepatitis B. *Eur Radiol* 2014; **24**: 70-78 [PMID: 23928932 DOI: 10.1007/s00330-013-2978-8]
- 103 **Shi Y**, Guo Q, Xia F, Dzyubak B, Glaser KJ, Li Q, Li J, Ehman RL. MR elastography for the assessment of hepatic fibrosis in patients with chronic hepatitis B infection: does histologic necroinflammation influence the measurement of hepatic stiffness? *Radiology* 2014; **273**: 88-98 [PMID: 24893048 DOI: 10.1148/radiol.14132592]
- 104 **Chang W**, Lee JM, Yoon JH, Han JK, Choi BI, Yoon JH, Lee KB, Lee KW, Yi NJ, Suh KS. Liver Fibrosis Staging with MR Elastography: Comparison of Diagnostic Performance between Patients with Chronic Hepatitis B and Those with Other Etiologic Causes. *Radiology* 2016; **280**: 88-97 [PMID: 26844364 DOI: 10.1148/radiol.2016150397]
- 105 **Lavanchy D**. Hepatitis B virus epidemiology, disease burden, treatment, and current and emerging prevention and control measures. *J Viral Hepat* 2004; **11**: 97-107 [PMID: 14996343 DOI: 10.1046/j.1365-2893.2003.00487.x]
- 106 **World Health Organization**. *Guidelines for the prevention, care and treatment of persons with chronic hepatitis B infection* 2015; Available from: <https://www.who.int/hiv/pub/hepatitis/hepatitisb-guidelines/en/>
- 107 **Kim BK**, Kim DY, Park JY, Ahn SH, Chon CY, Kim JK, Paik YH, Lee KS, Park YN, Han KH. Validation of FIB-4 and comparison with other simple noninvasive indices for predicting liver fibrosis and cirrhosis in hepatitis B virus-infected patients. *Liver Int* 2010; **30**: 546-553 [PMID: 20074094 DOI: 10.1111/j.1478-3231.2009.02192.x]
- 108 **Friedrich-Rust M**, Nierhoff J, Lupsor M, Sporea I, Fierbinteanu-Braticevici C, Strobel D, Takahashi H, Yoneda M, Suda T, Zeuzem S, Herrmann E. Performance of Acoustic Radiation Force Impulse imaging for the staging of liver fibrosis: a pooled meta-analysis. *J Viral Hepat* 2012; **19**: e212-e219 [PMID: 22239521 DOI: 10.1111/j.1365-2893.2011.01537.x]
- 109 **Sporea I**, Sirli R, Popescu A, Danilă M. Acoustic Radiation Force Impulse (ARFI)--a new modality for the evaluation of liver fibrosis. *Med Ultrason* 2010; **12**: 26-31 [PMID: 21165451]
- 110 **Lockhart M**, Moore JW. Classical differential and operant conditioning in rabbits (*Oryctolagus cuniculus*) with septal lesions. *J Comp Physiol Psychol* 1975; **88**: 147-154 [PMID: 1120791 DOI: 10.1136/bmj.323.7305.157]
- 111 **Xu X**, Su Y, Song R, Sheng Y, Ai W, Wu X, Liu H. Performance of transient elastography assessing fibrosis of single hepatitis B virus infection: a systematic review and meta-analysis of a diagnostic test. *Hepatol Int* 2015; **9**: 558-566 [PMID: 26187292 DOI: 10.1007/s12072-015-9643-z]
- 112 **Xu XY**, Kong H, Song RX, Zhai YH, Wu XF, Ai WS, Liu HB. The effectiveness of noninvasive biomarkers to predict hepatitis B-related significant fibrosis and cirrhosis: a systematic review and meta-analysis of diagnostic test accuracy. *PLoS One* 2014; **9**: e100182 [PMID: 24964038 DOI: 10.1371/journal.pone.0100182]



Published By Baishideng Publishing Group Inc
7041 Koll Center Parkway, Suite 160, Pleasanton, CA 94566, USA
Telephone: +1-925-2238242
Fax: +1-925-2238243
E-mail: bpgoffice@wjgnet.com
Help Desk: <https://www.f6publishing.com/helpdesk>
<https://www.wjgnet.com>

