

# World Journal of *Clinical Cases*

*World J Clin Cases* 2019 June 26; 7(12): 1367-1534





### REVIEW

- 1367 Biomarkers *vs* imaging in the early detection of hepatocellular carcinoma and prognosis  
*Balaceanu LA*

### ORIGINAL ARTICLE

#### Basic Study

- 1383 Study on gene expression patterns and functional pathways of peripheral blood monocytes reveals potential molecular mechanism of surgical treatment for periodontitis  
*Ma JJ, Liu HM, Xu XH, Guo LX, Lin Q*

#### Case Control Study

- 1393 Clinical differentiation of acute appendicitis and right colonic diverticulitis: A case-control study  
*Sasaki Y, Komatsu F, Kashima N, Sato T, Takemoto I, Kijima S, Maeda T, Ishii T, Miyazaki T, Honda Y, Shimada N, Urita Y*

#### Retrospective Study

- 1403 Feasibility of prostatectomy without prostate biopsy in the era of new imaging technology and minimally invasive techniques  
*Xing NZ, Wang MS, Fu Q, Yang FY, Li CL, Li YJ, Han SJ, Xiao ZJ, Ping H*
- 1410 Safety and efficacy of transfemoral intrahepatic portosystemic shunt for portal hypertension: A single-center retrospective study  
*Zhang Y, Liu FQ, Yue ZD, Zhao HW, Wang L, Fan ZH, He FL*

#### Observational Study

- 1421 Impact of gastroesophageal reflux disease on the quality of life of Polish patients  
*Gorczyca R, Pardak P, Pękala A, Filip R*

### SYSTEMATIC REVIEWS

- 1430 Non-*albicans* *Candida* prosthetic joint infections: A systematic review of treatment  
*Koutserimpas C, Zervakis SG, Maraki S, Alpantaki K, Ioannidis A, Kofteridis DP, Samonis G*

### META-ANALYSIS

- 1444 Relationship between circulating irisin levels and overweight/obesity: A meta-analysis  
*Jia J, Yu F, Wei WP, Yang P, Zhang R, Sheng Y, Shi YQ*

### CASE REPORT

- 1456 Cirrhosis complicating Shwachman-Diamond syndrome: A case report  
*Camacho SM, McLoughlin L, Nowicki MJ*

- 1461** Robot-assisted trans-gastric drainage and debridement of walled-off pancreatic necrosis using the EndoWrist stapler for the da Vinci Xi: A case report  
*Morelli L, Furbetta N, Gianardi D, Palmeri M, Di Franco G, Bianchini M, Stefanini G, Guadagni S, Di Candio G*
- 1467** Fulminant liver failure following a marathon: Five case reports and review of literature  
*Figiel W, Morawski M, Grąt M, Kornasiewicz O, Niewiński G, Raszeja-Wyszomirska J, Krasnodębski M, Kowalczyk A, Holówko W, Patkowski W, Zieniewicz K*
- 1475** Gaucher disease in Montenegro - genotype/phenotype correlations: Five cases report  
*Vujosevic S, Medenica S, Vujicic V, Dapcevic M, Bakic N, Yang R, Liu J, Mistry PK*
- 1483** Longitudinal observation of ten family members with idiopathic basal ganglia calcification: A case report  
*Kobayashi S, Utsumi K, Tateno M, Iwamoto T, Murayama T, Sohma H, Ukai W, Hashimoto E, Kawanishi C*
- 1492** Secondary lymphoma develops in the setting of heart failure when treating breast cancer: A case report  
*Han S, An T, Liu WP, Song YQ, Zhu J*
- 1499** Removal of pediatric stage IV neuroblastoma by robot-assisted laparoscopy: A case report and literature review  
*Chen DX, Hou YH, Jiang YN, Shao LW, Wang SJ, Wang XQ*
- 1508** Premonitory urges located in the tongue for tic disorder: Two case reports and review of literature  
*Li Y, Zhang JS, Wen F, Lu XY, Yan CM, Wang F, Cui YH*
- 1515** Female genital tract metastasis of lung adenocarcinoma with EGFR mutations: Report of two cases  
*Yan RL, Wang J, Zhou JY, Chen Z, Zhou JY*
- 1522** Novel heterozygous missense mutation of *SLC12A3* gene in Gitelman syndrome: A case report  
*Wang CL*
- 1529** Thoracotomy of an asymptomatic, functional, posterior mediastinal paraganglioma: A case report  
*Yin YY, Yang B, Ahmed YA, Xin H*

**ABOUT COVER**

Editorial Board Member of *World Journal of Clinical Cases*, Amirhossein Sahebkar, PharmD, PhD, Associate Professor, Biotechnology Research Center, Mashhad University of Medical Sciences, Mashhad 9177948564, Khorasan-Razavi, Iran

**AIMS AND SCOPE**

*World Journal of Clinical Cases* (*World J Clin Cases*, *WJCC*, online ISSN 2307-8960, DOI: 10.12998) is a peer-reviewed open access academic journal that aims to guide clinical practice and improve diagnostic and therapeutic skills of clinicians.

The primary task of *WJCC* is to rapidly publish high-quality Case Report, Clinical Management, Editorial, Field of Vision, Frontier, Medical Ethics, Original Articles, Meta-Analysis, Minireviews, and Review, in the fields of allergy, anesthesiology, cardiac medicine, clinical genetics, clinical neurology, critical care, dentistry, dermatology, emergency medicine, endocrinology, family medicine, gastroenterology and hepatology, etc.

**INDEXING/ABSTRACTING**

The *WJCC* is now indexed in PubMed, PubMed Central, Science Citation Index Expanded (also known as SciSearch®), and Journal Citation Reports/Science Edition. The 2018 Edition of Journal Citation Reports cites the 2017 impact factor for *WJCC* as 1.931 (5-year impact factor: N/A), ranking *WJCC* as 60 among 154 journals in Medicine, General and Internal (quartile in category Q2).

**RESPONSIBLE EDITORS FOR THIS ISSUE**

Responsible Electronic Editor: Jie Wang

Proofing Production Department Director: Yun-Xiaojuan Wu

**NAME OF JOURNAL**

*World Journal of Clinical Cases*

**ISSN**

ISSN 2307-8960 (online)

**LAUNCH DATE**

April 16, 2013

**FREQUENCY**

Semimonthly

**EDITORS-IN-CHIEF**

Dennis A Bloomfield, Sandro Vento

**EDITORIAL BOARD MEMBERS**

<https://www.wjgnet.com/2307-8960/editorialboard.htm>

**EDITORIAL OFFICE**

Jin-Lei Wang, Director

**PUBLICATION DATE**

June 26, 2019

**COPYRIGHT**

© 2019 Baishideng Publishing Group Inc

**INSTRUCTIONS TO AUTHORS**

<https://www.wjgnet.com/bpg/gerinfo/204>

**GUIDELINES FOR ETHICS DOCUMENTS**

<https://www.wjgnet.com/bpg/GerInfo/287>

**GUIDELINES FOR NON-NATIVE SPEAKERS OF ENGLISH**

<https://www.wjgnet.com/bpg/gerinfo/240>

**PUBLICATION MISCONDUCT**

<https://www.wjgnet.com/bpg/gerinfo/208>

**ARTICLE PROCESSING CHARGE**

<https://www.wjgnet.com/bpg/gerinfo/242>

**STEPS FOR SUBMITTING MANUSCRIPTS**

<https://www.wjgnet.com/bpg/GerInfo/239>

**ONLINE SUBMISSION**

<https://www.f6publishing.com>



## Fulminant liver failure following a marathon: Five case reports and review of literature

Wojciech Figiel, Marcin Morawski, Michał Grąt, Oskar Kornasiewicz, Grzegorz Niewiński, Joanna Raszeja-Wyszomirska, Maciej Krasnodębski, Arkadiusz Kowalczyk, Wacław Hołówo, Waldemar Patkowski, Krzysztof Zieniewicz

**ORCID number:** Wojciech Figiel (0000-0001-9716-7824); Marcin Morawski (0000-0002-7056-8668); Michał Grąt (0000-0003-3372-3072); Oskar Kornasiewicz (0000-0003-4027-0059); Grzegorz Niewiński (0000-0002-3185-5250); Joanna Raszeja-Wyszomirska (0000-0001-7204-9784); Maciej Krasnodębski (0000-0002-6234-615X); Arkadiusz Kowalczyk (0000-0002-2765-1271); Wacław Hołówo (0000-0003-1419-2704); Waldemar Patkowski (0000-0002-6238-1967); Krzysztof Zieniewicz (0000-0003-4481-1289).

**Author contributions:** Figiel W, Morawski M designed the study concept; Figiel W, Morawski M, Grąt M, Kornasiewicz O, Niewiński G, Raszeja-Wyszomirska J, Krasnodębski M, Kowalczyk A, Hołówo W, Patkowski W collected the data; Figiel W, Morawski M, Zieniewicz K analyzed the data; Figiel W, Morawski M wrote the draft of the article; all authors critically revised the manuscript; Zieniewicz K supervised the study.

**Supported by** the Foundation for Polish Science (FNP) with START stipend, No. START 032.2018.

**Informed consent statement:** Informed consent statement was obtained from the reported patients.

**Conflict-of-interest statement:** The authors deny any conflict of interest.

Wojciech Figiel, Marcin Morawski, Michał Grąt, Oskar Kornasiewicz, Maciej Krasnodębski, Arkadiusz Kowalczyk, Wacław Hołówo, Waldemar Patkowski, Krzysztof Zieniewicz, Department of General, Transplant, and Liver Surgery, Medical University of Warsaw, Warsaw 02097, Poland

Grzegorz Niewiński, Department of Anaesthesiology and Intensive Care, Medical University of Warsaw, Warsaw 02097, Poland

Joanna Raszeja-Wyszomirska, Liver and Internal Medicine Unit, Department of General, Transplant, and Liver Surgery, Medical University of Warsaw, Warsaw 02097, Poland

**Corresponding author:** Marcin Morawski, MD, Doctor, PhD student, Department of General, Transplant, and Liver Surgery, Medical University of Warsaw, ul. Banacha 1A, Warsaw 02097, Poland. [marcin.morawski@wum.edu.pl](mailto:marcin.morawski@wum.edu.pl)

**Telephone:** +48-22-5992545

**Fax:** +48-22-5991545

### Abstract

#### BACKGROUND

The growing popularity of marathon and half-marathon runs has led to an increased number of patients presenting with exertion-induced heat stroke. Mild hepatic involvement is often observed in these patients; however, fulminant liver failure may occur in approximately 5% of all cases. Liver transplantation is a potentially curative approach for exertion-induced liver failure, although there is a lack of consensus regarding the criteria and optimal timing of this intervention.

#### CASE SUMMARY

This paper describes 5 patients (4 men and 1 woman) who were referred to the department where this study was performed with the diagnosis of exertion-induced acute liver failure. Three patients underwent liver transplantation, 1 recovered spontaneously, and 1 patient died on day 11 following the exertion.

#### CONCLUSION

Exertion-induced heat stroke may present as fulminant liver failure. These patients may recover with conservative treatment, may require liver transplantation, or may die. No definitive criteria are available to determine patient suitability for a conservative *vs* surgical approach.



**CARE Checklist (2016) statement:**

The authors have read the CARE Checklist (2016), and the manuscript was prepared and revised according to the CARE Checklist (2016).

**Open-Access:** This article is an open-access article which was selected by an in-house editor and fully peer-reviewed by external reviewers. It is distributed in accordance with the Creative Commons Attribution Non Commercial (CC BY-NC 4.0) license, which permits others to distribute, remix, adapt, build upon this work non-commercially, and license their derivative works on different terms, provided the original work is properly cited and the use is non-commercial. See: <http://creativecommons.org/licenses/by-nc/4.0/>

**Manuscript source:** Unsolicited manuscript

**Received:** March 3, 2019

**Peer-review started:** March 4, 2019

**First decision:** April 18, 2019

**Revised:** April 29, 2019

**Accepted:** May 1, 2019

**Article in press:** May 2, 2019

**Published online:** June 26, 2019

**P-Reviewer:** Nag DS

**S-Editor:** Dou Y

**L-Editor:** A

**E-Editor:** Xing YX



**Key words:** Heat Stroke; Hepatic insufficiency; Liver transplantation; Case report

©The Author(s) 2019. Published by Baishideng Publishing Group Inc. All rights reserved.

**Core tip:** Patients with exertion-induced heat stroke may develop fulminant liver failure and may recover with conservative treatment alone or require liver transplantation. To date, there is a lack of definitive criteria to identify patients who could potentially benefit from a surgical vs. a conservative approach. This study discusses a series of 5 cases in which the following 3 distinct clinical outcomes were observed in patients: spontaneous recovery, the need for liver transplantation, and death following exertion-induced liver failure.

**Citation:** Figiel W, Morawski M, Grąt M, Kornasiewicz O, Niewiński G, Raszeja-Wyszomirska J, Krasnodębski M, Kowalczyk A, Hołowko W, Patkowski W, Zieniewicz K. Fulminant liver failure following a marathon: Five case reports and review of literature. *World J Clin Cases* 2019; 7(12): 1467-1474  
**URL:** <https://www.wjnet.com/2307-8960/full/v7/i12/1467.htm>  
**DOI:** <https://dx.doi.org/10.12998/wjcc.v7.i12.1467>

## INTRODUCTION

In recent years, marathons have gained widespread popularity and attract both, professional and homegrown runners. More than 800 races are held every year<sup>[1]</sup>, usually during the spring and summer, when high external temperature and humidity can create unfavorable conditions for exercise.

Heat produced by the human body at rest is a by-product of baseline metabolism. Homeostatic mechanisms tend to maintain the core body temperature within a range of  $37 \pm 0.5$  °C<sup>[2]</sup>. The liver, the heart, and the brain are organs with high metabolic rates and the main heat generators in the body. This heat is spread *via* the circulation to other body parts. Additional heat generated by the muscles during exercise can be dissipated by radiation or conduction to prevent hyperthermic injury to organs only when the core temperature exceeds the external temperature. However, when the conditions are reversed, sweating and evaporation occur to achieve heat loss. Under unfavorable conditions (*e.g.*, high external temperature and humidity and/or strenuous exercise) sweating and evaporation may be inadequate with a consequent elevation in core body temperature and multi-organ failure, which is defined as exertional heat stroke (EHS).

Individuals with EHS show core temperature  $> 40$  °C with consequent loss of consciousness and multi-organ damage<sup>[3]</sup>. Hepatic injury is common under such conditions; however, owing to the remarkable hepatic functional reserve, those affected might typically remain asymptomatic. However, acute liver failure has been reported in approximately 5% of patients with EHS<sup>[4]</sup>. Orthotopic liver transplantation (OLTx) is indicated in these individuals<sup>[5]</sup>, although a few reports have described spontaneous recovery in such patients<sup>[6]</sup>.

## CASE PRESENTATION

Between 2005 and 2017, 4 patients (3 men and 1 woman) were referred to the Department of General, Transplant, and Liver Surgery at the Medical University of Warsaw, and 1 man was referred to the Department of General and Transplant Surgery in Szczecin following a marathon run with clinical and biochemical findings suggesting EHS-induced fulminant liver failure (FLF).

### Case 1

A previously healthy 24-year-old man collapsed after a 10-km run and was admitted to a local hospital. On initial examination, he was conscious with body temperature of 39.9 °C and right upper quadrant abdominal tenderness, but no neurological symptoms. The patient reported slight upper abdominal discomfort lasting a few weeks before the marathon and also the use of protein and amino acid supplements as part of his preparations for the marathon. Blood tests performed on days 2 and 3 of

hospitalization revealed sudden elevation of serum alanine aminotransferase (ALT) and aspartate aminotransferase (AST) (ALT from 430 U/L to 8166 U/L and AST from 1397 U/L to 7550 U/L) (Figure 1A), lactate dehydrogenase (LDH) activity elevation from 4349 U/L to 10096 U/L, creatine kinase (CK) of 135400 U/L (indicating rhabdomyolysis), as well as deterioration of the synthetic function of the liver represented by an increased international normalized ratio (INR) of 7.12 (Figure 1B). Rhabdomyolysis caused acute kidney injury and elevation of serum creatinine levels (2.08 mg/dL, 4.70 mg/dL, and 6.28 mg/dL on days 1, 2, and 3, respectively) and a reduced estimated glomerular filtration rate (from 41.7 mL/min/1.73 m<sup>2</sup> to 11.7 mL/min/1.73 m<sup>2</sup>). Owing to the progressive worsening of his clinical status and biochemical parameters, the patient was referred to the department where this study was performed on day 3. On admission to our department, the patient was completely conscious [Glasgow Coma Scale (GCS) = 15] and cooperative. He was anuric (serum creatinine = 5.29 mg/dL) with anasarca. His abdomen was soft with normal peristalsis with slight epigastric tenderness. Additionally, subconjunctival and subcutaneous right cubital fossa hemorrhage was observed. Triple-phase abdominal computed tomography (CT) showed mild pleural and pelvic effusions, and faint contrast enhancement of the liver parenchyma [without contrast: 15 Hounsfield Units (HU), arterial phase: 20 HU, portal phase: 33 HU].

### Case 2

A previously healthy 26-year-old woman collapsed after a marathon run at the seaside (ambient temperature of 25°C) and was admitted to a local hospital. On initial examination, she was unconscious, with body temperature of 42°C, and upper body muscle rigidity. She regained consciousness within a few hours after admission; however, she demonstrated psychomotor irritability and reported upper abdominal discomfort. Head CT was performed to evaluate her prolonged upper body muscle rigidity, and the study was unremarkable. Blood tests performed on day 3 revealed markedly elevated serum ALT and AST levels of 6161 U/L and 7322 U/L, respectively (Figure 1C), LDH of 38910 U/L, serum CK levels > 40000 U/L (indicating rhabdomyolysis), as well as severe deterioration of the synthetic function of the liver represented by an increased INR of 18.1 on day 3 (Figure 1D). Owing to the severe hepatic impairment and rhabdomyolysis, the patient was referred to the department where this study was performed on day 3 to assess her suitability to undergo urgent liver transplantation. On admission to our department, the patient was stuporous. Her laboratory test results showed signs of acute renal failure (serum creatinine = 4.2 mg/dL) and disseminated intravascular coagulation (DIC, INR = 18.1, D-dimer = 13310 µg/mL, 28000 platelets/mm<sup>3</sup>, fibrinogen = 79 mg/dL) with no signs of hemorrhage or active bleeding.

### Case 3

A previously healthy 27-year-old man collapsed after an 11-km marathon run and was admitted to a local hospital. On initial examination, he was unconscious, and his initial medical records did not show details of his temperature, neurological status, or the efforts made to reduce his body temperature. He regained consciousness within a few hours after admission and was asymptomatic except for upper abdominal discomfort. Owing to rapid elevation of liver function tests on day 2 (Figures 1E, 1F), he was transferred to the department where this study was performed on day 2 for further evaluation. On admission to our department, the patient was fully conscious (GCS = 15) and only reported mild upper abdominal tenderness. His serum AST and ALT levels were high at 2916 U/L and 4085 U/L, respectively, LDH elevation to 3557 U/L, thrombocytopenia of 74000 platelets/mm<sup>3</sup>, and INR = 1.74.

### Case 4

A previously healthy 33-year-old man collapsed after running several kilometers during a marathon (ambient temperature = 30 °C) and was admitted to a local hospital. On admission, he was comatose (GCS = 6) with blood pressure of 90/60 mmHg, as well as nuchal and upper body muscle rigidity. CT upon admission did not show any abnormalities of the central nervous system. His early medical records did not show any information regarding body temperature or endeavors to reduce hyperthermia. He regained consciousness within a few hours after admission and was treated conservatively with crystalloid infusion. Assessment performed on consecutive days showed laboratory tests indicating DIC (INR = 8.81, 23000 platelets/mm<sup>3</sup>) accompanied by anterior chest wall hemorrhages without any signs of major bleeding. He was treated with fresh frozen plasma and intramuscular vitamin K1 injections. Blood tests performed on days 3 and 4 showed marked elevation of serum AST, ALT, and bilirubin levels (Figures 1G, 1H). Owing to the development of anuria and deterioration of his condition, he was transferred to the intensive care unit

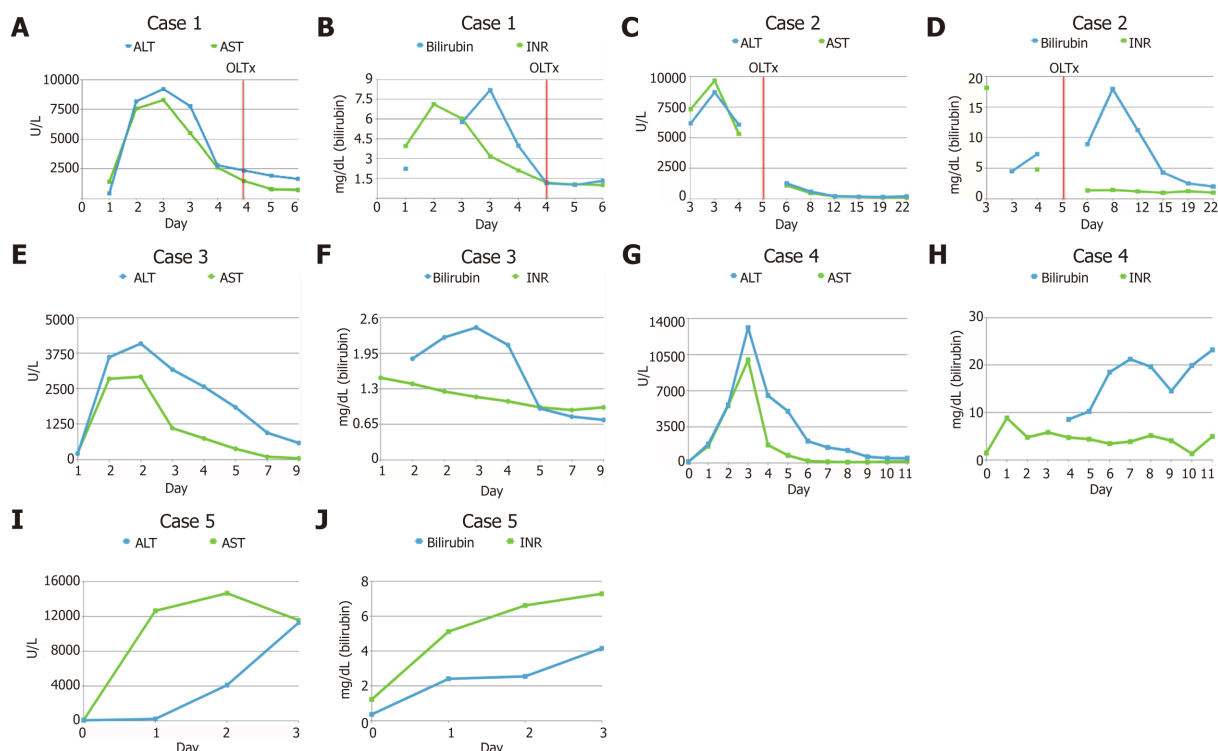


Figure 1 Laboratory findings following the exertion and liver transplantation. A, B: Case 1; C, D: Case 2; E, F: Case 3; G, H: Case 4; I, J: Case 5.

where he was intubated and continuous veno-venous hemodialysis was initiated. He was transferred to the department where this study was performed on day 7 following the exertion. On admission to our department, he was unconscious (GCS = 3) and was intubated.

### Case 5

A previously healthy 39-year-old man fainted after running several kilometers during a marathon and was admitted to a local hospital. On admission, the patient was stuporous and presented with generalized seizures. However, clinical examination did not show any significant abnormalities, and body cooling efforts were not deemed necessary. His medical history revealed several-year treatment for bipolar disorder (carbamazepine, clomipramine, and piracetam). Owing to rapidly progressing liver failure (Figure 1I, J) and rhabdomyolysis (CK = 15755 U/L, myoglobin > 1000 µg/L), the patient was referred to the department where this study was performed on day 3 to assess his suitability to undergo liver transplantation. On admission to our department, he was conscious and cooperative but slightly drowsy.

## FINAL DIAGNOSIS

In all five cases that were treated at our department, an exertion induced fulminant liver failure was confirmed the diagnostic follow up including other causes of fulminant liver failure. The diagnosis of heat stroke was established in accordance with criteria of Japanese Association of Acute Medicine Heat Stroke Committee Working Group<sup>[6]</sup>.

## TREATMENT

### Case 1

Immediately after admission, the patient's case was reviewed by the transplant team, and he was shortlisted for OLTx as an urgent recipient. Continuous renal replacement therapy was initiated to treat persistent rhabdomyolysis. The patient received cryoprecipitate and prothrombin complex concentrate transfusions, as well as parenteral vitamin K1 owing to severe coagulopathy (INR = 6.02) and thrombocytopenia (50000 platelets/mm<sup>3</sup>). OLTx was performed on day 4 following the



exertion. The liver was procured from a deceased donor and a piggy-back technique with end-to-end biliary anastomosis was used.

### Case 2

Body cooling was performed in the emergency department. The patient was examined by the transplant team and considered an appropriate candidate to receive urgent OLTx, which was performed (using the liver from a deceased donor) on day 5 following her initial admission to the previous hospital. A standard piggy-back technique and end-to-end biliary anastomosis were performed.

### Case 3

The case was reviewed by the transplant team, and the patient was listed for urgent OLTx.

### Case 4

Immediately after arrival to our department, his case was reviewed by our transplant team, and he was listed as an urgent candidate for OLTx. On day 9 following exertion, progression of liver failure necessitated the institution of the Prometheus liver support therapy system.

### Case 5

The case was reviewed by the transplant team, and he was listed as a candidate for OLTx. The OLTx was performed on day 4 following the exertion. The liver was procured from a deceased donor, and a piggy-back technique with end-to-end biliary anastomosis was used. A burst abdomen necessitated a reoperation on days 11 and 22 after the OLTx. His perioperative period was complicated by renal insufficiency treated with continuous veno-venous hemofiltration on the 1<sup>st</sup> and 2<sup>nd</sup> postoperative days.

---

## OUTCOME AND FOLLOW-UP

---

### Case 1

Liver and renal function recovered immediately after OLTx (day 5 onwards). Serum AST, ALT, bilirubin, and INR levels were normalized over a 30-d period following the OLTx (ALT = 63 U/L, AST = 31 U/L, bilirubin = 0.5 mg/dL, and INR = 0.98), and his serum creatinine level was sustained at 2.19 mg/dL. He was transferred from the surgical unit to the inpatient liver ward on post-transplantation day 10 and was discharged on postoperative day 30. He is presently 44 wk post-transplantation without any complaints.

### Case 2

A rapid decrease in serum aminotransferases (ALT = 580 U/L and AST = 440 U/L on post-transplantation day 3 and restoration of hepatic synthetic function (INR = 1.37 on post-transplantation day 1) occurred following the OLTx. Persistent features of kidney failure (serum creatinine = 7.42 mg/dL on post-transplantation day 3) necessitated the initiation of hemodialysis over 2 d. Intra-abdominal hemorrhage necessitated 2 reoperations (on post-transplantation days 7 and 14). She was discharged on postoperative day 40 without any signs of liver or renal impairment. She is now 13 years post-transplantation.

### Case 3

While awaiting a suitable graft, his biochemical parameters started improving, and his serum AST and ALT levels were 44 U/L and 584 U/L, respectively on day 9. He was discharged on day 9 following the exertion with no clinical and biochemical signs of liver or renal damage.

### Case 4

On the following day after admission, the patient developed hypertensive urgency (blood pressure 320/220 mmHg) followed by a rapid decline in blood pressure requiring noradrenaline infusion. The incident was accompanied by bilaterally dilated pupils that soon became unreactive. CT showed intracerebral hemorrhage in the left parietal area. A second episode of severe elevation of blood pressure was observed, and the patient died on day 11 following the exertion.

### Case 5

The patient was discharged on day 37 following OLTx after his laboratory test results showed normalization, with no signs of liver or renal function impairment. He is now

10 years post-transplantation.

## DISCUSSION

This report discusses a case series comprising 5 previously healthy individuals who developed signs of EHS-induced FLF. All patients were screened for other causes of FLF including hepatitis B and C infection, Wilson's disease, autoimmune hepatitis, and hemochromatosis. Owing to a lack of admission records in a few patients, it was not possible to determine whether all patients met Bouchama's criteria for heat stroke<sup>[7]</sup>, although all patients fulfilled the Japanese Association of Acute Medicine Heat Stroke Committee Working Group (JAAM-HS-WG) criteria<sup>[6]</sup>: The JAAM-HS-WG definition includes patients exposed to high environmental temperature meeting at least 1 of the following criteria: (1) GCS of  $\leq 14$ ; (2) Serum creatinine or total bilirubin levels of  $\geq 1.2$  mg/dL; and (3) JAAM DIC score of  $\geq 4$ <sup>[8]</sup>.

All patients in this case series showed the classical evolution of the clinical course observed in such cases, comprising the following: (1) Hyperthermic phase (neurological disturbances associated with hyperthermia); (2) Hematological and enzymatic phase (leukocytosis and hypocoagulability); and (3) Renal and hepatic phase (acute liver and renal failure)<sup>[9]</sup>. The mechanisms for heat-induced liver failure remain unclear; however, it has previously been suggested that heat-triggered systemic inflammation can cause multi-organ failure with consequent activation of multiple pathways promoting cell death including interleukin 1b and high mobility group box protein 1 downstream signaling<sup>[10,11]</sup>. It is also known that the pathophysiology of EHS-induced liver failure is associated with ischemia-induced hypoxic hepatitis<sup>[12]</sup>, which may be attributed to systemic hypoperfusion caused by shunting of blood to the skin, thrombosis of inflow vessels, or congestive heart failure<sup>[12]</sup>. This hypothesis is supported in this study by the radiological finding of poor contrast enhancement in Case 1 suggesting flow disturbances in the liver parenchyma observed on day 3<sup>[4,5,12,16-32]</sup> (Figure 1I) and significant hypotension (blood pressure 60/40 mmHg) upon admission in Case 4.

This study highlights 3 distinct clinical outcomes in these patients: (1) Death while awaiting a suitable graft; (2) OLTx; and (3) Spontaneous recovery with supportive treatment alone. These observations highlight the need for criteria to determine the necessity and urgency of OLTx. Currently, the King's College Criteria (KCC) and the Clichy criteria are widely accepted prognostic indicators to select patients with FLF who require OLTx. Based on the KCC, OLTx should be performed in patients presenting with non-acetaminophen-induced acute liver injury when the prothrombin time is longer than 100 s (INR  $> 6.5$ ), or if any 3 of the following criteria are observed: (1) Prothrombin time  $> 50$  s (INR  $> 3.5$ ); (2) Age  $< 10$  years or  $> 40$  years; (3) Duration of jaundice before onset of encephalopathy  $> 7$  d; (4) Total serum bilirubin level  $> 17.5$  mg/dL; and (5) Etiology attributable to non-A and non-B hepatitis, halothane hepatitis, or idiosyncratic drug reactions<sup>[13]</sup>. In this study, 4 of 5 patients met the KCC within 3 d following exertion. Interestingly, the only patient who did not meet the KCC was Case 4 who recovered spontaneously. This observation suggests that KCC could potentially predict patient suitability for OLTx; however, further studies are warranted to verify this hypothesis. Patients with FLF are not routinely screened for Factor V levels at the hospital where this study was performed; therefore, identifying which patients met the Clichy criteria was not possible<sup>[14]</sup>. Furthermore, the Clichy criteria were designed to predict outcomes in patients with acute viral hepatitis, which would limit their value/applicability in patients with EHS-induced FLF<sup>[15]</sup>.

A PubMed database search (keywords: Liver transplantation, heatstroke) yielded 20 cases of EHS-induced FLF (Figure 2). Of these 20 patients, 14 (70%) were treated conservatively and 6 (30%) received OLTx. Among the patients treated conservatively, 6 patients (43%) died and 8 (57%) recovered spontaneously.

## CONCLUSION

This case series and a review of the literature show that EHS constitute a heterogeneous group of patients observed at emergency departments with varying clinical presentations. Thus, it is difficult to conclusively predict patient outcomes and the urgency of OLTx. Multicenter analysis of existing cases would help to establish more accurate guidelines to manage patients presenting with EHS-induced FLF.

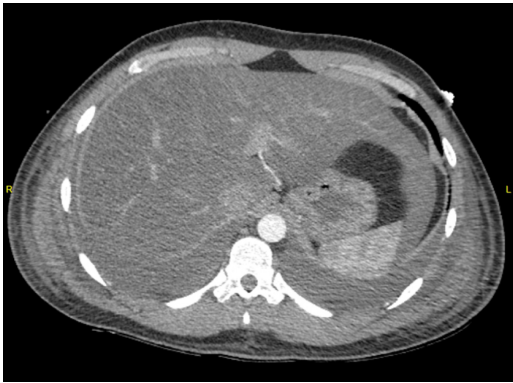

Figure 2 Poor contrast enhancement of liver parenchyma in arterial phase in Case 1.

## REFERENCES

- 1 Day SM, Thompson PD. Cardiac risks associated with marathon running. *Sports Health* 2010; **2**: 301-306 [PMID: 23015951 DOI: 10.1177/1941738110373066]
- 2 Hutchison JS, Ward RE, Lacroix J, Hébert PC, Barnes MA, Bohn DJ, Dirks PB, Doucette S, Fergusson D, Gottesman R, Joffe AR, Kirpalani HM, Meyer PG, Morris KP, Moher D, Singh RN, Skippen PW; Hypothermia Pediatric Head Injury Trial Investigators and the Canadian Critical Care Trials Group. Hypothermia therapy after traumatic brain injury in children. *N Engl J Med* 2008; **358**: 2447-2456 [PMID: 18525042 DOI: 10.1056/NEJMoa0706930]
- 3 Adams T, Stacey E, Stacey S, Martin D. Exertional heat stroke. *Br J Hosp Med (Lond)* 2012; **73**: 72-78 [PMID: 22504748 DOI: 10.12968/hmed.2012.73.2.72]
- 4 Hadad E, Ben-Ari Z, Heled Y, Moran DS, Shani Y, Epstein Y. Liver transplantation in exertional heat stroke: a medical dilemma. *Intensive Care Med* 2004; **30**: 1474-1478 [PMID: 15105986 DOI: 10.1007/s00134-004-2312-7]
- 5 Hassanein T, Perper JA, Tepperman L, Starzl TE, Van Thiel DH. Liver failure occurring as a component of exertional heatstroke. *Gastroenterology* 1991; **100**: 1442-1447 [PMID: 2013389 DOI: 10.1016/0016-5085(91)70036-W]
- 6 Hifumi T, Kondo Y, Shimizu K, Miyake Y. Heat stroke. *J Intensive Care* 2018; **6**: 30 [PMID: 29850022 DOI: 10.1186/s40560-018-0298-4]
- 7 Bouchama A, Knochel JP. Heat stroke. *N Engl J Med* 2002; **346**: 1978-1988 [PMID: 12075060 DOI: 10.1056/NEJMr011089]
- 8 Gando S, Saitoh D, Ogura H, Mayumi T, Koseki K, Ikeda T, Ishikura H, Iba T, Ueyama M, Eguchi Y, Otomo Y, Okamoto K, Kushimoto S, Endo S, Shimazaki S; Japanese Association for Acute Medicine Disseminated Intravascular Coagulation (JAAM DIC) Study Group. Disseminated intravascular coagulation (DIC) diagnosed based on the Japanese Association for Acute Medicine criteria is a dependent continuum to overt DIC in patients with sepsis. *Thromb Res* 2009; **123**: 715-718 [PMID: 18774163 DOI: 10.1016/j.thromres.2008.07.006]
- 9 Epstein Y. Exertional heatstroke: lessons we tend to forget. *Am J Med Sports* 2000; **2**: 143-152
- 10 Leon LR, Helwig BG. Heat stroke: role of the systemic inflammatory response. *J Appl Physiol* (1985) 2010; **109**: 1980-1988 [PMID: 20522730 DOI: 10.1152/jappphysiol.00301.2010]
- 11 Geng Y, Ma Q, Liu YN, Peng N, Yuan FF, Li XG, Li M, Wu YS, Li BL, Song WB, Zhu W, Xu WW, Fan J, Su L. Heatstroke induces liver injury via IL-1 $\beta$  and HMGB1-induced pyroptosis. *J Hepatol* 2015; **63**: 622-633 [PMID: 25931416 DOI: 10.1016/j.jhep.2015.04.010]
- 12 Heneghan HM, Nazirawan F, Dorcaratto D, Fiore B, Boylan JF, Maguire D, Hoti E. Extreme heatstroke causing fulminant hepatic failure requiring liver transplantation: a case report. *Transplant Proc* 2014; **46**: 2430-2432 [PMID: 24998305 DOI: 10.1016/j.transproceed.2013.12.055]
- 13 O'Grady JG, Alexander GJ, Hayllar KM, Williams R. Early indicators of prognosis in fulminant hepatic failure. *Gastroenterology* 1989; **97**: 439-445 [PMID: 2490426 DOI: 10.1016/0016-5085(89)90081-4]
- 14 Pauwels A, Mostefa-Kara N, Florent C, Lévy VG. Emergency liver transplantation for acute liver failure. Evaluation of London and Clichy criteria. *J Hepatol* 1993; **17**: 124-127 [PMID: 8445211 DOI: 10.1016/S0168-8278(05)80532-X]
- 15 Bernuau J, Samuel D, Durand F. Criteria for emergency liver transplantation in patients with acute viral hepatitis and factor V below 50% of normal: a prospective study. *Hepatology* 1991; **14**: 49A
- 16 Berger J, Hart J, Millis M, Baker AL. Fulminant hepatic failure from heat stroke requiring liver transplantation. *J Clin Gastroenterol* 2000; **30**: 429-431 [PMID: 10875474 DOI: 10.1097/00004836-200006000-00015]
- 17 Chavoutier-Uzzan F, Bernuau J, Degott C, Rueff B, Benhamou JP. [Heatstroke: a rare cause of massive hepatic necrosis due to hypoxia]. *Gastroenterol Clin Biol* 1988; **12**: 668-669 [PMID: 3063579]
- 18 Dunker M, Rehm M, Briegel J, Thiel M, Schelling G. [Exertion-related heat stroke. Lethal multiorgan failure from accidental hyperthermia in a 23 year old athlete]. *Anaesthesist* 2001; **50**: 500-505 [PMID: 11496687 DOI: 10.1007/s001010100169]
- 19 Feller RB, Wilson JS. Hepatic failure in fatal exertional heatstroke. *Aust N Z J Med* 1994; **24**: 69 [PMID: 8002866 DOI: 10.1111/j.1445-5994.1994.tb04433.x]
- 20 Fidler S, Fagan E, Williams R, Dewhurst I, Cory CE. Heatstroke and rhabdomyolysis presenting as fulminant hepatic failure. *Postgrad Med J* 1988; **64**: 157-159 [PMID: 3174530 DOI: 10.1136/pgmj.64.748.157]
- 21 Giercksky T, Boberg KM, Farstad IN, Halvorsen S, Schruppf E. Severe liver failure in exertional heat stroke. *Scand J Gastroenterol* 1999; **34**: 824-827 [PMID: 10499485 DOI: 10.1080/003655299750025778]

- 22 **Heyman SN**, Marmor S, Ben-Abraham R, Shani Y, Heled Y, Shapira I, Lifschitz-Mercer B, Amital H. [Multi-organ failure in a young soldier: a clinical-pathological meeting]. *Harefuah* 2002; **141**: 204-209, 220 [PMID: [11905096](#)]
- 23 **Ichai C**, Ciais JF, Hyvernat H, Labib Y, Fabiani P, Grimaud D. [Fatal acute liver failure: a rare complication of exertion-induced heat stroke]. *Ann Fr Anesth Reanim* 1997; **16**: 64-67 [PMID: [9686100](#) DOI: [10.1016/S0750-7658\(97\)84282-7](#)]
- 24 **Inayat F**, Virk HU. Liver Transplantation after Exertional Heatstroke-Induced Acute Liver Failure. *Cureus* 2016; **8**: e768 [PMID: [27738568](#) DOI: [10.7759/cureus.768](#)]
- 25 **Jin Q**, Chen E, Jiang J, Lu Y. Acute hepatic failure as a leading manifestation in exertional heat stroke. *Case Rep Crit Care* 2012; **2012**: 295867 [PMID: [24826335](#) DOI: [10.1155/2012/295867](#)]
- 26 Extreme physical effort in summer heat followed by collapse, stupor, purpura, jaundice and azotemia. *Am J Med* 1955; **18**: 659-670 [PMID: [14361451](#) DOI: [10.1016/0002-9343\(55\)90466-6](#)]
- 27 **Pastor MA**, Pérez-Aguilar F, Ortiz V, Nicolás D, Berenguer J. [Acute hepatitis due to heatstroke]. *Gastroenterol Hepatol* 1999; **22**: 398-399 [PMID: [10592672](#)]
- 28 **Saissy JM**. Liver transplantation in a case of fulminant liver failure after exertion. *Intensive Care Med* 1996; **22**: 831 [PMID: [8880256](#) DOI: [10.1007/BF01709530](#)]
- 29 **Sørensen JB**, Ranek L. Exertional heatstroke: survival in spite of severe hypoglycemia, liver and kidney damage. *J Sports Med Phys Fitness* 1988; **28**: 108-110 [PMID: [3398504](#)]
- 30 **Sukenik S**, Livnat S, Hausmann MJ, Sikuler E. [Heat stroke associated with massive hepatic necrosis]. *Harefuah* 1991; **121**: 425-429 [PMID: [1786888](#)]
- 31 **Takahashi K**, Chin K, Ogawa K, Kasahara M, Sakaguchi T, Hasegawa S, Sumi K, Nakamura T, Tamaki A, Mishima M, Nakamura T, Tanaka K. Living donor liver transplantation with noninvasive ventilation for exertional heat stroke and severe rhabdomyolysis. *Liver Transpl* 2005; **11**: 570-572 [PMID: [15838872](#) DOI: [10.1002/lt.20400](#)]
- 32 **Vescia FG**, Peck OC. Liver disease from heat stroke. *Gastroenterology* 1962; **43**: 340-343 [PMID: [13925606](#) DOI: [10.1016/S0016-5085\(19\)35014-0](#)]
- 33 **Davis BC**, Tillman H, Chung RT, Stravitz RT, Reddy R, Fontana RJ, McGuire B, Davern T, Lee WM; Acute Liver Failure Study Group. Heat stroke leading to acute liver injury & failure: A case series from the Acute Liver Failure Study Group. *Liver Int* 2017; **37**: 509-513 [PMID: [28128878](#) DOI: [10.1111/liv.13373](#)]



Published By Baishideng Publishing Group Inc  
7041 Koll Center Parkway, Suite 160, Pleasanton, CA 94566, USA  
Telephone: +1-925-2238242  
Fax: +1-925-2238243  
E-mail: [bpgoffice@wjgnet.com](mailto:bpgoffice@wjgnet.com)  
Help Desk: <https://www.f6publishing.com/helpdesk>  
<https://www.wjgnet.com>

