


World Journal of *Gastrointestinal Endoscopy*

World J Gastrointest Endosc 2019 November 16; 11(11): 523-547



**ORIGINAL ARTICLE****Retrospective Study**

- 523** Evaluating the risk of adverse events with interventional endoscopic retrograde cholangiopancreatography and endoscopic ultrasound procedures in cirrhotic patients

Yoo T, Epistola R, Epistola J, Ku L, Fleischman MW, Reicher S, Eysselein VE, Hou LA

Observational Study

- 531** Endoscopic ultrasound-through-the-needle biopsy in pancreatic cystic lesions: A large single center experience

Hashimoto R, Lee JG, Chang KJ, Chehade NEH, Samarasena JB

CASE REPORT

- 541** Oesophageal carcinoma mimicking a submucosal lesion: A case report

Shanmugam RM, Shanmugam C, Murugesan M, Kalyansundaram M, Gopalsamy S, Ranjan A

ABOUT COVER

Editorial Board Member of *World Journal of Gastrointestinal Endoscopy*, Antonio Pesce, MD, Research Fellow, Surgeon, Teaching Assistant, Medical, Surgical Sciences and Advanced Technologies "G.F. Ingrassia", University Hospital Policlinic "G. Rodolico", Catania 95123, Italy

AIMS AND SCOPE

The primary aim of *World Journal of Gastrointestinal Endoscopy* (WJGE, *World J Gastrointest Endosc*) is to provide scholars and readers from various fields of gastrointestinal endoscopy with a platform to publish high-quality basic and clinical research articles and communicate their research findings online.

WJGE mainly publishes articles reporting research results and findings obtained in the field of gastrointestinal endoscopy and covering a wide range of topics including capsule endoscopy, colonoscopy, double-balloon enteroscopy, duodenoscopy, endoscopic retrograde cholangiopancreatography, endosonography, esophagoscopy, gastrointestinal endoscopy, gastroscopy, laparoscopy, natural orifice endoscopic surgery, proctoscopy, and sigmoidoscopy.

INDEXING/ABSTRACTING

The WJGE is now abstracted and indexed in Emerging Sources Citation Index (Web of Science), PubMed, PubMed Central, China National Knowledge Infrastructure (CNKI), and Superstar Journals Database.

RESPONSIBLE EDITORS FOR THIS ISSUE

Responsible Electronic Editor: *Mei-Yi Liu*

Proofing Production Department Director: *Xiang Li*

NAME OF JOURNAL

World Journal of Gastrointestinal Endoscopy

ISSN

ISSN 1948-5190 (online)

LAUNCH DATE

October 15, 2009

FREQUENCY

Monthly

EDITORS-IN-CHIEF

Bing Hu, Anastasios Koulaouzidis, Sang Chul Lee

EDITORIAL BOARD MEMBERS

<https://www.wjgnet.com/1948-5190/editorialboard.htm>

EDITORIAL OFFICE

Ruo-Yu Ma, Director

PUBLICATION DATE

November 16, 2019

COPYRIGHT

© 2019 Baishideng Publishing Group Inc

INSTRUCTIONS TO AUTHORS

<https://www.wjgnet.com/bpg/gerinfo/204>

GUIDELINES FOR ETHICS DOCUMENTS

<https://www.wjgnet.com/bpg/GerInfo/287>

GUIDELINES FOR NON-NATIVE SPEAKERS OF ENGLISH

<https://www.wjgnet.com/bpg/gerinfo/240>

PUBLICATION MISCONDUCT

<https://www.wjgnet.com/bpg/gerinfo/208>

ARTICLE PROCESSING CHARGE

<https://www.wjgnet.com/bpg/gerinfo/242>

STEPS FOR SUBMITTING MANUSCRIPTS

<https://www.wjgnet.com/bpg/GerInfo/239>

ONLINE SUBMISSION

<https://www.f6publishing.com>



Observational Study

Endoscopic ultrasound-through-the-needle biopsy in pancreatic cystic lesions: A large single center experience

Rintaro Hashimoto, John G Lee, Kenneth J Chang, Nabil El Hage Chehade, Jason B Samarasena

ORCID number: Rintaro Hashimoto (0000-0002-6947-4138); John G Lee (0000-0001-9295-3447); Kenneth J Chang (0000-0001-9897-277X); Nabil El Hage Chehade (0000-0003-3578-395X); Jason B Samarasena (0000-0002-2981-3078).

Author contributions: All authors helped to perform the research; Hashimoto R manuscript writing, performing procedures and data analysis; Lee JG and Chang KJ performing procedures; El Hage Chehade N manuscript writing; Samarasena JB contribution to performing procedures and drafting conception.

Institutional review board statement: This study was reviewed and approved by the Ethics Committee of University of California Irvine Medical Center.

Informed consent statement: Patients were not required to give informed consent to the study because the analysis used anonymous clinical data that were obtained after each patient agreed to treatment by written consent.

Conflict-of-interest statement: No financial support was received from the company of microforceps to conduct this study. Dr Samarasena is a consultant to US Endoscopy. None of the other authors have any relevant conflicts of interest.

Data sharing statement: No data is shared.

STROBE statement: All the

Rintaro Hashimoto, John G Lee, Kenneth J Chang, Nabil El Hage Chehade, Jason B Samarasena, H. H. Chao Comprehensive Digestive Disease Center, Division of Gastroenterology and Hepatology, Department of Medicine, University of California, Irvine, Orange, CA 92868, United States

Corresponding author: Rintaro Hashimoto, MD, PhD, Doctor, H. H. Chao Comprehensive Digestive Disease Center, Division of Gastroenterology and Hepatology, Department of Medicine, University of California, Irvine, 333 City Blvd West, Suite 400, Orange, CA 92868, United States. rintaroh@uci.edu
Telephone: +1-714-4566745
Fax: +1-714-4567753

Abstract

BACKGROUND

Establishing a diagnosis of pancreatic cystic lesions (PCLs) preoperatively still remains challenging. Recently, endoscopic ultrasound (EUS)-through-the-needle biopsy (EUS-TTNB) using microforceps in PCLs has been made available.

AIM

To assess the efficacy and safety of EUS-TTNB in the diagnosis of PCLs.

METHODS

We retrospectively collected data of patients with PCLs who underwent both EUS-fine-needle aspiration (FNA) for cytology and EUS-TTNB at our institution since 2016. EUS-FNA for cytology was followed by EUS-TTNB in the same session. Evaluation of the cyst location, primary diagnosis, adverse events, and comparison between the cytologic fluid analyses and histopathology was performed. Technical success of EUS-TTNB was defined as visible tissue present after biopsy. Clinical success was defined as the presence of a specimen adequate to make a histologic or cytologic diagnosis.

RESULTS

A total of 56 patients (mean age 66.9 ± 11.7 , 53.6% females) with PCLs were enrolled over the study period. The mean cyst size was 28.8 mm (12-85 mm). The EUS-TTNB procedure was technically successful in all patients (100%). The clinical success rate using EUS-TTNB was much higher than standard EUS-FNA, respectively 80.4% (45/56) vs 25% (14/56). Adverse events occurred in 2 patients (3.6%) who developed mild pancreatitis that resolved with medical therapy. Using TTNB specimens, 23 of 32 cases (71.9%) with intraductal papillary

statement is checked.

Open-Access: This article is an open-access article which was selected by an in-house editor and fully peer-reviewed by external reviewers. It is distributed in accordance with the Creative Commons Attribution Non Commercial (CC BY-NC 4.0) license, which permits others to distribute, remix, adapt, build upon this work non-commercially, and license their derivative works on different terms, provided the original work is properly cited and the use is non-commercial. See: <http://creativecommons.org/licenses/by-nc/4.0/>

Manuscript source: Invited manuscript

Received: March 18, 2019

Peer-review started: March 18, 2019

First decision: May 9, 2019

Revised: September 25, 2019

Accepted: October 18, 2019

Article in press: October 18, 2019

Published online: November 16, 2019

P-Reviewer: Lim SJ, Reddy DN, Sitkin S, Zhu HF

S-Editor: Ma RY

L-Editor: A

E-Editor: Liu MY



mucinous neoplasm were further differentiated into gastric type (19 patients) and pancreaticobiliary type (4 patients) based on immunochemical staining.

CONCLUSION

EUS-TTNB for PCLs was technically feasible and had a favorable safety profile. Furthermore, the diagnostic yield for PCLs was much higher with EUS-TTNB than standard EUS-FNA cytology and fluid carcinoembryonic antigen. EUS-TTNB should be considered as an adjunct to EUS-FNA and cytologic analysis in the diagnosis and management of PCLs.

Key words: Pancreatic cyst lesion; Endoscopic ultrasound; Endoscopic ultrasound-guided fine needle aspiration; Cyst fluid; Biopsy

©The Author(s) 2019. Published by Baishideng Publishing Group Inc. All rights reserved.

Core tip: Establishing a diagnosis of pancreatic cystic lesions (PCLs) preoperatively still remains a challenge. Endoscopic ultrasound (EUS)-through-the-needle biopsy (EUS-TTNB) using microforceps was recently used to make a definitive diagnosis of PCLs. The aim of this study was to assess the safety and efficacy of EUS-TTNB compared with EUS-fine-needle aspiration (FNA), and feasibility of intrapapillary mucinous neoplasm (IPMN) subtyping using EUS-TTNB specimen. Fifty-six patients underwent EUS-TTNB. The rates of technical success, clinical success, and adverse events were 100%, 80.4% and 3.6%, respectively. The clinical success rate was higher in EUS-TTNB (80.4%) than in EUS-FNA (15%). IPMN subtyping was successful in 71.9% (23/32) in patients with IPMN.

Citation: Hashimoto R, Lee JG, Chang KJ, Chehade NEH, Samarasena JB. Endoscopic ultrasound-through-the-needle biopsy in pancreatic cystic lesions: A large single center experience. *World J Gastrointest Endosc* 2019; 11(11): 531-540

URL: <https://www.wjnet.com/1948-5190/full/v11/i11/531.htm>

DOI: <https://dx.doi.org/10.4253/wjge.v11.i11.531>

INTRODUCTION

Establishing a diagnosis of pancreatic cystic lesions (PCLs) preoperatively still remains challenging. PCLs are discovered more often than before as a result of the widespread use of highresolution imaging techniques^[1]. The prevalence of the PCLs is reported from 2.4% to 13.5% with increasing incidence with age^[2]. The incidence of PCLs has been reported in 12.9% in a population-based study over a period of 5-year follow-up^[3]. Some PCLs have the potential for malignant transformation to adenocarcinoma of the pancreas. On the other hand, the rate of malignant transformation is low in general^[4] and is estimated approximately 0.24% per year^[5]. The assessment of the risk of malignant transformation relies on information such as clinical history, results of radiological examinations, endoscopic ultrasound (EUS), cystic fluid analysis, and cytohistological testing. However, no single diagnostic tool has been found to be reliable for the differential diagnosis of PCLs.

EUS-fine needle aspiration (FNA) improves diagnostic accuracy in PCLs for differentiating mucinous versus non-mucinous PCLs, and malignant versus benign PCLs, in cases where computed tomography or magnetic resonance imaging are unclear. Evaluation of cyst fluid carcinoembryonic antigen (CEA), combined with cytology is often used for differentiating an IPMN or mucinous cystic neoplasm (MCN) from other PCLs. A recent meta-analysis showed EUS-FNA-based cytology had 42% sensitivity and 99% specificity to differentiate mucinous from non-mucinous pancreatic cystic neoplasm^[6]. A cyst fluid CEA level of ≥ 192 ng/mL can distinguish mucinous, from non-mucinous cysts, with a sensitivity of 52%-78% and specificity of 63-91%^[7-13]. In two meta-analysis, EUS-FNA-based cytology showed a sensitivity of 51% and specificity of 94% for the diagnosis of malignant PCLs^[14] and CEA seems not accurate to predict malignancy with sensitivity and specificity of 63%^[15]. Targeted cyst wall sampling using FNA can provide adequate specimen for cytologic or histologic evaluation in 65%-81% and offer additional diagnostic yield for mucinous cyst over fluid analysis/cytology alone^[16-18]. However, the diagnostic yield remains not enough

high due to the relatively small tissue sample that can be obtained using conventional FNA.

Recently, EUS-through-the-needle biopsy (EUS-TTNB) using microforceps (Figure 1; Moray™ microforceps, US Endoscopy, OH, United States) in PCLs has been made available^[19-27]. This method can provide a fragment of the cyst wall improving the diagnostic yield. However, there still remains limited data regarding the efficacy and its safety profile. The aim of this study is to evaluate EUS-TTNB in terms of diagnostic yield and safety in the diagnosis of PCLs. A secondary aim is to evaluate the additive value in diagnostic yield over standard EUS-FNA.

MATERIALS AND METHODS

Patient selection

We retrospectively reviewed all of the patients with PCLs who had EUS-FNA and EUS-TTNB at our institution between Jan 2016 and November 2018 using electronic endoscopy database. The indication of EUS-TTNB was judged by the endoscopists based on clinical background, size, radiologic imaging findings, existence of worrisome features like solid mass or nodule, and patient anxiety. This study protocol was approved by the University of California Irvine Medical Center Institutional Review Board.

Data collection

Patients demographics, radiologic imaging, endoscopy imaging, cyst fluid analysis, cytology and pathology results were reviewed. Follow-up data were obtained from clinical encounters or telephone interview after the procedure to discuss pathology results. Continuous variables were reported as median and range. Categorical variables were summarized as frequency and percentage.

Aims

The aim of this study was to assess the feasibility and safety of EUS-TTNB for PCLs, and evaluate the diagnostic yield compared with EUS-FNA.

Definitions

Technical success of EUS-TTNB was defined as visible tissue present after biopsy. Clinical success was defined as the presence of a specimen adequate to make a histologic or cytologic diagnosis. Safety was assessed by recording adverse events following American Society for Gastrointestinal Endoscopy Criteria. PCLs were classified as mucinous cysts (intraductal papillary mucinous neoplasms and mucinous cystic neoplasms), serous cystadenomas, or benign and/or inflammatory cysts (pseudocysts) based on cytology, pathology, and cyst fluid analysis. The histology evaluation of the TTNB specimen followed standard histology definitions for epithelial type. For diagnosis of mucinous cyst, mucinous epithelium with cytoplasmic mucin should be visible on routine hematoxylin and eosin stain. The presence of subepithelial ovarian type stroma defined an MCN, and the absence of such stroma defined an IPMN. If the diagnosis of IPMN was established, the expression of MUC1, MUC2, MUC5AC, MUC6 mucins were evaluated immunohistochemically for subtyping, if it was feasible.

Procedure

Three endosonographers performed or supervised all the EUS-TTNB procedures. Prophylactic antibiotics (Cefazolin 1g) were administered to all patients before needle puncture of PCLs. All the procedures were performed by using a linear echoendoscope (Olympus America, Center Valley, PA, United States). Careful evaluation was done for cyst location, size and presence of a mural nodule, solid mass or wall thickness. EUS-FNA was performed using the 19-gauge EUS-FNA needle (EchoTip Ultra needle; Cook Medical, Bloomington, IN, United States) with a stylet. Before puncturing PCLs, the stylet was removed and the microforceps was preloaded in the FNA needle. The needle was inserted into the PCL under EUS guidance and with the use of Doppler to avoid interposed vessels. After puncturing PCLs, the microforceps was inserted through the bore of the FNA needle. Once the forceps was seen within the cyst, the forceps was opened and the open jaws of the forceps were retracted and hubbed to the end of the needle (Figure 2). The needle with forceps open were then advanced using the FNA needle handle and gently pushed against the opposite walls, then closed and pulled back until the 'tent sign' was seen (Figure 3). Finally, the microforceps was pulled back inside the needle, and the specimen obtained was placed directly in formalin. In this manner, three to four passes were made with microforceps. After completion of biopsies, cyst fluid was aspirated and



Figure 1 Image of Moray™ microforceps (US Endoscopy, OH, United States).

sent for CEA and cytology. A minimum of 1 mL of intracystic fluid was aspirated and sent for CEA and amylase level. An experienced pathologist evaluated all the specimen and cytology. If IPMN was suspected, immunostaining was performed to determine the subtype. After the procedure, patients were followed up for any possible adverse events including abdominal pain, pancreatitis, or perforation.

Statistical analysis

In order to describe the patient cohort, descriptive statistical analyses were used, such as means, standard deviations, percentages, and frequency distribution, based on the nature of the statistical variables reported in the study. The value of $P < 0.05$ was considered statistically significant. Statistical analyses were done with R software (version 3.3.3; The R Foundation for Statistical Computing, Vienna, Austria).

RESULTS

Patient demographics, and clinical features of the PCLs are shown in Table 1. A total of 56 patients (mean age 66.9 ± 11.7 , 53.6% females) with PCLs were enrolled over the study period. The mean cyst size was 28.8 mm (12-85 mm). Cysts were in the uncinate (4 patients), head (13), neck (16), body (7) and tail (16). The average number of biopsies taken during EUS-TTNB was 3.14 per patient.

Technical and clinical success

The EUS-TTNB procedure was technically successful in all patients (100%). The clinical success rate using EUS-TTNB was much higher than standard EUS-FNA, respectively 80.4% (45/56) vs 25% (14/56). The results of histology confirmed by TTNB is shown in Table 2. There was one case of neuroendocrine tumor that was diagnosed by TTNB, which was not demonstrated by cytologic analysis. TTNB changed the diagnosis in one patient from mucinous cystadenoma to serous cystadenoma. TTNB made a diagnosis of adenocarcinoma in two cases. The one seemed to arise from IPMN and the other seemed to be cystic adenocarcinoma. Both cases were un-resectable.

Cyst fluid analysis

Fluid CEA analysis was available in 38/56 PCLs (67.9%). For the 25 PCLs with CEA < 192 ng/mL indicating a non-mucinous cyst, TTNB provided a diagnosis of mucinous cyst in 13/25 (52%) cases while EUS FNA provided a mucinous cyst diagnosis in 3/25 (12%) cases ($P < 0.01$). For 13 PCLs with CEA > 192 ng/mL, 10 PCLs (76.9%) were diagnosed as mucinous cyst based on TTNB histology while EUS-FNA gave a mucinous cyst diagnosis in 2/13 (15.4%) ($P < 0.01$) (Table 3).

Subtype of IPMN

Using TTNB specimens and immunostaining, 23 cases (71.9%) among 32 cases of intraductal papillary mucinous neoplasm were further differentiated into gastric type (19 patients) and pancreatobiliary type (4 patients) based on histological assessment and immunohistochemical staining.

Correlation between EUS-TTNB and surgical specimen

Four patients had surgery after EUS-TTNB in our case series. In three of four cases,

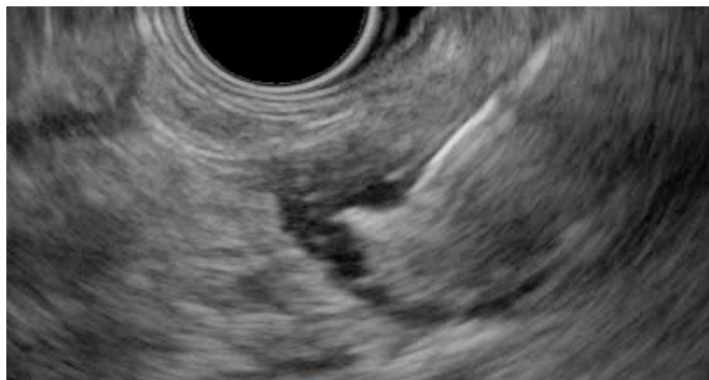

Figure 2 Endosonographic image of the microforceps opened within a pancreatic cystic lesion.

the diagnosis based on EUS-TTNB was the same as the one on surgical specimen. In one case, EUS-TTNB diagnosis was pancreato-biliary type IPMN, although it changed to gastric type IPMN on the surgical specimen.

Adverse events

Two patients (3.6%) developed acute pancreatitis after EUS-TTNB. Both patients were treated with supportive care and were discharged within 2 d without any invasive intervention.

DISCUSSION

EUS is useful in the diagnostic evaluation and estimating malignant potential of PCLs. EUS-FNA of PCLs is a well-established procedure and gives rise to information such as cytology and intracystic fluid marker analysis, to assist in differentiating mucinous from non-mucinous lesions. Differentiating PCLs is very important because SCAs do not require surgery, while on the other hand, MCNs need to be resected. However, the diagnostic accuracy of cytology and fluid markers such as CEA are still not enough high. Cyst fluid molecular analysis seemed promising but has issues with cost and availability^[6,12,28,29]. Some studies have shown that EUS-guided confocal laser endomicroscopy could be helpful but inter-observer agreement is very variable^[30,31]. EUS-TTNB is a straightforward procedure and some case series have already shown promising outcomes^[20-27].

Our study results showed 100% technical success and 80.4% of clinical success, which are very similar to previous case series study^[20-23,25-27]. In our study, 13 of 25 cysts with CEA < 192 ng/mL ended up having the diagnosis of mucinous cyst based on EUS-TTNB specimen. This result confirmed that fluid analysis for CEA is not reliable for differentiation of a mucinous cyst and non-mucinous cyst at our institution. EUS-TTNB demonstrated higher accuracy in providing the diagnosis of a mucinous cyst than EUS-FNA based cytology regardless of the value of CEA. This suggests EUS-TTNB is likely superior to the current standard of EUS-FNA cytology combined with fluid CEA analysis for detection of mucinous cysts.

With regards to complications, 2/56 patients (3.6%) developed acute pancreatitis after EUS-TTNB. Based on previous studies, the complications after this procedure are usually acute pancreatitis and local bleeding from the biopsy site. In the largest multicenter study of EUS-TTNB study with 114 patients^[26], pancreatitis occurred in 6 patients (5.3%). pancreatitis occurred in 6 patients (5.3%). This study contained one patient with severe acute pancreatitis who required cystogastrostomy for pseudocyst. In our study, pancreatitis in both patients were self-limited and mild.

In contrast to previous studies on TTNB, our institution attempted to subtype IPMN using the EUS-TTNB specimen. Several studies have suggested the histologic subtype of IPMN may be an important factor in its natural history. Studies have indicated in particular that the pancreaticobiliary subtype of IPMN may be associated with a poor prognosis^[32,33] although this is controversial^[34]. Using a combination of histologic analysis and immunohistochemical staining, we were successfully able to subtype the majority of IPMNs in our series. Subtyping using EUS-TTNB may be helpful to decide how to follow the IPMN without resection. Our study is the first study indicating that subtype of IPMN with EUS-TTNB can be reproducible. In one surgical case, IPMN subtype based on EUS-TTNB was not consistent with that based on the surgical specimen. In this particular case, the surgical specimen was a mixed

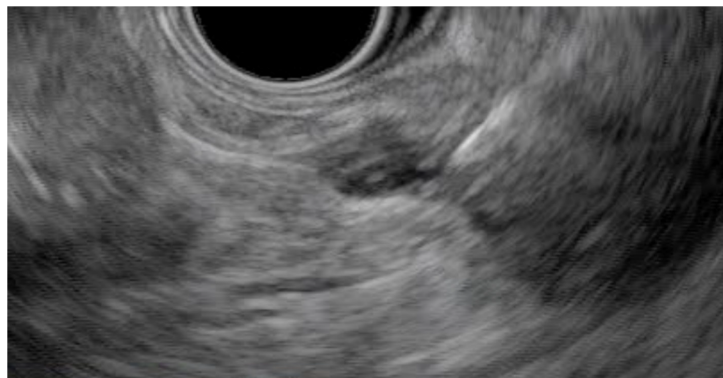

Figure 3 Endosonographic image of the microforceps bite of the wall tenting tissue within a pancreatic cystic lesion.

subtype and we do need to keep in mind that IPMN subtype based on EUS-TTNB may not represent the predominant subtype of the entire PCL in some cases.

Our study has several limitations. First, this is a single center, retrospective study. Secondly, the number of enrolled patients is relatively low, although this is the largest study at a single center study to our knowledge using a standardized technique. Lastly, we cannot conclude the correlation between TTNB specimen and surgical specimen because only 4 patients had surgery after EUS-TTNB in this cohort.

In conclusion, EUS-TTNB for PCLs was technically feasible and had a favorable safety profile in this study. Furthermore, the diagnostic yield for PCLs was much higher with EUS-TTNB than standard EUS-FNA cytology and fluid CEA. EUS-TTNB should be considered as an adjunct to EUS-FNA and cytologic analysis in the diagnosis and management of PCLs.

Table 1 Patient characteristics

Patient characteristics	
Age, mean \pm SD, yr	66.9 \pm 11.7
Sex, male/female	26/30
Cyst size, mm	28.8 (12-85)
Location	
Uncinate	4
Head	13
Neck	16
Body	7
Tail	16
Biopsy times	3.14 (1-6)
Pre-biopsy clinical diagnosis	
Intraductal papillary mucinous neoplasm	31
Unknown	18
Pseudocyst	5
Mucinous cystadenoma	1
Neuroendocrine tumor	1

Table 2 Results of endoscopic guided through the needle biopsy

Technical success	100% (56/56)
Clinical success	80.4% (45/56)
Adverse events	3.6% (2/56)
Histopathological diagnosis by EUS-TTNB	
IPMN	32
Pseudocyst	4
Serous cyst neoplasm	4
Neuroendocrine tumor	2
Adenocarcinoma	2
Paraganglioma	1
Inconclusive	11
Subtyping of IPMN (<i>n</i> = 32)	
Gastric type	19
Pancreatobiliary type	4
Inconclusive	9

IPMN: Intraductal papillary mucinous neoplasm; EUS-TTNB: Endoscopic ultrasound-through-the-needle biopsy.

Table 3 Comparison between endoscopic ultrasound-fine-needle aspiration and endoscopic ultrasound-through-the-needle biopsy

	EUS-FNA	EUS-TTNB	<i>P</i> value
Clinical success	25% (14/56)	80.4% (45/56)	< 0.001
Mucinous cyst diagnosis in cysts > CEA 192 ng/mL	12% (3/25)	52% (13/25)	0.005
Mucinous cyst diagnosis in cysts < CEA 192 ng/mL	15.4% (2/13)	76.9% (10/13)	0.005

EUS-FNA: Endoscopic ultrasound-fine-needle aspiration; EUS-TTNB: Endoscopic ultrasound-through-the-needle biopsy; CEA: Carcinoembryonic antigen.

ARTICLE HIGHLIGHTS

Research background

Pancreatic cysts are increasingly being identified in asymptomatic patients. Establishing a diagnosis of pancreatic cystic lesions (PCLs) preoperatively still remains a challenge. Endoscopic

ultrasound (EUS)-fine-needle aspiration (FNA) showed high specificity in diagnosing mucinous cysts and high grade atypia. However, the sensitivity is not enough high because of relatively acellular samples. Recently, EUS-through-the-needle biopsy (EUS-TTNB) using microforceps was recently used to make a definitive diagnosis of PCLs. There have been some studies showing the efficacy and safety of EUS-TTNB for PCLs.

Research motivation

The number of studies describing the safety and efficacy of EUS-TTNB is still small. There have been no study evaluating the feasibility of intraductal papillary mucinous neoplasm (IPMN) subtyping using EUS-TTNB specimen.

Research objectives

The aim of this study was to evaluate the safety and efficacy of EUS-TTNB, compare the tissue acquisition and diagnostic tissue yield of EUS-TTNB with EUS-FNA, and assess the feasibility of IPMN subtyping using EUS-TTNB specimen.

Research methods

A retrospective analysis of endoscopy reporting system and medical records of patients who underwent EUS-TTNB for PCLs was conducted. The review and analysis were conducted through our endoscopy reporting system (endoPRO iQ®) and medical records.

Research results

A total of 56 patients with PCLs were included. The clinical success rate using EUS-TTNB (80.4%) was much higher than EUS-FNA (25%). Adverse events occurred only in 2 patients (3.6%) who developed mild pancreatitis that resolved with medical therapy. Subtyping of IPMN was successful in 23 of 32 cases (71.9%) using TTNB specimens.

Research conclusions

EUS-TTNB is a safe and feasible procedure for evaluation of PCLs. The clinical success rate was higher in EUS-TTNB than in EUS-FNA. IPMN subtyping was also possible in many cases.

Research perspectives

Given recent development of genetic mutation analysis of PCLs, risk stratification using EUS-TTNB specimen might be possible in the future.

REFERENCES

- 1 Ketwaroo GA, Morteale KJ, Sawhney MS. Pancreatic Cystic Neoplasms: An Update. *Gastroenterol Clin North Am* 2016; **45**: 67-81 [PMID: 26895681 DOI: 10.1016/j.gtc.2015.10.006]
- 2 Lee KS, Sekhar A, Rofsky NM, Pedrosa I. Prevalence of incidental pancreatic cysts in the adult population on MR imaging. *Am J Gastroenterol* 2010; **105**: 2079-2084 [PMID: 20354507 DOI: 10.1038/ajg.2010.122]
- 3 Kromrey ML, Bülow R, Hübner J, Paperlein C, Lerch MM, Ittermann T, Völzke H, Mayerle J, Kühn JP. Prospective study on the incidence, prevalence and 5-year pancreatic-related mortality of pancreatic cysts in a population-based study. *Gut* 2018; **67**: 138-145 [PMID: 28877981 DOI: 10.1136/gutjnl-2016-313127]
- 4 Gardner TB, Glass LM, Smith KD, Ripple GH, Barth RJ, Klubansky DA, Colacchio TA, Tsapakos MJ, Suriawinata AA, Tsongalis GJ, Pipas JM, Gordon SR. Pancreatic cyst prevalence and the risk of mucin-producing adenocarcinoma in US adults. *Am J Gastroenterol* 2013; **108**: 1546-1550 [PMID: 24091499 DOI: 10.1038/ajg.2013.103]
- 5 Scheiman JM, Hwang JH, Moayyedi P. American gastroenterological association technical review on the diagnosis and management of asymptomatic neoplastic pancreatic cysts. *Gastroenterology* 2015; **148**: 824-824.e22 [PMID: 25805376 DOI: 10.1053/j.gastro.2015.01.014]
- 6 Gillis A, Cipollone I, Cousins G, Conlon K. Does EUS-FNA molecular analysis carry additional value when compared to cytology in the diagnosis of pancreatic cystic neoplasm? A systematic review. *HPB (Oxford)* 2015; **17**: 377-386 [PMID: 25428782 DOI: 10.1111/hpb.12364]
- 7 Al-Haddad M, DeWitt J, Sherman S, Schmidt CM, LeBlanc JK, McHenry L, Coté G, El Chafic AH, Luz L, Stuart JS, Johnson CS, Klochan C, Imperiale TF. Performance characteristics of molecular (DNA) analysis for the diagnosis of mucinous pancreatic cysts. *Gastrointest Endosc* 2014; **79**: 79-87 [PMID: 23845445 DOI: 10.1016/j.gie.2013.05.026]
- 8 Brugge WR, Lewandrowski K, Lee-Lewandrowski E, Centeno BA, Szydio T, Regan S, del Castillo CF, Warshaw AL. Diagnosis of pancreatic cystic neoplasms: a report of the cooperative pancreatic cyst study. *Gastroenterology* 2004; **126**: 1330-1336 [PMID: 15131794]
- 9 Cizginer S, Turner BG, Bilge AR, Karaca C, Pitman MB, Brugge WR. Cyst fluid carcinoembryonic antigen is an accurate diagnostic marker of pancreatic mucinous cysts. *Pancreas* 2011; **40**: 1024-1028 [PMID: 21775920 DOI: 10.1097/MPA.0b013e31821bd62f]
- 10 Gaddam S, Ge PS, Keach JW, Mullady D, Fukami N, Edmundowicz SA, Azar RR, Shah RJ, Murad FM, Kushnir VM, Watson RR, Ghassemi KF, Sedarat A, Komanduri S, Jaiyeola DM, Brauer BC, Yen RD, Amateau SK, Hosford L, Hollander T, Donahue TR, Schulick RD, Edil BH, McCarter M, Gajdos C, Attwell A, Muthusamy VR, Early DS, Wani S. Suboptimal accuracy of carcinoembryonic antigen in differentiation of mucinous and nonmucinous pancreatic cysts: results of a large multicenter study. *Gastrointest Endosc* 2015; **82**: 1060-1069 [PMID: 26077458 DOI: 10.1016/j.gie.2015.04.040]
- 11 Kadayifei A, Al-Haddad M, Atar M, Dewitt JM, Forcione DG, Sherman S, Casey BW, Fernandez-Del Castillo C, Schmidt CM, Pitman MB, Brugge WR. The value of KRAS mutation testing with CEA for the diagnosis of pancreatic mucinous cysts. *Endosc Int Open* 2016; **4**: E391-E396 [PMID: 27092317 DOI: 10.1055/s-0042-101755]
- 12 Khalid A, Zahid M, Finkelstein SD, LeBlanc JK, Kaushik N, Ahmad N, Brugge WR, Edmundowicz SA,

- Hawes RH, McGrath KM. Pancreatic cyst fluid DNA analysis in evaluating pancreatic cysts: a report of the PANDA study. *Gastrointest Endosc* 2009; **69**: 1095-1102 [PMID: [19152896](#) DOI: [10.1016/j.gie.2008.07.033](#)]
- 13 **Winner M**, Sethi A, Poneros JM, Stavropoulos SN, Francisco P, Lightdale CJ, Allendorf JD, Stevens PD, Gonda TA. The role of molecular analysis in the diagnosis and surveillance of pancreatic cystic neoplasms. *JOP* 2015; **16**: 143-149 [PMID: [25791547](#) DOI: [10.6092/1590-8577/2941](#)]
 - 14 **Wang QX**, Xiao J, Orange M, Zhang H, Zhu YQ. EUS-Guided FNA for Diagnosis of Pancreatic Cystic Lesions: a Meta-Analysis. *Cell Physiol Biochem* 2015; **36**: 1197-1209 [PMID: [26138881](#) DOI: [10.1159/000430290](#)]
 - 15 **Ngamruengphong S**, Bartel MJ, Raimondo M. Cyst carcinoembryonic antigen in differentiating pancreatic cysts: a meta-analysis. *Dig Liver Dis* 2013; **45**: 920-926 [PMID: [23790480](#) DOI: [10.1016/j.dld.2013.05.002](#)]
 - 16 **Barresi L**, Tarantino I, Traina M, Granata A, Curcio G, Azzopardi N, Baccarini P, Liotta R, Fornelli A, Maimone A, Jovine E, Cennamo V, Fabbri C. Endoscopic ultrasound-guided fine needle aspiration and biopsy using a 22-gauge needle with side fenestration in pancreatic cystic lesions. *Dig Liver Dis* 2014; **46**: 45-50 [PMID: [23916241](#) DOI: [10.1016/j.dld.2013.06.008](#)]
 - 17 **Hong SK**, Loren DE, Rogart JN, Siddiqui AA, Sendekci JA, Bibbo M, Coben RM, Meckes DP, Kowalski TE. Targeted cyst wall puncture and aspiration during EUS-FNA increases the diagnostic yield of premalignant and malignant pancreatic cysts. *Gastrointest Endosc* 2012; **75**: 775-782 [PMID: [22317883](#) DOI: [10.1016/j.gie.2011.12.015](#)]
 - 18 **Rogart JN**, Loren DE, Singu BS, Kowalski TE. Cyst wall puncture and aspiration during EUS-guided fine needle aspiration may increase the diagnostic yield of mucinous cysts of the pancreas. *J Clin Gastroenterol* 2011; **45**: 164-169 [PMID: [20818233](#) DOI: [10.1097/MCG.0b013e3181eed6d2](#)]
 - 19 **Attili F**, Pagliari D, Rimbaş M, Inzani F, Brizi MG, Costamagna G, Larghi A. Endoscopic ultrasound-guided histological diagnosis of a mucinous non-neoplastic pancreatic cyst using a specially designed through-the-needle microforceps. *Endoscopy* 2016; **48** Suppl 1: E188-E189 [PMID: [27213974](#) DOI: [10.1055/s-0042-108194](#)]
 - 20 **Barresi L**, Crinò SF, Fabbri C, Attili F, Poley JW, Carrara S, Tarantino I, Bernardoni L, Giovannelli S, Di Leo M, Manfrin E, Tacelli M, Bruno MJ, Traina M, Larghi A. Endoscopic ultrasound-through-the-needle biopsy in pancreatic cystic lesions: A multicenter study. *Dig Endosc* 2018; **30**: 760-770 [PMID: [29808529](#) DOI: [10.1111/den.13197](#)]
 - 21 **Basar O**, Yuksel O, Yang DJ, Samarasena J, Forcione D, DiMaio CJ, Wagh MS, Chang K, Casey B, Fernandez-Del Castillo C, Pitman MB, Brugge WR. Feasibility and safety of microforceps biopsy in the diagnosis of pancreatic cysts. *Gastrointest Endosc* 2018; **88**: 79-86 [PMID: [29510146](#) DOI: [10.1016/j.gie.2018.02.039](#)]
 - 22 **Kovacevic B**, Karstensen JG, Havre RF, Pham KD, Giovannini M, Dabizzi E, Arcidiacono P, Santo E, Sequeiros EV, Klausen P, Rift CV, Hasselby JP, Toxvaerd A, Kalaitzakis E, Hansen CP, Vilmann P. Initial experience with EUS-guided microforceps for diagnosis of pancreatic cystic lesions: A multicenter feasibility study (with video). *Endosc Ultrasound* 2018; **7**: 383-388 [PMID: [30168479](#) DOI: [10.4103/eus.eus.16_18](#)]
 - 23 **Kovacevic B**, Klausen P, Hasselby JP, Karstensen JG, Rift CV, Kalaitzakis E, Toxvaerd A, Hansen CP, Storkholm J, Hassan H, Vilmann P. A novel endoscopic ultrasound-guided through-the-needle microforceps procedure improves diagnosis of pancreatic cystic lesions. *Endoscopy* 2018; **50**: 1105-1111 [PMID: [29980151](#) DOI: [10.1055/a-0625-6440](#)]
 - 24 **Mittal C**, Obuch JC, Hammad H, Edmundowicz SA, Wani S, Shah RJ, Brauer BC, Attwell AR, Kaplan JB, Wagh MS. Technical feasibility, diagnostic yield, and safety of microforceps biopsies during EUS evaluation of pancreatic cystic lesions (with video). *Gastrointest Endosc* 2018; **87**: 1263-1269 [PMID: [29309781](#) DOI: [10.1016/j.gie.2017.12.025](#)]
 - 25 **Yang D**, Samarasena JB, Jamil LH, Chang KJ, Lee D, Ona MA, Lo SK, Gaddam S, Liu Q, Draganov PV. Endoscopic ultrasound-guided through-the-needle microforceps biopsy in the evaluation of pancreatic cystic lesions: a multicenter study. *Endosc Int Open* 2018; **6**: E1423-E1430 [PMID: [30574535](#) DOI: [10.1055/a-0770-2700](#)]
 - 26 **Yang D**, Trindade AJ, Yachinski P, Benias P, Nieto J, Manvar A, Ho S, Esnakula A, Gamboa A, Sethi A, Gupte A, Khara HS, Diehl DL, El Chafic A, Shah J, Forsmark CE, Draganov PV. Histologic Analysis of Endoscopic Ultrasound-Guided Through the Needle Microforceps Biopsies Accurately Identifies Mucinous Pancreas Cysts. *Clin Gastroenterol Hepatol* 2019; **17**: 1587-1596 [PMID: [30471456](#) DOI: [10.1016/j.cgh.2018.11.027](#)]
 - 27 **Zhang ML**, Arpin RN, Brugge WR, Forcione DG, Basar O, Pitman MB. Moray micro forceps biopsy improves the diagnosis of specific pancreatic cysts. *Cancer Cytopathol* 2018; **126**: 414-420 [PMID: [29660844](#) DOI: [10.1002/cncy.21988](#)]
 - 28 **Kadayifci A**, Atar M, Wang JL, Forcione DG, Casey BW, Pitman MB, Brugge WR. Value of adding GNAS testing to pancreatic cyst fluid KRAS and carcinoembryonic antigen analysis for the diagnosis of intraductal papillary mucinous neoplasms. *Dig Endosc* 2017; **29**: 111-117 [PMID: [27514845](#) DOI: [10.1111/den.12710](#)]
 - 29 **Singhi AD**, McGrath K, Brand RE, Khalid A, Zeh HJ, Chennat JS, Fasanella KE, Papachristou GI, Slivka A, Bartlett DL, Dasyam AK, Hogg M, Lee KK, Marsh JW, Monaco SE, Ohori NP, Pingpank JF, Tsung A, Zureikat AH, Wald AI, Nikiforova MN. Preoperative next-generation sequencing of pancreatic cyst fluid is highly accurate in cyst classification and detection of advanced neoplasia. *Gut* 2018; **67**: 2131-2141 [PMID: [28970292](#) DOI: [10.1136/gutjnl-2016-313586](#)]
 - 30 **Nakai Y**, Iwashita T, Park DH, Samarasena JB, Lee JG, Chang KJ. Diagnosis of pancreatic cysts: EUS-guided, through-the-needle confocal laser-induced endomicroscopy and cystoscopy trial: DETECT study. *Gastrointest Endosc* 2015; **81**: 1204-1214 [PMID: [25634486](#) DOI: [10.1016/j.gie.2014.10.025](#)]
 - 31 **Napoléon B**, Lemaistre AI, Pujol B, Caillol F, Lucidarme D, Bourdariat R, Morellon-Mialhe B, Fumex F, Lefort C, Lepilliez V, Palazzo L, Monges G, Filoche B, Giovannini M. A novel approach to the diagnosis of pancreatic serous cystadenoma: needle-based confocal laser endomicroscopy. *Endoscopy* 2015; **47**: 26-32 [PMID: [25325684](#) DOI: [10.1055/s-0034-1390693](#)]
 - 32 **Furukawa T**, Hatori T, Fujita I, Yamamoto M, Kobayashi M, Ohike N, Morohoshi T, Egawa S, Unno M, Takao S, Osako M, Yonezawa S, Mino-Kenudson M, Lauwers GY, Yamaguchi H, Ban S, Shimizu M. Prognostic relevance of morphological types of intraductal papillary mucinous neoplasms of the pancreas. *Gut* 2011; **60**: 509-516 [PMID: [21193453](#) DOI: [10.1136/gut.2010.210567](#)]
 - 33 **Distler M**, Kersting S, Niedergethmann M, Aust DE, Franz M, Rückert F, Ehehalt F, Pilarsky C, Post S,

- Saegeer HD, Grützmann R. Pathohistological subtype predicts survival in patients with intraductal papillary mucinous neoplasm (IPMN) of the pancreas. *Ann Surg* 2013; **258**: 324-330 [PMID: [23532107](#) DOI: [10.1097/SLA.0b013e318287ab73](#)]
- 34 **Kang MJ**, Lee KB, Jang JY, Han IW, Kim SW. Evaluation of clinical meaning of histological subtypes of intraductal papillary mucinous neoplasm of the pancreas. *Pancreas* 2013; **42**: 959-966 [PMID: [23462330](#) DOI: [10.1097/MPA.0b013e31827cddbc](#)]



Published By Baishideng Publishing Group Inc
7041 Koll Center Parkway, Suite 160, Pleasanton, CA 94566, USA
Telephone: +1-925-2238242
E-mail: bpgoffice@wjgnet.com
Help Desk: <https://www.f6publishing.com/helpdesk>
<https://www.wjgnet.com>

