


# World Journal of *Clinical Cases*

*World J Clin Cases* 2019 September 6; 7(17): 2413-2657



**MINIREVIEWS**

- 2413** Multifocal G1-G2 gastric neuroendocrine tumors: Differentiating between Type I, II and III, a clinicopathologic review  
*Algashaamy K, Garcia-Buitrago M*
- 2420** Attention deficit hyperactivity disorder and comorbidity: A review of literature  
*Gnanavel S, Sharma P, Kaushal P, Hussain S*

**ORIGINAL ARTICLE****Case Control Study**

- 2427** Dietary manipulation and testosterone replacement therapy may explain changes in body composition after spinal cord injury: A retrospective case report  
*Gorgey AS, Lester RM, Ghatas MP, Sistrun SN, Lavis T*

**Retrospective Study**

- 2438** Risk factors, clinical features, and short-term prognosis of spontaneous fungal peritonitis in cirrhosis: A matched case-control study  
*Huang CH, Pang LT, Xu LC, Ge TT, Xu QM, Chen Z*
- 2450** Incidence of portal vein thrombosis after splenectomy and its influence on transjugular intrahepatic portosystemic shunt stent patency  
*Dong F, Luo SH, Zheng LJ, Chu JG, Huang H, Zhang XQ, Yao KC*

**Observational Study**

- 2463** Multiplex gene expression profile in inflamed mucosa of patients with Crohn's disease ileal localization: A pilot study  
*Giudici F, Lombardelli L, Russo E, Cavalli T, Zambonin D, Logiodice F, Kullolli O, Giusti L, Bargellini T, Fazi M, Biancone L, Scaringi S, Clemente AM, Perissi E, Delfino G, Torcia MG, Ficari F, Tonelli F, Piccinni MP, Malentacchi C*

**Prospective Study**

- 2477** Analysis of the postoperative hemostatic profile of colorectal cancer patients subjected to liver metastasis resection surgery  
*Perez Navarro G, Pascual Bellosta AM, Ortega Lucea SM, Serradilla Martín M, Ramirez Rodriguez JM, Martinez Ubieta J*

**SYSTEMATIC REVIEW**

- 2487** Systematic review of ablative therapy for the treatment of renal allograft neoplasms  
*Favi E, Raison N, Ambrogi F, Delbue S, Clementi MC, Lamperti L, Perego M, Bischeri M, Ferraresso M*

## CASE REPORT

- 2505** Subcutaneous sarcoidosis of the upper and lower extremities: A case report and review of the literature  
*Mehrzaad R, Festa J, Bhatt R*
- 2513** Atypical cutaneous lesions in advanced-stage Hodgkin lymphoma: A case report  
*Massaro F, Ferrari A, Zendri E, Zanelli M, Merli F*
- 2519** Characteristics of multiple nodules in a patient with pulmonary Langerhans cell histiocytosis: A case report  
*Kanaji N, Tokunaga Y, Ishikawa R, Watanabe N, Kadowaki N*
- 2526** Impact of continuous local lavage on pancreatic juice-related postoperative complications: Three case reports  
*Hori T, Ogawa K, Yamamoto H, Harada H, Matsumura K, Yamamoto M, Yamada M, Yazawa T, Kuriyama K, Tani M, Yasukawa D, Kamada Y, Aisu Y, Tani R, Aoyama R, Nakayama S, Sasaki Y, Nishimoto K, Zaima M*
- 2536** Adult intussusception caused by colonic anisakis: A case report  
*Choi YI, Park DK, Cho HY, Choi SJ, Chung JW, Kim KO, Kwon KA, Kim YJ*
- 2542** Robotic-assisted resection of ovarian tumors in children: A case report  
*Xie XX, Wang N, Wang ZH, Zhu YY, Wang JR, Wang XQ*
- 2549** Synovial sarcoma in the plantar region: A case report and literature review  
*Gao J, Yuan YS, Liu T, Lv HR, Xu HL*
- 2556** Severe serous cavity bleeding caused by acquired factor V deficiency associated with lymphatic leakage in a hemodialysis patient: A case report  
*Zhao WB, Chen YR, Luo D, Lin HC, Long B, Wu ZY, Peng H*
- 2562** Supermicrosurgery in fingertip defects-split tibial flap of the second toe to reconstruct multiple fingertip defects: A case report  
*Wang KL, Zhang ZQ, Buckwalter JA, Yang Y*
- 2567** Ultrasound-guided fascia iliaca compartment block combined with general anesthesia for amputation in an acute myocardial infarction patient after percutaneous coronary intervention: A case report  
*Ling C, Liu XQ, Li YQ, Wen XJ, Hu XD, Yang K*
- 2573** Rare spontaneous intrahepatic portosystemic shunt in hepatitis B-induced cirrhosis: A case report  
*Tan YW, Sheng JH, Tan HY, Sun L, Yin YM*
- 2580** Imaging of mixed epithelial and stromal tumor of the kidney: A case report and review of the literature  
*Ye J, Xu Q, Zheng J, Wang SA, Wu YW, Cai JH, Yuan H*
- 2587** Allogenic tooth transplantation using 3D printing: A case report and review of the literature  
*Xu HD, Miron RJ, Zhang XX, Zhang YF*

## REVIEW

- 2597 Fecal microbiota transplantation as an effective initial therapy for pancreatitis complicated with severe *Clostridium difficile* infection: A case report  
*Hu Y, Xiao HY, He C, Lv NH, Zhu L*

## CASE REPORT

- 2605 Organ-associated pseudosarcomatous myofibroblastic proliferation with ossification in the lower pole of the kidney mimicking renal pelvic carcinoma: A case report  
*Zhai TY, Luo BJ, Jia ZK, Zhang ZG, Li X, Li H, Yang JJ*
- 2611 Treating aplasia cutis congenita in a newborn with the combination of ionic silver dressing and moist exposed burn ointment: A case report  
*Lei GF, Zhang JP, Wang XB, You XL, Gao JY, Li XM, Chen ML, Ning XQ, Sun JL*
- 2617 Cause of postprandial vomiting - a giant retroperitoneal ganglioneuroma enclosing large blood vessels: A case report  
*Zheng X, Luo L, Han FG*
- 2623 Carcinoma ex pleomorphic adenoma of the trachea: A case report  
*Gao HX, Li Q, Chang WL, Zhang YL, Wang XZ, Zou XX*
- 2630 Wilson disease associated with immune thrombocytopenia: A case report and review of the literature  
*Ma TJ, Sun GL, Yao F, Yang ZL*
- 2637 Calcifying fibrous tumor of the mediastinum: A case report  
*Qi DJ, Zhang QF*
- 2644 Brachiocephalic artery stenting through the carotid artery: A case report and review of the literature  
*Xu F, Wang F, Liu YS*
- 2652 An extremely rare pedunculated lipoma of the hypopharynx: A case report  
*Sun Q, Zhang CL, Liu ZH*

**ABOUT COVER**

Editorial Board Member of *World Journal of Clinical Cases*, Marianna Luongo, MD, Doctor, Surgeon, Department of Neurosurgery, Azienda Ospedaliera Regionale San Carlo, Potenza 85100, Italy

**AIMS AND SCOPE**

The primary aim of the *World Journal of Clinical Cases (WJCC)* is to provide scholars and readers from various fields of clinical medicine with a platform to publish high-quality clinical research articles and communicate their research findings online.

The *WJCC* mainly publishes case reports, case series, research results and findings in the field of clinical medicine covering a wide range of topics including diagnostic, therapeutic, and preventive modalities.

**INDEXING/ABSTRACTING**

The *WJCC* is now indexed in PubMed, PubMed Central, Science Citation Index Expanded (also known as SciSearch®), and Journal Citation Reports/Science Edition. The 2019 Edition of Journal Citation Reports cites the 2018 impact factor for *WJCC* as 1.153 (5-year impact factor: N/A), ranking *WJCC* as 99 among 160 journals in Medicine, General and Internal (quartile in category Q3).

**RESPONSIBLE EDITORS FOR THIS ISSUE**

Responsible Electronic Editor: *Yan-Xia Xing*

Proofing Production Department Director: *Yun-Xiaojian Wu*

**NAME OF JOURNAL**

*World Journal of Clinical Cases*

**ISSN**

ISSN 2307-8960 (online)

**LAUNCH DATE**

April 16, 2013

**FREQUENCY**

Semimonthly

**EDITORS-IN-CHIEF**

Dennis A Bloomfield, Sandro Vento

**EDITORIAL BOARD MEMBERS**

<https://www.wjnet.com/2307-8960/editorialboard.htm>

**EDITORIAL OFFICE**

Jin-Lei Wang, Director

**PUBLICATION DATE**

September 6, 2019

**COPYRIGHT**

© 2019 Baishideng Publishing Group Inc

**INSTRUCTIONS TO AUTHORS**

<https://www.wjnet.com/bpg/gerinfo/204>

**GUIDELINES FOR ETHICS DOCUMENTS**

<https://www.wjnet.com/bpg/GerInfo/287>

**GUIDELINES FOR NON-NATIVE SPEAKERS OF ENGLISH**

<https://www.wjnet.com/bpg/gerinfo/240>

**PUBLICATION MISCONDUCT**

<https://www.wjnet.com/bpg/gerinfo/208>

**ARTICLE PROCESSING CHARGE**

<https://www.wjnet.com/bpg/gerinfo/242>

**STEPS FOR SUBMITTING MANUSCRIPTS**

<https://www.wjnet.com/bpg/GerInfo/239>

**ONLINE SUBMISSION**

<https://www.f6publishing.com>

# Organ-associated pseudosarcomatous myofibroblastic proliferation with ossification in the lower pole of the kidney mimicking renal pelvic carcinoma: A case report

Tian-Yuan Zhai, Bin-Jie Luo, Zhan-Kui Jia, Zheng-Guo Zhang, Xiang Li, Hao Li, Jin-Jian Yang

**ORCID number:** Tian-Yuan Zhai (0000-0002-8481-1155); Bin-Jie Luo (0000-0002-0805-528X); Zhan-Kui Jia (0000-0003-2743-7002); Zheng-Guo Zhang (0000-0002-3727-6778); Xiang Li (0000-0002-5276-1798); Hao Li (0000-0003-3152-7545); Jin-Jian Yang (0000-0002-8498-7599).

**Author contributions:** Zhai TY, Luo BJ and Yang JJ designed the report; Zhang ZG, Li X and Li H collected the patient's clinical data; Zhai TY, Jia ZK and Yang JJ analyzed the data and wrote the paper.

**Supported by** the National Natural Science Foundation of China, No. 81570685.

**Informed consent statement:** The study participants provided informed written consent prior to their treatments and study enrollment.

**Conflict-of-interest statement:** All authors declare no conflict of interest related to this study or its publication.

**CARE Checklist (2016) statement:** The manuscript was prepared and revised according to the CARE Checklist (2016).

**Open-Access:** This article is an open-access article which was selected by an in-house editor and fully peer-reviewed by external reviewers. It is distributed in accordance with the Creative Commons Attribution Non Commercial (CC BY-NC 4.0) license, which permits others to distribute, remix, adapt, build

Tian-Yuan Zhai, Bin-Jie Luo, Zhan-Kui Jia, Zheng-Guo Zhang, Xiang Li, Hao Li, Jin-Jian Yang, Department of Urology, The First Affiliated Hospital of Zhengzhou University, Zhengzhou 450052, Henan Province, China

**Corresponding author:** Jin-Jian Yang, MD, MD, Professor, Surgeon, Department of Urology, The First Affiliated Hospital of Zhengzhou University, No. 1 Jianshe Road, Zhengzhou 450052, Henan Province, China. [yangjinjian2011@163.com](mailto:yangjinjian2011@163.com)

**Telephone:** +86-370-67967227

**Fax:** +86-370-67967227

## Abstract

### BACKGROUND

Organ-associated pseudosarcomatous myofibroblastic proliferation (PMP) is a very rare disorder. In the urogenital tract, PMP preferentially involves the urinary bladder; kidney involvement is rare. Here, we report a rare case of PMP with ossification in the lower pole of the kidney, which mimics urothelial carcinoma or an osteogenic tumor.

### CASE SUMMARY

A Chinese man was admitted to our hospital due to intermittent hematuria for more than 1 mo. Enhanced renal computed tomography revealed a mass in the left renal pelvis and upper ureter. The preoperative clinical diagnosis was renal pelvic carcinoma, determined by imaging examination and biopsy. After a standard preparation for surgery, the patient underwent retroperitoneoscopic radical nephroureterectomy. The operative findings were an extensive renal tumor (6 cm × 4.5 cm × 4.5 cm) invading the lower pole of the kidney and upper ureter. The final pathological diagnosis was organ-associated PMP with ossification. After 6-mo follow-up, no recurrence or metastasis was found.

### CONCLUSION

This case of PMP was unusual for its mimicking renal pelvic carcinoma in imaging examinations, making biopsy necessary.

**Key words:** Pseudosarcomatous myofibroblastic proliferation; Kidney; Renal pelvic; Carcinoma; Case report

©The Author(s) 2019. Published by Baishideng Publishing Group Inc. All rights reserved.

upon this work non-commercially, and license their derivative works on different terms, provided the original work is properly cited and the use is non-commercial. See: <http://creativecommons.org/licenses/by-nc/4.0/>

**Manuscript source:** Unsolicited manuscript

**Received:** March 17, 2019

**Peer-review started:** March 18, 2019

**First decision:** July 30, 2019

**Revised:** August 4, 2019

**Accepted:** August 20, 2019

**Article in press:** August 20, 2019

**Published online:** September 6, 2019

**P-Reviewer:** Exbrayat JM, Mehdi I

**S-Editor:** Dou Y

**L-Editor:** Wang TQ

**E-Editor:** Qi LL



**Core tip:** Organ-associated pseudosarcomatous myofibroblastic proliferation (PMP) in the urinary bladder has been reported. However, it rarely occurs in the kidney and no previous case of renal PMP with ossification have been reported. In this case report, the preoperative clinical diagnosis of renal pelvic carcinoma was made by imaging examination and biopsy. Retroperitoneoscopic radical nephroureterectomy was performed, and the final pathological diagnosis was organ-associated PMP with ossification. This case may help us to better understand this disease with regards to the related clinical manifestations, laboratory examination, imaging and pathologic results.

**Citation:** Zhai TY, Luo BJ, Jia ZK, Zhang ZG, Li X, Li H, Yang JJ. Organ-associated pseudosarcomatous myofibroblastic proliferation with ossification in the lower pole of the kidney mimicking renal pelvic carcinoma: A case report. *World J Clin Cases* 2019; 7(17): 2605-2610

**URL:** <https://www.wjnet.com/2307-8960/full/v7/i17/2605.htm>

**DOI:** <https://dx.doi.org/10.12998/wjcc.v7.i17.2605>

## INTRODUCTION

Organ-associated pseudosarcomatous myofibroblastic proliferation (PMP), also known as inflammatory myofibroblastic tumor, pseudomalignant spindle cell proliferation and inflammatory pseudotumor, was first reported by Roth *et al*<sup>[1]</sup> in 1980. In general, the organ-associated PMP is a rare type of benign spindle cell tumor. The most commonly reported diagnoses involve the urinary bladder. Other potential sites where PMPs may occur include the head, neck, abdomen, pelvic cavity, retroperitoneum, and limbs<sup>[2]</sup>. Cases involving the kidney have been reported rarely, and no previous cases of renal PMP with ossification have been reported<sup>[3]</sup>.

According to the 2016 World Health Organization classification of tumors of the urinary system and male genital organs, PMP is a benign mesenchymal bladder tumor with malignant potential derived from fibroblasts and myofibroblasts<sup>[4]</sup>. For the rare cases that have been reported in the kidney, either the renal parenchyma or the renal pelvis have been involved; furthermore, in these cases the tumor has presented in single, multiple or bilateral forms. Finally, the proportion of male-to-female patients in China is about 2:1, and the mean age is approximately 30 years old.

Herein, we report a rare case of PMP with ossification in the lower pole of the kidney, which mimicked urothelial carcinoma or an osteogenic tumor.

## CASE PRESENTATION

### Chief complaints

A 72-year-old man without prior contributory history presented with intermittent gross hematuria that had lasted for more than 1 mo. On the day before the hospital consultation, the symptoms had worsened remarkably and were accompanied by lower abdominal and back pain, which were relieved after urination.

### History of past illness

The patient's past history was unremarkable.

### Personal and family history

The patient's family history was unremarkable.

### Physical examination upon admission

The preoperative physical examination provided findings that were unremarkable.

### Laboratory examinations

Routine blood testing showed normal erythrocyte count ( $4.23 \times 10^{12}/L$ ; normal range:  $4.3-5.8 \times 10^{12}/L$ ) and hemoglobin level (138 g/L; normal range: 130-175 g/L). Routine urine test showed occult blood of 3+, substantially elevated erythrocyte count ( $2512/\mu L$ ; normal range: 0-7/ $\mu L$ ) and high end of normal leucocyte count ( $12/\mu L$ ; normal range: 0-12/ $\mu L$ ). Urine culture was positive for *Enterococcus faecalis*.

### Imaging examinations

Enhanced renal computed tomography (CT) showed a heterogeneous mass 6 cm in diameter at the left pyeloureteral junction, which indicated a benign lesion or hematoma (Figure 1A). Magnetic resonance imaging (MRI) showed that the left renal pelvis was occupied by a cystic and solid mass (approximately 6.0 cm × 4.5 cm × 4.5 cm in size) with calcification or ossification, which indicated a hamartoma or teratoma (Figure 1B). Emission CT showed that the left renal glomerular filtration rate was 15.4 mL/min and the right renal glomerular filtration rate was 58.9 mL/min (normal range: 80-120 mL/min).

## FINAL DIAGNOSIS

According to the pathological examination, the final diagnosis was renal organ-associated PMP with ossification.

## TREATMENT

In order to define the pathology of the lesion, a flexible ureteroscopic examination was performed and biopsy taken of the large mass (6 cm in diameter) in the left renal pelvis. Microscopic examination of the biopsy sample showed a highly proliferative area composed of spindle cells and irregular bone tissue. Heterotopic ossification was considered, and osteogenic tumor could not be excluded completely. To address the suspicion of renal pelvic carcinoma, a retroperitoneoscopic radical nephroureterectomy was performed.

The gross specimen presented as a gray-white and pink-grey mass with capsule, in the lower pole of the kidney (Figure 2A), with a negative surgical margin. Histopathologic features suggested it was an organ-associated PMP with ossification and chondrification of the left kidney (Figure 2B). Immunohistochemical staining showed positivity for calponin, SATB-2, and for Ki-67 (60%) (Figure 2C and 2D), and negativity for CK and P16.

## OUTCOME AND FOLLOW-UP

After a 6-mo follow-up, the patient did not complain of obvious discomfort and no signs of recurrence were found.

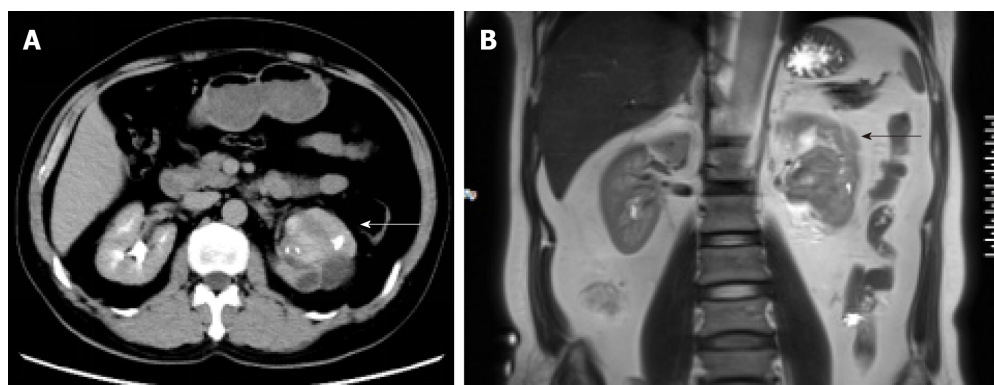
## DISCUSSION

The pathogenesis of PMP is unknown. In kidney, the tumor itself may represent a reactive hyperplasia related to chronic inflammation of the renal parenchyma. Many microorganisms, such as mycobacterium, corynebacterium, human herpes virus, Epstein-Barr virus and human papillomavirus, have been proposed as potential pathogenic factors<sup>[5-7]</sup>. In our case, the urine culture was positive for *Enterococcus faecalis*, supporting the possibility of such an association with chronic inflammation of the renal parenchyma.

Previous studies have indicated an association between PMP and expression of activin receptor-like kinase 1 and p80 expression or chromosomal rearrangements involving 2p23. It remains unknown, however, whether the tumor itself is reactive or neoplastic in nature. While renal clear cell carcinoma, chromophobe cell carcinoma and sarcoma with ossification have all been reported in the literature<sup>[8,9]</sup>, no previous case of renal PMP with ossification has been reported. The mechanism of ossification is thus similarly unclear. We conjecture that it may be related to the transformation of immature fibroblasts into osteoblasts or chondrocytes in the mesenchymal tissue, due to the repair of tissue damage.

The clinical manifestations of renal PMP lack specificity and are mainly comprised of lumbago, fever, hematuria and renal percussion pain. As such, diagnosis of renal PMP depends on imaging and histopathological examination. The tumors appear as a solid mass of low density or slightly high density on CT scans, with contrast-enhanced CT images showing a low degree of enhancement. In MRI, the masses usually show low signal intensity with heterogeneous or homogeneous enhancement on T1- and T2-weighted images<sup>[10,11]</sup>.

In our case, the CT showed a heterogeneous mass and MRI showed a cystic and solid mass with ossification in the left renal pelvis and upper ureter, which made it difficult to distinguish from renal pelvic carcinoma and osteogenic tumors. The



**Figure 1** Imaging examination of our case of renal organ-associated pseudosarcomatous myofibroblastic proliferation. A: Computed tomography showed a heterogeneous mass (indicated with arrows) of 6 cm in diameter at the left pyeloureteral junction; B: Magnetic resonance imaging showed that the left renal pelvis was occupied by a cystic and solid mass (indicated with arrows) with calcification or ossification.

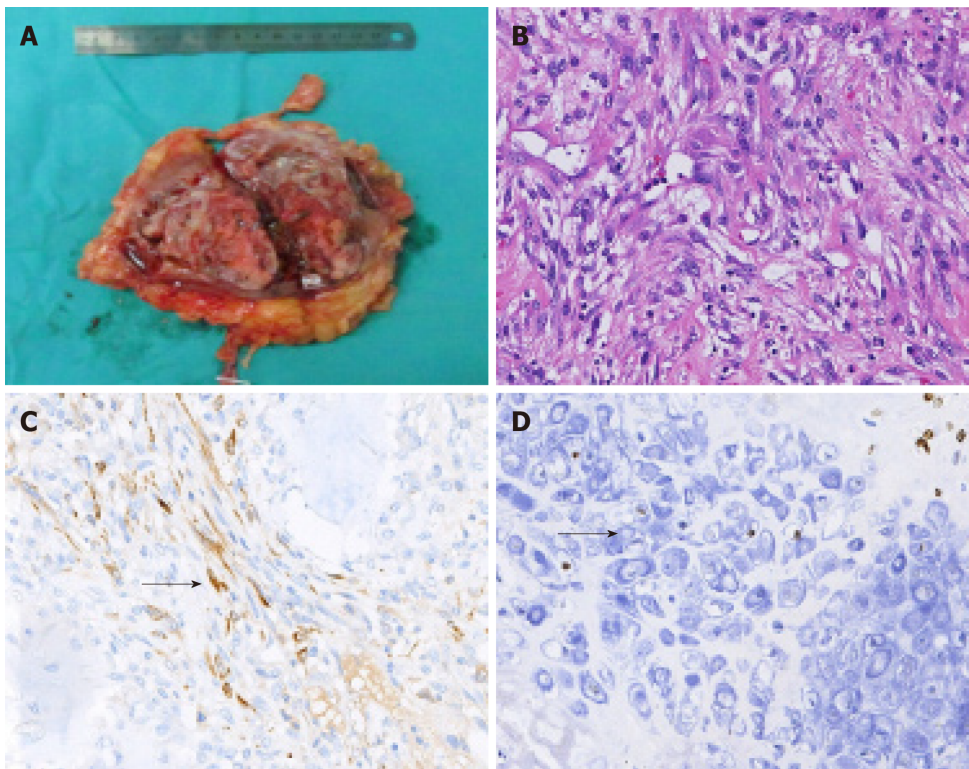
differential diagnosis of renal PMP includes renal cell carcinoma, renal sarcoma, teratoma, and renal pelvic carcinoma. However, renal PMPs are characterized by obscure edges, whereas the margins of renal cell carcinoma are clear. The CT-enhanced scans of our patient showed a gradual, slight enhancement in the renal PMP, different from the typical flow-type enhancement of renal cell carcinoma.

It was difficult to establish the diagnosis preoperatively. As such, the final diagnosis was dependent on findings from histopathologic and immunohistochemical examinations of the biopsied tissue. Microscopically, PMP lesions are mainly composed of proliferative fusiform myofibroblasts and inflammatory cells, lacking severe cytologic atypia and containing fewer mitoses than sarcomas<sup>[3]</sup>. Expression of p53 has been proposed as a marker to differentiate PMPs (usually negative on immunostain) from sarcomas (usually positive)<sup>[12]</sup>. In our case, the biopsied mass showed negativity for CK5/6, p53 and p16, along with positivity for calponin, smooth muscle actin and other smooth muscle-derived markers.

At present, there is no standard treatment regimen for renal PMP. Broad-spectrum antibiotics are recommended, accompanied by symptomatic treatment and traditional Chinese medicine. If conservative treatment is ineffective, simple tumor resection or partial nephrectomy would be feasible. It was recently reported that Myofibroblastic tumour patients had promising results with crizotinib treatment, so tyrosine kinase inhibitors (TKIs) can be used as an alternative to conservative treatment<sup>[13,14]</sup>. For tumors that are difficult to completely resect, TKIs can be also used as neoadjuvant therapy. However, since in most cases the prognosis of renal PMPs is good, TKIs adjuvant therapy after operation is not recommended routinely. According to our experience, It is recommended that CT examination be performed 3-mo or 6-mo in the first two years after operation, if nothing special found in the CT result, the re-examination time may extend to every 6-mo or 1 year afterwards. For patients undergoing partial nephrectomy, CT examination is also recommended 1-mo after operation. Most patients have a satisfactory prognosis, and for our case, the patient did not complain of any obvious discomfort at the 6-mo follow-up and no signs of recurrence were found.

## CONCLUSION

Renal organ-associated PMP is a rare lesion that may mimic renal pelvic carcinoma, clinically and radiologically. Diagnosis of renal PMP depends on imaging and histopathological examination. Conservative treatment is recommended, and a satisfactory prognosis can be achieved.



**Figure 2** Gross specimen and histological examination of our case of renal organ-associated pseudosarcomatous myofibroblastic proliferation with ossification. A: Longitudinal section of our patient's kidney showing a gray-white and pink-grey mass, with capsule in the lower pole of the kidney; B: Microscopic view of the renal organ-associated pseudosarcomatous myofibroblastic proliferation staining with hematoxylin eosin (original magnification  $\times 200$ ). The lesions were found to be composed mainly of proliferative fusiform myofibroblasts and inflammatory cells; C, D: Immunohistochemical staining showed positivity for calponin (C) and SATB-2 (D) (Arrows indicate positive cells).

## REFERENCES

- 1 Roth JA. Reactive pseudosarcomatous response in urinary bladder. *Urology* 1980; **16**: 635-637 [PMID: 7445316 DOI: 10.1016/0090-4295(80)90578-6]
- 2 Coffin CM, Watterson J, Priest JR, Dehner LP. Extrapulmonary inflammatory myofibroblastic tumor (inflammatory pseudotumor). A clinicopathologic and immunohistochemical study of 84 cases. *Am J Surg Pathol* 1995; **19**: 859-872 [PMID: 7611533 DOI: 10.1097/00000478-199508000-00001]
- 3 Leroy X, Copin MC, Graziana JP, Wacrenier A, Gosselin B. Inflammatory pseudotumor of the renal pelvis. A report of 2 cases with clinicopathologic and immunohistochemical study. *Arch Pathol Lab Med* 2000; **124**: 1209-1212 [PMID: 10923085 DOI: 10.1043/0003-9985(2000)124<1209:IPOTRP>2.0.CO;2]
- 4 Moch H, Cubilla AL, Humphrey PA, Reuter VE, Ulbright TM. The 2016 WHO Classification of Tumours of the Urinary System and Male Genital Organs-Part A: Renal, Penile, and Testicular Tumours. *Eur Urol* 2016; **70**: 93-105 [PMID: 26935559 DOI: 10.1016/j.eururo.2016.02.029]
- 5 Montgomery EA, Shuster DD, Burkart AL, Esteban JM, Sgrignoli A, Elwood L, Vaughn DJ, Griffin CA, Epstein JI. Inflammatory myofibroblastic tumors of the urinary tract: a clinicopathologic study of 46 cases, including a malignant example inflammatory fibrosarcoma and a subset associated with high-grade urothelial carcinoma. *Am J Surg Pathol* 2006; **30**: 1502-1512 [PMID: 17122505 DOI: 10.1097/01.pas.0000213280.35413.1b]
- 6 Dobrosz Z, Ryś J, Paleń P, Własczek P, Ciepiela M. Inflammatory myofibroblastic tumor of the bladder - an unexpected case coexisting with an ovarian teratoma. *Diagn Pathol* 2014; **9**: 138 [PMID: 25027562 DOI: 10.1186/1746-1596-9-138]
- 7 Selves J, Meggetto F, Brousset P, Voigt JJ, Pradère B, Grasset D, Icart J, Mariamé B, Knecht H, Delsol G. Inflammatory pseudotumor of the liver. Evidence for follicular dendritic reticulum cell proliferation associated with clonal Epstein-Barr virus. *Am J Surg Pathol* 1996; **20**: 747-753 [PMID: 8651355 DOI: 10.1097/00000478-199606000-00013]
- 8 Hartman RJ, Helfand BT, Dalton DP. Clear cell renal cell carcinoma with osseous metaplasia: a case report. *Can J Urol* 2011; **18**: 5564-5567 [PMID: 21333055]
- 9 Kaneko T, Suzuki Y, Takata R, Takata K, Sakuma T, Fujioka T. Extraskeletal mesenchymal chondrosarcoma of the kidney. *Int J Urol* 2006; **13**: 285-286 [PMID: 16643625 DOI: 10.1111/j.1442-2042.2006.01293.x]
- 10 Park SB, Cho KS, Kim JK, Lee JH, Jeong AK, Kwon WJ, Kim HH. Inflammatory pseudotumor (myoblastic tumor) of the genitourinary tract. *AJR Am J Roentgenol* 2008; **191**: 1255-1262 [PMID: 18806173 DOI: 10.2214/AJR.07.3663]
- 11 Patnana M, Sevrakov AB, Elsayes KM, Viswanathan C, Lubner M, Menias CO. Inflammatory pseudotumor: the great mimicker. *AJR Am J Roentgenol* 2012; **198**: W217-W227 [PMID: 22358018 DOI: 10.2214/AJR.11.7288]
- 12 Ledet SC, Brown RW, Cagle PT. p53 immunostaining in the differentiation of inflammatory pseudotumor from sarcoma involving the lung. *Mod Pathol* 1995; **8**: 282-286 [PMID: 7617655]

- 13 **Felkai L**, Bánusz R, Kovalszky I, Sápi Z, Garami M, Papp G, Karászi K, Varga E, Csóka M. The Presence of ALK Alterations and Clinical Relevance of Crizotinib Treatment in Pediatric Solid Tumors. *Pathol Oncol Res* 2019; **25**: 217-224 [PMID: [29081033](#) DOI: [10.1007/s12253-017-0332-1](#)]
- 14 **Kiratli H**, Uzun S, Varan A, Akyüz C, Orhan D. Management of anaplastic lymphoma kinase positive orbito-conjunctival inflammatory myofibroblastic tumor with crizotinib. *J AAPOS* 2016; **20**: 260-263 [PMID: [27312965](#) DOI: [10.1016/j.jaapos.2016.01.009](#)]



Published By Baishideng Publishing Group Inc  
7041 Koll Center Parkway, Suite 160, Pleasanton, CA 94566, USA  
Telephone: +1-925-2238242  
Fax: +1-925-2238243  
E-mail: [bpgoffice@wjgnet.com](mailto:bpgoffice@wjgnet.com)  
Help Desk: <https://www.f6publishing.com/helpdesk>  
<https://www.wjgnet.com>

