

World Journal of *Clinical Cases*

World J Clin Cases 2019 September 26; 7(18): 2658-2915



**OPINION REVIEW**

- 2658** Effective use of the Japan Narrow Band Imaging Expert Team classification based on diagnostic performance and confidence level
Hirata D, Kashida H, Iwatate M, Tochio T, Teramoto A, Sano Y, Kudo M

MINIREVIEWS

- 2666** Low fermentable oligosaccharides, disaccharides, monosaccharides, and polyols diet in children
Fodor I, Man SC, Dumitrascu DL
- 2675** High-resolution colonic manometry and its clinical application in patients with colonic dysmotility: A review
Li YW, Yu YJ, Fei F, Zheng MY, Zhang SW

ORIGINAL ARTICLE**Retrospective Study**

- 2687** Predictors of rebleeding and in-hospital mortality in patients with nonvariceal upper digestive bleeding
Lazăr DC, Ursoniu S, Goldiș A
- 2704** Analgesic effect of parecoxib combined with ropivacaine in patients undergoing laparoscopic hepatectomy
Huang SS, Lv WW, Liu YF, Yang SZ
- 2712** Prognostic significance of 14v-lymph node dissection to D2 dissection for lower-third gastric cancer
Zheng C, Gao ZM, Sun AQ, Huang HB, Wang ZN, Li K, Gao S

Observational Study

- 2722** Wall shear stress can improve prediction accuracy for transient ischemic attack
Liu QY, Duan Q, Fu XH, Jiang M, Xia HW, Wan YL

Prospective Study

- 2734** Characterization of microbiota in systemic-onset juvenile idiopathic arthritis with different disease severities
Dong YQ, Wang W, Li J, Ma MS, Zhong LQ, Wei QJ, Song HM

SYSTEMATIC REVIEWS

- 2746** Sinusoidal obstruction syndrome: A systematic review of etiologies, clinical symptoms, and magnetic resonance imaging features
Zhang Y, Jiang HY, Wei Y, Song B

META-ANALYSIS

- 2760** Respiratory training interventions improve health status of heart failure patients: A systematic review and network meta-analysis of randomized controlled trials
Wang MH, Yeh ML

CASE REPORT

- 2776** *Mycobacterium chimaera* infections following cardiac surgery in Treviso Hospital, Italy, from 2016 to 2019: Cases report
Inojosa WO, Giobbia M, Muffato G, Minniti G, Baldasso F, Carniato A, Farina F, Forner G, Rossi MC, Formentini S, Rigoli R, Scotton PG
- 2787** Giant squamous cell carcinoma of the gallbladder: A case report
Junior MAR, Favaro MDL, Santin S, Silva CM, Iamarino APM
- 2794** Liver re-transplantation for donor-derived neuroendocrine tumor: A case report
Mrzljak A, Kocman B, Skrtic A, Furac I, Popic J, Franusic L, Zunec R, Mayer D, Mikulic D
- 2802** Calcifying fibrous tumor originating from the gastrohepatic ligament that mimicked a gastric submucosal tumor: A case report
Kwan BS, Cho DH
- 2808** Pancreatitis, panniculitis, and polyarthritides syndrome caused by pancreatic pseudocyst: A case report
Jo S, Song S
- 2815** Glomus tumor of uncertain malignant potential of the brachial plexus: A case report
Thanindrarn P, Chobpenthai T, Phorkhar T, Nelson SD
- 2823** Conservative pulp treatment for Oehlers type III dens invaginatus: A case report
Lee HN, Chen YK, Chen CH, Huang CY, Su YH, Huang YW, Chuang FH
- 2831** Propofol pump controls nonconvulsive status epilepticus in a hepatic encephalopathy patient: A case report
Hor S, Chen CY, Tsai ST
- 2838** Teriparatide as nonoperative treatment for femoral shaft atrophic nonunion: A case report
Tsai MH, Hu CC
- 2843** Successful repair of acute type A aortic dissection during pregnancy at 16th gestational week with maternal and fetal survival: A case report and review of the literature
Chen SW, Zhong YL, Ge YP, Qiao ZY, Li CN, Zhu JM, Sun LZ
- 2851** Inferior pancreaticoduodenal artery pseudoaneurysm in a patient with calculous cholecystitis: A case report
Xu QD, Gu SG, Liang JH, Zheng SD, Lin ZH, Zhang PD, Yan J

- 2857** ALK-positive anaplastic large cell lymphoma of the thoracic spine occurring in pregnancy: A case report
Yang S, Jiang WM, Yang HL
- 2871** Multiple gastric adenocarcinoma of fundic gland type: A case report
Chen O, Shao ZY, Qiu X, Zhang GP
- 2879** Repair of the portal vein using a hepatic ligamentum teres patch for laparoscopic pancreaticoduodenectomy: A case report
Wei Q, Chen QP, Guan QH, Zhu WT
- 2899** Pleomorphic lipoma in the anterior mediastinum: A case report
Mao YQ, Liu XY, Han Y
- 2905** Guillain-Barré syndrome in a patient with multiple myeloma after bortezomib therapy: A case report
Xu YL, Zhao WH, Tang ZY, Li ZQ, Long Y, Cheng P, Luo J
- 2910** Bowen's disease on the palm: A case report
Yu SR, Zhang JZ, Pu XM, Kang XJ

ABOUT COVER

Editorial Board Member of *World Journal of Clinical Cases*, Shao-Ping Yu, MD, Associate Professor, Chief Doctor, Department of Gastroenterology and Hepatology, Dongguan Kanghua Hospital, Dongguan 523080, Guangdong Province, China

AIMS AND SCOPE

The primary aim of *World Journal of Clinical Cases* (*WJCC*, *World J Clin Cases*) is to provide scholars and readers from various fields of clinical medicine with a platform to publish high-quality clinical research articles and communicate their research findings online.

WJCC mainly publishes case reports, case series, and articles reporting research results and findings obtained in the field of clinical medicine and covering a wide range of topics including diagnostic, therapeutic, and preventive modalities.

INDEXING/ABSTRACTING

The *WJCC* is now indexed in PubMed, PubMed Central, Science Citation Index Expanded (also known as SciSearch®), and Journal Citation Reports/Science Edition. The 2019 Edition of Journal Citation Reports cites the 2018 impact factor for *WJCC* as 1.153 (5-year impact factor: N/A), ranking *WJCC* as 99 among 160 journals in Medicine, General and Internal (quartile in category Q3).

RESPONSIBLE EDITORS FOR THIS ISSUE

Responsible Electronic Editor: Ji-Hong Liu

Proofing Production Department Director: Yun-Xiaoqian Wu

NAME OF JOURNAL

World Journal of Clinical Cases

ISSN

ISSN 2307-8960 (online)

LAUNCH DATE

April 16, 2013

FREQUENCY

Semimonthly

EDITORS-IN-CHIEF

Dennis A Bloomfield, Bao-Gan Peng, Sandro Vento

EDITORIAL BOARD MEMBERS

<https://www.wjgnet.com/2307-8960/editorialboard.htm>

EDITORIAL OFFICE

Jin-Lei Wang, Director

PUBLICATION DATE

September 26, 2019

COPYRIGHT

© 2019 Baishideng Publishing Group Inc

INSTRUCTIONS TO AUTHORS

<https://www.wjgnet.com/bpg/gerinfo/204>

GUIDELINES FOR ETHICS DOCUMENTS

<https://www.wjgnet.com/bpg/GerInfo/287>

GUIDELINES FOR NON-NATIVE SPEAKERS OF ENGLISH

<https://www.wjgnet.com/bpg/gerinfo/240>

PUBLICATION MISCONDUCT

<https://www.wjgnet.com/bpg/gerinfo/208>

ARTICLE PROCESSING CHARGE

<https://www.wjgnet.com/bpg/gerinfo/242>

STEPS FOR SUBMITTING MANUSCRIPTS

<https://www.wjgnet.com/bpg/GerInfo/239>

ONLINE SUBMISSION

<https://www.f6publishing.com>

Successful repair of acute type A aortic dissection during pregnancy at 16th gestational week with maternal and fetal survival: A case report and review of the literature

Su-Wei Chen, Yong-Liang Zhong, Yi-Peng Ge, Zhi-Yu Qiao, Cheng-Nan Li, Jun-Ming Zhu, Li-Zhong Sun

ORCID number: Su-Wei Chen (0000-0003-2549-103X); Yong-Liang Zhong (0000-0001-7110-8439); Yi-Peng Ge (0000-0003-2822-7111); Zhi-Yu Qiao (0000-0003-3512-8031); Cheng-Nan Li (0000-0002-2655-7873); Jun-Ming Zhu (0000-0002-6919-9164); Li-Zhong Sun (0000-0001-9750-5854).

Author contributions: Chen SW, Zhong YL, Ge YP, Qiao ZY, and Li CN reviewed the literature; Chen SW drafted the manuscript; Zhu JM and Sun LZ were responsible for revising the manuscript for important intellectual content; and all of the authors approved the final version to be published.

Supported by Beijing Major Science and Technology Projects from Beijing Municipal Science and Technology Commission, No. Z171100001017083; National Science and Technology Support Program of China, No. 2015BAI12B03; Beijing Lab for Cardiovascular Precision Medicine, No. PXM2017_014226_000037.

Informed consent statement: Written informed consent was obtained from the patient for publication of this report and any accompanying images.

Conflict-of-interest statement: The authors declare that they have no conflicts of interest.

CARE Checklist (2016) statement: The authors have read the CARE Checklist (2016), and the manuscript was prepared and revised according to the CARE

Su-Wei Chen, Yong-Liang Zhong, Yi-Peng Ge, Zhi-Yu Qiao, Cheng-Nan Li, Jun-Ming Zhu, Li-Zhong Sun, Department of Cardiovascular Surgery, Beijing Anzhen Hospital, Capital Medical University, Beijing 100029, China

Su-Wei Chen, Yong-Liang Zhong, Yi-Peng Ge, Zhi-Yu Qiao, Cheng-Nan Li, Jun-Ming Zhu, Li-Zhong Sun, Beijing Aortic Disease Center, Beijing Anzhen Hospital, Capital Medical University, Beijing 100029, China

Su-Wei Chen, Yong-Liang Zhong, Yi-Peng Ge, Zhi-Yu Qiao, Cheng-Nan Li, Jun-Ming Zhu, Li-Zhong Sun, Beijing Institute of Heart, Lung, and Blood Vessel Diseases, Beijing Anzhen Hospital, Capital Medical University, Beijing 100029, China

Su-Wei Chen, Yong-Liang Zhong, Yi-Peng Ge, Zhi-Yu Qiao, Cheng-Nan Li, Jun-Ming Zhu, Li-Zhong Sun, Beijing Engineering Research Center of Vascular Prostheses, Beijing Anzhen Hospital, Capital Medical University, Beijing 100029, China

Corresponding author: Jun-Ming Zhu, MD, Chairman, Chief Doctor, Director, Professor, Surgeon, Professor and Doctoral Supervisor of Cardiac Surgery, Department of Cardiovascular Surgery, Beijing Anzhen Hospital, 2 Anzhen Road, Chaoyang District, Beijing 100029, China. anzhenzm@126.com

Telephone: +86-10-64456588

Fax: +86-10-64456588

Abstract

BACKGROUND

Aortic dissection during pregnancy is a rare but life-threatening event for mothers and fetuses. It often occurs in the third trimester of pregnancy and the postpartum period. Most patients have connective tissue diseases such as Marfan syndrome. Thus, the successful repair of a sporadic aortic dissection with maternal and fetal survival in the early second trimester is extremely rare.

CASE SUMMARY

A 28-year-old woman without Marfan syndrome presented with chest pain at the 16th gestational week. Aortic computed tomographic angiography confirmed an acute type A aortic dissection (TAAD) with aortic arch and descending aorta involvement. Preoperative fetal ultrasound confirmed that the fetus was stable in the uterus. The patient underwent total arch replacement with a frozen elephant trunk using moderate hypothermic circulatory arrest with the fetus *in situ*. The patient recovered uneventfully and continued to be pregnant after discharge. At

Checklist (2016).

Open-Access: This article is an open-access article which was selected by an in-house editor and fully peer-reviewed by external reviewers. It is distributed in accordance with the Creative Commons Attribution Non Commercial (CC BY-NC 4.0) license, which permits others to distribute, remix, adapt, build upon this work non-commercially, and license their derivative works on different terms, provided the original work is properly cited and the use is non-commercial. See: <http://creativecommons.org/licenses/by-nc/4.0/>

Manuscript source: Unsolicited manuscript

Received: March 22, 2019

Peer-review started: March 22, 2019

First decision: July 30, 2019

Revised: August 21, 2019

Accepted: August 25, 2019

Article in press: August 26, 2019

Published online: September 26, 2019

P-Reviewer: Yellanthoor RB, Ajmal M, Altarabsheh SE

S-Editor: Dou Y

L-Editor: Wang TQ

E-Editor: Zhou BX



the 38th gestational week, she delivered a healthy female infant by cesarean section. After 2.5 years of follow-up, the patient is uneventful and the child's development is normal.

CONCLUSION

A fetus in the second trimester may have a high possibility of survival and healthy growth after aortic arch surgery.

Key words: Aortic dissection; Pregnancy; Cardiopulmonary bypass; Hypothermia circulatory arrest; Case report

©The Author(s) 2019. Published by Baishideng Publishing Group Inc. All rights reserved.

Core tip: Aortic dissection during pregnancy is a rare but life-threatening event for mothers and fetuses. The successful repair of a sporadic aortic dissection with maternal and fetal survival in the early second trimester is exceedingly rare. This case highlights that a fetus in the second trimester may have a high possibility of survival and healthy growth after aortic arch surgery using hypothermic circulatory arrest.

Citation: Chen SW, Zhong YL, Ge YP, Qiao ZY, Li CN, Zhu JM, Sun LZ. Successful repair of acute type A aortic dissection during pregnancy at 16th gestational week with maternal and fetal survival: A case report and review of the literature. *World J Clin Cases* 2019; 7(18): 2843-2850

URL: <https://www.wjnet.com/2307-8960/full/v7/i18/2843.htm>

DOI: <https://dx.doi.org/10.12998/wjcc.v7.i18.2843>

INTRODUCTION

Type A aortic dissection (TAAD) is a disease with a high mortality rate that increases 1% to 2% per hour after the onset of symptoms in untreated patients. Moreover, acute aortic dissection during pregnancy is a rare and catastrophic disease that leads to extreme lethality of mothers and babies. The significant maternal and fetal mortality is as high as 30% and 50%, respectively^[1]. Here, we present a case of TAAD who underwent moderate hypothermic circulatory arrest (MHCA) aortic surgery at the 16th gestational week.

CASE PRESENTATION

Chief complaints

A 28-year-old pregnant woman (G4P2) at the 16th gestational week was admitted to our emergency room, who complained of severe chest and back pain for 24 h.

History of present illness

The patient had severe, tearing chest pain that radiated to the back. The pain was continuous and could not be alleviated for 24 h. There were no adverse accompanying symptoms.

History of past illness

The patient had a history of miscarriage.

History of family illness

The patient had no family history.

Physical examination

The patient was 160 cm tall and weighed 58 kg (body mass index = 22.7). The patient's temperature was 36.6 °C, heart rate was 78 bp/min, blood pressure was 130/70 mmHg, respiratory rate was 18 breaths/min, and oxygen saturation in room air was 98%. There were no murmurs from the cardiac auscultation. The pulses of both upper extremity arteries and dorsal arteries were equal. The bowel sounds were normal.

Laboratory examinations

On admission, blood analysis revealed mild leukocytosis of $13 \times 10^9/\text{L}$ with predominant neutrophils (94.9%). D-dimer and serum C-reactive protein levels increased to 8974 $\mu\text{g}/\text{mL}$ and 35.5 mg/dL , respectively. In addition, hematocrit, platelet count, blood biochemistry, prothrombin, partial thromboplastin time as well as creatinine levels were normal.

Imaging examinations

Aortic computed tomographic angiography (CTA) revealed an acute TAAD with the initial tear located at the ascending aorta (Figure 1). The aortic dissection involved the aortic arch and its branches and extended to the iliac arteries. The bloodstream of vital abdominal organs, including the celiac trunk, the mesenteric arteries, and the renal arteries, came from the true lumen. The diameter of the descending aorta was normal. Transthoracic echocardiography (TTE) showed mild regurgitation of the aortic valve without pericardial effusion. The inner diameters of the ascending aorta and the aortic sinuses were 37 mm and 31 mm, respectively. Fetal ultrasound confirmed that the fetus was stable without distress.

FINAL DIAGNOSIS

The patient was diagnosed with TAAD at the 16th gestational week. Fetal development was normal without intrauterine distress.

TREATMENT

An emergency Sun's procedure was performed with the fetus *in situ*. Our surgical technique was previously described in detail^[2,3]. In brief, a median sternotomy was performed under MHCA with selective antegrade cerebral perfusion (SACP). The right axillary artery (RAA) cannulation was used for cardiopulmonary bypass (CPB) and SACP. The right femoral artery (RFA) cannulation was also utilized to increase the blood flow of the uterus. The distal ascending aorta was cross-clamped and the heart was arrested with perfusion of cold blood cardioplegia. The ascending aorta was replaced during the cooling phase. When the nasopharyngeal temperature reached 25 °C, the supra-arch vessels were cross-clamped and SACP was started (5-10 $\text{mL}/\text{kg}/\text{min}$). A stent elephant trunk (SET) (Cronus®, MicroPort Medical, Shanghai, China) was inserted into the true lumen of the descending aorta, and an anastomosis between the distal end of the four-branched prosthetic graft and the distal aorta incorporating the SET was performed. Therewith, the blood perfusion of the lower body was started *via* the limb of the prosthetic graft and RFA. Then, CPB was gradually resumed to normal flow and rewarming started. During the rewarming phase, the left common carotid artery, left subclavian artery, and innominate artery were reconstructed sequentially. The times of CPB, aortic cross-clamp, and SACP were 152 min, 66 min, and 17 min, respectively. During the surgery, the patient's blood pressure was monitored *via* the radial artery and dorsal pedal artery. We also monitored the fetus using ultrasound and electronic fetal monitoring. No fetal distress was observed during the procedure (Figure 2).

OUTCOMES AND FOLLOW-UP

The times of mechanical ventilation and ICU stay were 12 h and 43 h, respectively. The patient received oral administration of Betaloc and Procardin to control heart rate and blood pressure after surgery. The postoperative course was uneventful, and she was discharged at 7 d postoperatively and continued the pregnancy. The aortic graft was patent and no anastomotic leakage was detected on discharge CTA (Figure 3). The patient underwent periodic prenatal examination and TTE between gestation week 16 and week 38. No obvious abnormality was found in the mother and the fetus. At the 38th gestational week, the patient delivered a healthy female infant by cesarean section. The Apgar score of the newborn was 10/10/10. The follow-up of the patient and newborn was satisfactory. The baby had no neurological or physiological abnormalities. Moreover, the patient and the baby did not receive any further intervention.

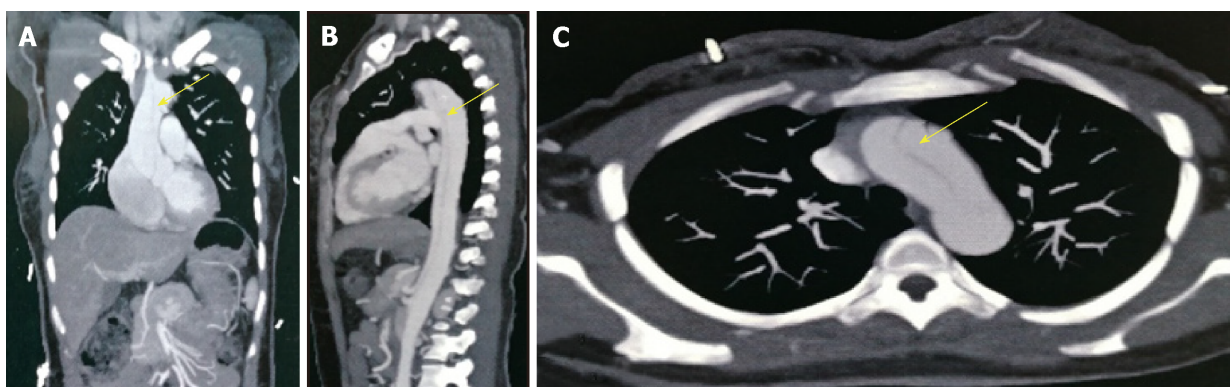


Figure 1 Preoperative imaging diagnosis. A: The aortic dissection involved the ascending aorta (yellow arrow); B: The aortic dissection involved the descending thoracic aorta, which extended to the iliac arteries (yellow arrow); C: The aortic dissection involved the aortic arch (yellow arrow).

DISCUSSION

The most common phases for aortic dissection in pregnancy often occur in the third trimester and early postpartum period^[4,5]. The incidence of aortic dissection in pregnant women is 7-fold higher than in non-pregnant people^[6]. TAAD is usually associated with a high maternal risk and even higher fetal risk of death^[7,8]. Thus, the correct options and management strategies are especially important for mothers and fetuses.

To meet the needs of fetal growth and development, the blood volume of pregnant women begins to increase at the 6th gestational week, peaks during the 32nd to 34th gestational weeks, and maintains at a high level until the postpartum period. Moreover, the signaling pathways also change during pregnancy^[9]. Thus, pregnancy itself without any other complications is associated with a high risk of aortic dissection^[10]. Moreover, a history of hypertension, aortitis, surgical manipulation, cardiac catheterization, cocaine exposure, and young age are also risk factors^[1,9,11]. In the present case, the patient was at a young age but had no related history of illness. Therefore, the cause of aortic dissection may be related to young age and the pregnancy itself.

Although pregnant women should not be exposed to radiation, CTA can not only acquire sufficient information but can also be performed in a short period of time and can reconstruct the aorta in three dimensions, which may assist in surgical planning. The current guidelines suggested that low doses of radiation during CTA was acceptable in the diagnosis of aortic diseases in pregnancy^[12]. Barrus *et al*^[13] also suggested that CTA should be the primary diagnostic tool, and TTE should be a supplementary diagnostic method.

Immer-Bansi *et al*^[14] reported a patient in which misinterpretation of the intraoperative cardiotocography led to an emergency caesarean section. Moreover, Barrus *et al*^[13] reported a patient with aortic dissection who underwent repair surgery without effective monitoring for the fetus. Although the above studies consider medically futile of the intraoperative fetal monitoring, we believe that it can provide useful feedback for managing CPB and make a comprehensive assessment of the fetus during and after surgery.

CPB induces a systemic inflammatory response^[15] that increases the risk of maternal and fetal deaths, which are approximately 3% and 20%, respectively^[16,17]. The literature considered that the processes of cooling and rewarming both decreased blood flow to the uterus and placenta and increased contractions that prompt fetal bradycardia and intrauterine hypoxia^[11,16,18]. The blood flow to the uterus cannot adjust by itself and mainly relies on mean arterial pressure and vascular resistance. Moreover, the hypothermic circulatory arrest (HCA) may also lead to fetal brain atrophy and death^[19,20]. However, HCA is still inevitable for TAAD involving the aortic arch. In this case, in order to reduce the risk of adverse events, we used moderate hypothermia and maintained a high flow rate ($> 2.4 \text{ L/m}^2/\text{min}$) with mean arterial pressure $> 70 \text{ mm}$ during CPB. For myocardial protection, we chose cold blood cardioplegia rather than cold crystal cardioplegia^[21]. Meanwhile, both RAA and RFA cannulations were used to maintain a stable and approximate physiological blood flow to the upper and lower body. In addition, SACP not only provided

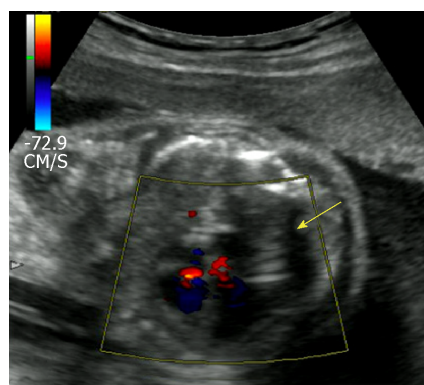


Figure 2 Postoperative ultrasound of the fetus. The normal heart blood flow of the fetal is shown (yellow arrow).

effective cerebral protection for mothers but also had no influence on placental perfusion^[11].

The timing of aortic surgery should be based on the types of dissection, the conditions of the fetus, and gestational age^[21]. Currently, although different experts had different perspectives on specific gestational weeks to perform aortic surgery and cesarean section, many studies suggested that the optimal timing for cesarean section followed by aortic repair was after reaching fetal maturity^[1,22-24], in which the fetal organogenesis was basically complete, and the fetus could survive outside the womb. The probability of independent fetal survival was low before 23 gestational weeks^[11]. Therefore, when aortic dissection occurs before fetal maturity, an urgent aortic repair with aggressive fetal monitoring is preferred. However, the risk of fetal developmental anomalies during the first trimester is significantly increased after aortic arch surgery. The probability of fetal survival and normal growth may not be high. Thus, the main controversy is whether fetuses in the second trimester can survive aortic surgery using HCA and eventually have full-term delivery healthily.

According to the gestational age and HCA surgery, we summarize the cases with TAAD who underwent aortic arch surgery in the literature^[7,13,17,19,25-33] (Table 1). In these 13 patients, all mothers survived. Only one fetus died and one fetus had neurological abnormalities. Moreover, half of the patients were in the second trimester. In spite of fetal death and postnatal neurological abnormalities, the results showed that most fetuses survived and brought up healthily. Thus, if the immature fetuses can survive after HCA surgery in the second trimester, they may have a high possibility of full-term delivery and healthy growth.

In addition to surgery, some drugs can also affect the outcomes. Vasoconstrictors should be avoided for pregnant patients during the perioperative period^[29], because it will increase contractions, resulting in fetal hypoxia. Although beta-blockers are thought to reduce aortic dilatation and aortic growth^[34], the evidence is still insufficient and controversial^[35]. The common side effects are fetal bradycardia and growth restriction^[36]. Besides, Warfarin is considered teratogenic as well^[1]. In the present case, the aortic valve was preserved, thus the effects of Warfarin were avoided. In addition, although the patient was treated with a beta-blocker and calcium channel blocker, fetal development was not affected. Generally, the fetuses should be closely monitored to avoid adverse outcomes if mothers are treated with the above drugs.

Postpartum hemorrhage is an important cause of maternal death. To prevent uterine bleeding, Yang *et al* suggested that a hysterectomy should be actively performed after cesarean section^[37]. However, in our present case, the insertion of a Cook balloon was safe and effective in reducing secondary damage^[21].

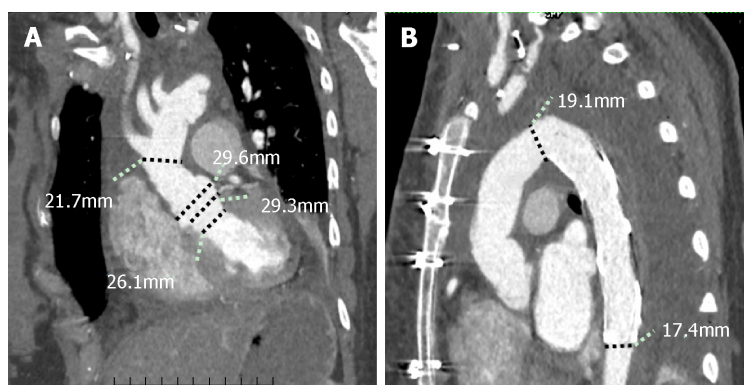
CONCLUSION

If fetuses can survive after HCA surgery in the second trimester, they may have a high possibility of full-term delivery and healthy growth.

Table 1 Outcomes of 13 pregnant women with type A aortic dissection treated by aortic repair surgery using hypothermic circulatory arrest in the literature

No.	Author	Age (Yr)	GWs	HCA (°C)	HCA (min)	CPB (min)	MBFR	MPP	SCP	Fetus	Mother
1	Buffolo <i>et al</i> ^[25]	28	21	19	37	120	2.4	60	—	S/N	Alive
2	Shaker <i>et al</i> ^[29]	34	35	18	11	—	—	—	ACP	S/N	Alive
3	Sakaguchi <i>et al</i> ^[17]	33	26	20	80	367	—	—	—	Died	Alive
4	Ham <i>et al</i> ^[27]	43	37	11	37	—	—	—	ACP	S/N	Alive
5	Barrus <i>et al</i> ^[13]	31	21	18	25	228	>4.5	70	RCP	S/N	Alive
6	Seeburger <i>et al</i> ^[26]	27	17	22	20	244	—	—	—	S/N	Alive
7	Marumoto <i>et al</i> ^[28]	28	33	23	37	137	—	—	—	S/N	Alive
8	Kunishige <i>et al</i> ^[7]	32	16	22.8	46	302	> 4.5	80	—	S/N	Alive
9	Easo <i>et al</i> ^[30]	28	24	28	21	—	—	—	ACP	S/N	Alive
10	Dong <i>et al</i> ^[31]	27	29	24.6	21	198	—	—	—	S/N	Alive
11	Nonga <i>et al</i> ^[32]	29	29	—	56	253	—	—	—	S/N	Alive
12	Shihata <i>et al</i> ^[33]	36	35	—	—	260	—	—	ACP	S/N	Alive
13	Mul <i>et al</i> ^[19]	32	29	28	5	—	>5.5	>70	—	S/A	Alive

HCA: Hypothermic circulatory arrest; GWs: Gestational weeks; MBFR: Mean bypass flow rate (L/min/m); MPP: Mean perfusion pressure (mmHg); SCP: Selective cerebral perfusion; S/N: Survival and normal; S/A: Survival and abnormal. The bar indicates no inference.

**Figure 3** Postoperative images of the patient. A and B: The good continuity of the prosthetic graft without thrombus.

REFERENCES

- Immer FF, Bansi AG, Immer-Bansi AS, McDougall J, Zehr KJ, Schaff HV, Carrel TP. Aortic dissection in pregnancy: analysis of risk factors and outcome. *Ann Thorac Surg* 2003; **76**: 309-314 [PMID: 12842575 DOI: 10.1016/s0003-4975(03)00169-3]
- Ma WG, Zhu JM, Zheng J, Liu YM, Ziganshin BA, Elefteriades JA, Sun LZ. Sun's procedure for complex aortic arch repair: total arch replacement using a tetrafurcate graft with stented elephant trunk implantation. *Ann Cardiothorac Surg* 2013; **2**: 642-648 [PMID: 24109575 DOI: 10.3978/j.issn.2225-319X.2013.09.03]
- Sun L, Qi R, Zhu J, Liu Y, Zheng J. Total arch replacement combined with stented elephant trunk implantation: a new "standard" therapy for type a dissection involving repair of the aortic arch? *Circulation* 2011; **123**: 971-978 [PMID: 21339481 DOI: 10.1161/CIRCULATIONAHA.110.015081]
- Loeys BL, Dietz HC, Braverman AC, Callewaert BL, De Backer J, Devereux RB, Hilhorst-Hofstee Y, Jondeau G, Faivre L, Milewicz DM, Pyeritz RE, Sponseller PD, Wordworth P, De Paepe AM. The revised Ghent nosology for the Marfan syndrome. *J Med Genet* 2010; **47**: 476-485 [PMID: 20591885 DOI: 10.1136/jmg.2009.072785]
- Crawford JD, Hsieh CM, Schenning RC, Slater MS, Landry GJ, Moneta GL, Mitchell EL. Genetics, Pregnancy, and Aortic Degeneration. *Ann Vasc Surg* 2016; **30**: 158.e5-158.e9 [PMID: 26381327 DOI: 10.1016/j.avsg.2015.06.100]
- Howard DP, Banerjee A, Fairhead JF, Perkins J, Silver LE, Rothwell PM; Oxford Vascular Study. Population-based study of incidence and outcome of acute aortic dissection and premorbid risk factor control: 10-year results from the Oxford Vascular Study. *Circulation* 2013; **127**: 2031-2037 [PMID: 23599348 DOI: 10.1161/CIRCULATIONAHA.112.000483]
- Kunishige H, Ishibashi Y, Kawasaki M, Yamakawa T, Morimoto K, Inoue N. Surgical treatment for acute type A aortic dissection during pregnancy (16 weeks) with Loeys-Dietz syndrome. *Gen Thorac Cardiovasc Surg* 2012; **60**: 764-767 [PMID: 22627960 DOI: 10.1007/s11748-012-0073-8]
- Jovic TH, Aboelmagd T, Ramalingam G, Jones N, Nashef SA. Type A Aortic Dissection in Pregnancy: Two Operations Yielding Five Healthy Patients. *Aorta (Stamford)* 2014; **2**: 113-115 [PMID: 26798726]

- DOI: [10.12945/j.aorta.2014.14-013](https://doi.org/10.12945/j.aorta.2014.14-013)]
- 9 **Smok DA.** Aortopathy in pregnancy. *Semin Perinatol* 2014; **38**: 295-303 [PMID: [25037520](https://pubmed.ncbi.nlm.nih.gov/25037520/) DOI: [10.1053/j.semperi.2014.04.019](https://doi.org/10.1053/j.semperi.2014.04.019)]
 - 10 **Sawlani N, Shroff A, Vidovich MI.** Aortic dissection and mortality associated with pregnancy in the United States. *J Am Coll Cardiol* 2015; **65**: 1600-1601 [PMID: [25881947](https://pubmed.ncbi.nlm.nih.gov/25881947/) DOI: [10.1016/j.jacc.2014.12.066](https://doi.org/10.1016/j.jacc.2014.12.066)]
 - 11 **Lansman SL, Goldberg JB, Kai M, Tang GH, Malekan R, Spielvogel D.** Aortic surgery in pregnancy. *J Thorac Cardiovasc Surg* 2017; **153**: S44-S48 [PMID: [27431443](https://pubmed.ncbi.nlm.nih.gov/27431443/) DOI: [10.1016/j.jtcvs.2016.06.015](https://doi.org/10.1016/j.jtcvs.2016.06.015)]
 - 12 **Erbel R, Aboyans V, Boileau C, Bossone E, Bartolomeo RD, Eggebrecht H, Evangelista A, Falk V, Frank H, Gaemperli O, Grabenwöger M, Haverich A, Jung B, Manolis AJ, Meijboom F, Nienaber CA, Roffi M, Rousseau H, Sechtem U, Sirnes PA, Allmen RS, Vrints CJ; ESC Committee for Practice Guidelines.** 2014 ESC Guidelines on the diagnosis and treatment of aortic diseases: Document covering acute and chronic aortic diseases of the thoracic and abdominal aorta of the adult. The Task Force for the Diagnosis and Treatment of Aortic Diseases of the European Society of Cardiology (ESC). *Eur Heart J* 2014; **35**: 2873-2926 [PMID: [25173340](https://pubmed.ncbi.nlm.nih.gov/25173340/) DOI: [10.1093/eurheartj/ehu281](https://doi.org/10.1093/eurheartj/ehu281)]
 - 13 **Barrus A, Afshar S, Sani S, LaBounty TG, Padilla C, Farber MK, Rudikoff AG, Hernandez Conte A.** Acute Type A Aortic Dissection and Successful Surgical Repair in a Woman at 21 Weeks Gestational Pregnancy With Maternal and Fetal Survival: A Case Report. *J Cardiothorac Vasc Anesth* 2018; **32**: 1487-1493 [PMID: [29217246](https://pubmed.ncbi.nlm.nih.gov/29217246/) DOI: [10.1053/j.jvca.2017.09.011](https://doi.org/10.1053/j.jvca.2017.09.011)]
 - 14 **Immer-Bansi A, Immer FF, Henle S, Spörri S, Petersen-Felix S.** Unnecessary emergency caesarean section due to silent CTG during anaesthesia? *Br J Anaesth* 2001; **87**: 791-793 [PMID: [11878536](https://pubmed.ncbi.nlm.nih.gov/11878536/) DOI: [10.1093/bja/87.5.791](https://doi.org/10.1093/bja/87.5.791)]
 - 15 **Taylor KM.** SIRS--the systemic inflammatory response syndrome after cardiac operations. *Ann Thorac Surg* 1996; **61**: 1607-1608 [PMID: [8651756](https://pubmed.ncbi.nlm.nih.gov/8651756/) DOI: [10.1016/0003-4975\(96\)00225-1](https://doi.org/10.1016/0003-4975(96)00225-1)]
 - 16 **Pomini F, Mercogliano D, Cavalletti C, Caruso A, Pomini P.** Cardiopulmonary bypass in pregnancy. *Ann Thorac Surg* 1996; **61**: 259-268 [PMID: [8561577](https://pubmed.ncbi.nlm.nih.gov/8561577/) DOI: [10.1016/0003-4975\(95\)00818-7](https://doi.org/10.1016/0003-4975(95)00818-7)]
 - 17 **Sakaguchi M, Kitahara H, Seto T, Furusawa T, Fukui D, Yanagiya N, Nishimura K, Amano J.** Surgery for acute type A aortic dissection in pregnant patients with Marfan syndrome. *Eur J Cardiothorac Surg* 2005; **28**: 280-3; discussion 283-5 [PMID: [15939618](https://pubmed.ncbi.nlm.nih.gov/15939618/) DOI: [10.1016/j.ejcts.2005.02.047](https://doi.org/10.1016/j.ejcts.2005.02.047)]
 - 18 **Becker RM.** Intracardiac surgery in pregnant women. *Ann Thorac Surg* 1983; **36**: 453-458 [PMID: [6625739](https://pubmed.ncbi.nlm.nih.gov/6625739/) DOI: [10.1016/s0003-4975\(10\)60486-9](https://doi.org/10.1016/s0003-4975(10)60486-9)]
 - 19 **Mul TF, van Herwerden LA, Cohen-Overbeek TE, Catsman-Berrevoets CE, Lotgering FK.** Hypoxic-ischemic fetal insult resulting from maternal aortic root replacement, with normal fetal heart rate at term. *Am J Obstet Gynecol* 1998; **179**: 825-827 [PMID: [9758001](https://pubmed.ncbi.nlm.nih.gov/9758001/) DOI: [10.1016/s0002-9378\(98\)70094-8](https://doi.org/10.1016/s0002-9378(98)70094-8)]
 - 20 **Rajagopalan S, Nwazota N, Chandrasekhar S.** Outcomes in pregnant women with acute aortic dissections: a review of the literature from 2003 to 2013. *Int J Obstet Anesth* 2014; **23**: 348-356 [PMID: [25223644](https://pubmed.ncbi.nlm.nih.gov/25223644/) DOI: [10.1016/j.ijoa.2014.05.001](https://doi.org/10.1016/j.ijoa.2014.05.001)]
 - 21 **Zhu JM, Ma WG, Peterss S, Wang LF, Qiao ZY, Ziganshin BA, Zheng J, Liu YM, Elefteriades JA, Sun LZ.** Aortic Dissection in Pregnancy: Management Strategy and Outcomes. *Ann Thorac Surg* 2017; **103**: 1199-1206 [PMID: [27825688](https://pubmed.ncbi.nlm.nih.gov/27825688/) DOI: [10.1016/j.athoracsur.2016.08.089](https://doi.org/10.1016/j.athoracsur.2016.08.089)]
 - 22 **Wanga S, Silversides C, Dore A, de Waard V, Mulder B.** Pregnancy and Thoracic Aortic Disease: Managing the Risks. *Can J Cardiol* 2016; **32**: 78-85 [PMID: [26604124](https://pubmed.ncbi.nlm.nih.gov/26604124/) DOI: [10.1016/j.cjca.2015.09.003](https://doi.org/10.1016/j.cjca.2015.09.003)]
 - 23 **Kohli E, Jwayyed S, Giorgio G, Bhalla MC.** Acute type a aortic dissection in a 36-week pregnant patient. *Case Rep Emerg Med* 2013; **2013**: 390670 [PMID: [23781352](https://pubmed.ncbi.nlm.nih.gov/23781352/) DOI: [10.1155/2013/390670](https://doi.org/10.1155/2013/390670)]
 - 24 **Sato S, Ogino H, Matsuda H, Sasaki H, Tanaka H, Iba Y.** Annuloaortic ectasia treated successfully in a pregnant woman with Marfan syndrome: report of a case. *Surg Today* 2012; **42**: 285-287 [PMID: [22127536](https://pubmed.ncbi.nlm.nih.gov/22127536/) DOI: [10.1007/s00595-011-0069-5](https://doi.org/10.1007/s00595-011-0069-5)]
 - 25 **Buffolo E, Palma JH, Gomes WJ, Vega H, Born D, Moron AF, Carvalho AC.** Successful use of deep hypothermic circulatory arrest in pregnancy. *Ann Thorac Surg* 1994; **58**: 1532-1534 [PMID: [7979691](https://pubmed.ncbi.nlm.nih.gov/7979691/) DOI: [10.1016/0003-4975\(94\)91952-6](https://doi.org/10.1016/0003-4975(94)91952-6)]
 - 26 **Seeburger J, Mohr FW, Falk V.** Acute type A dissection at 17 weeks of gestation in a Marfan patient. *Ann Thorac Surg* 2007; **83**: 674-676 [PMID: [17258012](https://pubmed.ncbi.nlm.nih.gov/17258012/) DOI: [10.1016/j.athoracsur.2006.06.019](https://doi.org/10.1016/j.athoracsur.2006.06.019)]
 - 27 **Ham S.** Emergency repair of aortic dissection in a 37-week parturient: a case report. *AANA J* 2010; **78**: 63-68 [PMID: [20977131](https://pubmed.ncbi.nlm.nih.gov/20977131/)]
 - 28 **Marumoto A, Nakamura Y, Harada S, Saiki M, Nishimura M.** Acute aortic dissection at 33 weeks of gestation with fetal distress syndrome. *Gen Thorac Cardiovasc Surg* 2011; **59**: 566-568 [PMID: [21850584](https://pubmed.ncbi.nlm.nih.gov/21850584/) DOI: [10.1007/s11748-010-0735-3](https://doi.org/10.1007/s11748-010-0735-3)]
 - 29 **Shaker WH, Refaat AA, Hakamei MA, Ibrahim MF.** Acute type A aortic dissection at seven weeks of gestation in a Marfan patient: case report. *J Card Surg* 2008; **23**: 569-570 [PMID: [18928496](https://pubmed.ncbi.nlm.nih.gov/18928496/) DOI: [10.1111/j.1540-8191.2007.00551.x](https://doi.org/10.1111/j.1540-8191.2007.00551.x)]
 - 30 **Easo J, Horst M, Schmuck B, Thomas RP, Saupe S, Book M, Weymann A.** Retrograde type a dissection in a 24th gestational week pregnant patient - the importance of interdisciplinary interaction to a successful outcome. *J Cardiothorac Surg* 2018; **13**: 36 [PMID: [29720205](https://pubmed.ncbi.nlm.nih.gov/29720205/) DOI: [10.1186/s13019-018-0724-7](https://doi.org/10.1186/s13019-018-0724-7)]
 - 31 **Dong X, Lu J, Cheng W, Wang C.** An atypical presentation of chronic Stanford type A aortic dissection during pregnancy. *J Clin Anesth* 2016; **33**: 337-340 [PMID: [27555189](https://pubmed.ncbi.nlm.nih.gov/27555189/) DOI: [10.1016/j.jclinane.2016.04.039](https://doi.org/10.1016/j.jclinane.2016.04.039)]
 - 32 **Nonga BN, Pasquet A, Noirhomme P, El-Khoury G.** Successful bovine arch replacement for a type A acute aortic dissection in a pregnant woman with severe haemodynamic compromise. *Interact Cardiovasc Thorac Surg* 2012; **15**: 309-310 [PMID: [22547559](https://pubmed.ncbi.nlm.nih.gov/22547559/) DOI: [10.1093/icvts/ivs143](https://doi.org/10.1093/icvts/ivs143)]
 - 33 **Shihata M, Pretorius V, MacArthur R.** Repair of an acute type A aortic dissection combined with an emergency cesarean section in a pregnant woman. *Interact Cardiovasc Thorac Surg* 2008; **7**: 938-940 [PMID: [18583394](https://pubmed.ncbi.nlm.nih.gov/18583394/) DOI: [10.1510/icvts.2008.182766](https://doi.org/10.1510/icvts.2008.182766)]
 - 34 **Meijboom LJ, Vos FE, Timmermans J, Boers GH, Zwinderman AH, Mulder BJ.** Pregnancy and aortic root growth in the Marfan syndrome: a prospective study. *Eur Heart J* 2005; **26**: 914-920 [PMID: [15681576](https://pubmed.ncbi.nlm.nih.gov/15681576/) DOI: [10.1093/eurheartj/ehi103](https://doi.org/10.1093/eurheartj/ehi103)]
 - 35 **Gersony DR, McCloughlin MA, Jin Z, Gersony WM.** The effect of beta-blocker therapy on clinical outcome in patients with Marfan's syndrome: a meta-analysis. *Int J Cardiol* 2007; **114**: 303-308 [PMID: [16831475](https://pubmed.ncbi.nlm.nih.gov/16831475/) DOI: [10.1016/j.ijcard.2005.11.116](https://doi.org/10.1016/j.ijcard.2005.11.116)]
 - 36 **Lydakis C, Lip GY, Beevers M, Beevers DG.** Atenolol and fetal growth in pregnancies complicated by hypertension. *Am J Hypertens* 1999; **12**: 541-547 [PMID: [10371362](https://pubmed.ncbi.nlm.nih.gov/10371362/) DOI: [10.1016/s0895-7061\(99\)00031-x](https://doi.org/10.1016/s0895-7061(99)00031-x)]

- 37 **Yang Z**, Yang S, Wang F, Wang C. Acute aortic dissection in pregnant women. *Gen Thorac Cardiovasc Surg* 2016; **64**: 283-285 [PMID: [25085319](#) DOI: [10.1007/s11748-014-0460-4](#)]



Published By Baishideng Publishing Group Inc
7041 Koll Center Parkway, Suite 160, Pleasanton, CA 94566, USA
Telephone: +1-925-2238242
E-mail: bpgoffice@wjgnet.com
Help Desk: <https://www.f6publishing.com/helpdesk>
<https://www.wjgnet.com>

