

World Journal of *Clinical Cases*

World J Clin Cases 2019 September 6; 7(17): 2413-2657





MINIREVIEWS

- 2413** Multifocal G1-G2 gastric neuroendocrine tumors: Differentiating between Type I, II and III, a clinicopathologic review
Algashaamy K, Garcia-Buitrago M
- 2420** Attention deficit hyperactivity disorder and comorbidity: A review of literature
Gnanavel S, Sharma P, Kaushal P, Hussain S

ORIGINAL ARTICLE

Case Control Study

- 2427** Dietary manipulation and testosterone replacement therapy may explain changes in body composition after spinal cord injury: A retrospective case report
Gorgey AS, Lester RM, Ghatas MP, Sistrun SN, Lavis T

Retrospective Study

- 2438** Risk factors, clinical features, and short-term prognosis of spontaneous fungal peritonitis in cirrhosis: A matched case-control study
Huang CH, Pang LT, Xu LC, Ge TT, Xu QM, Chen Z
- 2450** Incidence of portal vein thrombosis after splenectomy and its influence on transjugular intrahepatic portosystemic shunt stent patency
Dong F, Luo SH, Zheng LJ, Chu JG, Huang H, Zhang XQ, Yao KC

Observational Study

- 2463** Multiplex gene expression profile in inflamed mucosa of patients with Crohn's disease ileal localization: A pilot study
Giudici F, Lombardelli L, Russo E, Cavalli T, Zamboni D, Logiodice F, Kullolli O, Giusti L, Bargellini T, Fazi M, Biancone L, Scaringi S, Clemente AM, Perissi E, Delfino G, Torcia MG, Ficari F, Tonelli F, Piccinni MP, Malentacchi C

Prospective Study

- 2477** Analysis of the postoperative hemostatic profile of colorectal cancer patients subjected to liver metastasis resection surgery
Perez Navarro G, Pascual Bellosta AM, Ortega Lucea SM, Serradilla Martín M, Ramirez Rodriguez JM, Martinez Ubieta J

SYSTEMATIC REVIEW

- 2487** Systematic review of ablative therapy for the treatment of renal allograft neoplasms
Favi E, Raison N, Ambrogi F, Delbue S, Clementi MC, Lamperti L, Perego M, Bischeri M, Ferraresso M

CASE REPORT

- 2505** Subcutaneous sarcoidosis of the upper and lower extremities: A case report and review of the literature
Mehrzaad R, Festa J, Bhatt R
- 2513** Atypical cutaneous lesions in advanced-stage Hodgkin lymphoma: A case report
Massaro F, Ferrari A, Zendri E, Zanelli M, Merli F
- 2519** Characteristics of multiple nodules in a patient with pulmonary Langerhans cell histiocytosis: A case report
Kanaji N, Tokunaga Y, Ishikawa R, Watanabe N, Kadowaki N
- 2526** Impact of continuous local lavage on pancreatic juice-related postoperative complications: Three case reports
Hori T, Ogawa K, Yamamoto H, Harada H, Matsumura K, Yamamoto M, Yamada M, Yazawa T, Kuriyama K, Tani M, Yasukawa D, Kamada Y, Aisu Y, Tani R, Aoyama R, Nakayama S, Sasaki Y, Nishimoto K, Zaima M
- 2536** Adult intussusception caused by colonic anisakis: A case report
Choi YI, Park DK, Cho HY, Choi SJ, Chung JW, Kim KO, Kwon KA, Kim YJ
- 2542** Robotic-assisted resection of ovarian tumors in children: A case report
Xie XX, Wang N, Wang ZH, Zhu YY, Wang JR, Wang XQ
- 2549** Synovial sarcoma in the plantar region: A case report and literature review
Gao J, Yuan YS, Liu T, Lv HR, Xu HL
- 2556** Severe serous cavity bleeding caused by acquired factor V deficiency associated with lymphatic leakage in a hemodialysis patient: A case report
Zhao WB, Chen YR, Luo D, Lin HC, Long B, Wu ZY, Peng H
- 2562** Supermicrosurgery in fingertip defects-split tibial flap of the second toe to reconstruct multiple fingertip defects: A case report
Wang KL, Zhang ZQ, Buckwalter JA, Yang Y
- 2567** Ultrasound-guided fascia iliaca compartment block combined with general anesthesia for amputation in an acute myocardial infarction patient after percutaneous coronary intervention: A case report
Ling C, Liu XQ, Li YQ, Wen XJ, Hu XD, Yang K
- 2573** Rare spontaneous intrahepatic portosystemic shunt in hepatitis B-induced cirrhosis: A case report
Tan YW, Sheng JH, Tan HY, Sun L, Yin YM
- 2580** Imaging of mixed epithelial and stromal tumor of the kidney: A case report and review of the literature
Ye J, Xu Q, Zheng J, Wang SA, Wu YW, Cai JH, Yuan H
- 2587** Allogenic tooth transplantation using 3D printing: A case report and review of the literature
Xu HD, Miron RJ, Zhang XX, Zhang YF

- 2597** Fecal microbiota transplantation as an effective initial therapy for pancreatitis complicated with severe *Clostridium difficile* infection: A case report
Hu Y, Xiao HY, He C, Lv NH, Zhu L
- 2605** Organ-associated pseudosarcomatous myofibroblastic proliferation with ossification in the lower pole of the kidney mimicking renal pelvic carcinoma: A case report
Zhai TY, Luo BJ, Jia ZK, Zhang ZG, Li X, Li H, Yang JJ
- 2611** Treating aplasia cutis congenita in a newborn with the combination of ionic silver dressing and moist exposed burn ointment: A case report
Lei GF, Zhang JP, Wang XB, You XL, Gao JY, Li XM, Chen ML, Ning XQ, Sun JL
- 2617** Cause of postprandial vomiting - a giant retroperitoneal ganglioneuroma enclosing large blood vessels: A case report
Zheng X, Luo L, Han FG
- 2623** Carcinoma ex pleomorphic adenoma of the trachea: A case report
Gao HX, Li Q, Chang WL, Zhang YL, Wang XZ, Zou XX
- 2630** Wilson disease associated with immune thrombocytopenia: A case report and review of the literature
Ma TJ, Sun GL, Yao F, Yang ZL
- 2637** Calcifying fibrous tumor of the mediastinum: A case report
Qi DJ, Zhang QF
- 2644** Brachiocephalic artery stenting through the carotid artery: A case report and review of the literature
Xu F, Wang F, Liu YS
- 2652** An extremely rare pedunculated lipoma of the hypopharynx: A case report
Sun Q, Zhang CL, Liu ZH

ABOUT COVER

Editorial Board Member of *World Journal of Clinical Cases*, Marianna Luongo, MD, Doctor, Surgeon, Department of Neurosurgery, Azienda Ospedaliera Regionale San Carlo, Potenza 85100, Italy

AIMS AND SCOPE

The primary aim of the *World Journal of Clinical Cases (WJCC)* is to provide scholars and readers from various fields of clinical medicine with a platform to publish high-quality clinical research articles and communicate their research findings online.

The *WJCC* mainly publishes case reports, case series, research results and findings in the field of clinical medicine covering a wide range of topics including diagnostic, therapeutic, and preventive modalities.

INDEXING/ABSTRACTING

The *WJCC* is now indexed in PubMed, PubMed Central, Science Citation Index Expanded (also known as SciSearch®), and Journal Citation Reports/Science Edition. The 2019 Edition of Journal Citation Reports cites the 2018 impact factor for *WJCC* as 1.153 (5-year impact factor: N/A), ranking *WJCC* as 99 among 160 journals in Medicine, General and Internal (quartile in category Q3).

RESPONSIBLE EDITORS FOR THIS ISSUE

Responsible Electronic Editor: *Yan-Xia Xing*

Proofing Production Department Director: *Yun-Xiaojian Wu*

NAME OF JOURNAL

World Journal of Clinical Cases

ISSN

ISSN 2307-8960 (online)

LAUNCH DATE

April 16, 2013

FREQUENCY

Semimonthly

EDITORS-IN-CHIEF

Dennis A Bloomfield, Sandro Vento

EDITORIAL BOARD MEMBERS

<https://www.wjnet.com/2307-8960/editorialboard.htm>

EDITORIAL OFFICE

Jin-Lei Wang, Director

PUBLICATION DATE

September 6, 2019

COPYRIGHT

© 2019 Baishideng Publishing Group Inc

INSTRUCTIONS TO AUTHORS

<https://www.wjnet.com/bpg/gerinfo/204>

GUIDELINES FOR ETHICS DOCUMENTS

<https://www.wjnet.com/bpg/GerInfo/287>

GUIDELINES FOR NON-NATIVE SPEAKERS OF ENGLISH

<https://www.wjnet.com/bpg/gerinfo/240>

PUBLICATION MISCONDUCT

<https://www.wjnet.com/bpg/gerinfo/208>

ARTICLE PROCESSING CHARGE

<https://www.wjnet.com/bpg/gerinfo/242>

STEPS FOR SUBMITTING MANUSCRIPTS

<https://www.wjnet.com/bpg/GerInfo/239>

ONLINE SUBMISSION

<https://www.f6publishing.com>

Supermicrosurgery in fingertip defects-split tibial flap of the second toe to reconstruct multiple fingertip defects: A case report

Ke-Lie Wang, Zi-Qing Zhang, Joseph A Buckwalter, Yi Yang

ORCID number: Ke-Lie Wang (0000-0001-8736-5704); Zi-Qing Zhang (0000-0003-4743-7413); Joseph A Buckwalter (0000-0001-9758-7255); Yi Yang (0000-0002-0692-8024).

Author contributions: Wang KL, Zhang ZQ and Yang Y were responsible for conception and design, acquisition of data and drafting the article and performed the surgery; Buckwalter JA revised the article.

Informed consent statement: Informed written consent was obtained from the patient for publication of this report and any accompanying images.

Conflict-of-interest statement: No potential conflicts of interest relevant to this article were reported.

CARE Checklist (2016) statement: The authors have read the CARE Checklist (2016), and the manuscript was prepared and revised according to the CARE Checklist (2016).

Open-Access: This article is an open-access article which was selected by an in-house editor and fully peer-reviewed by external reviewers. It is distributed in accordance with the Creative Commons Attribution Non Commercial (CC BY-NC 4.0) license, which permits others to distribute, remix, adapt, build upon this work non-commercially, and license their derivative works on different terms, provided the original work is properly cited and the use is non-commercial. See:

Ke-Lie Wang, Zi-Qing Zhang, Department of Microsurgery and Hand Surgery, the Longgang Orthopedics Hospital of Shenzhen, Shenzhen 518116, Guangdong Province, China

Joseph A Buckwalter, Department of Orthopaedics and Rehabilitation, University of Iowa, Iowa City, IA 52240, United States

Yi Yang, Department of Microsurgery and Orthopedic Trauma, the First Affiliated Hospital of Sun Yat-sen University, Guangzhou 510080, Guangdong Province, China

Corresponding author: Yi Yang, MD, PHD, Surgeon, Department of Microsurgery and Orthopedic Trauma, the First Affiliated Hospital of Sun Yat-sen University, No. 58 Zhongshan Road 2, Guangzhou 510080, Guangdong Province, China. 270382272@qq.com
Telephone: +86-20-28823388
Fax: +86-20-28823388

Abstract

BACKGROUND

Injuries to multiple fingertips pose a significant treatment dilemma. Numerous reconstructive options exist, all with the ultimate goal of restoring function and sensibility to the injured fingertips.

CASE SUMMARY

A 24-year-old male suffered injury to multiple fingertips of the right hand, resulting in exposed distal phalanges of the middle, ring, and small fingers. The amputated distal stumps were not possible for replantation. Free flap coverage was selected in order to achieve better functional outcome. The fingertip defects were covered by performing a right second toe split tibial flap using local anesthesia at the harvest site and brachial plexus nerve block for the right upper extremity. At 6-month follow-up, all three of the reconstructed fingertips had some preserved nail growth, Semmes-Weinstein Monofilaments testing was equal to the contralateral side and the Static Two-Point Discrimination were comparable to the contralateral side.

CONCLUSION

This report provides a novel reconstructive option for the management of multiple fingertip injuries and demonstrates the utility of supermicrosurgery in management of these injuries.

Key words: Supermicrosurgery; Fingertip defects; Split; Tibial flap; Second toe; Reconstruct; Case report

<http://creativecommons.org/licenses/by-nc/4.0/>

Manuscript source: Unsolicited Manuscript

Received: March 29, 2019

Peer-review started: April 4, 2019

First decision: June 19, 2019

Revised: June 27, 2019

Accepted: July 20, 2019

Article in press: July 20, 2019

Published online: September 6, 2019

P-Reviewer: Ünver B

S-Editor: Cui LJ

L-Editor: A

E-Editor: Xing YX



©The Author(s) 2019. Published by Baishideng Publishing Group Inc. All rights reserved.

Core tip: Injuries to multiple fingertips pose a significant treatment dilemma. Numerous reconstructive options exist, all with the ultimate goal of restoring function and sensibility to the injured fingertips. We present a case of a split tibial flap of the second toe utilized to treat multiple fingertip injuries, resulting in satisfactory restoration of function and sensation. This report provides a novel reconstructive option for the management of multiple fingertip injuries and demonstrates the utility of supermicrosurgery in management of these injuries.

Citation: Wang KL, Zhang ZQ, Buckwalter JA, Yang Y. Supermicrosurgery in fingertip defects-split tibial flap of the second toe to reconstruct multiple fingertip defects: A case report. *World J Clin Cases* 2019; 7(17): 2562-2566

URL: <https://www.wjnet.com/2307-8960/full/v7/i17/2562.htm>

DOI: <https://dx.doi.org/10.12998/wjcc.v7.i17.2562>

INTRODUCTION

The fingertips are the most frequently injured part of the hand^[1,2]. The underlying finger pulps play a vital role in functions of daily life such as sensation, fine touch, and grip perception. It is imperative to manage fingertip injuries with the goal of obtaining a painless, functional finger with protective sensation^[3].

Given the complexity of fingertip injuries, successful replantation of amputated finger pulp is not always possible. Therefore, numerous surgical options have been reported for finger pulp reconstruction with good functional and sensory outcomes, such as V-Y advancement, pedicle flaps, free flaps, and toe pulp transfer^[1,2,4-15].

The purpose of this report is to describe a novel reconstructive method to restore function and sensation after injury to three finger pulps by using the split second toe tibial flap.

CASE PRESENTATION

Chief complaints

A 24-year-old male presented to our hospital, with a shearing, crush-type injury to multiple fingertips of the right hand, resulting in exposed distal phalanges of the middle, ring, and small fingers. The amputated distal stumps were retrieved, but due to the nature of the injury, replantation was not possible.

History of past illness

The patient was a healthy, non-smoker, without signs of tinea pedis or unguis. A variety of reconstruction strategies were presented to the patient and his family, including stump revision amputation, V-Y flap advancement, and pedicle or free flap coverage.

FINAL DIAGNOSIS

After consideration of the options, the patient elected for free flap coverage in order to potentially achieve better functional recovery.

TREATMENT

Initially, the patient underwent irrigation and debridement of the injured fingertips with vacuum-assisted closure (VAC) to cover the wounds. Three days later, we covered the fingertip defects by performing a right second toe split tibial flap using local anesthesia at the harvest site and brachial plexus nerve block for the right upper extremity. The defects of the right middle, ring, and small finger measured $1.8 \text{ cm}^2 \times 1.5 \text{ cm}^2$, $1.5 \text{ cm}^2 \times 1.2 \text{ cm}^2$, and $1.2 \text{ cm}^2 \times 1.0 \text{ cm}^2$, respectively (Figure 1A). A $1.6 \text{ cm}^2 \times 4.5 \text{ cm}^2$ tibial second toe flap was then harvested and accordingly split into three small

flaps as F1, F2, and F3 under the microscope with respective flap areas of $1.3 \text{ cm}^2 \times 1.0 \text{ cm}^2$, $1.6 \text{ cm}^2 \times 1.2 \text{ cm}^2$, and $1.8 \text{ cm}^2 \times 1.5 \text{ cm}^2$ (Figure 1B-D). The F3, F2, and F1 were transferred to middle, ring, and little fingertips with the one artery (the diameter for F3, F2, F1 was 0.8, 0.5, 0.4 mm, respectively), one vein (the diameter for F3, F2, F1 was 0.9, 0.8, 0.5 mm, respectively), and one nerve (the diameter for F3, F2, F1 was 1.0, 0.8, 0.6 mm, respectively) (Figure 2A-C). The anastomoses were completed to the recipient sites by using 11-0 Prolene suture under the microscope, and the donor site was closed with full thickness skin graft.

Post-operatively, Cefuroxime were administered for three days; Papaverine hydrochloride was administered intramuscularly (30 mg, q6h→qd, day1→day 7) for seven days; and Heparin was continually administered intravenously (12500 IU every 24 h) for seven days. Blood coagulation function was monitored every two days to ensure the activated partial thromboplastin time exceeded no more than 1.5 times of the normal level. The patient remained non-weight bearing for both the right upper extremity and right lower extremity, and was discharged from the hospital without any noted complications.

OUTCOME AND FOLLOW-UP

At 6-mo follow-up, the patient had no donor site or harvest site complications (Figure 3A and B), and reported no residual pain or cold intolerance. All three of the reconstructed fingertips had some preserved nail growth, measuring 17 mm, 13 mm, and 10 mm of the middle, ring, and small fingers, respectively. Semmes-Weinstein Monofilament testing was equal to the contralateral side with the 2.83 of the right middle, ring, and small fingertips. The Static Two-Point Discrimination (s2PD) measurements were 8 mm, 9 mm, and 8 mm in the right middle, ring, and small fingertips, while in the contralateral side the measurements were 6 mm, 5 mm and 4 mm, respectively.

DISCUSSION

The fingertips perform unique and significant functions of daily life such as sensation, fine handling, and gripping^[1,2], and they are the most frequently injured part of the hand. For these reasons, it is of vital importance to treat fingertip injuries with careful strategy to achieve pain-free, quality functional and sensory outcomes. In cases where replantation of an amputated fingertip is not feasible, numerous reconstructive options exist^[2-16]. When considering the appropriate surgical technique and reconstruction options, a surgeon should deliberate on the characteristics of the injury, the advantages and disadvantages of the reconstructive method, and the potential for recovering of function, especially for cases involving multiple fingertips injuries.

This case report offers a novel reconstructive option for the management of multiple fingertip injuries. In this case, the patient had no surgical or post-operative complications, and reported no pain, cold intolerance, or functional deficits. Although the patient reported no perceived functional or sensory deficits, the s2PD measurements were decreased compared to contralateral side. These s2PD measurements were all less than 10mm and Semmes-Weinstein Monofilaments testing was equal to the contralateral side, indicating a satisfactory sensory outcome.

CONCLUSION

The concept of supermicrosurgery has found increasing clinical applications in recent years^[16]. With supermicrosurgery, the dissection and anastomosis of very small caliber structures with minimal donor-site morbidity had become a reasonable option. The split tibial second toe flap utilized for this patient is an advanced application of supermicrosurgery, in which the multiple defects were covered with one single split flap. This report is noteworthy for its originality and application of supermicrosurgery. Supermicrosurgery should continue to be explored and considered as a feasible option for fingertip defect reconstruction and other diseases treatment such as lymphedema, nerve repair, organ transplantation, and free flaps in the future.

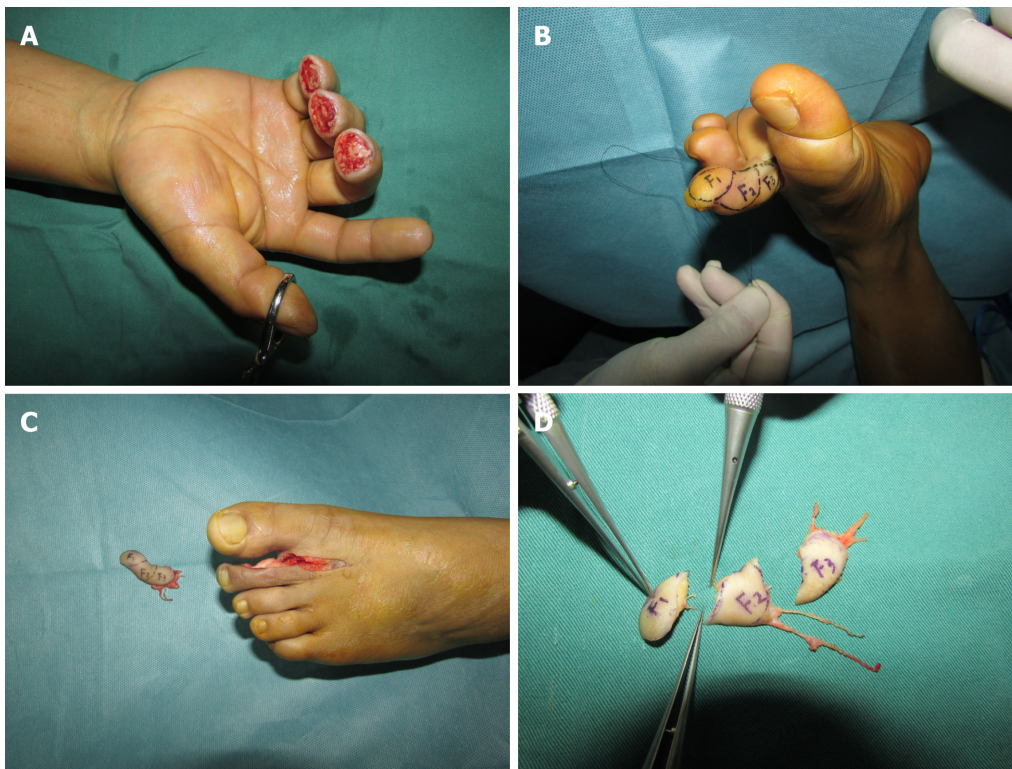


Figure 1 Split tibial second toe flap. A: Three days after the first stage surgery, the wounds were clean and ready for free flap transfer; B: A $1.6\text{ cm}^2 \times 4.5\text{ cm}^2$ tibial second toe flap designed before operation; C: Harvested tibial second toe flap; D: Flap was split into three small flaps as F1, F2, and F3 under a microscope.

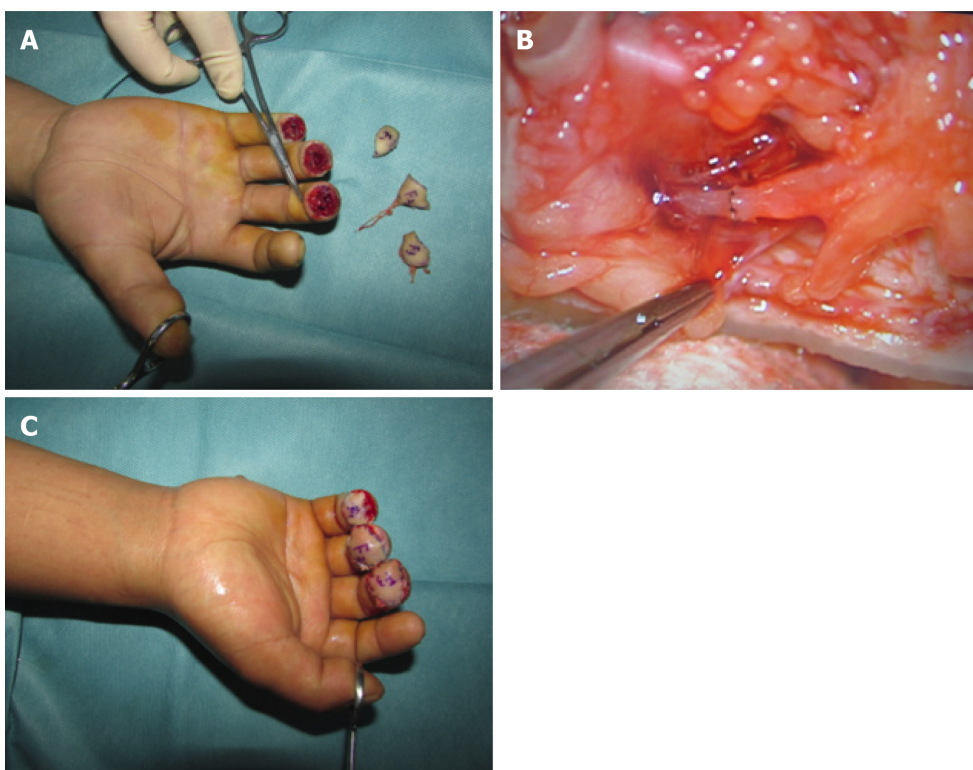


Figure 2 F3, F2, and F1 were transferred to middle, ring, and little fingertips with the one artery. A: F1, F2, and F3 flaps before transfer to recipient sites; B: Representative anastomosis of the vessels and nerve; C: F1, F2, and F3 flaps transferred to recipient sites.

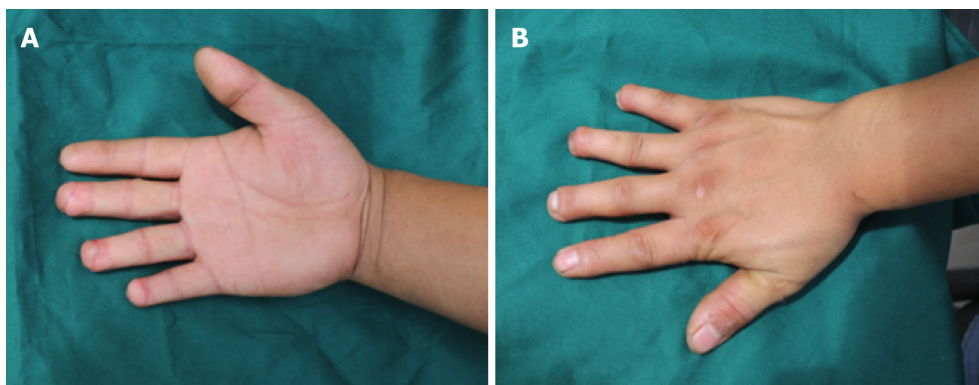


Figure 3 Six months after the surgery. A: Palmar view; B: Dorsal view.

REFERENCES

- 1 Panattoni JB, De Ona IR, Ahmed MM. Reconstruction of fingertip injuries: surgical tips and avoiding complications. *J Hand Surg Am* 2015; **40**: 1016-1024 [PMID: 25823622 DOI: 10.1016/j.jhsa.2015.02.010]
- 2 Lemmon JA, Janis JE, Rohrich RJ. Soft-tissue injuries of the fingertip: methods of evaluation and treatment. An algorithmic approach. *Plast Reconstr Surg* 2008; **122**: 105e-117e [PMID: 18766028 DOI: 10.1097/PRS.0b013e3181823be0]
- 3 Lee DH, Mignemi ME, Crosby SN. Fingertip injuries: an update on management. *J Am Acad Orthop Surg* 2013; **21**: 756-766 [PMID: 24292932 DOI: 10.5435/JAAOS-21-12-756]
- 4 Song D, Pafitanis G, Yang P, Narushima M, Li Z, Liu L, Wang Z. Innervated dorsoradial perforator free flap: A reliable supermicrosurgery fingertip reconstruction technique. *J Plast Reconstr Aesthet Surg* 2017; **70**: 1001-1008 [PMID: 28601599 DOI: 10.1016/j.bjps.2017.05.038]
- 5 Shao X, Chen C, Zhang X, Yu Y, Ren D, Lu L. Coverage of fingertip defect using a dorsal island pedicle flap including both dorsal digital nerves. *J Hand Surg Am* 2009; **34**: 1474-1481 [PMID: 19733984 DOI: 10.1016/j.jhsa.2009.06.021]
- 6 Ni F, Appleton SE, Chen B, Wang B. Aesthetic and functional reconstruction of fingertip and pulp defects with pivot flaps. *J Hand Surg Am* 2012; **37**: 1806-1811 [PMID: 22763057 DOI: 10.1016/j.jhsa.2012.05.003]
- 7 Lim GJ, Yam AK, Lee JY, Lam-Chuan T. The spiral flap for fingertip resurfacing: short-term and long-term results. *J Hand Surg Am* 2008; **33**: 340-347 [PMID: 18343289 DOI: 10.1016/j.jhsa.2007.12.005]
- 8 Huang YC, Liu Y, Chen TH. Use of homodigital reverse island flaps for distal digital reconstruction. *J Trauma* 2010; **68**: 429-433 [PMID: 20154554 DOI: 10.1097/TA.0b013e3181a8b33d]
- 9 Xianyu M, Lei C, Laijin L, Zhigang L. Reconstruction of finger-pulp defect with a homodigital laterodorsal fasciocutaneous flap distally based on the dorsal branches of the proper palmar digital artery. *Injury* 2009; **40**: 1346-1350 [PMID: 19698942 DOI: 10.1016/j.injury.2009.07.067]
- 10 Regmi S, Gu JX, Zhang NC, Liu HJ. A Systematic Review of Outcomes and Complications of Primary Fingertip Reconstruction Using Reverse-Flow Homodigital Island Flaps. *Aesthetic Plast Surg* 2016; **40**: 277-283 [PMID: 26913519 DOI: 10.1007/s00266-016-0624-y]
- 11 Acar MA, Güzel Y, Güleç A, Türkmen F, Erkoçak ÖF, Yılmaz G. Reconstruction of multiple fingertip injuries with reverse flow homodigital flap. *Injury* 2014; **45**: 1569-1573 [PMID: 25037528 DOI: 10.1016/j.injury.2014.06.009]
- 12 Karamese M, Akatekin A, Abac M, Koplay TG, Tosun Z. Fingertip Reconstruction With Reverse Adipofascial Homodigital Flap. *Ann Plast Surg* 2015; **75**: 158-162 [PMID: 26165570 DOI: 10.1097/SAP.000000000000137]
- 13 Kim KS, Yoo SI, Kim DY, Lee SY, Cho BH. Fingertip reconstruction using a volar flap based on the transverse palmar branch of the digital artery. *Ann Plast Surg* 2001; **47**: 263-268 [PMID: 11562030 DOI: 10.1097/00000637-200109000-00008]
- 14 Borman H, Maral T, Tancer M. Fingertip reconstruction using two variations of direct-flow homodigital neurovascular island flaps. *Ann Plast Surg* 2000; **45**: 24-30 [PMID: 10917094 DOI: 10.1097/00000637-200045010-00005]
- 15 Varitimidis SE, Dailiana ZH, Zibis AH, Hantes M, Bargiotas K, Malizos KN. Restoration of function and sensitivity utilizing a homodigital neurovascular island flap after amputation injuries of the fingertip. *J Hand Surg Br* 2005; **30**: 338-342 [PMID: 15936132 DOI: 10.1016/j.jhsb.2005.04.014]
- 16 Masia J, Olivares L, Koshima I, Teo TC, Suominen S, Van Landuyt K, Demirtas Y, Becker C, Pons G, Garusi C, Mitsunaga N. Barcelona consensus on supermicrosurgery. *J Reconstr Microsurg* 2014; **30**: 53-58 [PMID: 24037459 DOI: 10.1055/s-0033-1354742]



Published By Baishideng Publishing Group Inc
7041 Koll Center Parkway, Suite 160, Pleasanton, CA 94566, USA
Telephone: +1-925-2238242
Fax: +1-925-2238243
E-mail: bpgoffice@wjgnet.com
Help Desk: <https://www.f6publishing.com/helpdesk>
<https://www.wjgnet.com>

