

# World Journal of *Hematology*

*World J Hematol* 2019 December 20; 8(1): 1-9





### MINIREVIEWS

- 1 Adult Langerhans cell histiocytosis and immunomodulatory drugs: Review and analysis of thirty-four case reports

*Mauro E, Stefani PM, Gherlinzoni F*

**ABOUT COVER**

Editor-in-Chief of *World Journal of Hematology*, Pier Paolo Piccaluga, MD, PhD, Associate Professor, Department of Experimental, Diagnostic and Experimental Medicine, S. Orsola-Malpighi Hospital, Bologna University School of Medicine, Bologna 40138, Italy

**AIMS AND SCOPE**

The primary aim of *World Journal of Hematology* (WJH, *World J Hematol*) is to provide scholars and readers from various fields of hematology with a platform to publish high-quality basic and clinical research articles and communicate their research findings online.

WJH mainly publishes articles reporting research results and findings obtained in the field of hematology and covering a wide range of topics including anemia, blood coagulation disorders, blood group incompatibility, blood platelet disorders, blood protein disorders, bone marrow diseases, hematologic neoplasms, hemoglobinopathies, hemorrhagic disorders, leukocyte disorders, methemoglobinemia, pancytopenia, polycythemia, hematologic pregnancy complications, preleukemia, sulfhemoglobinemia, and thrombophilia.

**INDEXING/ABSTRACTING**

*World Journal of Hematology* is now indexed in China National Knowledge Infrastructure (CNKI), China Science and Technology Journal Database (CSTJ), and Superstar Journals Database.

**RESPONSIBLE EDITORS FOR THIS ISSUE**

Responsible Electronic Editor: *Yan-Xia Xing*

Proofing Production Department Director: *Xiang Li*

**NAME OF JOURNAL**

*World Journal of Hematology*

**ISSN**

ISSN 2218-6204 (online)

**LAUNCH DATE**

June 2, 2012

**FREQUENCY**

Irregular

**EDITORS-IN-CHIEF**

Pier Paolo Piccaluga

**EDITORIAL BOARD MEMBERS**

<https://www.wjgnet.com/2218-6204/editorialboard.htm>

**EDITORIAL OFFICE**

Ya-Juan Ma, Director

**PUBLICATION DATE**

December 20, 2019

**COPYRIGHT**

© 2019 Baishideng Publishing Group Inc

**INSTRUCTIONS TO AUTHORS**

<https://www.wjgnet.com/bpg/gerinfo/204>

**GUIDELINES FOR ETHICS DOCUMENTS**

<https://www.wjgnet.com/bpg/GerInfo/287>

**GUIDELINES FOR NON-NATIVE SPEAKERS OF ENGLISH**

<https://www.wjgnet.com/bpg/gerinfo/240>

**PUBLICATION MISCONDUCT**

<https://www.wjgnet.com/bpg/gerinfo/208>

**ARTICLE PROCESSING CHARGE**

<https://www.wjgnet.com/bpg/gerinfo/242>

**STEPS FOR SUBMITTING MANUSCRIPTS**

<https://www.wjgnet.com/bpg/GerInfo/239>

**ONLINE SUBMISSION**

<https://www.f6publishing.com>



## Adult Langerhans cell histiocytosis and immunomodulatory drugs: Review and analysis of thirty-four case reports

Endri Mauro, Piero Maria Stefani, Filippo Gherlinzoni

**ORCID number:** Endri Mauro (0000-0002-4521-0998); Piero Maria Stefani (0000-0003-3764-2165); Filippo Gherlinzoni (0000-0002-9136-2108).

**Author contributions:** Mauro E designed the paper, performed the research and wrote the manuscript; Stefani PM and Gherlinzoni F analyzed the data; all authors contributed to this manuscript.

**Conflict-of-interest statement:** Authors declare no conflicts of interest for this article.

**Open-Access:** This is an open-access article that was selected by an in-house editor and fully peer-reviewed by external reviewers. It is distributed in accordance with the Creative Commons Attribution Non Commercial (CC BY-NC 4.0) license, which permits others to distribute, remix, adapt, build upon this work non-commercially, and license their derivative works on different terms, provided the original work is properly cited and the use is non-commercial. See: <http://creativecommons.org/licenses/by-nc/4.0/>

**Manuscript source:** Unsolicited manuscript

**Received:** March 18, 2019

**Peer-review started:** March 19, 2019

**First decision:** September 17, 2019

**Revised:** October 26, 2019

**Accepted:** December 6, 2019

**Article in press:** December 6, 2019

**Published online:** December 20, 2019

**P-Reviewer:** Diamantidis MD

**Endri Mauro, Piero Maria Stefani, Filippo Gherlinzoni,** Hematology Unit, Ca' Foncello Hospital, Treviso 31100, Italy

**Corresponding author:** Endri Mauro, PhD, Doctor, Hematology Unit, Ca' Foncello Hospital, Piazzale Ospedale 1, Treviso 31100, Italy. [endri76@libero.it](mailto:endri76@libero.it)

**Telephone:** +39-42-2322609

**Fax:** +39-42-2322542

### Abstract

Langerhans cell histiocytosis (LCH) is a rare neoplastic disease in dendritic cells. LCH is classified as either a single-system (SS) or multisystem (MS) disease. There is not a standard first-line treatment for LCH in adults. We analyzed the efficacy and safety of immunomodulatory drugs (IMiDs) by searching PubMed/MEDLINE for case reports previously published. The clinical response (nonactive disease or active disease that regressed) was 94% in SS and 53% in MS. IMiDs should only be considered for adults with cutaneous SS involvement; in MS, they should be used only for patients not eligible for more aggressive treatments.

**Key words:** Langerhans cell histiocytosis; Immunomodulatory drugs; Thalidomide; Lenalidomide

©The Author(s) 2019. Published by Baishideng Publishing Group Inc. All rights reserved.

**Core tip:** Langerhans cell histiocytosis (LCH) is a rare neoplastic disease derived from dendritic cells that is seen in children as well as in adults. There is not a standard first-line treatment in adults; no prospective trials have been undertaken on this population, and chemotherapy schedules are often reported from pediatric experiences with suboptimal efficacy and a higher toxicity in adults than in children. Immunomodulatory drugs (IMiDs), as less toxic therapeutic options, have been considered for treating LCH. We analyzed the efficacy and safety of IMiDs in adults with LCH from previously published research.

**Citation:** Mauro E, Stefani PM, Gherlinzoni F. Adult Langerhans cell histiocytosis and immunomodulatory drugs: Review and analysis of thirty-four case reports. *World J Hematol* 2019; 8(1): 1-9

**URL:** <https://www.wjnet.com/2218-6204/full/v8/i1/1.htm>

**DOI:** <https://dx.doi.org/10.5315/wjh.v8.i1.1>

**S-Editor:** Tang JZ

**L-Editor:** A

**E-Editor:** Xing YX



## INTRODUCTION

Langerhans cell histiocytosis (LCH) is a rare neoplastic disease derived from dendritic cells that is seen in children as well as in adults<sup>[1]</sup>. The LCH incidence is estimated to be 1-2 cases per million in adults<sup>[2,3]</sup>. The diagnosis of LCH is based on histologic and immunophenotypic evaluations of lesions: In particular, evidence of Langerhans cell infiltrates with a positivity for CD1a and/or CD207 (Langerin) as seen on an optical microscope or the presence of Birbeck granules as seen on an electronic microscope. Multiple organs may be involved in generating a broad spectrum of clinical manifestations<sup>[4,5]</sup>, from a skin rash to an explosive disseminated disease. In particular, the disease may affect organs or organ systems, especially the bone, skin, pituitary gland, lymph nodes, liver, spleen, gut, central nervous system (CNS), bone marrow, and lungs, with focal or multifocal infiltrates<sup>[4,6]</sup>, that results in different outcomes. The expert panel on behalf of the Euro-Histio-Net classified the disease as either single system LCH (SS-LCH) or multisystem LCH (MS-LCH) (two or more organs/system involved) with or without the involvement of high-risk organs such as bone marrow, spleen, liver or CNS<sup>[6]</sup>. Recently, mutations in the BRAF gene have been reported in approximately 50% of cases, representing a breakthrough in understanding the pathogenesis of LCH<sup>[7-9]</sup>. In particular, BRAF mutations induce constitutive activation of downstream mitogen-activated protein kinase (MAPK)/extracellular signal-regulated kinases, offering new therapeutic targets for the MAPK pathway<sup>[9]</sup>. Based on multifocal or focal LCH and on the involvement at special sites, the treatment changes<sup>[6]</sup>. However, there is not a standard for first-line treatment for adults with LCH; no prospective trials have been undertaken on this population, and the therapy schedules are often reported from pediatric experiences<sup>[1,6,10]</sup>. Therefore, the treatment depends on the extent and severity of the disease at onset. In particular, the pediatric treatment schedule for vinblastine in combination with a prednisone has been used in adults but has a suboptimal efficacy and higher toxicity in adults than in children<sup>[11]</sup>. Other therapeutic approaches for MS-LCH adults include monotherapy with cladribine, cytarabine, etoposide or polychemotherapy regimens<sup>[11-14]</sup>. According to the expert panel of Euro-Histio-Net, recommendations for first-line therapy are summarized in Table 1<sup>[6]</sup>. Among the therapeutic options with activity against LCH, immunomodulatory drugs (IMiDs) have been taken into account. In LCH, a variety of cytokines, IL-1, IL-10, interferon gamma, granulocyte-macrophage colony stimulating factor and tumor necrosis factor alpha (TNF- $\alpha$ ), are expressed at high levels and play key roles in the pathogenesis of disease<sup>[15]</sup>. TNF- $\alpha$  is considered the major promoter for Langerhans cell proliferation and production from hematopoietic stem cells, and its expression is modulated by IMiDs<sup>[16]</sup>. Here, we analyzed the efficacy and safety of IMiDs in LCH.

## LITERATURE RESEARCH

To summarize the current experience of IMiDs as the treatment for LCH, we conducted a PubMed/MEDLINE search for case reports and case series from 1987 until 2018. The search items used were LCH, IMiDs, thalidomide, and lenalidomide; the limits set were case reports, human, and English, French and German languages. A total of 53 articles were found. Review articles, pediatric cases and *in vitro* analyses were excluded. A total of 29 articles about case reports or case series were found<sup>[10,17-44]</sup>. Six patients treated with thalidomide were included in the study for a toxicity and efficacy analysis<sup>[45]</sup>. According to the Writing Group of the Histiocyte Society<sup>[46]</sup> and recommendations from the Euro-Histio-Net<sup>[6]</sup>, in all collected cases, the histopathological diagnosis was made with positivity of CD1a and/or Langerin (CD207) or the presence of Birbeck granules on electronic microscopy. All patients were treated with IMiDs. Moreover, evaluating every single case, we stratified the disease as SS-LCH or MS-LCH. Briefly: SS-LCH is defined as having one organ or system involved (in particular, bone with single or multiple lesions, skin, lymph node, hypothalamic-pituitary/CNS, lungs or other systems), and MS-LCH is defined as having two or more organs or systems involved<sup>[6]</sup>. To assess the disease state after treatment, we applied the HS criteria to every case description<sup>[47]</sup>. Briefly, if the authors reported that all signs and symptoms were resolved, we considered the described patients as having a nonactive disease (NAD); otherwise, the patients were classified as having active disease (AD). AD was further subdivided into regressive [active disease regressive (ADR); improvement in the symptoms or signs, with no new lesions], stable [Active disease stable (ADS); persistence of symptoms or signs, with no new lesions], or progressive disease (PD) (progression and/or appearance of new lesions).

**Table 1 Recommendations for first-line therapy**

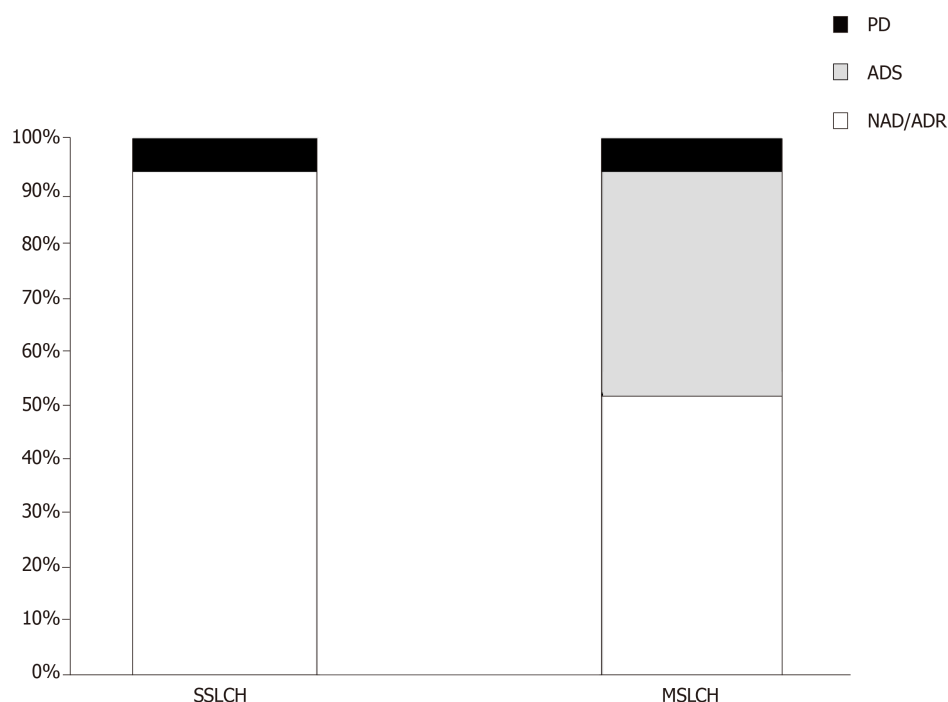
Disease category	Treatment
Unifocal LCH	
Skin	Local therapy (e.g., topical mustard nitrogen 20% in children) Phototherapy: PUVA, narrow band ultraviolet B
Bone	Intralesional steroid injection (40-160 mg methylprednisolone) Radiotherapy (in case of neurological deficit, soft tissue involvement)
Multifocal SS-LCH without "organ risk"	
SS-LCH (bone lesions)	Zoledronic acid
SS-LCH (skin)	Methotrexate 20 mg per week p.o/i.v. Azathioprine 2 mg/kg/d p.o. Thalidomide 100 mg/die p.o. (skin or soft tissue multifocal SS-LCH if symptomatic)
Symptomatic MS-LCH without "risk organs"	Cytarabine 100 mg/m <sup>2</sup> d1-5 q4w i.v. Etoposide 100 mg/m <sup>2</sup> d1-5 q4w i.v. Vinblastin/Prednisone ("pediatric like schedule")
MS-LCH with "risk organs"	2-CDA 6 mg/m <sup>2</sup> d1-5 q4w s.c./i.v.
PLCH asymptomatic	Quit smoking Careful observation
PLCH symptomatic	Systemic steroids Chemotherapy in case of progressive disease In case of severe respiratory failure or major pulmonary failure consider lung transplantation

"Risk organs" contains hematopoietic system, spleen, liver, and central nervous system. LCH: Langerhans cell histiocytosis. SS-LCH: Single-system Langerhans cell histiocytosis; MS-LCH: Multisystem Langerhans cell histiocytosis; P-LCH: Pulmonary Langerhans cell histiocytosis; PUVA: Psoralen plus ultraviolet A.

## RESULTS

A total of 34 patients (21 female and 13 male) were included in this study, including 17 SS-LCH and 17 MS-LCH patients. Detailed information of each patient is displayed in [Table 2](#). The mean age at diagnosis was 45.3 years (range 20-73). The skin or mucocutaneous involvement was reported in 32 patients (94%), and these patients were considered as having only a single organ represented in the SS-LCH group. In addition, the following involved areas were reported: the genital/perineal zone in 22 patients, trunk in 10 patients, groins in 9 patients, axillary involvement in 7 patients, scalp in 5 patients, buccal/mucosal involvement in 5 patients, face in 4 patients, nails in 3 patients, neck in 2 patients, external auditory meatus in 1 patients, retroauricular zone 1 patients, and feet 1 patients. The other organs involved are reported in [Table 3](#). Thalidomide was used in 32 patients, and lenalidomide was used in 2 patients. In 14 patients [7 SS-LCH (20.5%) and 7 MS-LCH (20.5%)], thalidomide was the first-line therapy, while in 20 patients (58.8%) IMiDs were the therapy that followed treatment with steroids, radiotherapy, surgery and chemotherapy. The details of treatment types are summarized in [Table 4](#). The mean thalidomide dosage was 155 mg/d (range 50-500 mg), and the mean lenalidomide dosage was 25 mg/d in case study of Szturz *et al*<sup>[41]</sup> and 10 mg/d in the case study by El-Safadi *et al*<sup>[24]</sup>. The mean duration of therapy with IMiDs was 10.7 mo. Regarding adverse events, the authors reported fatigue/somnolence in 9 patients (22.5%), neuropathy in 6 patients (15%), constipation in 1 patient (2.5%), thrombosis in 1 patient (2.5%), skin rash in 1 patient (2.5%), and neutropenia in 1 patient (2.5%). Regarding the outcomes, considering NAD and ADR, the overall response rate was 73.5%; ADS was reported in 20.5% of patients, and PD was reported in 6% of patients. In the SS-LCH group, 16 patients (94%) achieved NAD/ADR and one patient (6%) achieved PD; in the MS-LCH group, 9 patients (53%) achieved NAD/ADR, 7 patients (41%) achieved a ADS and one patient had PD ([Figure 1](#)). After starting therapy, the follow-up was evaluable in 30 patients with any response (NAD/ADR/ADS/PD) at a mean of 11.6 mo (range 3-60). During follow-up, 7 patients (23.3%) (2 SS-LCH and 5 MS-LCH) were referred for other cytotoxic regimens because of relapse or suboptimal disease control.





**Figure 1 Final treatment outcome ( $n = 34$ ).** MS-LCH: Multisystem Langerhans cell histiocytosis; SS-LCH: Single-system Langerhans cell histiocytosis; NAD: Nonactive disease; ADR: Active disease regressive; ADS: Active disease stable; PD: Progression disease.

## DISCUSSION

Because of the rarity of LCH, there are no standard therapies for adults, and no prospective trials have been undertaken on this setting population. According to the standard pediatric treatment, the vinblastine/prednisone treatment experience has been employed in adults; however, suboptimal efficacy and near universal toxicity have been reported<sup>[11]</sup>. More recently, in a retrospective study, 35 adults (28 patients with MS-LCH) were treated with vinblastine and steroids as a first-line therapy, achieving an overall response rate of 71%<sup>[48]</sup>. In this study, neutropenia was reported in 17% of patients, peripheral sensitive neuropathy (grade 2) in 26% of patients, and peripheral motor neuropathy (grade 2) in 3% of patients<sup>[48]</sup>. As an alternative choice to vinblastine, other drugs, such as cladribine and cytosine arabinoside (ARA-c), have been considered in adults<sup>[1,11]</sup>. In particular, Saven *et al*<sup>[14]</sup> conducted phase II trials with cladribine; in total, 13 patients were enrolled with an overall response rate of 75% with not only skin involvement but also soft tissues, lymph nodes, bones and pulmonary sites. The principal acute toxicity was hematologic with seven patients experiencing grade 3 or 4 neutropenia. On other hand, Cantu *et al*<sup>[11]</sup> reported a retrospective study in which the poor response rate of ARA-c (21%) and the number of grade 3-4 toxic events (20%) were lowest of the three regimens shown in the study (vinblastine, cladribin and ARA-c) in patients with bone involvement. Retrospective analyses of the MACOP-B regimen (methorexate, doxorubicin, cyclophamide, vincristine, prednisone, and bleomycin) have shown high efficacy<sup>[13]</sup> in adults with LCH. However, this intensive treatment should be reserved for very severe cases. The BRAF-V600E mutation gene discovery paved the way for targeted therapies such as BRAF or MEK inhibitors in patients with LCH<sup>[49]</sup>. In particular, vemurafenib is the first selective BRAF inhibitor approved by the United States Food and Drug Administration for malignant melanomas where BRAF mutations are expressed. However, in melanoma trials, vemurafenib was associated with considerable toxicity, including secondary squamous cell carcinoma, in over 30% of patients; moreover, the optimal dosage and duration of this treatment require further investigation<sup>[50]</sup>. A variety of cytokines are expressed in LCH lesions. In particular, high levels of IL-1, IL-10 and TNF- $\alpha$  have been reported<sup>[15]</sup>. IMiDs such as thalidomide and lenalidomide (an analogue of thalidomide) are cytokine modulators, especially for the inhibition of TNF- $\alpha$ ; therefore, these drugs have been considered feasible candidates for the treatment of LCH. However, the evaluation of the efficacy and safety of IMiDs in LCH are limited mostly to case reports. To our knowledge, the study of McClain *et al*<sup>[10]</sup> is the only phase II trial using thalidomide for LCH. In this study, the authors enrolled 16 patients: 12 pediatric patients (ages from birth to 3 years) and 4 adult patients (ages

**Table 2** List of case reports on immunomodulatory drugs in langerhans cell histiocytosis

Ref.	Publication year	Age	Sex	SS-LCH (1) MS-LCH (2)	Previous therapies	IMiDS dose <sup>†</sup>	Duration (mo)	Out come
Gnassia <i>et al</i> <sup>[27]</sup>	1987	32	F	1	No	50	60	NAD
Viraben <i>et al</i> <sup>[43]</sup>	1988	48	M	1	NA	300	1	NAD
Bensaid <i>et al</i> <sup>[19]</sup>	1992	29	F	2	No	100	3	ADR
Misery <i>et al</i> <sup>[33]</sup>	1993	67	M	1	No	200	3	NAD
Thomas <i>et al</i> <sup>[42]</sup>	1993	24	F	2	No	50	3	ADS
Thomas <i>et al</i> <sup>[42]</sup>	1993	59	F	2	Prednisone	50	18	ADS
Dallafior <i>et al</i> <sup>[23]</sup>	1995	65	F	1	Cladribin	200-100	10	NAD
Meunier <i>et al</i> <sup>[32]</sup>	1995	66	M	1	No	100	2	NAD
Bouyssou-Gauthier <i>et al</i> <sup>[21]</sup>	1996	68	M	2	Cyclophosphamide/steroids	NA	NA	ADS
Gerlach <i>et al</i> <sup>[26]</sup>	1998	73	F	2	Etoposide/topi-cal mustard	200	12	ADR
Lair <i>et al</i> <sup>[29]</sup>	1998	33	F	2	RT/surgery	100	28	ADS
Claudon <i>et al</i> <sup>[22]</sup>	2002	44	F	2	Metotrexate/steroids	100	4	ADR
Kolde <i>et al</i> <sup>[28]</sup>	2002	23	M	2	No	500	3	ADS
Kolde <i>et al</i> <sup>[28]</sup>	2002	61	F	2	Prednisone	500	16	ADS
Mortazavi <i>et al</i> <sup>[35]</sup>	2002	29	M	2	No	100	2	ADS
Santillan <i>et al</i> <sup>[38]</sup>	2003	33	F	1	RT/surgery	100	12	NAD
Padula <i>et al</i> <sup>[36]</sup>	2004	31	F	1	RT/surgery	NA	NA	NAD
Sander <i>et al</i> <sup>[37]</sup>	2004	38	M	1	Cladribin	200	6	NAD
Mauro <i>et al</i> <sup>[31]</sup>	2005	73	F	2	CVP	100	7	ADR
Alioua <i>et al</i> <sup>[17]</sup>	2006	43	F	2	No	100	12	ADR
Moravvej <i>et al</i> <sup>[34]</sup>	2006	27	M	1	PUVA	100	3	ADR
Wollina <i>et al</i> <sup>[44]</sup>	2006	38	M	2	Cladribin	200	9	NAD
Broekaert <i>et al</i> <sup>[20]</sup>	2007	57	F	2	No	50	24	ADR
McClain <i>et al</i> <sup>[10]</sup>	2007	45	F	1	Vinorelbine/prednisone	100	22	NR/PD
McClain <i>et al</i> <sup>[10]</sup>	2007	31	F	2	Vinorelbine/prednisone/RT	100	0,5	NR/PD
McClain <i>et al</i> <sup>[10]</sup>	2007	21	F	2	Vinorelbine/prednisone/RT	100	5	NAD
McClain <i>et al</i> <sup>[10]</sup>	2007	46	F	2	Vinorelbine/prednisone/RT	100	12	NAD
Li <i>et al</i> <sup>[30]</sup>	2010	27	M	1	No	150	5	NAD
Fernandes <i>et al</i> <sup>[25]</sup>	2011	60	F	1	No	100	4	NAD
Shahidi-Dadras <i>et al</i> <sup>[39]</sup>	2011	20	M	1	Topical steroid	200	6	NAD
Szturz <i>et al</i> <sup>[41]</sup>	2012	35	M	2	Cladribin/Cyclophosphamide methylprednisolone/RT/CHO-EP/BEAM	Lena 25	9	ADR
El-safadi <i>et al</i> <sup>[24]</sup>	2012	59	F	1	Surgery/RT/MTX	Lena 10	19	NAD



Subramaniyan <i>et al</i> <sup>[40]</sup>	2015	71	M	1	No	200	10	NAD
Ruiz Beguerie <i>et al</i> <sup>[18]</sup>	2017	56	F	1	No	150	12	NAD

<sup>1</sup>Dose in mg/d. MS-LCH: Multisystem Langerhans cell histiocytosis; SS-LCH: Single-system Langerhans cell histiocytosis; RT: Radiotherapy; NAD: Nonactive disease; ADR: Active disease regressive; ADS: Active disease stable; NR/PD: Nonresponse/progression disease; MTX: Methotrexate; Lena 10: Lenalidomide 10 mg; Lena 25: Lenalidomide 25 mg; CVP: Cyclophosphamide, vincristine, prednisone; CHOEP: Cyclophosphamide, doxorubicin, vincristine, etoposide, and prednisone; BEAM: Carmustine, etoposide, cytarabine, and melphalan; PUVA: Photochemotherapy; NA: Not available; F: Female; M: Male; IMiDs: Immunomodulatory drugs.

from 34 years to 46 years). Moreover, in 2004, Sander and coworkers reported a cutaneous LCH case successfully treated with thalidomide and reported ten cases published in the literature with similar clinical features<sup>[37]</sup>. In 2013, European panel of experts established recommendations about the diagnosis and therapy<sup>[6]</sup>. Grades of treatment recommendations were based on non-analytic studies (for example, case reports, case series, small retrospective studies, and expert opinions). After reviewing the literature<sup>[10,37]</sup>, thalidomide was advised for LCH with mild symptoms in skin or soft tissue multifocal single system without risk organs involved. We performed a literature search for case reports on LCH treated with IMiDs and found 34 cases from 1987 to 2018. In our study, 94% of patients with SS-LCH achieved the best response (NAD/ADR) (Figure 1). In total, 50% of patients reported were MS-LCH (Table 3); in this analysis, the response rate for patients with NAD/ADR was 53%, and ADS was found in 41% of the patients. After somnolence, neuropathy is the most reported adverse event (16% of patients). In addition to the previously reported studies and recommendations from panel experts, we confirm in a larger setting of patients that IMiDs should be considered for treating adult patients with only mucocutaneous involvement; however, in the MS-LCH group, as expected, the IMiDs show a lower response rate. Therefore, other therapeutic approaches such as ARA-c, cladribin or vinblastine are recommended. In conclusion, IMiDs are a validated alternative to cytotoxic chemotherapeutic agents in most patients with SS-LCH; on other hand, considering the response rate in our study (53%) in patients with MS-LCH, IMiDs could be an evaluable choice for the treatment only in a limited number of patients based on age, compliance, performance status, expected toxicities, previous treatments, neuropathy or other comorbidities that make the patients not eligible for more aggressive treatments. Our study has several limitations. A publication bias toward more interesting and/or severe cases and successfully treated cases may lead to an over- or underestimation of the efficacy and safety of IMiDs in LCH. Prospective research for optimal treatment strategies for LCH should be warranted, albeit difficult to conduct for epidemiological reasons.

## CONCLUSION

Different therapeutic strategies have been proposed for treatment of LCH in adults. The efficacy and safety of IMiDs have been reported in the treatment of multifocal SS-LCH (in particular skin or soft tissue if symptomatic). However, IMiDs could play a key role also in MS-LCH only in a limited setting of patients not eligible for more aggressive schedules.

**Table 3 Clinical features of all 34 patients**

Clinical features	All patients (%)
Female	21 (62)
Age at diagnosis mean (range)	45.3 (20-73)
Muco-cutaneous involvement	32 (94)
Multiorgan involvement	17 (50)
Lung involvement	3 (9)
CNS/pituitary involvement	8 (23.5)
Bone involvement	6 (18)
Lymph nodes involvement	3 (9)
Splenomegaly/hepatomegaly	2 (6)
Others sites involved (bone marrow, parotid gland)	2 (6)

CNS: Central nervous system.

**Table 4 Previous treatments**

Treatment before IMiDs	n (%)
None	14 (41)
Radiotherapy	8 (23.5)
Steroids	8 (23.5)
Vinorelbine	4 (12)
Surgery	4 (12)
Cladribin	4 (12)
Metotrexate	2 (6%)
Polichemotherapy regimens	2 (6)
Cyclophosphamide (single agent)	2 (6)
Topical drugs	2 (6)
Etoposide	1 (3)
PUVA	1 (3)

PUVA: Psolaren plus ultraviolet A; IMiDs: Immunomodulatory drugs.

## REFERENCES

- Allen CE, Ladisch S, McClain KL. How I treat Langerhans cell histiocytosis. *Blood* 2015; **126**: 26-35 [PMID: 25827831 DOI: 10.1182/blood-2014-12-569301]
- Goyal G, Shah MV, Hook CC, Wolanskyj AP, Call TG, Rech KL, Go RS. Adult disseminated Langerhans cell histiocytosis: incidence, racial disparities and long-term outcomes. *Br J Haematol* 2018; **182**: 579-581 [PMID: 28653448 DOI: 10.1111/bjh.14818]
- Baumgartner I, von Hochstetter A, Baumert B, Luetolf U, Follath F. Langerhans'-cell histiocytosis in adults. *Med Pediatr Oncol* 1997; **28**: 9-14 [PMID: 8950330 DOI: 10.1002/(sici)1096-911x(199701)28:1<9:aid-mpo3>3.0.co;2-p]
- Lau SK, Chu PG, Weiss LM. Immunohistochemical expression of Langerin in Langerhans cell histiocytosis and non-Langerhans cell histiocytic disorders. *Am J Surg Pathol* 2008; **32**: 615-619 [PMID: 18277880 DOI: 10.1097/PAS.0b013e31815b212b]
- Valladeau J, Ravel O, Dezutter-Dambuyant C, Moore K, Kleijmeer M, Liu Y, Duvert-Frances V, Vincent C, Schmitt D, Davoust J, Caux C, Lebecque S, Saeland S. Langerin, a novel C-type lectin specific to Langerhans cells, is an endocytic receptor that induces the formation of Birbeck granules. *Immunity* 2000; **12**: 71-81 [PMID: 10661407 DOI: 10.1016/s1074-7613(00)80160-0]
- Girschikofsky M, Arico M, Castillo D, Chu A, Doberauer C, Fichter J, Haroche J, Kaltsas GA, Makras P, Marzano AV, de Menthon M, Micke O, Passoni E, Seegenschmiedt HM, Tazi A, McClain KL. Management of adult patients with Langerhans cell histiocytosis: recommendations from an expert panel on behalf of Euro-Histio-Net. *Orphanet J Rare Dis* 2013; **8**: 72 [PMID: 23672541 DOI: 10.1186/1750-1172-8-72]
- Badalian-Very G, Vergilio JA, Degar BA, MacConaill LE, Brandner B, Calicchio ML, Kuo FC, Ligon AH, Stevenson KE, Kehoe SM, Garraway LA, Hahn WC, Meyerson M, Fleming MD, Rollins BJ. Recurrent BRAF mutations in Langerhans cell histiocytosis. *Blood* 2010; **116**: 1919-1923 [PMID: 20519626 DOI: 10.1182/blood-2010-04-279083]
- Berres ML, Lim KP, Peters T, Price J, Takizawa H, Salmon H, Idoyaga J, Ruza A, Lupo PJ, Hicks MJ, Shih A, Simko SJ, Abhyankar H, Chakraborty R, Leboeuf M, Beltrão M, Lira SA, Heym KM, Bigley V,

- Collin M, Manz MG, McClain K, Merad M, Allen CE. BRAF-V600E expression in precursor versus differentiated dendritic cells defines clinically distinct LCH risk groups. *J Exp Med* 2014; **211**: 669-683 [PMID: 24638167 DOI: 10.1084/jem.20130977]
- 9 **Diamond EL**, Durham BH, Haroche J, Yao Z, Ma J, Parikh SA, Wang Z, Choi J, Kim E, Cohen-Aubart F, Lee SC, Gao Y, Micol JB, Campbell P, Walsh MP, Sylvester B, Dolgalev I, Aminova O, Heguy A, Zappile P, Nakitandwe J, Ganzel C, Dalton JD, Ellison DW, Estrada-Veras J, Lacouture M, Gahl WA, Stephens PJ, Miller VA, Ross JS, Ali SM, Briggs SR, Fasan O, Block J, Héritier S, Donadieu J, Solit DB, Hyman DM, Baselga J, Janku F, Taylor BS, Park CY, Amoura Z, Dogan A, Emile JF, Rosen N, Gruber TA, Abdel-Wahab O. Diverse and Targetable Kinase Alterations Drive Histiocytic Neoplasms. *Cancer Discov* 2016; **6**: 154-165 [PMID: 26566875 DOI: 10.1158/2159-8290.CD-15-0913]
- 10 **McClain KL**, Kozinetz CA. A phase II trial using thalidomide for Langerhans cell histiocytosis. *Pediatr Blood Cancer* 2007; **48**: 44-49 [PMID: 16333818 DOI: 10.1002/pbc.20578]
- 11 **Cantu MA**, Lupo PJ, Bilgi M, Hicks MJ, Allen CE, McClain KL. Optimal therapy for adults with Langerhans cell histiocytosis bone lesions. *PLoS One* 2012; **7**: e43257 [PMID: 22916233 DOI: 10.1371/journal.pone.0043257]
- 12 **Simko SJ**, McClain KL, Allen CE. Up-front therapy for LCH: is it time to test an alternative to vinblastine/prednisone? *Br J Haematol* 2015; **169**: 299-301 [PMID: 25400231 DOI: 10.1111/bjh.13208]
- 13 **Derenzini E**, Fina MP, Stefoni V, Pellegrini F, Broccoli A, Gandolfi L, Pileri S, Fanti S, Lopci E, Castellucci P, Agostinelli C, Baccarani M, Zinzani PL. MACOP-B regimen in the treatment of adult Langerhans cell histiocytosis: experience on seven patients. *Ann Oncol* 2010; **21**: 1173-1178 [PMID: 19861578 DOI: 10.1093/annonc/mdp455]
- 14 **Saven A**, Burian C. Cladribine activity in adult langerhans-cell histiocytosis. *Blood* 1999; **93**: 4125-4130 [PMID: 10361109 DOI: 10.1182/blood.V93.12.4125]
- 15 **Egeler RM**, Favara BE, van Meurs M, Laman JD, Claassen E. Differential In situ cytokine profiles of Langerhans-like cells and T cells in Langerhans cell histiocytosis: abundant expression of cytokines relevant to disease and treatment. *Blood* 1999; **94**: 4195-4201 [PMID: 10590064]
- 16 **Caux C**, Dezutter-Dambuyant C, Schmitt D, Banchereau J. GM-CSF and TNF-alpha cooperate in the generation of dendritic Langerhans cells. *Nature* 1992; **360**: 258-261 [PMID: 1279441 DOI: 10.1038/360258a0]
- 17 **Alioua Z**, Hjira N, Oumakhir S, Frikh R, Ghfir M, Rimani M, Sedrati O. [Thalidomide in adult multisystem Langerhans cell histiocytosis: a case report]. *Rev Med Interne* 2006; **27**: 633-636 [PMID: 16631279 DOI: 10.1016/j.revmed.2006.01.022]
- 18 **Ruiz Beguerie J**, Fernández J, Stringa MF, Anaya J. Vulvar Langerhans cell histiocytosis and thalidomide: an effective treatment option. *Int J Dermatol* 2017; **56**: 324-326 [PMID: 27778317 DOI: 10.1111/ijd.13377]
- 19 **Bensaid P**, Machet L, Vaillant L, Machet MC, Scotto B, Lorette G. Langerhans-cell histiocytosis in the adult: regressive parotid involvement following thalidomide therapy. *Ann Dermatol Venereol* 1992; **119**: 281-283 [PMID: 1530241]
- 20 **Broekaert SM**, Metzler G, Burgdorf W, Röcken M, Schaller M. Multisystem Langerhans cell histiocytosis: successful treatment with thalidomide. *Am J Clin Dermatol* 2007; **8**: 311-314 [PMID: 17902734 DOI: 10.2165/00128071-200708050-00007]
- 21 **Bouyssou-Gauthier ML**, Bedane C, Jaccard A, Dang PM, Labrousse F, Leboutet MJ, Bernard P, Bonnetblanc JM. [Multicentric histiocytosis with hematological involvement]. *Ann Dermatol Venereol* 1996; **123**: 460-463 [PMID: 9033715]
- 22 **Claudon A**, Dietemann JL, Hamman De Compte A, Hassler P. [Interest in thalidomide in cutaneo-mucous and hypothalamo-hypophyseal involvement of Langerhans cell histiocytosis]. *Rev Med Interne* 2002; **23**: 651-656 [PMID: 12162220 DOI: 10.1016/s0248-8663(02)00627-6]
- 23 **Dallafor S**, Pugin P, Cerny T, Betticher D, Saurat JH, Hauser C. [Successful treatment of a case of cutaneous Langerhans cell granulomatosis with 2-chlorodeoxyadenosine and thalidomide]. *Hautarzt* 1995; **46**: 553-560 [PMID: 7558825 DOI: 10.1007/s001050050298]
- 24 **El-Safadi S**, Dreyer T, Oehmke F, Muenstedt K. Management of adult primary vulvar Langerhans cell histiocytosis: review of the literature and a case history. *Eur J Obstet Gynecol Reprod Biol* 2012; **163**: 123-128 [PMID: 22464205 DOI: 10.1016/j.ejogrb.2012.03.010]
- 25 **Fernandes LB**, Guerra JG, Costa MB, Paiva IG, Duran FP, Jacó DN. Langerhans cells histiocytosis with vulvar involvement and responding to thalidomide therapy--case report. *An Bras Dermatol* 2011; **86**: S78-S81 [PMID: 22068778 DOI: 10.1590/s0365-05962011000700020]
- 26 **Gerlach B**, Stein A, Fischer R, Wozel G, Dittert DD, Richter G. Langerhans cell histiocytosis in the elderly. *Hautarzt* 1998; **49**: 23-30 [PMID: 9522189 DOI: 10.1007/s001050050696]
- 27 **Gnassia A**, Gnassia R, Bovalent D, Puissant A, Goudal H. Histiocytosis X avec "granulome eosinophile vulvaire": effet spectaculaire du thalidomide. *Ann Dermatol Vénéréol*. 1987; **114**: 1387-1389
- 28 **Kolde G**, Schulze P, Sterry W. Mixed response to thalidomide therapy in adults: two cases of multisystem Langerhans' cell histiocytosis. *Acta Derm Venereol* 2002; **82**: 384-386 [PMID: 12430744 DOI: 10.1080/000155502320624186]
- 29 **Lair G**, Marie I, Cailleux N, Blot E, Boullié MC, Courville P, Lauret P, Lévesque H, Courtois H. [Langerhans histiocytosis in adults: cutaneous and mucous lesion regression after treatment with thalidomide]. *Rev Med Interne* 1998; **19**: 196-198 [PMID: 9775141 DOI: 10.1016/s0248-8663(97)80720-5]
- 30 **Li R**, Lin T, Gu H, Zhou Z. Successful thalidomide treatment of adult solitary perianal Langerhans cell histiocytosis. *Eur J Dermatol* 2010; **20**: 391-392 [PMID: 20146969 DOI: 10.1684/ejd.2010.0905]
- 31 **Mauro E**, Fraulini C, Rigolin GM, Galeotti R, Spanedda R, Castoldi G. A case of disseminated Langerhans' cell histiocytosis treated with thalidomide. *Eur J Haematol* 2005; **74**: 172-174 [PMID: 15654911 DOI: 10.1111/j.1600-0609.2004.00358.x]
- 32 **Meunier L**, Marck Y, Ribeyre C, Meynadier J. Adult cutaneous Langerhans cell histiocytosis: remission with thalidomide treatment. *Br J Dermatol* 1995; **132**: 168 [PMID: 7756144 DOI: 10.1111/j.1365-2133.1995.tb08659.x]
- 33 **Misery L**, Larbre B, Lyonnet S, Faure M, Thivolet J. Remission of Langerhans cell histiocytosis with thalidomide treatment. *Clin Exp Dermatol* 1993; **18**: 487 [PMID: 8252782 DOI: 10.1111/j.1365-2230.1993.tb02262.x]
- 34 **Moravvej H**, Yousefi M, Barikbin B. An unusual case of adult disseminated cutaneous Langerhans cell histiocytosis. *Dermatol Online J* 2006; **12**: 13 [PMID: 17083893]
- 35 **Mortazavi H**, Ehsani A, Namazi MR, Hosseini M. Langerhans' cell histiocytosis. *Dermatol Online J*

- 2002; **8**: 18 [PMID: [12546773](#)]
- 36 **Padula A**, Medeiros LJ, Silva EG, Deavers MT. Isolated vulvar Langerhans cell histiocytosis: report of two cases. *Int J Gynecol Pathol* 2004; **23**: 278-283 [PMID: [15213605](#) DOI: [10.1097/01.pgp.0000130042.31203.b0](#)]
- 37 **Sander CS**, Kaatz M, Elsner P. Successful treatment of cutaneous langerhans cell histiocytosis with thalidomide. *Dermatology* 2004; **208**: 149-152 [PMID: [15057007](#) DOI: [10.1159/000076491](#)]
- 38 **Santillan A**, Montero AJ, Kavanagh JJ, Liu J, Ramirez PT. Vulvar Langerhans cell histiocytosis: a case report and review of the literature. *Gynecol Oncol* 2003; **91**: 241-246 [PMID: [14529688](#) DOI: [10.1016/s0090-8258\(03\)00370-6](#)]
- 39 **Shahidi-Dadras M**, Saeedi M, Shakoei S, Ayatollahi A. Langerhans cell histiocytosis: an uncommon presentation, successfully treated by thalidomide. *Indian J Dermatol Venereol Leprol* 2011; **77**: 587-590 [PMID: [21860158](#) DOI: [10.4103/0378-6323.84064](#)]
- 40 **Subramaniyan R**, Ramachandran R, Rajangam G, Donaparthi N. Purely cutaneous Langerhans cell histiocytosis presenting as an ulcer on the chin in an elderly man successfully treated with thalidomide. *Indian Dermatol Online J* 2015; **6**: 407-409 [PMID: [26753141](#) DOI: [10.4103/2229-5178.169743](#)]
- 41 **Szturcz P**, Adam Z, Rehák Z, Koukalová R, Slaisová R, Stehliková O, Chovancová J, Klabusay M, Krejčí M, Pour L, Hájek R, Mayer J. Lenalidomide proved effective in multisystem Langerhans cell histiocytosis. *Acta Oncol* 2012; **51**: 412-415 [PMID: [22103591](#) DOI: [10.3109/0284186X.2011.631581](#)]
- 42 **Thomas L**, Ducros B, Secchi T, Balme B, Moulin G. Successful treatment of adult's Langerhans cell histiocytosis with thalidomide. Report of two cases and literature review. *Arch Dermatol* 1993; **129**: 1261-1264 [PMID: [8215489](#) DOI: [10.1001/archderm.1993.01680310031004](#)]
- 43 **Viraben R**, Dupre A, Gorguet B. Pure cutaneous histiocytosis resembling sinus histiocytosis. *Clin Exp Dermatol* 1988; **13**: 197-199 [PMID: [3246081](#) DOI: [10.1111/j.1365-2230.1988.tb01970.x](#)]
- 44 **Wollina U**, Kaatz M, Krönert C, Schönlebe J, Schmalenberg H, Schreiber G, Köstler E, Haroske G. Cutaneous Langerhans cell histiocytosis with subsequent development of haematological malignancies. Report of two cases. *Acta Dermatovenereol Alp Pannonica Adriat* 2006; **15**: 79-84 [PMID: [16998607](#)]
- 45 **Crickx E**, Bouaziz JD, Lorillon G, de Menthon M, Cordoliani F, Bugnet E, Bagot M, Rybojad M, Mourah S, Tazi A. Clinical Spectrum, Quality of Life, BRAF Mutation Status and Treatment of Skin Involvement in Adult Langerhans Cell Histiocytosis. *Acta Derm Venereol* 2017; **97**: 838-842 [PMID: [28421232](#) DOI: [10.2340/00015555-2674](#)]
- 46 Histiocytosis syndromes in children. Writing Group of the Histiocyte Society. *Lancet* 1987; **1**: 208-209 [PMID: [2880029](#) DOI: [10.1016/S0140-6736\(87\)90016-X](#)]
- 47 **Broadbent V**, Gardner H. Current therapy for Langerhans cell histiocytosis. *Hematol Oncol Clin North Am* 1998; **12**: 327-338 [PMID: [9561903](#) DOI: [10.1016/S0889-8588\(05\)70513-X](#)]
- 48 **Tazi A**, Lorillon G, Haroche J, Neel A, Dominique S, Aouba A, Bouaziz JD, de Margerie-Melon C, Bugnet E, Cottin V, Comont T, Lavigne C, Kahn JE, Donadieu J, Chevret S. Vinblastine chemotherapy in adult patients with langerhans cell histiocytosis: a multicenter retrospective study. *Orphanet J Rare Dis* 2017; **12**: 95 [PMID: [28532436](#) DOI: [10.1186/s13023-017-0651-z](#)]
- 49 **Haroche J**, Cohen-Aubart F, Emile JF, Arnaud L, Maksud P, Charlotte F, Cluzel P, Drier A, Hervier B, Benameur N, Besnard S, Donadieu J, Amoura Z. Dramatic efficacy of vemurafenib in both multisystemic and refractory Erdheim-Chester disease and Langerhans cell histiocytosis harboring the BRAF V600E mutation. *Blood* 2013; **121**: 1495-1500 [PMID: [23258922](#) DOI: [10.1182/blood-2012-07-446286](#)]
- 50 **Kobayashi M**, Tojo A. Langerhans cell histiocytosis in adults: Advances in pathophysiology and treatment. *Cancer Sci* 2018; **109**: 3707-3713 [PMID: [30281871](#) DOI: [10.1111/cas.13817](#)]



Published By Baishideng Publishing Group Inc  
7041 Koll Center Parkway, Suite 160 Pleasanton, CA 94566, USA  
Telephone: +1-925-2238242  
E-mail: [bpgoffice@wjgnet.com](mailto:bpgoffice@wjgnet.com)  
Help Desk: <https://www.f6publishing.com/helpdesk>  
<https://www.wjgnet.com>

