



All

Images

Videos

翻译成中文

开启取词

89,800 Results

Any time ▾

A rare case of primary anterior chest wall pleomorphic ...

www.saudijhealthsci.org/article.asp?issn=2278-0521;year=2014;... ▾

CASE REPORT. Primary **pleomorphic liposarcoma** of the **chest wall** or **mediastinum** is **rare**. Most of the reported cases of the chest wall **liposarcomas** were low-grade well-differentiated **liposarcoma** and/or developed from a subcutaneous **lipoma**. We report a very unique and unusual **case** of primary **pleomorphic liposarcoma** of **anterior** chest wall entrapping...

Published in: [Saudi Journal for Health Sciences](#) - 2014

Authors: [Ghosh](#)

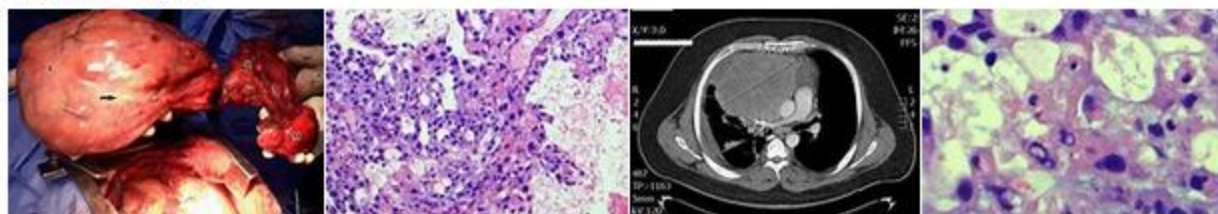
About: [Liposarcoma](#) · [Pleomorphism](#) · [Mediastinum](#)

Case Report The rare mediastinal lipoma: a ... - mafiadoc.com

<https://mafiadoc.com/case-report-the-rare-mediastinal-lipoma-a...> ▾

Jan 30, 2014 - muscular or infiltrating **lipoma**, **angiolipoma**, **pleomorphic lipoma**, **myxoid lipoma**, and atypical **lipoma**. ... In this study, we report a **rare case** of **mediastinal lipoma** in a female cadaver during Gross Anatomy Laboratory dissection for first-year ... **Mediastinal** lipomas typically arise within the **anterior mediastinum**, which is not ...

Images of a rare case of pleomorphic lipoma in the anterior ...

bing.com/images

See more images of a rare case of pleomorphic lipoma in the anterior mediastinum

FULL TEXT - Giant Pleomorphic liposarcoma of anterior ...

www.ijcasereportsandimages.com/archive/2015/010-2015-ijcri/CR... ▾

Liposarcomas in the **mediastinum** are very **rare**, with a reported incidence of less than 1% of all mediastinal tumors. **Pleomorphic liposarcoma** is the least frequent but most malignant histological subtype of **liposarcoma**, which has classical imaging features described in literature. We report a **rare case** of **mediastinal Pleomorphic Liposarcoma** in an adult patient, presenting with atypical imaging ...

Published in: [International Journal of Case Reports and Images](#) - 2015

Authors: [Dandina Mahesh](#) · [Chamarthi Madhavi](#) · [Jaideep Kumar Trivedi](#) · [Vasamsetti Bhusha...](#)

About: [Electronic journal](#) · [Liposarcoma](#) · [Pleomorphism](#)

Match Overview

1	Crossref 40 words Xiaowei Chen. "Fine needle aspiration of pleomorphic lipoma of the neck: Report of two cases", <i>Diagnostic Cytopathol</i>	2%
2	Crossref 17 words Yuqiang Mao, Ran Xu, Xiaoying Liu, Wenjun Shi, Yun Han. "Elevated fibrous sheath interacting protein 1 levels are a ...	1%
3	Internet 12 words crawled on 20-Sep-2014 effiloop.com	1%

Name of Journal: *World Journal of Clinical Cases*

Manuscript NO: 47808

Manuscript Type: CASE REPORT

Pleomorphic lipoma in the anterior mediastinum: A case report

Mao YQ *et al.* Anterior mediastinum pleomorphic lipoma

Yu-Qiang Mao, Xiao-Ying Liu, Yun Han

Abstract

BACKGROUND

Pleomorphic lipoma (PL) is a rare benign mesenchymal tumor occurring predominantly in middle-aged and elderly men. It is typically found in the subcutaneous tissue of the posterior neck, back, and shoulders. There have also been a few reported cases in the face, scalp, and upper extremities. Currently, there is no report on its occurrence in the anterior mediastinum.



国内版 国际版

Pleomorphic lipoma in the anterior mediastinum: A case report



All Images Videos

翻译成中文

关闭取词

104,000 Results Any time ▾

Primary mediastinal liposarcoma: a case report

<https://www.ncbi.nlm.nih.gov/pmc/articles/PMC2222671>

Nov 30, 2007 · **Malignant liposarcoma** develops more commonly in the **posterior mediastinum**.

Liposarcoma of the anterior mediastinum is very rare and only a few **cases** have been **reported** in the **international literature** . **Mediastinal liposarcomas** may extend into the **pleural** spaces and achieve a large size before detection.

Cited by: 16

Author: Nikolaos Barbetakis, Georgios Samanidi...

Publish Year: 2007

Primary mediastinal liposarcoma: a case report | Journal ...

<https://jmedicalcasereports.biomedcentral.com/articles/10.1186/1752-1947-1-161> ▾

Nov 30, 2007 · Discussion. It usually occurs in adults, with most **cases** occur in patients more than 40 years old [1, 2]. **Malignant liposarcoma** develops more commonly in the **posterior mediastinum**.

Liposarcoma of the **anterior mediastinum** is very rare and only a few **cases** have been **reported** in the **international literature** [3].

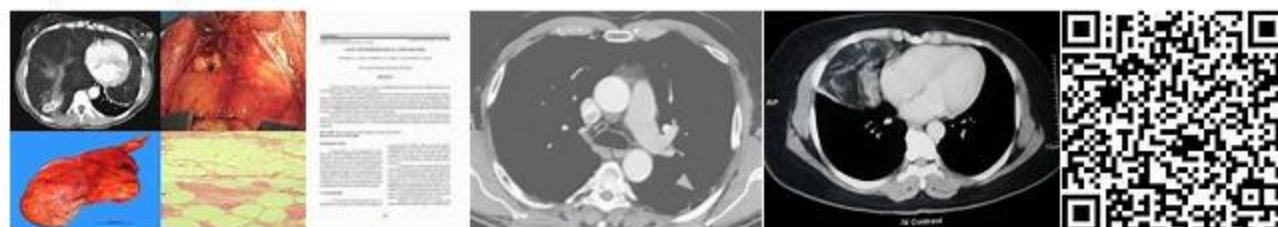
Cited by: 16

Author: Nikolaos Barbetakis, Georgios Samanidi...

Publish Year: 2007

Images of Pleomorphic lipoma in the anterior mediastinum a ...

<bing.com/images>



See more images of Pleomorphic lipoma in the anterior mediastinum a case report

Giant primary liposarcoma of the anterior mediastinum: A ...

https://www.researchgate.net/publication/328361047_Giant_primary_liposarcoma_of_the...

Primary mediastinal liposarcomas are rare **malignancies**, comprising fewer than 1% of all **mediastinal tumors**. We herein **report** a **radical resection** of a **massive liposarcoma** arising from the **anterior** ...