

World Journal of *Clinical Cases*

World J Clin Cases 2019 September 6; 7(17): 2413-2657





MINIREVIEWS

- 2413** Multifocal G1-G2 gastric neuroendocrine tumors: Differentiating between Type I, II and III, a clinicopathologic review
Algashaamy K, Garcia-Buitrago M
- 2420** Attention deficit hyperactivity disorder and comorbidity: A review of literature
Gnanavel S, Sharma P, Kaushal P, Hussain S

ORIGINAL ARTICLE

Case Control Study

- 2427** Dietary manipulation and testosterone replacement therapy may explain changes in body composition after spinal cord injury: A retrospective case report
Gorgey AS, Lester RM, Ghatas MP, Sistrun SN, Lavis T

Retrospective Study

- 2438** Risk factors, clinical features, and short-term prognosis of spontaneous fungal peritonitis in cirrhosis: A matched case-control study
Huang CH, Pang LT, Xu LC, Ge TT, Xu QM, Chen Z
- 2450** Incidence of portal vein thrombosis after splenectomy and its influence on transjugular intrahepatic portosystemic shunt stent patency
Dong F, Luo SH, Zheng LJ, Chu JG, Huang H, Zhang XQ, Yao KC

Observational Study

- 2463** Multiplex gene expression profile in inflamed mucosa of patients with Crohn's disease ileal localization: A pilot study
Giudici F, Lombardelli L, Russo E, Cavalli T, Zambonin D, Logiodice F, Kullolli O, Giusti L, Bargellini T, Fazi M, Biancone L, Scaringi S, Clemente AM, Perissi E, Delfino G, Torcia MG, Ficari F, Tonelli F, Piccinni MP, Malentacchi C

Prospective Study

- 2477** Analysis of the postoperative hemostatic profile of colorectal cancer patients subjected to liver metastasis resection surgery
Perez Navarro G, Pascual Bellosta AM, Ortega Lucea SM, Serradilla Martín M, Ramirez Rodriguez JM, Martinez Ubieta J

SYSTEMATIC REVIEW

- 2487** Systematic review of ablative therapy for the treatment of renal allograft neoplasms
Favi E, Raison N, Ambrogi F, Delbue S, Clementi MC, Lamperti L, Perego M, Bischeri M, Ferraresso M

CASE REPORT

- 2505** Subcutaneous sarcoidosis of the upper and lower extremities: A case report and review of the literature
Mehrzaad R, Festa J, Bhatt R
- 2513** Atypical cutaneous lesions in advanced-stage Hodgkin lymphoma: A case report
Massaro F, Ferrari A, Zendri E, Zanelli M, Merli F
- 2519** Characteristics of multiple nodules in a patient with pulmonary Langerhans cell histiocytosis: A case report
Kanaji N, Tokunaga Y, Ishikawa R, Watanabe N, Kadowaki N
- 2526** Impact of continuous local lavage on pancreatic juice-related postoperative complications: Three case reports
Hori T, Ogawa K, Yamamoto H, Harada H, Matsumura K, Yamamoto M, Yamada M, Yazawa T, Kuriyama K, Tani M, Yasukawa D, Kamada Y, Aisu Y, Tani R, Aoyama R, Nakayama S, Sasaki Y, Nishimoto K, Zaima M
- 2536** Adult intussusception caused by colonic anisakis: A case report
Choi YI, Park DK, Cho HY, Choi SJ, Chung JW, Kim KO, Kwon KA, Kim YJ
- 2542** Robotic-assisted resection of ovarian tumors in children: A case report
Xie XX, Wang N, Wang ZH, Zhu YY, Wang JR, Wang XQ
- 2549** Synovial sarcoma in the plantar region: A case report and literature review
Gao J, Yuan YS, Liu T, Lv HR, Xu HL
- 2556** Severe serous cavity bleeding caused by acquired factor V deficiency associated with lymphatic leakage in a hemodialysis patient: A case report
Zhao WB, Chen YR, Luo D, Lin HC, Long B, Wu ZY, Peng H
- 2562** Supermicrosurgery in fingertip defects-split tibial flap of the second toe to reconstruct multiple fingertip defects: A case report
Wang KL, Zhang ZQ, Buckwalter JA, Yang Y
- 2567** Ultrasound-guided fascia iliaca compartment block combined with general anesthesia for amputation in an acute myocardial infarction patient after percutaneous coronary intervention: A case report
Ling C, Liu XQ, Li YQ, Wen XJ, Hu XD, Yang K
- 2573** Rare spontaneous intrahepatic portosystemic shunt in hepatitis B-induced cirrhosis: A case report
Tan YW, Sheng JH, Tan HY, Sun L, Yin YM
- 2580** Imaging of mixed epithelial and stromal tumor of the kidney: A case report and review of the literature
Ye J, Xu Q, Zheng J, Wang SA, Wu YW, Cai JH, Yuan H
- 2587** Allogenic tooth transplantation using 3D printing: A case report and review of the literature
Xu HD, Miron RJ, Zhang XX, Zhang YF

- 2597** Fecal microbiota transplantation as an effective initial therapy for pancreatitis complicated with severe *Clostridium difficile* infection: A case report
Hu Y, Xiao HY, He C, Lv NH, Zhu L
- 2605** Organ-associated pseudosarcomatous myofibroblastic proliferation with ossification in the lower pole of the kidney mimicking renal pelvic carcinoma: A case report
Zhai TY, Luo BJ, Jia ZK, Zhang ZG, Li X, Li H, Yang JJ
- 2611** Treating aplasia cutis congenita in a newborn with the combination of ionic silver dressing and moist exposed burn ointment: A case report
Lei GF, Zhang JP, Wang XB, You XL, Gao JY, Li XM, Chen ML, Ning XQ, Sun JL
- 2617** Cause of postprandial vomiting - a giant retroperitoneal ganglioneuroma enclosing large blood vessels: A case report
Zheng X, Luo L, Han FG
- 2623** Carcinoma ex pleomorphic adenoma of the trachea: A case report
Gao HX, Li Q, Chang WL, Zhang YL, Wang XZ, Zou XX
- 2630** Wilson disease associated with immune thrombocytopenia: A case report and review of the literature
Ma TJ, Sun GL, Yao F, Yang ZL
- 2637** Calcifying fibrous tumor of the mediastinum: A case report
Qi DJ, Zhang QF
- 2644** Brachiocephalic artery stenting through the carotid artery: A case report and review of the literature
Xu F, Wang F, Liu YS
- 2652** An extremely rare pedunculated lipoma of the hypopharynx: A case report
Sun Q, Zhang CL, Liu ZH

ABOUT COVER

Editorial Board Member of *World Journal of Clinical Cases*, Marianna Luongo, MD, Doctor, Surgeon, Department of Neurosurgery, Azienda Ospedaliera Regionale San Carlo, Potenza 85100, Italy

AIMS AND SCOPE

The primary aim of the *World Journal of Clinical Cases (WJCC)* is to provide scholars and readers from various fields of clinical medicine with a platform to publish high-quality clinical research articles and communicate their research findings online.

The *WJCC* mainly publishes case reports, case series, research results and findings in the field of clinical medicine covering a wide range of topics including diagnostic, therapeutic, and preventive modalities.

INDEXING/ABSTRACTING

The *WJCC* is now indexed in PubMed, PubMed Central, Science Citation Index Expanded (also known as SciSearch®), and Journal Citation Reports/Science Edition. The 2019 Edition of Journal Citation Reports cites the 2018 impact factor for *WJCC* as 1.153 (5-year impact factor: N/A), ranking *WJCC* as 99 among 160 journals in Medicine, General and Internal (quartile in category Q3).

RESPONSIBLE EDITORS FOR THIS ISSUE

Responsible Electronic Editor: *Yan-Xia Xing*

Proofing Production Department Director: *Yun-Xiaojian Wu*

NAME OF JOURNAL

World Journal of Clinical Cases

ISSN

ISSN 2307-8960 (online)

LAUNCH DATE

April 16, 2013

FREQUENCY

Semimonthly

EDITORS-IN-CHIEF

Dennis A Bloomfield, Sandro Vento

EDITORIAL BOARD MEMBERS

<https://www.wjnet.com/2307-8960/editorialboard.htm>

EDITORIAL OFFICE

Jin-Lei Wang, Director

PUBLICATION DATE

September 6, 2019

COPYRIGHT

© 2019 Baishideng Publishing Group Inc

INSTRUCTIONS TO AUTHORS

<https://www.wjnet.com/bpg/gerinfo/204>

GUIDELINES FOR ETHICS DOCUMENTS

<https://www.wjnet.com/bpg/GerInfo/287>

GUIDELINES FOR NON-NATIVE SPEAKERS OF ENGLISH

<https://www.wjnet.com/bpg/gerinfo/240>

PUBLICATION MISCONDUCT

<https://www.wjnet.com/bpg/gerinfo/208>

ARTICLE PROCESSING CHARGE

<https://www.wjnet.com/bpg/gerinfo/242>

STEPS FOR SUBMITTING MANUSCRIPTS

<https://www.wjnet.com/bpg/GerInfo/239>

ONLINE SUBMISSION

<https://www.f6publishing.com>

Fecal microbiota transplantation as an effective initial therapy for pancreatitis complicated with severe *Clostridium difficile* infection: A case report

Yang Hu, Hai-Ying Xiao, Cong He, Nong-Hua Lv, Liang Zhu

ORCID number: Yang Hu (0000-0003-0993-3352); Hai-Ying Xiao (0000-0002-6567-1046); Cong He (0000-0002-1185-5456); Nong-Hua Lv (0000-0003-4373-551X); Liang Zhu (0000-0001-9080-1378).

Author contributions: Xiao HY and Hu Y searched for similar published cases, analyzed the data, and wrote the manuscript; Xiao HY collected the patient's clinical data; Zhu L designed the study; He C performed the fecal microbiota transplantation procedure; He C and Lv NH provided the materials for the study and participated in writing the paper; all authors issued final approval for the version to be submitted.

Supported by Project of Postgraduate Teaching Case Base Construction of Nanchang University, No. 9202-0210210802; Project of Health Commission of Jiangxi Province, No. 20175071; Postgraduate Innovation Fund Project of Nanchang University, No. 2017262.

Conflict-of-interest statement: The authors declare that they have no conflicts of interest.

CARE Checklist (2016) statement: The authors have read the CARE Checklist (2016), and the manuscript was prepared and revised according to the CARE Checklist (2016).

Open-Access: This article is an open-access article which was selected by an in-house editor and fully peer-reviewed by external

Yang Hu, Hai-Ying Xiao, Cong He, Nong-Hua Lv, Liang Zhu, Department of Gastroenterology, The First Affiliated Hospital of Nanchang University, Nanchang 330006, Jiangxi Province, China

Corresponding author: Liang Zhu, MD, PhD, Academic Fellow, Attending Doctor, Doctor, Department of Gastroenterology, The First Affiliated Hospital of Nanchang University, No. 17, Yongwaizheng Street, Nanchang 330006, Jiangxi Province, China. 89493075@qq.com
Telephone: +86-791-88694228
Fax: +86-791-88694228

Abstract

BACKGROUND

Moderately severe acute pancreatitis (MSAP) is a critical form of acute pancreatitis that is related with high morbidity and mortality. Severe *Clostridium difficile* infection (sCDI) is a serious and rare nosocomial diarrheal complication, especially in MSAP patients. Fecal microbiota transplantation (FMT) is a highly effective treatment for refractory and recurrent CDI (rCDI). However, knowledge regarding the initial use of FMT in patients suffering from sCDI is limited.

CASE SUMMARY

Here, we report an MSAP patient complicated with sCDI who was treated by FMT as a first-line therapy. The patient was a 51-year-old man who suffered from diarrhea in his course of acute pancreatitis. An enzyme immunoassay was performed to detect toxins, and the result was positive for toxin-producing *C. difficile* and toxin B and negative for *C. difficile* ribotype 027. The colonoscopy revealed pseudomembranous colitis. Due to these findings, sCDI was our primary consideration. Because the patient provided informed consent for FMT treatment, we initially treated the patient by FMT rather than metronidazole. Diarrhea resolved within 5 d after FMT. The patient remained asymptomatic, and the follow-up colonoscopy performed 40 d after discharge showed a complete recovery. Our case is the first reported in China.

CONCLUSION

This case explores the possibilities of initially using FMT to treat severe CDI. Moreover, FMT may become a critical component of the treatment for severe CDI in MSAP patients.

Key words: Acute pancreatitis; *Clostridium difficile* infection; Fecal microbiota

reviewers. It is distributed in accordance with the Creative Commons Attribution Non Commercial (CC BY-NC 4.0) license, which permits others to distribute, remix, adapt, build upon this work non-commercially, and license their derivative works on different terms, provided the original work is properly cited and the use is non-commercial. See: <http://creativecommons.org/licenses/by-nc/4.0/>

Manuscript source: Unsolicited manuscript

Received: April 9, 2019

Peer-review started: April 10, 2019

First decision: May 9, 2019

Revised: July 2, 2019

Accepted: July 20, 2019

Article in press: July 20, 2019

Published online: September 6, 2019

P-Reviewer: Khuroo MS, Manenti A, Tantau A, Hoff DAL, Neri V

S-Editor: Dou Y

L-Editor: Wang TQ

E-Editor: Zhou BX



transplantation; Pseudomembranous colitis; Initial therapy; Case report

©The Author(s) 2019. Published by Baishideng Publishing Group Inc. All rights reserved.

Core tip: A rare complication of acute pancreatitis is *Clostridium difficile* infection (CDI). Certain antibiotics are used as the treatment of choice for CDI. However, in our case, fecal microbiota transplantation (FMT) was considered the best treatment and achieved good results. This case demonstrates that FMT can be considered a first-line treatment for primary severe CDI in moderately severe acute pancreatitis patients.

Citation: Hu Y, Xiao HY, He C, Lv NH, Zhu L. Fecal microbiota transplantation as an effective initial therapy for pancreatitis complicated with severe *Clostridium difficile* infection: A case report. *World J Clin Cases* 2019; 7(17): 2597-2604

URL: <https://www.wjnet.com/2307-8960/full/v7/i17/2597.htm>

DOI: <https://dx.doi.org/10.12998/wjcc.v7.i17.2597>

INTRODUCTION

Clostridium difficile (*C. difficile*) infection (CDI) is the most common cause of diarrhea in resident patients, and its incidence, morbidity, mortality, and likelihood of recurrence are increasing^[1]. CDI has become an important healthcare-associated infection with a considerable economic impact worldwide. CDI causes post-antibiotic associated diarrhea and colitis from dysbiosis due to the overgrowth of *C. difficile*. Certain antibiotic therapy remains the treatment of choice^[2]. Moderately severe acute pancreatitis (MSAP) is characterized by transient organ failure or local or systemic complications without persistent organ failure^[3]. However, in recent years, fecal microbiota transplantation (FMT) has emerged as a new treatment method that is highly effective for the treatment of recurrent and refractory CDI (rCDI)^[4]. To date, limited data have been available demonstrating that FMT is more cost-effective than some antibiotics as a first-line treatment for the first episode of severe CDI, especially in the treatment of MSAP patients. Here, we report a patient suffering from MSAP with hospital-acquired CDI who was completely cured by FMT after the first CDI episode.

CASE PRESENTATION

Chief complaints

Persistent upper abdominal pain for 5 d.

History of present illness

A 51-year-old man was admitted to our Intensive Care Unit (ICU) after 5 d of persistent severe upper abdominal pain. On day 9 after admission to the hospital, diarrhea developed with a frequency of 4-10 times/d. We stopped all treatments (rhubarb, mirabilite, and mannitol, oral; glycerol enema) that could induce diarrhea and administered montmorillonite and probiotics (Medilac-s, Live Combined Bacillus Subtilis and Enterococcus Faecium Enteric-coated Capsules 500 mg, t.i.d). However, the amount and frequency of diarrhea remained unrelieved.

History of past illness

The patient had a history of chronic consumption of large amounts of alcohol (approximately 80 g/d), had no significant prior medical history, and denied any history of drug use or smoking.

Family history

The patient's family history was unremarkable.

Physical examination upon admission

Upon admission, the physical examination showed a pulse rate of 90 beats per minute, blood pressure of 120/70 mmHg, body temperature of 36.5 °C, and respiration rate of 23 breaths per minute. Pulse oxygen saturation was normal (96%). Moderate tenderness pain in the upper abdomen was observed without rebound

tenderness; the results of bilateral chest percussion revealed dullness, and the lower lung breathing sounds disappeared; and the bedside ultrasound showed bilateral pleural effusion. Heart auscultation did not find anything. No jaundice was observed in the skin and sclera. After diarrhea occurred, rectal palpation was negative. The macroscopic aspects of the stools were yellow water-like stool.

Imaging examinations

Contrast-enhanced computed tomography (CT) showed the following findings: Necrotizing pancreatitis, CT Severity Index (CTSI) level D, and a pancreatic necrotic area < 30% (Figure 1).

Laboratory examinations

The laboratory analysis of the blood tests showed that many inflammatory markers were elevated (Table 1). The stool cultures were negative, and the fecal occult blood test scored 3+. An enzyme immunoassay (EIA) (GeneXpert, Cepheid, America) was performed to detect toxins, and the results were positive for toxin-producing *C. difficile* and toxin B and negative for *C. difficile* ribotype 027.

FINAL DIAGNOSIS

The preliminary combined results indicated MSAP according to the revised Atlanta classification^[3]. Colonoscopy revealed pseudomembranous colitis with yellow pseudomembranes on the wall of the transverse colon and descending colon (Figure 2A). In addition, HE staining revealed the presence of a pseudomembrane composed of an exudate made of inflammatory debris and white blood cells; Gram staining revealed the presence of Gram-positive bacilli. These results combined with the pathological and endoscopic characteristics led to a final diagnosis of pseudomembranous colitis due to severe CDI.

TREATMENT

We administered the routine treatments of fasting, gastric decompression, fluid resuscitation, and early enteral nutrition (EN); moreover, thoracic puncture and drainage were performed. The drugs administered included omeprazole (20 mg iv qd), ulinastatin (10 WU, q8 h, iv), somatostatin (0.5 mg/h, iv), an analgesic (butorphanol tartrate 3 mg/h, iv) as needed, catharsis (rhubarb, mirabilite, and mannitol, oral; glycerol enema), and a subcutaneous insulin injection for hyperglycemia. After these treatments, the patient clearly improved and was moved from the ICU. Because there was no evidence of pancreatic infection, no antibiotics were administered during hospitalization.

After CDI was diagnosed, we performed FMT on hospitalization day 20. The following abnormal laboratory finding was revealed before performing FMT: hemoglobin 116 g/L.

Fresh stool (50 g) from a donor was collected on the day of infusion, diluted with 200 mL sterile saline, and stirred in a blender (NJM-9060; NUC Electronics, Daegu, South Korea). The homogenized solution was filtered twice through a re-sterilized metal sieve. The sample was centrifuged, and the precipitate was dissolved in 200 mL normal saline twice. The final filtrates (200 mL) were infused into the patient *via* a nasal-jejunal tube. Before applying FMT, the patient was provided relevant knowledge and was required to fast for 1 h before the operation and 1 h after the operation. The infusion of the donor feces was performed three times (once every two days).

The stool donor for the FMT was a graduate student, who had no familial relationship with the patient. The donor was negative for blood-borne communicable diseases, and the stool tests were also negative for HBsAg, HCV-Ab, VDRL, HEV-IgM, HIV, CMV, syphilis, *C. difficile* toxin, roundworm, pinworm, hookworm, amoeba, and duovirus. The donor had no history of antibiotic use or any chemotherapy within the past year.

OUTCOME AND FOLLOW-UP

By the day after the second FMT, the frequency of diarrhea had dropped to twice a day, and the diarrhea resolved 5 d after the completion of the FMT process. During the treatment, the patient did not report any adverse events. The patient left the

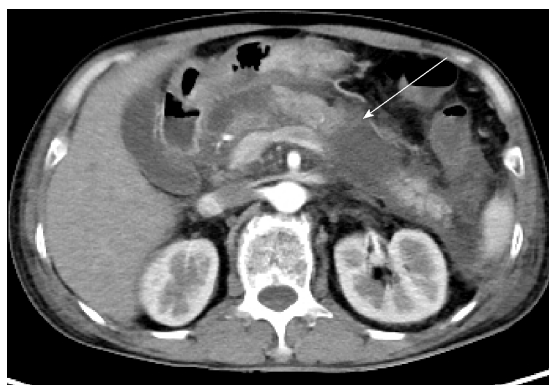


Figure 1 Contrast-enhanced computed tomography revealed necrotizing pancreatitis (as shown by the arrow).

hospital on day 25. After 40 d, a follow-up EIA for toxins did not detect toxin-producing *C. difficile*, toxin B, or *C. difficile* ribotype 027. Meanwhile, the follow-up colonoscopy showed that the bowel was normal (Figure 2B).

DISCUSSION

Our case shows that FMT can be a potential treatment option as a first-line treatment for severe CDI.

The United States data showed that the incidence of CDI had gradually increased from 30 per 100000 in 1996 to 84 per 100000 in 2005^[5]. A cohort study showed that the prevalence of this epidemic in AP patients significantly increased from 386 per 100000 in 1998 to 576 per 100000 in 2012, and CDI increases the mortality of and economic burden on patients with AP^[6]. However, to date, only a few reports of the treatment of CDI in patients with AP have been published.

We speculate that the causes of dysbacteriosis in our patient were as follows: (1) History of excessive alcohol consumption; (2) A hospital stay longer than 7 d for MSAP; (3) Gut barrier dysfunction; and (4) A high carbohydrate intake. We did not perform a confirmation test, which might have revealed a toxigenic culture, because the patient had a very particular diarrhea symptom, endoscopic findings, and positive toxin detection. According to the European Society of Clinical Microbiology and Infectious Diseases (ESCMID)^[7], a two-stage test [glutamate dehydrogenase (GDH) or nucleic acid amplification tests (NAATs) for toxin genes, followed by a highly sensitive toxin test or GDH in combination with a toxin test] is recommended for the diagnosis of CDI. We performed the NAATs (Xpert) and toxin B EIA test, and both tests were positive; thus, we believe that CDI was most likely present. However, we used enteroscopy as another diagnostic tool in this patient because we thought that he might have other causes for the severe diarrhea, which is consistent with the indications for enteroscopy in patients with CDI^[8]. According to the ESCMID guidelines^[9], pseudomembranous colitis can support the diagnosis of severe CDI in our case.

There was no evidence of infection in our AP patient, and antibiotics may result in adverse events, affecting the patient's prognosis and prolonging the hospitalization time. Additionally, FMT is still in the preliminary stage of research at our center and is free of charge. Therefore, FMT was our first choice of treatment for this patient. Various options were discussed in length with the patient and his family. We agree that choosing FMT management instead of antibiotics in primary CDI is controversial. In recent years, with the deepening understanding of the pathogenesis of CDI in the medical community, great changes have been implemented in the management of CDI. Initially, metronidazole was mainly used as a first-line management^[10]. Data before 2000 demonstrated that the proportion of patients receiving metronidazole to achieve a clinical cure was similar to the group of receiving vancomycin. However, recent data show that vancomycin had a significant effect on both symptom relief and a lower recurrence rate^[11]. While antibiotics have been the mainstay of CDI treatment for decades, the increase in CDI frequency, severity, and treatment failures has prompted investigations into the development of alternative therapies that are less disruptive to the colonic microbiota. This effect may be driven by the resistance patterns of the bacteria. FMT is currently an alternative recommended option in select guidelines^[4] due to more and more evidence suggesting efficacy. Unfortunately,

Table 1 Laboratory findings of the patient

Testing item	Results	Reference range
WBC, count/mL	12360	3500-9500
HCT, %	46.9	43-58.0
Serum amylase, IU/L	156	20-110
c(Ca ²⁺), mmol/L	1.79	2.11-2.52
CRP, mg/L	141	<10
Alb, g/L	26.8	40.0-55.0
LDH, U/L	529	120-250
FBG, mmol/L	5.86	3.9-6.1
ESR, mm/h	69	<20
HIV	(-)	(-)
HBsAg	(-)	(-)
HCV-Ab	(-)	(-)

WBC: White blood cells; HCT: Haematocrit; CRP: C-reactive protein; Alb: Albumin; LDH: Lactic dehydrogenase; FBG: Fasting blood-glucose; ESR: erythrocyte sedimentation rate; HIV: Human immunodeficiency virus; HCV: Hepatitis C virus.

because data regarding the use of FMT in initial CDI episodes are limited, FMT is currently recommended only for the treatment of recurrent CDI infections. Based on this background, we discussed the advantages and disadvantages with the patient and obtained written informed consent from the patient and his family. We may consider how to choose drugs if vancomycin gradually lost its current therapeutic effect as metronidazole did, as FMT has no drug resistance problem. The strategy that not all people at risk of or with CDI need enduring antibiotic treatment suggests why FMT is a potential and much needed additional treatment approach. Indeed, more relevant clinical studies are needed to conquer the epidemic.

From an evidence-based perspective, to date, there is insufficient evidence to recommend FMT as an initial treatment for the first episode of CDI^[4]. We searched MEDLINE for articles published in English from 1980 to January 2019 involving human participants that described the use of FMT to treat primary CDI (Table 2). We did not restrict the search on the basis of the study design. We identified 10 patients treated with FMT during initial episodes of CDI, all of which were reported in case study series, and not enough data were published^[12]. Nine patients were a part of a series involving 20 patients initially treated with FMT for primary CDI^[13]; an overall response to treatment was achieved in seven patients in the transplantation group and five patients in the metronidazole group. In one case report, FMT achieved a good effect with no adverse events, although the approaches and methods differed from those used in our patients^[14].

Our report supports the availability of FMT for the management of severe CDI as an initial therapy. In addition, some studies show that FMT is more cost-effective than antimicrobial therapy^[15]. The dramatic effect of FMT shown here provides evidence of the important role of gut microbiota in maintaining homeostasis. There is evidence to support that healthy donors' bacteria can restore the structure and function of the recipients' intestinal microbial community^[16]. FMT can not only eradicate *C. difficile* but also restore the potential defect of the fecal flora.

To the best of our knowledge, this article presents the first report of severe CDI complicating MSAP that was treated successfully *via* FMT in China; this article also presents a rare report of FMT used as a first-line treatment for new-onset severe CDI. As the risks of FMT are small and the potential benefits for severe ill patients are considerable, we advocate that the use of FMT in this patient population is reasonable. Furthermore, FMT may play a role in treating patients with SAP complicated with infections. However, fecal microbiota constitutes a highly complex material, and we do not precisely know which components are beneficial or potentially harmful. More trials assessing FMT as an initial treatment for sCDI are needed.

CONCLUSION

CDI occurs when normal intestinal flora is weakened and induces a severe clinical

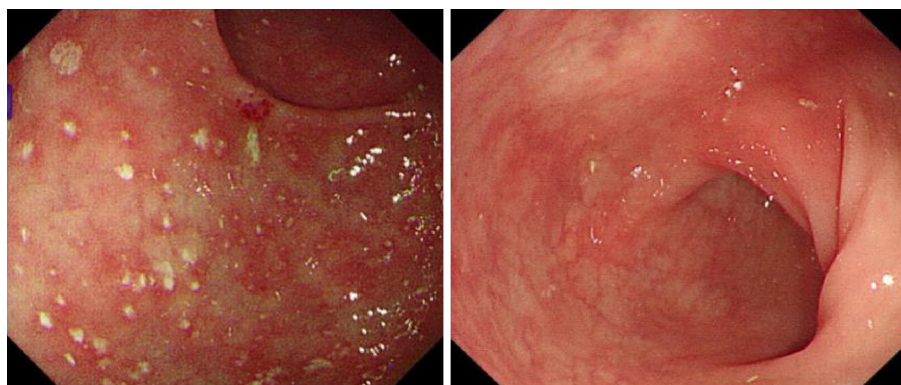


Figure 2 Colonoscopy results. A: Colonoscopy showing the appearance of “pseudomembranes” on the mucosa of the colon; B: Follow-up colonoscopy showing that the bowel was normal.

burden. Our case shows that the possibility of CDI should be considered when abnormal diarrhea occurs in a pancreatitis patient. Furthermore, FMT is equally effective in the initial CDI treatment and may become an alternative to antibiotic therapy in primary *C. difficile* infection, especially in AP patients.

Table 2 Published reports of fecal microbiota transplantation in patients with primary *Clostridium difficile* infection worldwide

Patient	Sex	Age(yr)	Complication	Antibiotics	EIA for toxins	Fecal material delivery	Adverse events
1	M	51	MSAP	-	Positive for toxin-producing <i>C. difficile</i> and toxin B	Nasogastric tube	None
2 ^[16]	F	64	Dental pain and infections	Clindamycin	Positive for <i>C. difficile</i> toxin and GDH	Colonoscopy	None
3 ^[15]	F (4) M (5)	67 (34-88)	-	Yes		Retention enema	(1) A foul smell from the patient's stool; (2) No clinical symptoms but an increase in the CRP levels a few days after treatment

EIA: Enzyme immunoassay; MSAP: Moderately severe acute pancreatitis; GDH: Glutamate dehydrogenase; *C. difficile*: *Clostridium difficile*.

REFERENCES

1. Lessa FC, Winston LG, McDonald LC, Emerging Infections Program *C. difficile* Surveillance Team. Burden of *Clostridium difficile* infection in the United States. *N Engl J Med* 2015; **372**: 2369-2370 [PMID: 26061850 DOI: 10.1056/NEJMc1505190]
2. Peng Z, Ling L, Stratton CW, Li C, Polage CR, Wu B, Tang YW. Advances in the diagnosis and treatment of *Clostridium difficile* infections. *Emerg Microbes Infect* 2018; **7**: 15 [PMID: 29434201 DOI: 10.1038/s41426-017-0019-4]
3. Banks PA, Bollen TL, Dervenis C, Gooszen HG, Johnson CD, Sarr MG, Tsotos GG, Vege SS; Acute Pancreatitis Classification Working Group. Classification of acute pancreatitis--2012: revision of the Atlanta classification and definitions by international consensus. *Gut* 2013; **62**: 102-111 [PMID: 23100216 DOI: 10.1136/gutjnl-2012-302779]
4. Cammarota G, Ianiro G, Tilg H, Rajilić-Stojanović M, Kump P, Satokari R, Sokol H, Arkkila P, Pintos C, Hart A, Segal J, Aloï M, Masucci L, Molinaro A, Scaldaferrì F, Gasbarrini G, Lopez-Sanroman A, Link A, de Groot P, de Vos WM, Högenauer C, Malfertheiner P, Mattila E, Milosavljević T, Nieuwdorp M, Sanguinetti M, Simren M, Gasbarrini A; European FMT Working Group. European consensus conference on faecal microbiota transplantation in clinical practice. *Gut* 2017; **66**: 569-580 [PMID: 28087657 DOI: 10.1136/gutjnl-2016-313017]
5. Kelly CP, LaMont JT. *Clostridium difficile*--more difficult than ever. *N Engl J Med* 2008; **359**: 1932-1940 [PMID: 18971494 DOI: 10.1056/NEJMr0707500]
6. Trikudanathan G, Munigala S. Impact of *Clostridium difficile* infection in patients hospitalized with acute pancreatitis- a population based cohort study. *Pancreatol* 2017; **17**: 201-202 [PMID: 28258934 DOI: 10.1016/j.pan.2017.02.012]
7. Crobach MJ, Planche T, Eckert C, Barbut F, Terveer EM, Dekkers OM, Wilcox MH, Kuijper EJ. European Society of Clinical Microbiology and Infectious Diseases: update of the diagnostic guidance document for *Clostridium difficile* infection. *Clin Microbiol Infect* 2016; **22** Suppl 4: S63-S81 [PMID: 27460910 DOI: 10.1016/j.cmi.2016.03.010]
8. Burkart NE, Kwaan MR, Shepela C, Madoff RD, Wang Y, Rothenberger DA, Melton GB. Indications and Relative Utility of Lower Endoscopy in the Management of *Clostridium difficile* Infection. *Gastroenterol Res Pract* 2011; **2011**: 626582 [PMID: 22028704 DOI: 10.1155/2011/626582]
9. Debast SB, Bauer MP, Kuijper EJ; European Society of Clinical Microbiology and Infectious Diseases. European Society of Clinical Microbiology and Infectious Diseases: update of the treatment guidance document for *Clostridium difficile* infection. *Clin Microbiol Infect* 2014; **20** Suppl 2: 1-26 [PMID: 24118601 DOI: 10.1111/1469-0691.12418]
10. Paknikar R, Pekow J. Fecal Microbiota Transplantation for the Management of *Clostridium difficile* Infection. *Surg Infect (Larchmt)* 2018; **19**: 785-791 [PMID: 30300561 DOI: 10.1089/sur.2018.221]
11. Johnson S, Louie TJ, Gerding DN, Cornely OA, Chasan-Taber S, Fitts D, Gelone SP, Broom C, Davidson DM; Polymer Alternative for CDI Treatment (PACT) investigators. Vancomycin, metronidazole, or tolevamer for *Clostridium difficile* infection: results from two multinational, randomized, controlled trials. *Clin Infect Dis* 2014; **59**: 345-354 [PMID: 24799326 DOI: 10.1093/cid/ciu313]
12. Brandt LJ, Borody TJ, Campbell J. Endoscopic fecal microbiota transplantation: "first-line" treatment for severe *clostridium difficile* infection? *J Clin Gastroenterol* 2011; **45**: 655-657 [PMID: 21716124 DOI: 10.1097/MCG.0b013e3182257d4f]
13. Juul FE, Garborg K, Bretthauer M, Skudal H, Øines MN, Wiig H, Rose Ø, Seip B, Lamont JT, Midtvedt T, Valeur J, Kalager M, Holme Ø, Helsing L, Løberg M, Adami HO. Fecal Microbiota Transplantation for Primary *Clostridium difficile* Infection. *N Engl J Med* 2018; **378**: 2535-2536 [PMID: 29860912 DOI: 10.1056/NEJMc1803103]
14. Tanaka T, Kato H, Fujimoto T. Successful Fecal Microbiota Transplantation as an Initial Therapy for *Clostridium difficile* Infection on an Outpatient Basis. *Intern Med* 2016; **55**: 999-1000 [PMID: 27086820 DOI: 10.2169/internalmedicine.55.5701]
15. Jiang M, Leung NH, Ip M, You JHS. Cost-effectiveness analysis of ribotype-guided fecal microbiota transplantation in Chinese patients with severe *Clostridium difficile* infection. *PLoS One* 2018; **13**:

- e0201539 [PMID: 30048534 DOI: 10.1371/journal.pone.0201539]
- 16 **Seekatz AM**, Aas J, Gessert CE, Rubin TA, Saman DM, Bakken JS, Young VB. Recovery of the gut microbiome following fecal microbiota transplantation. *MBio* 2014; **5**: e00893-e00814 [PMID: 24939885 DOI: 10.1128/mBio.00893-14]



Published By Baishideng Publishing Group Inc
7041 Koll Center Parkway, Suite 160, Pleasanton, CA 94566, USA
Telephone: +1-925-2238242
Fax: +1-925-2238243
E-mail: bpgoffice@wjgnet.com
Help Desk: <https://www.f6publishing.com/helpdesk>
<https://www.wjgnet.com>

