

World Journal of *Clinical Cases*

World J Clin Cases 2019 August 6; 7(15): 1908-2133



**REVIEW**

- 1908** Bone alterations in inflammatory bowel diseases
Sgambato D, Gimigliano F, De Musis C, Moretti A, Toro G, Ferrante E, Miranda A, De Mauro D, Romano L, Iolascon G, Romano M

MINIREVIEWS

- 1926** Extrahepatic hepcidin production: The intriguing outcomes of recent years
Daher R, Lefebvre T, Puy H, Karim Z
- 1937** Neoadjuvant endocrine therapy: A potential strategy for ER-positive breast cancer
Yao LT, Wang MZ, Wang MS, Yu XT, Guo JY, Sun T, Li XY, Xu YY

ORIGINAL ARTICLE**Basic Study**

- 1954** Vestigial like family member 3 is a novel prognostic biomarker for gastric cancer
Zhang LH, Wang Z, Li LH, Liu YK, Jin LF, Qi XW, Zhang C, Wang T, Hua D

Retrospective Study

- 1964** HER2 heterogeneity is a poor prognosticator for HER2-positive gastric cancer
Kaito A, Kuwata T, Tokunaga M, Shitara K, Sato R, Akimoto T, Kinoshita T

Case Control Study

- 1978** Changes in corneal endothelial cell density in patients with primary open-angle glaucoma
Yu ZY, Wu L, Qu B

Observational Study

- 1986** Myocardial bridge-related coronary heart disease: Independent influencing factors and their predicting value
Zhao DH, Fan Q, Ning JX, Wang X, Tian JY
- 1996** Clinical significance and role of up-regulation of SERPINA3 expression in endometrial cancer
Zhou ML, Chen FS, Mao H
- 2003** Evaluation of right ventricular volume and systolic function in normal fetuses using intelligent spatiotemporal image correlation
Sun JX, Cai AL, Xie LM

- 2013** Correlation between intracoronary thrombus components and coronary blood flow after percutaneous coronary intervention for acute myocardial infarction at different onset time
Zhang MJ, Liu X, Liu LH, Li N, Zhang N, Wang YQ, Sun XJ, Huang PH, Yin HM, Liu YH, Zheng H

META-ANALYSIS

- 2022** Performance of common imaging techniques *vs* serum biomarkers in assessing fibrosis in patients with chronic hepatitis B: A systematic review and meta-analysis
Xu XY, Wang WS, Zhang QM, Li JL, Sun JB, Qin TT, Liu HB

CASE REPORT

- 2038** Acute bleeding after argon plasma coagulation for weight regain after gastric bypass: A case report
Moura DTHD, Sachdev AH, Lu PW, Ribeiro IB, Thompson CC
- 2044** Left colonic metastasis from primary hepatocellular carcinoma: A case report
Tagliabue F, Burati M, Chiarelli M, Marando A, Simone MD, Cioffi U
- 2049** ALK-positive anaplastic large cell lymphoma presenting multiple lymphomatous polyposis: A case report and literature review
Saito M, Izumiyama K, Ogasawara R, Mori A, Kondo T, Tanaka M, Morioka M, Miyashita K, Tanino M
- 2058** Modified Tong Xie Yao Fang relieves solitary rectal ulcer syndrome: A case report
Zhang LL, Hao WS, Xu M, Li C, Shi YY
- 2065** Hydrogen gas therapy induced shrinkage of metastatic gallbladder cancer: A case report
Chen JB, Pan ZB, Du DM, Qian W, Ma YY, Mu F, Xu KC
- 2075** Giant nonfunctional ectopic adrenocortical carcinoma on the anterior abdominal wall: A case report
Zhou DK, Liu ZH, Gao BQ, Wang WL
- 2081** Oncogenic osteomalacia caused by a phosphaturic mesenchymal tumor of the femur: A case report
Tang D, Wang XM, Zhang YS, Mi XX
- 2087** Gastric duplication cyst mimicking large cystic lymphangioma in an adult: A rare case report and review of the literature
Xu FY, Sun A, Gan Y, Hu HJ
- 2094** Endometriosis of the duplex appendix: A case report and review of the literature
Zhu MY, Fei FM, Chen J, Zhou ZC, Wu B, Shen YY
- 2103** Fever and neck pain after pacemaker lead extraction: A case report
Wang SX, Bai J, Ma R, Lan RF, Zheng J, Xu W

- 2110** c.753_754delAG, a novel *CFTR* mutation found in a Chinese patient with cystic fibrosis: A case report and review of the literature
Wang YQ, Hao CL, Jiang WJ, Lu YH, Sun HQ, Gao CY, Wu M
- 2120** Common iliac artery occlusion with small intestinal transection caused by blunt abdominal trauma: A case report and review of the literature
Zhou YX, Ji Y, Chen J, Yang X, Zhou Q, Lv J
- 2128** Percutaneous coronary intervention for ostial lesions of the left main stem in a patient with congenital single left coronary artery: A case report
Wu Q, Li ZZ, Yue F, Wei F, Zhang CY

ABOUT COVER

Editorial Board Member of *World Journal of Clinical Cases*, Shu-Pin Huang, MD, Associate Professor, Attending Doctor, Director, Department of Urology, Kaohsiung Medical University, Kaohsiung 807, Taiwan

AIMS AND SCOPE

World Journal of Clinical Cases (*World J Clin Cases*, *WJCC*, online ISSN 2307-8960, DOI: 10.12998) is a peer-reviewed open access academic journal that aims to guide clinical practice and improve diagnostic and therapeutic skills of clinicians.

The primary task of *WJCC* is to rapidly publish high-quality Case Report, Clinical Management, Editorial, Field of Vision, Frontier, Medical Ethics, Original Articles, Meta-Analysis, Minireviews, and Review, in the fields of allergy, anesthesiology, cardiac medicine, clinical genetics, clinical neurology, critical care, dentistry, dermatology, emergency medicine, endocrinology, family medicine, gastroenterology and hepatology, etc.

INDEXING/ABSTRACTING

The *WJCC* is now indexed in PubMed, PubMed Central, Science Citation Index Expanded (also known as SciSearch®), and Journal Citation Reports/Science Edition. The 2019 Edition of Journal Citation Reports cites the 2018 impact factor for *WJCC* as 1.153 (5-year impact factor: N/A), ranking *WJCC* as 99 among 160 journals in Medicine, General and Internal (quartile in category Q3).

RESPONSIBLE EDITORS FOR THIS ISSUE

Responsible Electronic Editor: *Yan-Xia Xing*

Proofing Production Department Director: *Yun-Xiaojuan Wu*

NAME OF JOURNAL

World Journal of Clinical Cases

ISSN

ISSN 2307-8960 (online)

LAUNCH DATE

April 16, 2013

FREQUENCY

Semimonthly

EDITORS-IN-CHIEF

Dennis A Bloomfield, Sandro Vento

EDITORIAL BOARD MEMBERS

<https://www.wjgnet.com/2307-8960/editorialboard.htm>

EDITORIAL OFFICE

Jin-Lei Wang, Director

PUBLICATION DATE

August 6, 2019

COPYRIGHT

© 2019 Baishideng Publishing Group Inc

INSTRUCTIONS TO AUTHORS

<https://www.wjgnet.com/bpg/gerinfo/204>

GUIDELINES FOR ETHICS DOCUMENTS

<https://www.wjgnet.com/bpg/GerInfo/287>

GUIDELINES FOR NON-NATIVE SPEAKERS OF ENGLISH

<https://www.wjgnet.com/bpg/gerinfo/240>

PUBLICATION MISCONDUCT

<https://www.wjgnet.com/bpg/gerinfo/208>

ARTICLE PROCESSING CHARGE

<https://www.wjgnet.com/bpg/gerinfo/242>

STEPS FOR SUBMITTING MANUSCRIPTS

<https://www.wjgnet.com/bpg/GerInfo/239>

ONLINE SUBMISSION

<https://www.f6publishing.com>

Giant nonfunctional ectopic adrenocortical carcinoma on the anterior abdominal wall: A case report

Dong-Kai Zhou, Zheng-Hao Liu, Bing-Qiang Gao, Wei-Lin Wang

ORCID number: Dong-Kai Zhou (0000-0003-0705-9796); Zheng-Hao Liu (0000-0002-2748-0775); Bing-Qiang Gao (0000-0002-1265-0217); Wei-Lin Wang (0000-0001-9432-2649).

Author contributions: Zhou DK wrote the manuscript; Liu ZH collected case data and prepared the photos; Gao BQ, and Wang WL proofread and revised the manuscript; all of the authors approved the final version to be published.

Supported by The National Natural Science Foundation of China, No. 81572307 and No. 81773096.

Informed consent statement: Informed consent was obtained from the patient.

Conflict-of-interest statement: The authors declare that there is no conflict of interest related to this report.

CARE Checklist (2016) statement: Guidelines of the CARE Checklist (2016) have been adopted while writing this manuscript.

Open-Access: This article is an open-access article which was selected by an in-house editor and fully peer-reviewed by external reviewers. It is distributed in accordance with the Creative Commons Attribution Non Commercial (CC BY-NC 4.0) license, which permits others to distribute, remix, adapt, build upon this work non-commercially, and license their derivative works on different terms, provided the original work is properly cited and

Dong-Kai Zhou, Zheng-Hao Liu, Bing-Qiang Gao, Wei-Lin Wang, Department of Hepatobiliary and Pancreatic Surgery, The Second Affiliated Hospital, School of Medicine, Zhejiang University, Hangzhou 310003, Zhejiang Province, China

Dong-Kai Zhou, Zheng-Hao Liu, Bing-Qiang Gao, Wei-Lin Wang, Key Laboratory of Precision Diagnosis and Treatment for Hepatobiliary and Pancreatic Tumor of Zhejiang Province, The First Affiliated Hospital, School of Medicine, Zhejiang University, Hangzhou 310003, Zhejiang Province, China

Dong-Kai Zhou, Zheng-Hao Liu, Bing-Qiang Gao, Wei-Lin Wang, Clinical Research Center of Hepatobiliary and Pancreatic Diseases of Zhejiang Province, The First Affiliated Hospital, School of Medicine, Zhejiang University, Hangzhou 310003, Zhejiang Province, China

Corresponding author: Wei-Lin Wang, MD, PhD, Doctor, Department of Hepatobiliary and Pancreatic Surgery, The Second Affiliated Hospital, School of Medicine, Zhejiang University, No.88 Jiefang Road, Hangzhou 310003, Zhejiang Province, China. wam@zju.edu.cn

Telephone: +86-571-87315003

Fax: +86-571-87022776

Abstract

BACKGROUND

Adrenocortical cancer (ACC) is an infrequent and often aggressive malignancy with a very poor prognosis. It can be classified as functional or nonfunctional. Nonfunctional ACC is hampered by the absence of specific signs or symptoms; only abdominal pain with or without incidental adrenal occupation is typically present.

CASE SUMMARY

We report a rare case of a patient with a 30 cm × 15 cm × 8 cm ectopic ACC on the anterior abdominal wall without organ adhesion. A 77-year-old male was admitted to our hospital because of a huge abdominal mass, which, by ultrasonography, had an unclear border with the liver. Computed tomography showed that the mass was not associated with any organ but was adherent to the anterior abdominal wall. The patient underwent tumor resection, and a postoperative pathology examination showed a neuroendocrine tumor, which was diagnosed as ACC. The patient was disease-free at the 9-mo follow up.

CONCLUSION

The anterior abdominal wall is a rare site of ACC growth.

Key words: Adrenocortical carcinoma; Nonfunctional; Ectopic; Abdominal wall; Case

the use is non-commercial. See:
<http://creativecommons.org/licenses/by-nc/4.0/>

Manuscript source: Unsolicited manuscript

Received: April 15, 2019

Peer-review started: April 15, 2019

First decision: May 31, 2019

Revised: June 28, 2019

Accepted: July 3, 2019

Article in press: July 3, 2019

Published online: August 6, 2019

P-Reviewer: Chen YY, Isik A

S-Editor: Dou Y

L-Editor: Wang TQ

E-Editor: Wu YXJ



report

©The Author(s) 2019. Published by Baishideng Publishing Group Inc. All rights reserved.

Core tip: Aberrant adrenal tissue can be found anywhere, but typically in the testes, ovaries, spermatic cord, and kidneys. The most common site is retroperitoneal fat near the adrenal gland; the bilateral lungs, liver, spleen, pancreas, colon, duodenum, and ovary are less common. This is, to our knowledge, the first report of adrenocortical cancer on the anterior abdominal wall in the English-language literature.

Citation: Zhou DK, Liu ZH, Gao BQ, Wang WL. Giant nonfunctional ectopic adrenocortical carcinoma on the anterior abdominal wall: A case report. *World J Clin Cases* 2019; 7(15): 2075-2080

URL: <https://www.wjgnet.com/2307-8960/full/v7/i15/2075.htm>

DOI: <https://dx.doi.org/10.12998/wjcc.v7.i15.2075>

INTRODUCTION

Adrenocortical cancer (ACC) is an infrequent and often aggressive malignancy with a very poor prognosis. According to the Surveillance, Epidemiology and End Results database, ACC has an annual incidence of 0.7-2 per million population^[1] and a bimodal age distribution with peaks before 5 years of age and at 40-60 years of age^[2].

ACC can be classified as functional or nonfunctional. The early diagnosis and treatment of nonfunctional ACC is hampered by the absence of specific signs or symptoms; only abdominal pain with or without incidental adrenal occupation is typically present. Based on its cost-effectiveness, the American Association of Clinical Endocrinologists guidelines recommend surgery for nonfunctional ACC lesions ≥ 4 cm in diameter^[3]. Here, we report the case of a patient with ACC on the abdominal wall. The patient underwent tumor resection and was disease-free at the 9-mo follow up.

CASE PRESENTATION

Chief complaints

A 77-year-old male (body mass index, 24.5 kg/m²), who 9 mo previously had been admitted to our hepatological surgery department, presented with an enormous exogenous liver occupation that had been detected by ultrasonography in a community hospital 2 d prior. He denied having abdominal pain, nausea, anorexia, or changes in bowel habit.

History of present illness

The patient had no clinical symptoms associated with steroid excess, except for hypertension. He was admitted to our department for diagnosis.

History of past illness

The patient had suffered from hypertension for 40 years but did not have diabetes or cardiovascular disease.

Personal and family history

His medical history and family history were unremarkable.

Physical examination

The results of a physical examination were unremarkable, except for a palpable hard mass and slight tenderness in the hepatic region.

Laboratory examinations

The results of laboratory tests were as follows: CA199, 112.0 U/mL (reference < 37.0 U/mL); alpha fetoprotein, 1.4 ng/mL (reference < 20.0 ng/mL); alanine transaminase, 89 U/L (reference < 35.0 U/L); aspartate transaminase, 49 U/L (reference < 40 U/L); and serum potassium, 4.40 mmol/L (reference 3.50-5.20 mmol/L). The results of the endocrine work-up were negative.

Imaging examinations

Ultrasonography revealed an enormous space-occupying lesion in the right upper abdomen, in which Color Doppler flow imaging showed a small amount of blood flow (Figure 1A). A left-hepatic origin was considered, but contrast-enhanced computed tomography (CT) showed an irregular fat-containing mass in the right upper abdominal cavity of uneven density with an obscure boundary (Figure 1B). The tumor exhibited heterogeneous enhancement in the arterial phase (Figure 1C) and delayed enhancement in the venous phase (Figure 1D).

TREATMENT

A laparotomy was performed. During surgery, a 30 cm × 15 cm × 8 cm tumor was found above the hepatic curvature of the colon in front of the right posterior peritoneum (Figure 2). The liver, pancreas, stomach, colon, and adrenal gland were not infringed, and there was no lymph-node metastasis. The tumor had invaded the local right-abdominal musculature.

FINAL DIAGNOSIS

A postoperative pathology examination indicated that the tumor was hypo-differentiated carcinoma with neuroendocrinalization and so was considered to be ACC. A histopathology examination showed a Weiss score of 6, as cells were distributed in sheets and wide bands, and extensive necrosis was present. The cytoplasm was eosinophilic, the karyotype was irregular, and giant neoplastic cells were present (Figure 3A). The Ki-67 labeling index was > 80% (Figure 3B), and the tumor cells were positive for melan A, vimentin, synaptophysin (Figure 3C-E), CK20, insulin-like growth factor-2 (IGF-2), and EMA; and negative for CK (pan), inhibin a, CgA, and S-100.

OUTCOME AND FOLLOW-UP

The patient underwent regular follow ups involving a physical examination, laboratory testing, and X-ray and CT imaging. He was disease-free at the 9-mo follow up.

DISCUSSION

ACC is a rare malignancy, accounting for about 0.05%-0.2% of all malignant tumors, and has an annual incidence of 1-2 per million^[4]. Ectopic adrenal tissue is commonly found in infants and children, but it is less common in adults^[5]. ACC is the second most aggressive malignant endocrine tumor after anaplastic thyroid cancer^[6]. Aberrant adrenal tissue can be found anywhere, but typically in the testes, ovaries, spermatic cord, and kidneys^[6]. The most common site is retroperitoneal fat near the adrenal gland^[7,8]; the bilateral lungs^[9], liver^[7], spleen^[8], pancreas^[8], colon^[8], duodenum^[8], and ovary^[6] are less common. This is, to our knowledge, the first report of ACC on the anterior abdominal wall in the English-language literature.

The clinical symptoms of primary ACC are dependent on the functional state and volume of the tumor. Around half of patients with ACC are asymptomatic or have symptoms caused by mechanical effects of tumor growth^[2], such as abdominal pain, nausea, poor appetite, and back pain^[1]. The other half of patients with ACC have symptoms related to elevated levels of steroid hormones-Cushing syndrome, Con syndrome, and feminization. ACC lesions are typically large as they grow rapidly; most are 10-13 cm in diameter, 9%-14% are < 6 cm, and 3% are < 4 cm^[1,10,11]. Generally, nonfunctional ACC lesions are small; large nonfunctional ACC lesions are very rare^[12].

The pathogenesis of ACC is unclear but is likely to involve IGF-2, tumor protein 53, and β -catenin. ACC can be diagnosed with 100% specificity and 96% sensitivity based on the levels of IGF-2 and Ki-67^[13].

Imaging (magnetic resonance imaging or CT) is crucial for identifying adrenal involvement in ACC. In general, ACC is a non-homogeneous tumor with hemorrhage or necrosis and an irregular margin. Nuclear aberrations-comprising a high mitotic count, high nuclear grade, and bizarre mitotic figures—are characteristic histological findings of ACC^[13].

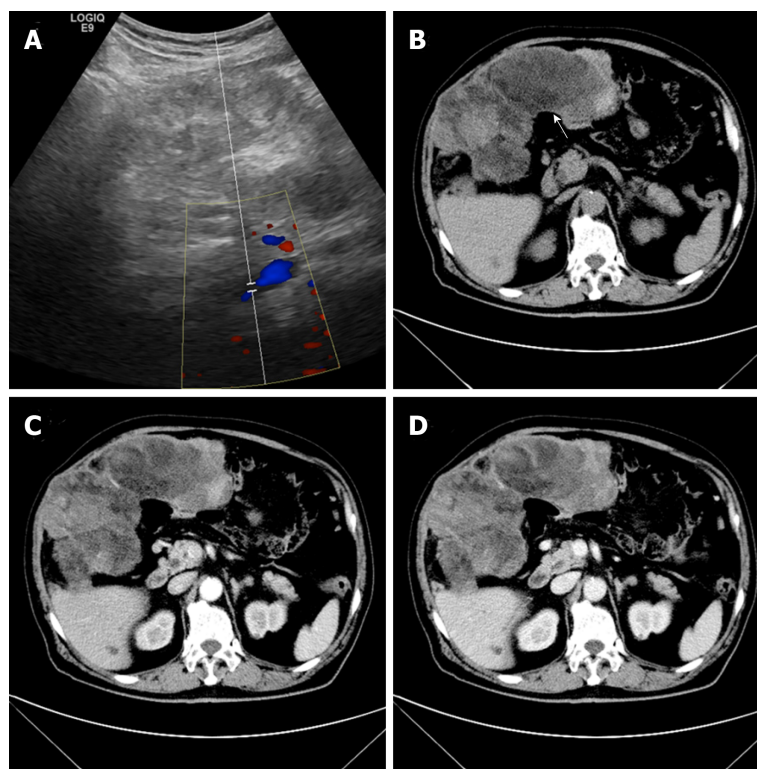


Figure 1 Imaging diagnosis. A: Color Doppler image showing blood flow; B: Computed tomography with contrast (white arrow, fat density); C: Uneven heterogeneous enhancement in the arterial phase; D: Delayed enhancement in the venous phase.

Complete surgical resection is the only potentially curative therapy for ACC; And it is equally important to choose surgical indications according to the latest guidelines for the surgeon^[14]. Indeed, complete resection is the most accurate predictor of the outcome. Paton *et al*^[11] reported that patients who have complete resection have a higher 5-year survival rate than those who have incomplete resection. In the retrospective study of Terzolo *et al*^[15], use of mitotane as adjunct therapy reduced the rates of recurrence and mortality, as did etoposide, doxorubicin and cisplatin plus mitotane, streptozotocin plus mitotane, and gemcitabine plus capecitabine^[1,16].

The 5-year overall survival rate of patients with ACC is 37%-47%^[1]. For advanced ACC, (*i.e.*, stage III tumor), the mENS[®]T TNM classification - which comprises the "GRAF" components: grade (G), resection status (R), age (A), and functioning symptoms at diagnosis (defined as tumor or hormone-related symptoms) (F) - is recommended^[17]. Rupture of the tumor capsule, metastasis, and a high Ki67 index are associated with reduced disease-free and overall survival.

CONCLUSION

ACC is rare and has a poor prognosis. The 5-year overall survival rate of patients with ACC is 37%-47%, and resection is the optimum treatment modality. We describe a case of a patient with ectopic adrenocortical carcinoma on the anterior abdominal wall and our patient was disease-free at 9 mo after resection of the tumor.

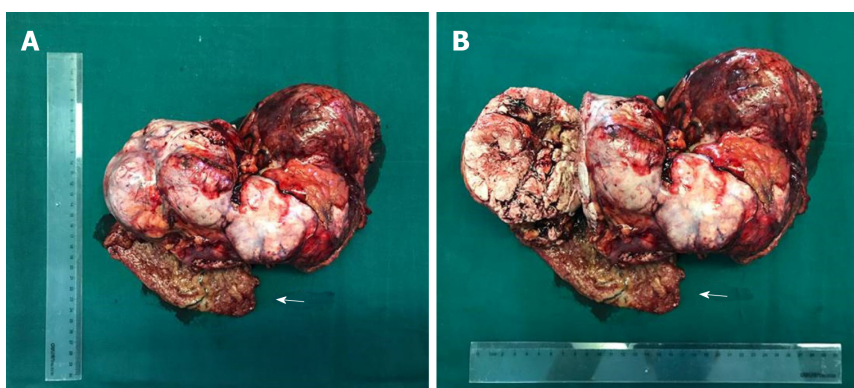


Figure 2 The 30 cm × 15 cm × 8 cm heterogeneous tumor with necrosis (A, B). Arrows invaded abdominal wall tissue.

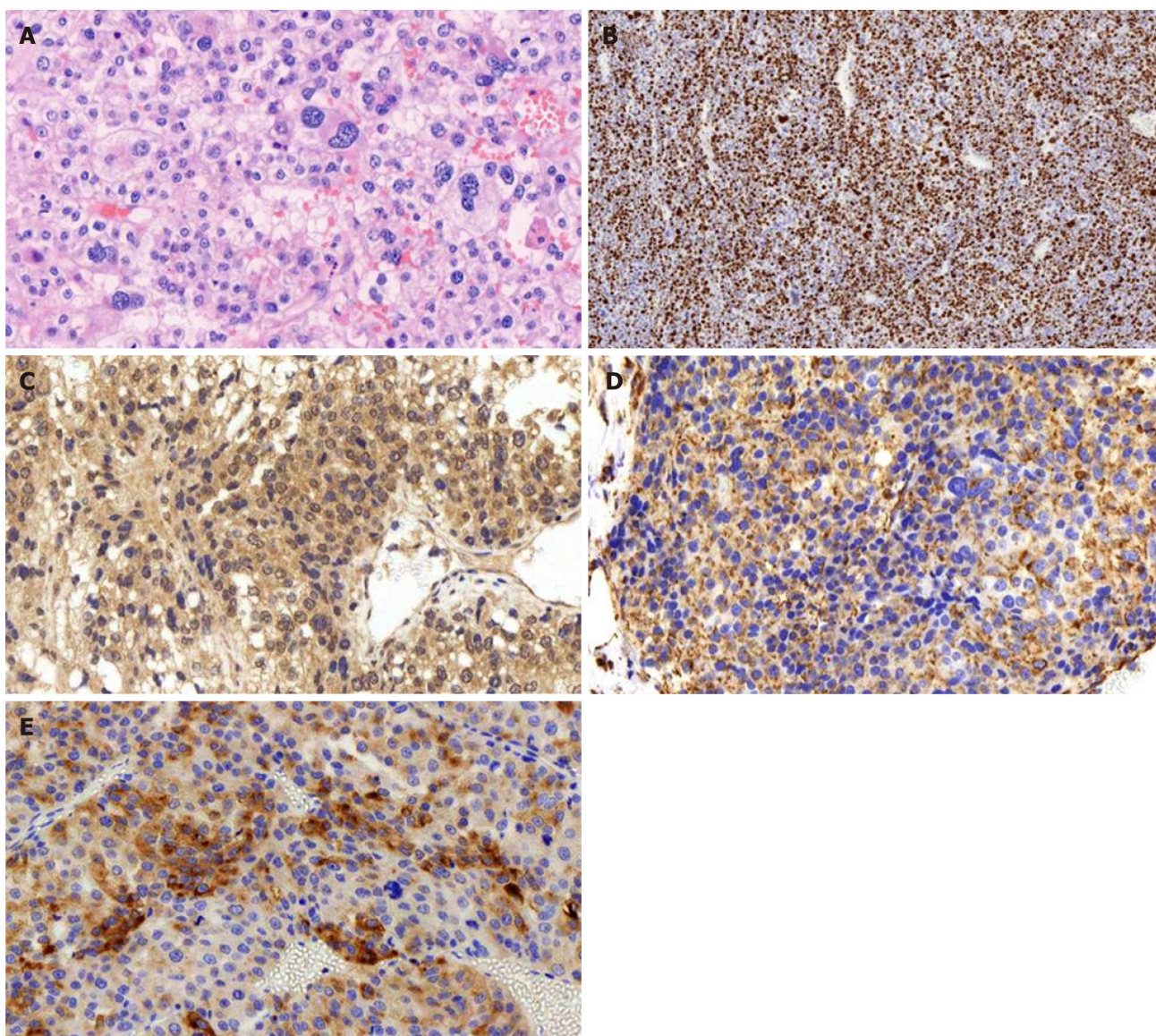


Figure 3 Histological staining. A: Histological staining showing significant nuclear atypia, necrosis, and pleomorphism of the tumor cells (magnification, 200×); B: The Ki-67 labeling index was > 80% (IHC staining; magnification, 50×); C-D: Positive IHC staining for (C) melan-A, (D) vimentin and (E) synaptophysin (magnification, 200×).

REFERENCES

- 1 **Fassnacht M**, Libé R, Kroiss M, Allolio B. Adrenocortical carcinoma: a clinician's update. *Nat Rev Endocrinol* 2011; **7**: 323-335 [PMID: [21386792](#) DOI: [10.1038/nrendo.2010.235](#)]
- 2 **Lam AK**. Update on Adrenal Tumours in 2017 World Health Organization (WHO) of Endocrine Tumours. *Endocr Pathol* 2017; **28**: 213-227 [PMID: [28477311](#) DOI: [10.1007/s12022-017-9484-5](#)]
- 3 **Wang TS**, Cheung K, Roman SA, Sosa JA. A cost-effectiveness analysis of adrenalectomy for nonfunctional adrenal incidentalomas: is there a size threshold for resection? *Surgery* 2012; **152**: 1125-1132 [PMID: [22989893](#) DOI: [10.1016/j.surg.2012.08.011](#)]
- 4 **Libé R**. Adrenocortical carcinoma (ACC): diagnosis, prognosis, and treatment. *Front Cell Dev Biol* 2015; **3**: 45 [PMID: [26191527](#) DOI: [10.3389/fcell.2015.00045](#)]
- 5 **Ayala AR**, Basaria S, Udelsman R, Westra WH, Wand GS. Corticotropin-independent Cushing's syndrome caused by an ectopic adrenal adenoma. *J Clin Endocrinol Metab* 2000; **85**: 2903-2906 [PMID: [10946901](#) DOI: [10.1210/jcem.85.8.6749](#)]
- 6 **Chentli F**, Terki N, Azzoug S. Ectopic adrenocortical carcinoma located in the ovary. *Eur J Endocrinol* 2016; **175**: K17-K23 [PMID: [27523914](#) DOI: [10.1530/EJE-16-0224](#)]
- 7 **Park WY**, Seo HI, Choi KU, Kim A, Kim YK, Lee SJ, Lee CH, Huh GY, Park DY. Three cases of adrenocortical tumors mistaken for hepatocellular carcinomas/diagnostic pitfalls and differential diagnosis. *Ann Diagn Pathol* 2017; **31**: 9-13 [PMID: [29146062](#) DOI: [10.1016/j.anndiagpath.2017.05.016](#)]
- 8 **Marincola Smith P**, Kiernan CM, Tran TB, Postlewait LM, Maithe SK, Prescott J, Pawlik T, Wang TS, Glenn J, Hatzaras I, Shenoy R, Phay J, Shirley LA, Fields RC, Jin L, Weber S, Salem A, Sicklick J, Gad S, Yopp A, Mansour J, Duh QY, Seiser N, Votanopoulos K, Levine EA, Poultsides G, Solórzano CC. Role of Additional Organ Resection in Adrenocortical Carcinoma: Analysis of 167 Patients from the U.S. Adrenocortical Carcinoma Database. *Ann Surg Oncol* 2018; **25**: 2308-2315 [PMID: [29868977](#) DOI: [10.1245/s10434-018-6546-y](#)]
- 9 **Arora S**, Damle NA, Aggarwal S, Passah A, Behera A, Arora G, Bal C, Tripathi M. Prostate-Specific Membrane Antigen Expression in Adrenocortical Carcinoma on 68Ga-Prostate-Specific Membrane Antigen PET/CT. *Clin Nucl Med* 2018; **43**: 449-451 [PMID: [29578871](#) DOI: [10.1097/RLU.0000000000002064](#)]
- 10 **Sturgeon C**, Shen WT, Clark OH, Duh QY, Kebebew E. Risk assessment in 457 adrenal cortical carcinomas: how much does tumor size predict the likelihood of malignancy? *J Am Coll Surg* 2006; **202**: 423-430 [PMID: [16500246](#) DOI: [10.1016/j.jamcollsurg.2005.11.005](#)]
- 11 **Paton BL**, Novitsky YW, Zerey M, Harrell AG, Norton HJ, Asbun H, Kercher KW, Heniford BT. Outcomes of adrenal cortical carcinoma in the United States. *Surgery* 2006; **140**: 914-20; discussion 919-20 [PMID: [17188138](#) DOI: [10.1016/j.surg.2006.07.035](#)]
- 12 **Tauchmanová L**, Colao A, Marzano LA, Sparano L, Camera L, Rossi A, Palmieri G, Marzano E, Salvatore M, Pettinato G, Lombardi G, Rossi R. Adrenocortical carcinomas: twelve-year prospective experience. *World J Surg* 2004; **28**: 896-903 [PMID: [15593464](#) DOI: [10.1007/s00268-004-7296-5](#)]
- 13 **Lerario AM**, Moraitis A, Hammer GD. Genetics and epigenetics of adrenocortical tumors. *Mol Cell Endocrinol* 2014; **386**: 67-84 [PMID: [24220673](#) DOI: [10.1016/j.mce.2013.10.028](#)]
- 14 **Isik A**, Firat D, Yilmaz I, Peker K, Idiz O, Yilmaz B, Demiryilmaz I, Celebi F. A survey of current approaches to thyroid nodules and thyroid operations. *Int J Surg* 2018; **54**: 100-104 [PMID: [29709542](#) DOI: [10.1016/j.ijsu.2018.04.037](#)]
- 15 **Terzolo M**, Angeli A, Fassnacht M, Daffara F, Tauchmanova L, Conton PA, Rossetto R, Buci L, Sperone P, Grossrubatscher E, Reimondo G, Bollito E, Papotti M, Saeger W, Hahner S, Koschker AC, Arvat E, Ambrosi B, Loli P, Lombardi G, Mannelli M, Bruzzi P, Mantero F, Allolio B, Dogliotti L, Berruti A. Adjuvant mitotane treatment for adrenocortical carcinoma. *N Engl J Med* 2007; **356**: 2372-2380 [PMID: [17554118](#) DOI: [10.1056/NEJMoa063360](#)]
- 16 **Henning JEK**, Deutschbein T, Altieri B, Steinhauer S, Kircher S, Sbiera S, Wild V, Schlötelburg W, Kroiss M, Perotti P, Rosenwald A, Berruti A, Fassnacht M, Ronchi CL. Gemcitabine-Based Chemotherapy in Adrenocortical Carcinoma: A Multicenter Study of Efficacy and Predictive Factors. *J Clin Endocrinol Metab* 2017; **102**: 4323-4332 [PMID: [29092062](#) DOI: [10.1210/jc.2017-01624](#)]
- 17 **Libé R**, Borget I, Ronchi CL, Zaggia B, Kroiss M, Kerkhofs T, Bertherat J, Volante M, Quinkler M, Chabre O, Bala M, Tabarin A, Beuschlein F, Vezzosi D, Deutschbein T, Borson-Chazot F, Hermesen I, Stell A, Fottner C, Leboulloux S, Hahner S, Mannelli M, Berruti A, Haak H, Terzolo M, Fassnacht M, Baudin E; ENSAT network. Prognostic factors in stage III-IV adrenocortical carcinomas (ACC): an European Network for the Study of Adrenal Tumor (ENSAT) study. *Ann Oncol* 2015; **26**: 2119-2125 [PMID: [26392430](#) DOI: [10.1093/annonc/mdv329](#)]



Published By Baishideng Publishing Group Inc
7041 Koll Center Parkway, Suite 160, Pleasanton, CA 94566, USA
Telephone: +1-925-2238242
Fax: +1-925-2238243
E-mail: bpgoffice@wjgnet.com
Help Desk: <https://www.f6publishing.com/helpdesk>
<https://www.wjgnet.com>

