

World Journal of *Gastroenterology*

World J Gastroenterol 2019 October 21; 25(39): 5897-6040



**REVIEW**

- 5897** Gut-liver axis signaling in portal hypertension
Simbrunner B, Mandorfer M, Trauner M, Reiberger T

ORIGINAL ARTICLE**Basic Study**

- 5918** Role of tristetraproline phosphorylation in paediatric patients with inflammatory bowel disease
Di Silvestre A, Lucafò M, Pugnetti L, Bramuzzo M, Stocco G, Barbi E, Decorti G
- 5926** STW 5 is effective against nonsteroidal anti-inflammatory drugs induced gastro-duodenal lesions in rats
Khayyal MT, Wadie W, Abd El-Haleim EA, Ahmed KA, Kelber O, Ammar RM, Abdel-Aziz H
- 5936** Superior gallstone dissolubility and safety of tert-amyl ethyl ether over methyl-tertiary butyl ether
You DD, Cho SJ, Kim OH, Song JS, Hwang KS, Lee SC, Kim KH, Choi HJ, Hong HE, Seo H, Hong TH, Park JH, Lee TY, Ahn J, Jung JK, Jung KY, Kim SJ
- 5953** Gender differences in vascular reactivity of mesenteric arterioles in portal hypertensive and non-portal hypertensive rats
Zhang B, Ji LH, Zhang CG, Zhao G, Wu ZY
- 5961** Construction of a replication-competent hepatitis B virus vector carrying secreted luciferase transgene and establishment of new hepatitis B virus replication and expression cell lines
Ruan J, Ping CY, Sun S, Cheng X, Han PY, Zhang YG, Sun DX
- 5973** Differentially expressed long noncoding RNAs and regulatory mechanism of LINC02407 in human gastric adenocarcinoma
Zhou LL, Jiao Y, Chen HM, Kang LH, Yang Q, Li J, Guan M, Zhu G, Liu FQ, Wang S, Bai X, Song YQ

Retrospective Study

- 5991** Retrospective study on mixed neuroendocrine non-neuroendocrine neoplasms from five European centres
Frizziero M, Wang X, Chakrabarty B, Childs A, Luong TV, Walter T, Khan MS, Morgan M, Christian A, Elshafie M, Shah T, Minicozzi A, Mansoor W, Meyer T, Lamarca A, Hubner RA, Valle JW, McNamara MG
- 6006** Recurrence and survival after surgery for pancreatic cancer with or without acute pancreatitis
Feng Q, Li C, Zhang S, Tan CL, Mai G, Liu XB, Chen YH

SYSTEMATIC REVIEW

- 6016** Complete or partial split in associating liver partition and portal vein ligation for staged hepatectomy: A systematic review and meta-analysis
Huang HC, Bian J, Bai Y, Lu X, Xu YY, Sang XT, Zhao HT

META-ANALYSIS

- 6025** Allicin as add-on therapy for *Helicobacter pylori* infection: A systematic review and meta-analysis
Si XB, Zhang XM, Wang S, Lan Y, Zhang S, Huo LY

ABOUT COVER

Editorial board member of *World Journal of Gastroenterology*, Kazuaki Inoue, MD, PhD, Associate Professor, Department of Internal Medicine, Division of Gastroenterology, Showa University Fujigaoka Hospital, Yokohama 227-8501, Japan

AIMS AND SCOPE

The primary aim of *World Journal of Gastroenterology* (WJG, *World J Gastroenterol*) is to provide scholars and readers from various fields of gastroenterology and hepatology with a platform to publish high-quality basic and clinical research articles and communicate their research findings online.

WJG mainly publishes articles reporting research results and findings obtained in the field of gastroenterology and hepatology and covering a wide range of topics including gastroenterology, hepatology, gastrointestinal endoscopy, gastrointestinal surgery, gastrointestinal oncology, and pediatric gastroenterology.

INDEXING/ABSTRACTING

The WJG is now indexed in Current Contents®/Clinical Medicine, Science Citation Index Expanded (also known as SciSearch®), Journal Citation Reports®, Index Medicus, MEDLINE, PubMed, PubMed Central, and Scopus. The 2019 edition of Journal Citation Report® cites the 2018 impact factor for WJG as 3.411 (5-year impact factor: 3.579), ranking WJG as 35th among 84 journals in gastroenterology and hepatology (quartile in category Q2). CiteScore (2018): 3.43.

RESPONSIBLE EDITORS FOR THIS ISSUE

Responsible Electronic Editor: *Yu-Jie Ma*

Proofing Production Department Director: *Yun-Xiaojuan Wu*

NAME OF JOURNAL

World Journal of Gastroenterology

ISSN

ISSN 1007-9327 (print) ISSN 2219-2840 (online)

LAUNCH DATE

October 1, 1995

FREQUENCY

Weekly

EDITORS-IN-CHIEF

Subrata Ghosh, Andrzej S Tarnawski

EDITORIAL BOARD MEMBERS

<http://www.wjgnet.com/1007-9327/editorialboard.htm>

EDITORIAL OFFICE

Ze-Mao Gong, Director

PUBLICATION DATE

October 21, 2019

COPYRIGHT

© 2019 Baishideng Publishing Group Inc

INSTRUCTIONS TO AUTHORS

<https://www.wjgnet.com/bpg/gerinfo/204>

GUIDELINES FOR ETHICS DOCUMENTS

<https://www.wjgnet.com/bpg/GerInfo/287>

GUIDELINES FOR NON-NATIVE SPEAKERS OF ENGLISH

<https://www.wjgnet.com/bpg/gerinfo/240>

PUBLICATION MISCONDUCT

<https://www.wjgnet.com/bpg/gerinfo/208>

ARTICLE PROCESSING CHARGE

<https://www.wjgnet.com/bpg/gerinfo/242>

STEPS FOR SUBMITTING MANUSCRIPTS

<https://www.wjgnet.com/bpg/GerInfo/239>

ONLINE SUBMISSION

<https://www.f6publishing.com>

Basic Study

STW 5 is effective against nonsteroidal anti-inflammatory drugs induced gastro-duodenal lesions in rats

Mohamed T Khayyal, Walaa Wadie, Enas A Abd El-Haleim, Kawkab A Ahmed, Olaf Kelber, Ramy M Ammar, Heba Abdel-Aziz

ORCID number: Mohamed T Khayyal (0000-0002-7805-6704); Walaa Wadie (0000-0002-3421-2189); Enas A Abd El-Haleim (0000-0001-9822-5416); Kawkab A Ahmed (0000-0001-7376-7411); Olaf Kelber (0000-0003-3334-5833); Ramy M Ammar (0000-0002-5183-2232); Heba Abdel-Aziz (0000-0002-4808-5926).

Author contributions: Khayyal MT, Wadie W, Abd El-Haleim EA carried out the experimental study; Ahmed KA performed the histological part; Kelber O, Ammar RM, Abdel-Aziz H was responsible for planning of the study; all authors involved in writing and revising the manuscript.

Institutional animal care and use committee statement: The study was approved by the Ethical Committee for experimentation with laboratory animals (Faculty of Pharmacy, Cairo University) following the revised guidelines of the European Economic Community regulations (86/609/EEC) (Permit Number: PT 2292).

Conflict-of-interest statement: Mohamed T Khayyal reports grants from Steigerwald Arzneimittelwerk GmbH, Bayer Consumer Health, during the conduct of the study; Olaf Kelber, Ramy M. Ammar, Heba Abdel-Aziz are employed by Steigerwald Arzneimittelwerk GmbH, Bayer Consumer Health, Darmstadt, Germany; all other authors have no conflict of interest.

ARRIVE guidelines statement: The

Mohamed T Khayyal, Walaa Wadie, Enas A Abd El-Haleim, Department of Pharmacology, Faculty of Pharmacy, Cairo University, Cairo 11562, Egypt

Kawkab A Ahmed, Department of Pathology, Faculty of Veterinary Medicine, Cairo University, Cairo 12211, Egypt

Olaf Kelber, Ramy M Ammar, Heba Abdel-Aziz, Steigerwald Arzneimittelwerk GmbH, Bayer Consumer Health, Darmstadt 64295, Germany

Ramy M Ammar, Department of Pharmacology, Faculty of Pharmacy, Kafrelsheikh University, Kafrelsheikh 33511, Egypt

Corresponding author: Mohamed T Khayyal, PhD, Professor, Department of Pharmacology, Faculty of Pharmacy, Cairo University, Kasr-El-Aini Street, Cairo 11562, Egypt.

mtkhayyal@gmail.com

Telephone: +20-1-222102644

Fax: +20-2-37743491

Abstract

BACKGROUND

Proton pump inhibitors are often used to prevent gastro-intestinal lesions induced by nonsteroidal anti-inflammatory drugs. However, they are not always effective against both gastric and duodenal lesions and their use is not devoid of side effects.

AIM

To explore the mechanisms mediating the clinical efficacy of STW 5 in gastro-duodenal lesions induced by nonsteroidal anti-inflammatory drugs (NSAIDs), exemplified here by diclofenac, in a comparison to omeprazole.

METHODS

Gastro-duodenal lesions were induced in rats by oral administration of diclofenac (5 mg/kg) for 6 successive days. One group was given concurrently STW 5 (5 mL/kg) while another was given omeprazole (20 mg/kg). A day later, animals were sacrificed, stomach and duodenum excised and divided into 2 segments: One for histological examination and one for measuring inflammatory mediators (tumor necrosis factor α , interleukins-1 β and 10), oxidative stress enzyme (heme oxygenase-1) and apoptosis regulator (B-cell lymphoma 2).

RESULTS

authors have read the ARRIVE guidelines, and the manuscript was prepared and revised according to the ARRIVE guidelines.

Open-Access: This article is an open-access article which was selected by an in-house editor and fully peer-reviewed by external reviewers. It is distributed in accordance with the Creative Commons Attribution Non Commercial (CC BY-NC 4.0) license, which permits others to distribute, remix, adapt, build upon this work non-commercially, and license their derivative works on different terms, provided the original work is properly cited and the use is non-commercial. See: <http://creativecommons.org/licenses/by-nc/4.0/>

Manuscript source: Unsolicited manuscript

Received: April 28, 2019

Peer-review started: April 28, 2019

First decision: July 22, 2019

Revised: August 16, 2019

Accepted: September 13, 2019

Article in press: September 13, 2019

Published online: October 21, 2019

P-Reviewer: Ciccone MM, Li FY, Serafino A, Tang ZP

S-Editor: Yan JP

L-Editor: A

E-Editor: Ma YJ



Diclofenac caused overt histological damage in both tissues, associated with parallel changes in all parameters measured. STW 5 and omeprazole effectively prevented these changes, but STW 5 superseded omeprazole in protecting against histological damage, particularly in the duodenum.

CONCLUSION

The findings support the therapeutic usefulness of STW 5 and its superiority over omeprazole as adjuvant therapy to NSAIDs to protect against their possible gastro-duodenal side effects.

Key words: Diclofenac; STW 5; Omeprazole; Gastro-intestinal lesions; Inflammation

©The Author(s) 2019. Published by Baishideng Publishing Group Inc. All rights reserved.

Core tip: The herbal preparation STW 5, clinically used in functional dyspepsia and irritable bowel syndrome, was compared to omeprazole in protecting against diclofenac-induced gastro-duodenal lesions in rats. Both drugs were effective in preventing changes in the level of inflammatory mediators (tumor necrosis factor α , interleukins-1 β and 10), in the level of the oxidative stress enzyme, heme oxygenase-1, and the apoptotic regulator (B-cell lymphoma 2) in both stomach and duodenum. However, STW 5 was more effective than omeprazole in protecting against the histological damage. The results emphasize the potential usefulness of STW 5 and its superiority over omeprazole in protecting against gastro-duodenal lesions induced by nonsteroidal anti-inflammatory drugs.

Citation: Khayyal MT, Wadie W, Abd El-Haleim EA, Ahmed KA, Kelber O, Ammar RM, Abdel-Aziz H. STW 5 is effective against nonsteroidal anti-inflammatory drugs induced gastro-duodenal lesions in rats. *World J Gastroenterol* 2019; 25(39): 5926-5935

URL: <https://www.wjgnet.com/1007-9327/full/v25/i39/5926.htm>

DOI: <https://dx.doi.org/10.3748/wjg.v25.i39.5926>

INTRODUCTION

The long-term use of nonsteroidal anti-inflammatory drugs (NSAIDs), such as diclofenac, has been reported to cause various adverse effects on the gastro-intestinal tract, including lesions in the stomach and duodenum, irritation of the mucosal surface and dyspepsia^[1]. Various mechanisms have been involved in the development of these side effects, such as local epithelial irritation, inhibition of prostaglandin synthesis, and interference with barrier function and mucosal blood flow^[2]. While proton pump inhibitors (PPIs) have been advocated to protect against the injurious effect of NSAIDs, some authors failed to show that omeprazole was capable of healing mucosal lesions caused by diclofenac^[3]. Because of the fact that PPIs and other agents like H₂ receptor blockers are not devoid of side effects on their own, attention has been shifted to the use of relatively safe and better tolerated herbal preparations.

A recent review article^[4] emphasizes the use of natural products and herbal medicines to counteract the undesirable side effects of NSAIDs. One of the herbal preparations with established clinical efficacy in gastro-intestinal disorders such as functional dyspepsia and irritable bowel syndrome^[5] as well as in drug-induced gastro-intestinal disturbances^[6] is STW 5. It was shown to have a favorable safety profile^[7] and has recently been included in the Rome IV treatment algorithm as a treatment option for functional dyspepsia^[8].

The anti-inflammatory and mucosal protective properties of STW 5 were investigated and documented in several animal models of gastrointestinal (GI) disorders, including reflux esophagitis^[9], gastric ulcer^[10] and ulcerative colitis^[11]. The present study aims at shedding more light on mechanisms mediating the clinical efficacy of STW 5 in gastro-duodenal lesions induced by NSAIDs^[6], exemplified here by diclofenac, using an experimental model.

MATERIALS AND METHODS

Animals

Adult female Wistar rats, each weighing 150-200, were purchased from the National Research Centre, Giza, Egypt. They were housed in Perspex cages, housing 5 animals per cage, at the Faculty of Pharmacy, Cairo University, at a temperature of 25 ± 2 °C and a relative humidity of 60%-70%, and a 12-h light/12-h dark cycle. Taking in consideration that the diet might influence the outcome of some pharmacological experiments^[12], it should be emphasized that the animals were fed a normal chow diet consisting of 66% carbohydrates, 22% protein, 6% fats, 3% fiber and 3% minerals and vitamins mixture and purchased from Alfa Media Trade (Giza, Egypt) and allowed water *ad libitum*. This diet was previously used in earlier experiments with STW 5 with no influence on the outcome of the results^[11]. They were allowed to acclimatize for 1 wk before being subjected to experimentation. The study was approved by the Ethical Committee for experimentation with laboratory animals (Faculty of Pharmacy, Cairo University) following the revised guidelines of the European Economic Community regulations (86/609/EEC) (Permit Number: PT 2292).

Chemicals

Diclofenac was obtained from Novartis Pharma, Egypt; Omeprazole from Eipico, Egypt; STW 5 (Iberogast®) was generously supplied by Steigerwald Arzneimittelwerk GmbH, Darmstadt, Germany. STW 5 consists of a combination of standardized fixed proportions of hydro-alcoholic extracts of the following medicinal herbs *Iberis amara*, *Melissa officinalis*, *Matricaria recutita*, *Carum carvi*, *Mentha piperita*, *Angelica archangelica*, *Silybum marianum*, *Chelidonium majus* and *Glycyrrhiza glabra*. The other chemicals used were all of analytical grade.

Experimental design

Four groups of animals, consisting of 10 rats each, were randomly allocated as follows:

Group 1: Normal untreated control rats; Group 2: Rats treated with diclofenac orally in a daily dose of 5 mg/kg for 6 d; Group 3: Rats treated orally with diclofenac (5 mg/kg) together with omeprazole (20 mg/kg) daily for 6 d. The dose of omeprazole was formerly reported to be effective for this purpose^[13]; Group 4: Rats treated orally with diclofenac (5 mg/kg) together with STW 5 (5 mL/kg) daily for 6 d.

The dose of diclofenac and length of period of administration were chosen on the basis of preliminary experiments carried out in our lab to determine an appropriate dose of diclofenac to be given for a suitable number of days in order to induce reproducible gastro-duodenal lesions without causing appreciable animal mortalities under our experimental conditions. Accordingly, treatment in the above groups was given for 6 d. This is in agreement with an earlier study which reported that diclofenac was used in a dose of 5 mg/kg for 7 d in rat for evaluation of its gastric tolerability^[14]. Furthermore, the dose of STW 5 was based on earlier studies in our lab showing good anti-inflammatory activity and good tolerability in experimental animals^[15].

The animals were sacrificed by decapitation under light ether anesthesia on the seventh day and the stomach and duodenum were isolated and divided into 2 segments. One segment was preserved in 10% formalin for histological examination, while the other was homogenized in ice-cold normal saline to obtain a 10% homogenate that was stored at -20 °C for the assay of different relevant parameters at a later stage. These comprised the cytokines involved in inflammation, namely, interleukin 1 β (IL-1 β), IL-10, tumor necrosis factor- α (TNF- α) as well as the enzyme, heme oxygenase-1 (HO-1), as a measure of oxidative stress and B-cell lymphoma 2 (Bcl2) as an indicator of apoptosis. These parameters were determined using rat specific enzyme-linked immunosorbent assay (ELISA) kits (R and D Systems GmbH, Wiesbaden, Germany) according to manufacturer's instructions.

Histological examination

The fixed stomach and duodenum segments were processed by paraffin embedded technique and transverse 4-5 μ m sections were stained with Hematoxylin and Eosin for light microscopic examination. The histological damage in the gastric sections was assessed by examining them for 5 criteria representing cell damage, namely: (1) Focal mucosal necrosis; (2) Congestion of the sub-mucosal blood vessels; (3) Sub-mucosal edema; (4 and 5) Inflammatory cell infiltration in the mucosa and sub-mucosa. The extent of damage for each of these signs was assessed on a score from 0 (normal) to 3 (severe). An overall damage score (ODS) was then computed semi-quantitatively for each examined slide^[16].

For the duodenal sections, six criteria were studied, namely, focal necrosis of the

mucosa, infiltration of inflammatory cells in the lamina propria, mucosal edema, congestion of blood vessels, activation of glands and sub-mucosal edema. Accordingly, a maximal ODS for gastric and duodenal sections was computed to be 15 and 18, respectively. The data was then represented as a box plot.

Statistical analysis

The histological scores were represented as a box plot using the medians analyzed by Kuskal-Wallis followed by Dunn's test. The other data were expressed as means \pm standard deviation (SD) and analyzed by one-way-analysis of variance test (ANOVA) followed by Tukey Kramer multiple comparisons test, setting the level of significance at $P \leq 0.05$.

RESULTS

Biochemical parameters

Diclofenac administration showed a marked 4-fold increase in the level of the pro-inflammatory cytokine, IL-1 β , in both stomach and duodenum as compared to untreated control. Treatment with omeprazole and STW 5 tended to protect against this increase nearly to the same extent, such that the increase of the cytokine was reduced only to about two-fold (Figure 1A and B). The other pro-inflammatory cytokine, TNF- α , was also markedly increased after diclofenac administration, albeit not as much as IL-1 β . Both omeprazole and STW 5 in the doses used tended to prevent this increase in both tissues (Figure 1C and D). In parallel with these findings, the anti-inflammatory cytokine, IL-10, was significantly reduced by diclofenac in both stomach and duodenum, an effect that was largely prevented by both omeprazole and STW 5 mainly in the stomach, albeit to a non-statistically significant extent in the duodenum (Figure 1E and F).

With respect to HO-1, an anti-oxidant as well as anti-inflammatory enzyme, diclofenac was shown to induce a marked drop in its gastric and duodenal level. Omeprazole was effective in preventing the changes in both tissues, whereas STW 5 was effective only in ameliorating the diclofenac-induced reduction in the duodenum (Figure 1G and H). The levels of the apoptotic regulator, Bcl2 were suppressed by more than half by diclofenac in both the stomach and duodenum, an effect which tended to be prevented by treatment with either omeprazole or STW 5 almost to the same extent. (Figure 1I and J).

Histopathological examination

Stomach: The stomach of control untreated rats showed a normal histological structure of gastric mucosa, submucosa and muscularis layers (Figure 2A). On the other hand, stomach of rats treated with diclofenac showed severe histopathological alterations evidenced as multiple focal necrosis of gastric mucosa associated with mononuclear cells infiltration as well as submucosal edema and inflammatory cell infiltration (Figure 2B). Some sections also showed cystic dilatation of the gastric glands. However, the stomach of rats treated with diclofenac/omeprazole showed only mild submucosal edema associated with mononuclear cell infiltration and congested submucosal blood vessel (Figure 2C). A further improvement of the picture was shown in the stomachs of rats treated with diclofenac/STW 5, where only a few sections showed mild submucosal edema with some inflammatory cell infiltration and congested submucosal blood vessels, but most sections showed no histopathological alterations whatsoever (Figure 2D).

Duodenum: The duodenum of control untreated rats showed a normal histological structure of the villi, crypts and muscularis layer (Figure 3A). However, the duodenum of rats treated with diclofenac showed focal mucosal necrosis associated with focal inflammatory cell infiltration and edema in the lamina propria, congested mucosal blood vessel and activation of the glands (Figure 3B). A marked amelioration of the histological picture was seen after combining diclofenac with either omeprazole or STW 5. Thus, sections from rats treated with diclofenac/omeprazole showed only mild changes in the lamina propria exhibited as a few inflammatory cell infiltration, slight activation of the glands and slight congestion of blood vessels (Figure 3C) while sections from rats treated with diclofenac/STW 5 showed hardly any histopathological alterations (Figure 3D). The ODS of the lesions in the stomach and duodenum is represented in Figure 4, where it becomes evident that STW 5 was superior to omeprazole in preventing the histological damage induced by diclofenac in both tissues.

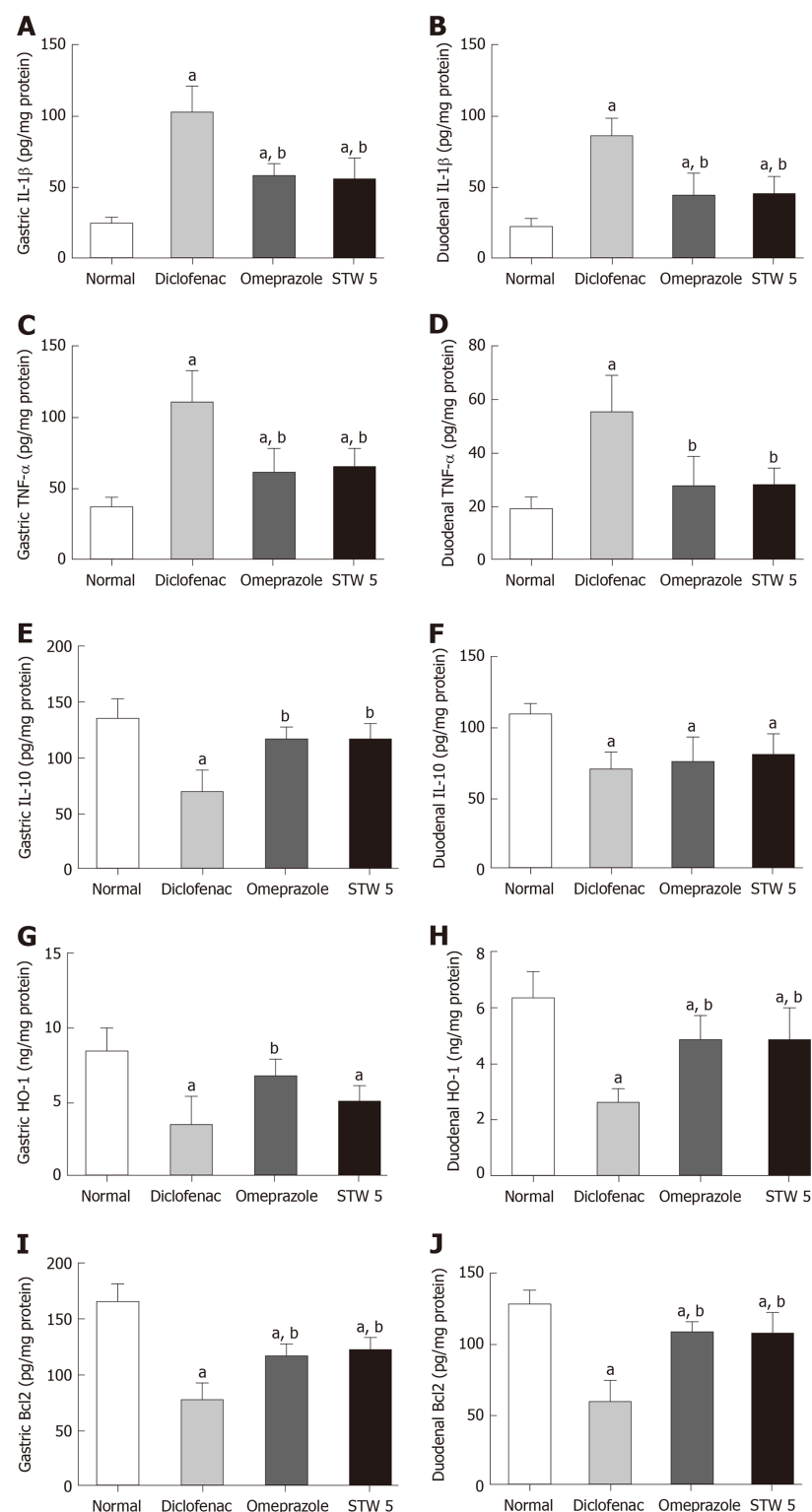


Figure 1 Changes in interleukin 1 β , tumor necrosis factor- α , interleukin 10, heme oxygenase-1, and B-cell lymphoma 2 concentration in gastro-intestinal lesions induced by diclofenac in rats after treatment with omeprazole (20 mg/kg) or STW 5 (5 mL/kg). A: Changes in interleukin 1 β concentration in gastric lesions; B: Changes in interleukin 1 β concentration in duodenal lesions; C: Changes in tumor necrosis factor- α concentration in gastric lesions; D: Changes in tumor necrosis factor- α concentration in duodenal lesions; E: Changes in interleukin 10 concentration in gastric lesions; F: Changes in interleukin 10 concentration in duodenal lesions; G: Changes in heme oxygenase-1 concentration in gastric lesions; H: Changes in heme oxygenase-1 concentration in duodenal lesions; I: Changes in B-cell lymphoma 2 concentration in gastric lesions; J: Changes in B-cell lymphoma 2 concentration in duodenal lesions. Data are expressed as means \pm SD. The significance of the difference between means was tested by ANOVA followed by Tukey Kramer multiple comparisons test. ^a $P < 0.05$ vs normal; ^b $P < 0.01$ vs diclofenac-treated group, $n = 7$. IL-1 β : Interleukin 1 β ; IL-10: Interleukin 10; TNF- α : Tumor necrosis factor- α ; HO-1: Heme oxygenase-1; Bcl2: B-cell lymphoma 2.

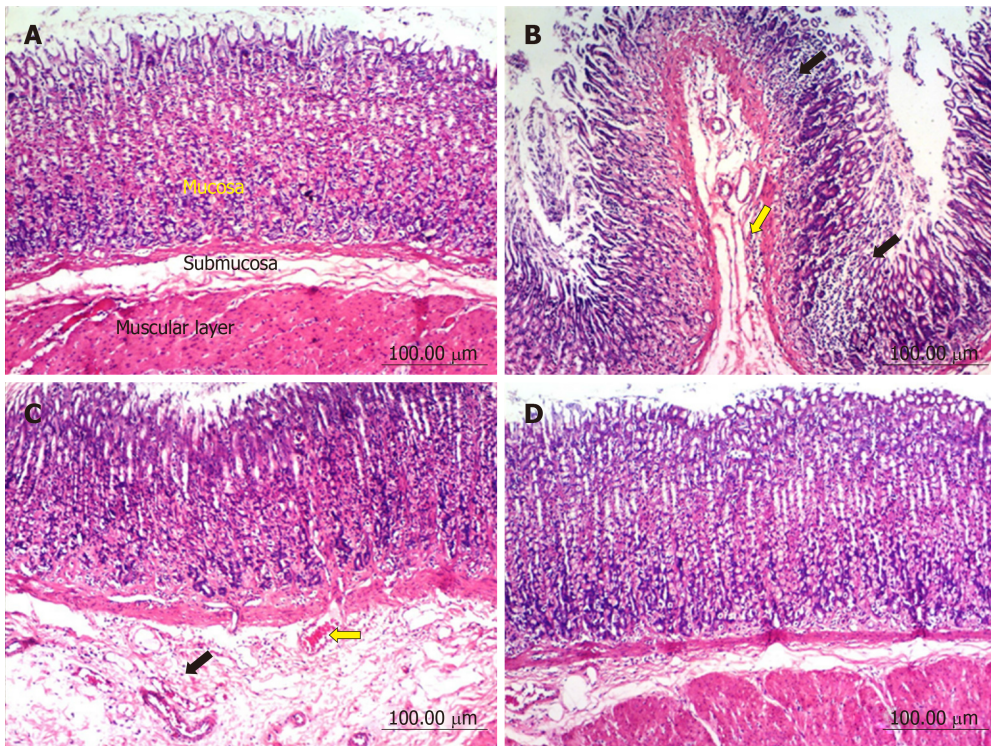


Figure 2 Histopathological changes in rat stomach. A: Untreated controls showing a normal histological structure of gastric layers (mucosa, submucosa and muscular layer); B: Diclofenac treated rats, showing multiple focal necrosis of gastric mucosa associated with mononuclear cell infiltration (black arrows), sub-mucosal edema and inflammatory cells infiltration (yellow arrow); C: Diclofenac together with omeprazole treated rats, showing sub-mucosal edema (black arrow) and congested sub-mucosal blood vessel (yellow arrow); D: Diclofenac together with STW 5 treated rats showing no histopathological alterations.

DISCUSSION

The fact that the frequent use of NSAIDs, including diclofenac, is prone to induce GI lesions has been well documented^[17]. In alignment with earlier reports, the administration of diclofenac in the given dose over several days resulted in changes in histological as well as associated biochemical parameters in both the stomach and duodenum. The histological changes were evidenced as gastric and duodenal mucosal necrosis, blood vessel congestion and edema as well as inflammatory cells infiltration into lamina propria and submucosa. Similar findings were reported by Devi *et al*^[18].

The GI histological changes were also reflected on the biochemical findings, where diclofenac induced a marked rise in the gastric and duodenal contents of IL-1 β and TNF- α , while reducing that of IL-10, indicating a disturbed balance between pro-inflammatory and anti-inflammatory cytokines. The role of these cytokines in the inflammatory process is well established. Thus, TNF- α besides contributing towards the induction of neutrophils to the inflamed mucosa^[19], activates the transcription factor, NF- κ B, thereby helping to up-regulate many genes involved in inflammatory and immune responses^[20]. The other pro-inflammatory cytokine, IL-1 β , enhances the production of other pro-inflammatory cytokines in the gut and contributes towards the expression of adhesion molecules on the endothelium^[21]. Among the different cells producing the anti-inflammatory cytokine, IL-10, are the regulatory B and T cells which are also involved in inflammation^[22]. HO-1 (also designated as heat shock protein-32) is constitutively found in the GI mucosa and becomes up-regulated during inflammation^[23]. It inhibits oxidative damage and reduces inflammatory events induced by inflammatory cytokines^[24].

In order to reduce the risk of GI injury induced by NSAIDs, adjuvant therapy has been advocated. Towards this end, PPIs have been reported to be very effective. Omeprazole has been effectively used in patients taking NSAIDs in order to heal and prevent recurrence of gastroduodenal injury^[25,26]. In support of this, the present study showed its good protective effect against the diclofenac-induced gastroduodenal lesions with marked improvement in the gastric and duodenal levels of the measured cytokines, antiapoptotic protein as well as HO-1 content. Nevertheless, there is some controversy in the literature in this respect. Some authors could not confirm that the drug is able to heal adequately the diclofenac induced GI lesions^[3].

The present study also showed that STW 5 had a better protective effect than omeprazole against the histological changes induced by diclofenac, as evidenced by a

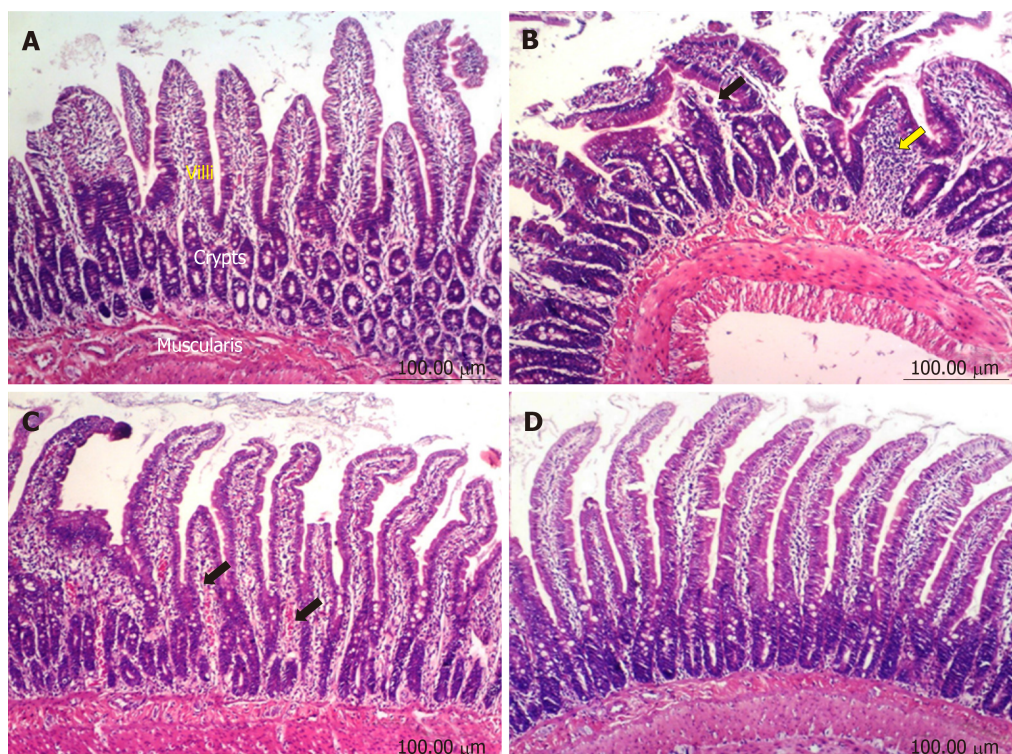


Figure 3 Histopathological changes in rat duodenum. A: Untreated controls showing a normal histological structure of villi, crypts and muscularis layer; B: Diclofenac treated rats showing focal mucosal necrosis (black arrow) associated with focal inflammatory cells infiltration in lamina propria (yellow arrow); C: Diclofenac together with omeprazole treated rats showing congestion of blood vessels in the lamina propria (black arrows); D: Diclofenac together with STW 5 treated rats showing no histopathological alterations.

reduction in the diclofenac-induced gastro-duodenal mucosal necrosis, blood vessel congestion, leukocytic infiltration, and edema. The superiority of STW 5 over omeprazole was previously reported in another experimental model of GI disorders, namely reflux esophagitis^[9], where the associated changes in the biochemical parameters were also significantly reduced or prevented.

The histological protective effect of STW 5 was associated with a reduction of the level of the pro-inflammatory cytokines, TNF- α and IL-1 β , while increasing that of IL-10. The herbal preparation was previously shown to have a dose-dependent inhibitory effect on TNF- α and/or IL-1 β both *in vitro*^[27] and *in vivo* using rat models of reflux esophagitis^[9] and colitis¹¹. Furthermore, STW 5 was reported to have anti-ulcerogenic and mucosal protective effects against indomethacin-induced gastric ulcers in rats^[10]. STW 5 has been reported to be clinically effective in functional dyspepsia and irritable bowel syndrome^[5], conditions that are often associated with inflammatory processes. The fact that STW 5 reduces the level of pro-inflammatory cytokines may at least partly be explained by its potential to inhibit the translocation of nuclear factor-kappa B, which plays an important role in regulating pro-inflammatory gene transcription^[28]. This reasoning is further supported by the work of Bertalot *et al*^[29] who showed that activation of Wnt pathway by STW 5 in a zebra fish model has a negative impact on NF- κ B signaling in enteric epithelial cells and on the enteric nervous system in general.

The relevance of gastric and/or duodenal HO-1 inflammatory lesions of these tissues is controversial in the literature. The intensity of colitis induced by dextran sulfate sodium was found to be associated with a decreased expression of HO-1^[30] while an increased expression was shown in many GI inflammatory conditions, including gastric ulcers^[31], colitis^[32] and radiation enteritis^[33]. In the present study, diclofenac led to a marked decline in the gastric and duodenal HO-1 contents, an effect which was largely prevented by omeprazole. STW 5, however, was mainly effective in the duodenum. Induction of HO-1 was previously reported to have a good protective effect against NSAIDs-induced gastric ulcers. It reduced gastric inflammation, tissue neutrophil activation, and pro-inflammatory cytokine expression caused by indomethacin^[34].

Since many of the observed histological changes involve apoptotic mechanisms, and since the Bcl2 family of proteins are critical regulators of the mitochondrial pathway of apoptosis, it was important to study the involvement of Bcl2 in our

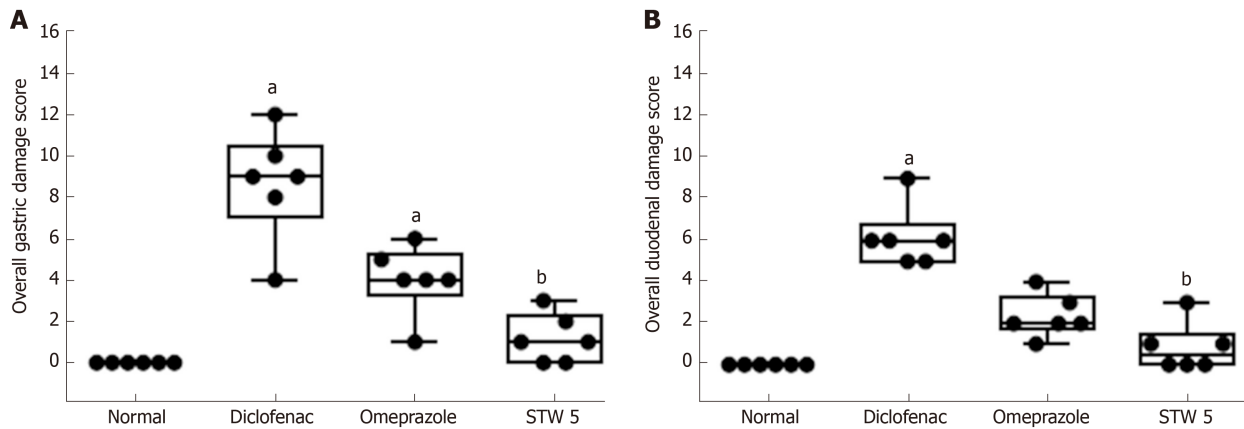


Figure 4 Changes in overall damage score in gastro-intestinal lesions induced by diclofenac in rats after treatment with omeprazole (20 mg/kg) or STW 5 (5 mL/kg). A: Gastric lesions; B: Duodenal lesions. Data are expressed as box plots of the median of six animals. ^a $P < 0.05$ vs normal; ^b $P < 0.01$ vs diclofenac-treated group.

experiments. Diclofenac led to a marked decline in the gastric and duodenal Bcl2 contents, thereby enhancing the apoptotic mechanisms. The effect was largely prevented to the same extent by both STW 5 omeprazole, pointing to their similar anti-apoptotic activity. The anti-apoptotic property of STW 5 was previously reported in detail by Khayyal *et al*^[15].

Collectively, the present findings show that both STW 5 and omeprazole are effective nearly to the same extent in preventing the changes in biochemical parameters associated with the inflammatory response in both the stomach and duodenum of diclofenac treated rats. However, STW 5 was more effective than omeprazole in preventing the histological changes induced by the NSAID, particularly in the duodenum. Furthermore, the study provides pharmacological evidence underlying the clinical usefulness of STW 5 in patients suffering from diclofenac and other NSAID induced gastro-intestinal disorders in placebo-controlled clinical trials^[6]. The findings further support more recent clinical and pre-clinical studies showing the efficacy and good tolerability of the herbal preparation^[35]. STW 5 may thus represent an effective and safe adjuvant therapy for use in patients taking NSAIDs to guard against the possible occurrence of gastro-duodenal lesions.

ARTICLE HIGHLIGHTS

Research background

Nonsteroidal anti-inflammatory drugs (NSAIDs), like diclofenac, are prone to induce gastro-duodenal injury on prolonged use, a fact that compromises their clinical usefulness. Continued efforts are being exerted to find agents that could be given alongside the NSAIDs to guard against such injury.

Research motivation

Whereas proton pump inhibitors (PPIs), like omeprazole, are often used to protect against such injury, they are not always effective in protecting against both gastric and duodenal lesions. Moreover, they often exert side effects on their own. Accordingly, the search continues to find agents, such as natural products, that could be safer than PPIs and prove effective against both gastric and duodenal lesions induced by NSAIDs. The herbal preparation, STW 5, has been the focus of our studies for many years, particularly in the field of gastro-intestinal ailments. The preparation has proved to be clinically effective in functional dyspepsia and irritable bowel syndrome, as well as experimentally effective against gastric ulcers, ulcerative colitis, and other gastro-intestinal disorders. STW 5 has a wide safety profile. We were therefore highly motivated to test its efficacy in protecting against the gastro-duodenal lesions induced by diclofenac, as an example of a widely used NSAID.

Research objectives

It was important not only to show the efficacy of the herbal preparation in protecting against diclofenac induced lesions, but also to compare its efficacy with that of omeprazole, as an example of a widely used PPI. This would then lead to its clinical trial and possible application as adjuvant therapy for patients who may be sensitive to the use of NSAIDs. STW 5 could then become a valuable and much safer substitute for PPIs.

Research methods

To achieve these aims experiments were designed to induce gastro-duodenal lesions in rats by

feeding them orally with diclofenac for 6 d. The rats were allocated into groups, some receiving concomitantly omeprazole, and others receiving STW 5. At the end of the experimental period, the animals were sacrificed, samples of blood were taken to determine levels of relevant mediators of inflammation, oxidative stress, and apoptosis using ELISA techniques. Sections of gastric and duodenal tissue were prepared for histological examination. All the chosen parameters were considered relevant to the study in question.

Research results

Diclofenac led to marked histological changes in both the stomach and duodenum, associated with significant changes in inflammatory cytokines (tumor necrosis factor α , interleukins-1 β and 10), in the oxidative stress enzyme, heme oxygenase 1, and in the apoptotic regulator, B-cell lymphoma 2. Both omeprazole and STW 5 in the given doses were comparable in their effects in counteracting the changes in all the biochemical parameters, but STW 5 was much more effective in preventing the histological changes in both the stomach and duodenum. The present results lend further support to the beneficial use of STW 5 in gastro-intestinal disorders. It would be of value to extend the study to other NSAIDs and to further prolong the administration of the NSAID for more than one week. In the present study, giving diclofenac for longer than 6 d led to animal mortality.

Research conclusions

STW 5 may offer a much safer alternative to PPIs to help protect the stomach and duodenum from damage in patients under prolonged treatment with NSAIDs. The good clinical tolerability of the herbal preparation which has already been well established in functional dyspepsia and irritable bowel syndrome may pave the way to introducing it in preliminary clinical trials as adjuvant therapy in patients undergoing therapy with NSAIDs.

Research perspectives

The study is a good example of developing new therapeutic indications for drugs already established on the market, based on well-designed experiments to show their potential efficacy in a new domain. The results obtained warrant further investigations and placebo-controlled studies before being clinically introduced as adjuvant therapy in patients under treatment with drugs that could potentially injure the gastro-intestinal tract.

REFERENCES

1. Chan FK, Lanas A, Scheiman J, Berger MF, Nguyen H, Goldstein JL. Celecoxib versus omeprazole and diclofenac in patients with osteoarthritis and rheumatoid arthritis (CONDOR): a randomised trial. *Lancet* 2010; **376**: 173-179 [PMID: 20638563 DOI: 10.1016/S0140-6736(10)60673-3]
2. Musumba C, Pritchard DM, Pirmohamed M. Review article: cellular and molecular mechanisms of NSAID-induced peptic ulcers. *Aliment Pharmacol Ther* 2009; **30**: 517-531 [PMID: 19575764 DOI: 10.1111/j.1365-2036.2009.04086.x]
3. Dorta G, Nicolet M, Vouillamoz D, Margalith D, Saraga E, Bouzourene H, Häcki WH, Stolte M, Blum AL, Armstrong D. The effects of omeprazole on healing and appearance of small gastric and duodenal lesions during dosing with diclofenac in healthy subjects. *Aliment Pharmacol Ther* 2000; **14**: 535-541 [PMID: 10792115 DOI: 10.1046/j.1365-2036.2000.00737.x]
4. Simon JP, Evan Prince S. Natural remedies for non-steroidal anti-inflammatory drug-induced toxicity. *J Appl Toxicol* 2017; **37**: 71-83 [PMID: 27652576 DOI: 10.1002/jat.3391]
5. Malfertheiner P. STW 5 (Iberogast) Therapy in Gastrointestinal Functional Disorders. *Dig Dis* 2017; **35** Suppl 1: 25-29 [PMID: 29421817 DOI: 10.1159/000485410]
6. Mac Lean N, Hübner-Steiner U. [Treatment of drug-induced gastrointestinal disorders. Double-blind study of the effectiveness of Iberogast compared to placebo]. *Fortschr Med* 1987; **105**: 239-242 [PMID: 3297957]
7. Rösch W, Liebrechts T, Gundermann KJ, Vinson B, Holtmann G. Phytotherapy for functional dyspepsia: a review of the clinical evidence for the herbal preparation STW 5. *Phytomedicine* 2006; **13** Suppl 5: 114-121 [PMID: 16978851 DOI: 10.1016]
8. Stanghellini V, Chan FK, Hasler WL, Malagelada JR, Suzuki H, Tack J, Talley NJ. Gastrointestinal Disorders. *Gastroenterology* 2016; **150**: 1380-1392 [PMID: 27147122 DOI: 10.1053/j.gastro.2016.02.011]
9. Abdel-Aziz H, Zaki HF, Neuhuber W, Kelber O, Weiser D, Khayyal MT. Effect of an herbal preparation, STW 5, in an acute model of reflux oesophagitis in rats. *J Pharmacol Sci* 2010; **113**: 134-142 [PMID: 20484868 DOI: 10.1254/jphs.09355FP]
10. Khayyal MT, Seif-El-Nasr M, El-Ghazaly MA, Okpanyi SN, Kelber O, Weiser D. Mechanisms involved in the gastro-protective effect of STW 5 (Iberogast) and its components against ulcers and rebound acidity. *Phytomedicine* 2006; **13** Suppl 5: 56-66 [PMID: 16963243 DOI: 10.1016/j.phymed.2006.03.019]
11. Wadie W, Abdel-Aziz H, Zaki HF, Kelber O, Weiser D, Khayyal MT. STW 5 is effective in dextran sulfate sodium-induced colitis in rats. *Int J Colorectal Dis* 2012; **27**: 1445-1453 [PMID: 22562255 DOI: 10.1007/s00384-012-1473-z]
12. Scicchitano P, Cameli M, Maiello M, Modesti PA, Muiesane ML, Novo S, Palmieroc P, Sabag PS, Pedrinelli R, Ciccone MM. Nutraceuticals and dyslipidaemia: Beyond the common therapeutics. *J Funct Foods* 2014; **6**: 11-32 [DOI: 10.1016/j.jff.2013.12.006]
13. Segawa K, Nakazawa S, Tsukamoto Y, Chujoh C, Yamao K, Hase S. Effect of omeprazole on gastric acid secretion in rat: evaluation of dose, duration of effect, and route of administration. *Gastroenterol Jpn* 1987; **22**: 413-418 [PMID: 3666382 DOI: 10.1007/bf02773807]
14. Kalra BS, Shalini, Chaturvedi S, Tayal V, Gupta U. Evaluation of gastric tolerability, antinociceptive and antiinflammatory activity of combination NSAIDs in rats. *Indian J Dent Res* 2009; **20**: 418-422 [PMID: 20139563 DOI: 10.4103/0970-9290.59439]
15. Khayyal MT, Abdel-Naby DH, Abdel-Aziz H, El-Ghazaly MA. A multi-component herbal preparation,

- STW 5, shows anti-apoptotic effects in radiation induced intestinal mucositis in rats. *Phytomedicine* 2014; **21**: 1390-1399 [PMID: [25022208](#) DOI: [10.1016/j.phymed.2014.04.030](#)]
- 16 **Howarth GS**, Francis GL, Cool JC, Xu X, Byard RW, Read LC. Milk growth factors enriched from cheese whey ameliorate intestinal damage by methotrexate when administered orally to rats. *J Nutr* 1996; **126**: 2519-2530 [PMID: [8857513](#) DOI: [10.1093/jn/126.10.2519](#)]
- 17 **Drini M**. Peptic ulcer disease and non-steroidal anti-inflammatory drugs. *Aust Prescr* 2017; **40**: 91-93 [PMID: [28798512](#) DOI: [10.18773/austprescr.2017.037](#)]
- 18 **Devi RS**, Narayan S, Vani G, Shyamala Devi CS. Gastroprotective effect of Terminalia arjuna bark on diclofenac sodium induced gastric ulcer. *Chem Biol Interact* 2007; **167**: 71-83 [PMID: [17327128](#) DOI: [10.1016/j.cbi.2007.01.011](#)]
- 19 **Stallmach A**, Giese T, Schmidt C, Ludwig B, Mueller-Molaian I, Meuer SC. Cytokine/chemokine transcript profiles reflect mucosal inflammation in Crohn's disease. *Int J Colorectal Dis* 2004; **19**: 308-315 [DOI: [10.1007/s00384-003-0554-4](#)]
- 20 **Papadakis KA**, Targan SR. Role of cytokines in the pathogenesis of inflammatory bowel disease. *Annu Rev Med* 2000; **51**: 289-298 [PMID: [10774465](#) DOI: [10.1146/annurev.med.51.1.289](#)]
- 21 **Dinarello CA**, Wolff SM. The role of interleukin-1 in disease. *N Engl J Med* 1993; **328**: 106-113 [PMID: [8439348](#) DOI: [10.1056/NEJM199301143280207](#)]
- 22 **Barada KA**, Mourad FH, Sawah SI, Khoury C, Safieh-Garabedian B, Nassar CF, Tawil A, Jurjus A, Saadé NE. Up-regulation of nerve growth factor and interleukin-10 in inflamed and non-inflamed intestinal segments in rats with experimental colitis. *Cytokine* 2007; **37**: 236-245 [PMID: [17517520](#) DOI: [10.1016/j.cyto.2007.04.005](#)]
- 23 **Barton SG**, Rampton DS, Winrow VR, Domizio P, Feakins RM. Expression of heat shock protein 32 (hemoxygenase-1) in the normal and inflamed human stomach and colon: an immunohistochemical study. *Cell Stress Chaperones* 2003; **8**: 329-334 [PMID: [15115285](#) DOI: [10.1379/1466-1268\(2003\)008<0329:eohsph>2.0.co;2](#)]
- 24 **Alcaraz MJ**, Fernández P, Guillén MI. Anti-inflammatory actions of the heme oxygenase-1 pathway. *Curr Pharm Des* 2003; **9**: 2541-2551 [PMID: [14529552](#) DOI: [10.2174/1381612033453749](#)]
- 25 **Hawkey CJ**, Karrasch JA, Szczepański L, Walker DG, Barkun A, Swannell AJ, Yeomans ND. Omeprazole compared with misoprostol for ulcers associated with nonsteroidal antiinflammatory drugs. Omeprazole versus Misoprostol for NSAID-induced Ulcer Management (OMNIUM) Study Group. *N Engl J Med* 1998; **338**: 727-734 [PMID: [9494149](#) DOI: [10.1056/NEJM199803123381105](#)]
- 26 **Cullen D**, Bardhan KD, Eisner M, Kogut DG, Peacock RA, Thomson JM, Hawkey CJ. Primary gastroduodenal prophylaxis with omeprazole for non-steroidal anti-inflammatory drug users. *Aliment Pharmacol Ther* 1998; **12**: 135-140 [PMID: [9692687](#) DOI: [10.1046/j.1365-2036.1998.00288.x](#)]
- 27 **Schneider M**, Efferth T, Abdel-Aziz H. Anti-inflammatory Effects of Herbal Preparations STW5 and STW5-II in Cytokine-Challenged Normal Human Colon Cells. *Front Pharmacol* 2016; **7**: 393 [PMID: [27833553](#) DOI: [10.3389/fphar.2016.00393](#)]
- 28 **Ghosh S**, Hayden MS. New regulators of NF-kappaB in inflammation. *Nat Rev Immunol* 2008; **8**: 837-848 [PMID: [18927578](#) DOI: [10.1038/nri2423](#)]
- 29 **Bertalot T**, Schrenk S, Facchinello N, Skobo T, Cenzi C, Dalla Valle L, Abdel-Aziz H, Di Liddo R. WNT signaling activation in the inflammatory process driven by the herbal preparation STW 5. United European Gastroenterology Week Conference; October 15-19; 2016 Vienna, Austria. 2016; P0512
- 30 **Khor TO**, Huang MT, Kwon KH, Chan JY, Reddy BS, Kong AN. Nrf2-deficient mice have an increased susceptibility to dextran sulfate sodium-induced colitis. *Cancer Res* 2006; **66**: 11580-11584 [PMID: [17178849](#) DOI: [10.1158/0008-5472.CAN-06-3562](#)]
- 31 **Luo C**, Chen H, Wang Y, Lin G, Li C, Tan L, Su Z, Lai X, Xie J, Zeng H. Protective effect of coptisine free base on indomethacin-induced gastric ulcers in rats: Characterization of potential molecular mechanisms. *Life Sci* 2018; **193**: 47-56 [PMID: [29223540](#) DOI: [10.1016/j.lfs.2017.12.004](#)]
- 32 **Zhu X**, Fan WG, Li DP, Kung H, Lin MC. Heme oxygenase-1 system and gastrointestinal inflammation: a short review. *World J Gastroenterol* 2011; **17**: 4283-4288 [PMID: [22090784](#) DOI: [10.3748/wjg.v17.i38.4283](#)]
- 33 **Giriş M**, Erbil Y, Doğru-Abbasoğlu S, Yanik BT, Aliş H, Olgaç V, Toker GA. The effect of heme oxygenase-1 induction by glutamine on TNBS-induced colitis. The effect of glutamine on TNBS colitis. *Int J Colorectal Dis* 2007; **22**: 591-599 [PMID: [17124609](#) DOI: [10.1007/s00384-006-0238-y](#)]
- 34 **Uc A**, Zhu X, Wagner BA, Buettner GR, Berg DJ. Heme oxygenase-1 is protective against nonsteroidal anti-inflammatory drug-induced gastric ulcers. *J Pediatr Gastroenterol Nutr* 2012; **54**: 471-476 [PMID: [21873894](#) DOI: [10.1097/MPG.0b013e3182334fdf](#)]
- 35 **Cremonini F**. Standardized herbal treatments on functional bowel disorders: moving from putative mechanisms of action to controlled clinical trials. *Neurogastroenterol Motil* 2014; **26**: 893-900 [PMID: [24965903](#) DOI: [10.1111/nmo.12384](#)]



Published By Baishideng Publishing Group Inc
7041 Koll Center Parkway, Suite 160, Pleasanton, CA 94566, USA
Telephone: +1-925-2238242
E-mail: bpgoffice@wjgnet.com
Help Desk: <http://www.f6publishing.com/helpdesk>
<http://www.wjgnet.com>

