

World Journal of *Clinical Cases*

World J Clin Cases 2019 October 26; 7(20): 3168-3383



**OPINION REVIEW**

- 3168** Clinical use of low-dose aspirin for elders and sensitive subjects
Zhang Y, Fang XM, Chen GX

ORIGINAL ARTICLE**Retrospective Study**

- 3175** Distribution and drug resistance of pathogenic bacteria in emergency patients
Huai W, Ma QB, Zheng JJ, Zhao Y, Zhai QR
- 3185** Comparative analysis of robotic *vs* laparoscopic radical hysterectomy for cervical cancer
Chen L, Liu LP, Wen N, Qiao X, Meng YG
- 3194** Feasibility of laparoscopic isolated caudate lobe resection for rare hepatic mesenchymal neoplasms
Li Y, Zeng KN, Ruan DY, Yao J, Yang Y, Chen GH, Wang GS
- 3202** Rh-incompatible hemolytic disease of the newborn in Hefei
Bi SH, Jiang LL, Dai LY, Zheng H, Zhang J, Wang LL, Wang C, Jiang Q, Liu Y, Zhang YL, Wang J, Zhu C, Liu GH, Teng RJ
- 3208** Soft tissue release combined with joint-sparing osteotomy for treatment of cavovarus foot deformity in older children: Analysis of 21 cases
Chen ZY, Wu ZY, An YH, Dong LF, He J, Chen R

Observational Study

- 3217** Clinical characteristics of sentinel polyps and their correlation with proximal colon cancer: A retrospective observational study
Wang M, Lu JJ, Kong WJ, Kang XJ, Gao F

Prospective Study

- 3226** Longitudinal observation of intraocular pressure variations with acute altitude changes
Xie Y, Sun YX, Han Y, Yang DY, Yang YQ, Cao K, Li SN, Li X, Lu XX, Wu SZ, Wang NL

Randomized Controlled Trial

- 3237** Combination of propofol and dezocine to improve safety and efficacy of anesthesia for gastroscopy and colonoscopy in adults: A randomized, double-blind, controlled trial
Li XT, Ma CQ, Qi SH, Zhang LM

META-ANALYSIS

- 3247** Prognostic significance of malignant ascites in gastric cancer patients with peritoneal metastasis: A systemic review and meta-analysis
Zheng LN, Wen F, Xu P, Zhang S

CASE REPORT

- 3259** Gonadotrophin-releasing hormone agonist-induced pituitary adenoma apoplexy and casual finding of a parathyroid carcinoma: A case report and review of literature
Triviño V, Fidalgo O, Juane A, Pombo J, Cordido F
- 3267** Constrictive pericarditis as a cause of refractory ascites after liver transplantation: A case report
Bezjak M, Kocman B, Jadrijević S, Gašparović H, Mrzljak A, Kanižaj TF, Vujanić D, Bubalo T, Mikulić D
- 3271** Endoluminal closure of an unrecognized penetrating stab wound of the duodenum with endoscopic band ligation: A case report
Kim DH, Choi H, Kim KB, Yun HY, Han JH
- 3276** Spontaneous superior mesenteric artery dissection following upper gastrointestinal panendoscopy: A case report and literature review
Ou Yang CM, Yen YT, Chua CH, Wu CC, Chu KE, Hung TI
- 3282** Hepatic amyloidosis leading to hepatic venular occlusive disease and Budd-Chiari syndrome: A case report
Li TT, Wu YF, Liu FQ, He FL
- 3296** De Winter syndrome and ST-segment elevation myocardial infarction can evolve into one another: Report of two cases
Lin YY, Wen YD, Wu GL, Xu XD
- 3303** Next generation sequencing reveals co-existence of hereditary spherocytosis and Dubin-Johnson syndrome in a Chinese girl: A case report
Li Y, Li Y, Yang Y, Yang WR, Li JP, Peng GX, Song L, Fan HH, Ye L, Xiong YZ, Wu ZJ, Zhou K, Zhao X, Jing LP, Zhang FK, Zhang L
- 3310** Recognizable type of pituitary, heart, kidney and skeletal dysplasia mostly caused by SEMA3A mutation: A case report
Hu F, Sun L
- 3322** Repeated lumps and infections: A case report on breast augmentation complications
Zhang MX, Li SY, Xu LL, Zhao BW, Cai XY, Wang GL
- 3329** Severe mental disorders following anti-retroviral treatment in a patient on peritoneal dialysis: A case report and literature review
He QE, Xia M, Ying GH, He XL, Chen JH, Yang Y

- 3335** Fish bone-induced myocardial injury leading to a misdiagnosis of acute myocardial infarction: A case report
Wang QQ, Hu Y, Zhu LF, Zhu WJ, Shen P
- 3341** Potentially fatal electrolyte imbalance caused by severe hydrofluoric acid burns combined with inhalation injury: A case report
Fang H, Wang GY, Wang X, He F, Su JD
- 3347** Ureter - an unusual site of breast cancer metastasis: A case report
Zhou ZH, Sun LJ, Zhang GM
- 3353** Alternative technique to save ischemic bowel segment in management of neonatal short bowel syndrome: A case report
Geng L, Zhou L, Ding GJ, Xu XL, Wu YM, Liu JJ, Fu TL
- 3358** Sister Mary Joseph's nodule in endometrial carcinoma: A case report
Li Y, Guo P, Wang B, Jia YT
- 3364** Synchronous quadruple primary malignancies of the cervix, endometrium, ovary, and stomach in a single patient: A case report and review of literature
Wang DD, Yang Q
- 3372** Ureteral Ewing's sarcoma in an elderly woman: A case report
Li XX, Bi JB
- 3377** Anaplastic lymphoma kinase-negative anaplastic large cell lymphoma masquerading as Behcet's disease: A case report and review of literature
Luo J, Jiang YH, Lei Z, Miao YL

ABOUT COVER

Editorial Board Member of *World Journal of Clinical Cases*, Faycal Lakhdar, MD, Professor, Department of Neurosurgery, University Hospital Center of Fes, University Sidi Mohammed Ben Abdellah, FES 10000, Morocco

AIMS AND SCOPE

The primary aim of *World Journal of Clinical Cases* (WJCC, *World J Clin Cases*) is to provide scholars and readers from various fields of clinical medicine with a platform to publish high-quality clinical research articles and communicate their research findings online.

WJCC mainly publishes articles reporting research results and findings obtained in the field of clinical medicine and covering a wide range of topics, including case control studies, retrospective cohort studies, retrospective studies, clinical trials studies, observational studies, prospective studies, randomized controlled trials, randomized clinical trials, systematic reviews, meta-analysis, and case reports.

INDEXING/ABSTRACTING

The WJCC is now indexed in PubMed, PubMed Central, Science Citation Index Expanded (also known as SciSearch®), and Journal Citation Reports/Science Edition. The 2019 Edition of Journal Citation Reports cites the 2018 impact factor for WJCC as 1.153 (5-year impact factor: N/A), ranking WJCC as 99 among 160 journals in Medicine, General and Internal (quartile in category Q3).

RESPONSIBLE EDITORS FOR THIS ISSUE

Responsible Electronic Editor: Ji-Hong Liu

Proofing Production Department Director: Yun-Xiaojuan Wu

NAME OF JOURNAL

World Journal of Clinical Cases

ISSN

ISSN 2307-8960 (online)

LAUNCH DATE

April 16, 2013

FREQUENCY

Semimonthly

EDITORS-IN-CHIEF

Dennis A Bloomfield, Bao-Gan Peng, Sandro Vento

EDITORIAL BOARD MEMBERS

<https://www.wjnet.com/2307-8960/editorialboard.htm>

EDITORIAL OFFICE

Jin-Lei Wang, Director

PUBLICATION DATE

October 26, 2019

COPYRIGHT

© 2019 Baishideng Publishing Group Inc

INSTRUCTIONS TO AUTHORS

<https://www.wjnet.com/bpg/gerinfo/204>

GUIDELINES FOR ETHICS DOCUMENTS

<https://www.wjnet.com/bpg/GerInfo/287>

GUIDELINES FOR NON-NATIVE SPEAKERS OF ENGLISH

<https://www.wjnet.com/bpg/gerinfo/240>

PUBLICATION MISCONDUCT

<https://www.wjnet.com/bpg/gerinfo/208>

ARTICLE PROCESSING CHARGE

<https://www.wjnet.com/bpg/gerinfo/242>

STEPS FOR SUBMITTING MANUSCRIPTS

<https://www.wjnet.com/bpg/GerInfo/239>

ONLINE SUBMISSION

<https://www.f6publishing.com>

Next generation sequencing reveals co-existence of hereditary spherocytosis and Dubin–Johnson syndrome in a Chinese girl: A case report

Yuan Li, Yang Li, Yang Yang, Wen-Rui Yang, Jian-Ping Li, Guang-Xin Peng, Lin Song, Hui-Hui Fan, Lei Ye, You-Zhen Xiong, Zhi-Jie Wu, Kang Zhou, Xin Zhao, Li-Ping Jing, Feng-Kui Zhang, Li Zhang

ORCID number: Yuan Li (0000-0001-8603-011X); Yang Li (0000-0001-8864-6487); Yang Yang (0000-0002-4268-1823); Wen-Rui Yang (0000-0001-9650-3937); Jian-Ping Li (0000-0002-9765-2579); Guang-Xin Peng (0000-0001-6666-7391); Lin Song (0000-0002-5999-3049); Hui-Hui Fan (0000-0001-6446-2376); Lei Ye (0000-0001-6615-9573); You-Zhen Xiong (0000-0002-1569-4872); Zhi-Jie Wu (0000-0003-3984-0819); Kang Zhou (0000-0003-2900-2520); Xin Zhao (0000-0002-5621-0459); Li-Ping Jing (0000-0002-7315-9755); Feng-Kui Zhang (0000-0002-2553-5998); Li Zhang (0000-0002-4702-9658).

Author contributions: Li Y designed and wrote the report; Zhang L and Zhang FK reviewed the manuscript for its intellectual content and revised the entire work; Li Y, Yang Y, and Li JP performed the histological assessments and evaluations; Yang WR, Ye L, and Xiong YZ performed the imaging assessments and evaluations; Zhao X, Wu ZJ, and Zhou K analysed the NGS data and made evaluations; Peng GX, Fan HH, and Song L performed the hemolytic test and flow cytometry analysis; Jing LP reviewed the manuscript for its intellectual content; all authors have read and approved the final manuscript.

Supported by the National Science and Technology Important and Special Project of China, No. 2017ZX09304024.

Yuan Li, Yang Li, Yang Yang, Wen-Rui Yang, Jian-Ping Li, Guang-Xin Peng, Lin Song, Hui-Hui Fan, Lei Ye, You-Zhen Xiong, Zhi-Jie Wu, Kang Zhou, Xin Zhao, Li-Ping Jing, Feng-Kui Zhang, Li Zhang, Anemia Therapeutic Center, Institute of Hematology and Blood Diseases Hospital, CAMS and PUMC, Tianjin 300020, China

Corresponding author: Li Zhang, MD, Professor, Anemia Therapeutic Center, Institute of Hematology and Blood Diseases Hospital, CAMS and PUMC, Tianjin 300020, China.

zhangli@ihcams.ac.cn

Telephone: +86-22-23909223

Fax: +86-22-23909014

Abstract

BACKGROUND

Hereditary spherocytosis (HS) is a hereditary disease of hemolytic anemia that occurs due to the erythrocyte membrane defects. Dubin–Johnson syndrome (DJS), which commonly results in jaundice, is a benign hereditary disorder of bilirubin clearance that occurs only rarely. The co-occurrence of HS and DJS is extremely rare. We recently diagnosed and treated a case of co-occurring HS and DJS.

CASE SUMMARY

A 21-year-old female patient presented to our department because of severe jaundice, severe splenomegaly, and mild anemia since birth. We eventually confirmed the diagnosis of co-occurring DJS and HS by next generation sequencing (NGS). The treatment of ursodeoxycholic acid in combination with phenobarbital successfully increased hemoglobin and reduced total bilirubin and direct bilirubin.

CONCLUSION

The routine application of NGS can efficiently render a definite diagnosis when inherited disorders are suspected.

Key words: Hereditary spherocytosis; Dubin–Johnson syndrome; Hemolytic anemia; Jaundice; Next generation sequencing; ABCC2; SPTB; Case report

©The Author(s) 2019. Published by Baishideng Publishing Group Inc. All rights reserved.

Informed consent statement: The patient involved in this study gave written informed consent authorizing the use and disclosure of his protected health information. The study protocol was approved without restrictions by the Medical Ethics Committee of Institute of Hematology and Blood Diseases Hospital, CAMS and PUMC.

Conflict-of-interest statement: The authors have no conflicts of interest to disclose.

CARE Checklist (2016) statement: The manuscript was prepared and revised according to the CARE Checklist (2016).

Open-Access: This article is an open-access article which was selected by an in-house editor and fully peer-reviewed by external reviewers. It is distributed in accordance with the Creative Commons Attribution Non Commercial (CC BY-NC 4.0) license, which permits others to distribute, remix, adapt, build upon this work non-commercially, and license their derivative works on different terms, provided the original work is properly cited and the use is non-commercial. See: <http://creativecommons.org/licenses/by-nc/4.0/>

Manuscript source: Unsolicited manuscript

Received: April 19, 2019

Peer-review started: April 22, 2019

First decision: August 1, 2019

Revised: August 21, 2019

Accepted: September 9, 2019

Article in press: September 9, 2019

Published online: October 26, 2019

P-Reviewer: Jeong BH, Devgun M

S-Editor: Zhang L

L-Editor: Wang TQ

E-Editor: Xing YX



Core tip: A rare case of co-occurring Dubin-Johnson syndrome and hereditary spherocytosis, which presented exceptionally severe jaundice, was diagnosed by next generation sequencing.

Citation: Li Y, Li Y, Yang Y, Yang WR, Li JP, Peng GX, Song L, Fan HH, Ye L, Xiong YZ, Wu ZJ, Zhou K, Zhao X, Jing LP, Zhang FK, Zhang L. Next generation sequencing reveals co-existence of hereditary spherocytosis and Dubin-Johnson syndrome in a Chinese girl: A case report. *World J Clin Cases* 2019; 7(20): 3303-3309

URL: <https://www.wjgnet.com/2307-8960/full/v7/i20/3303.htm>

DOI: <https://dx.doi.org/10.12998/wjcc.v7.i20.3303>

INTRODUCTION

Hereditary spherocytosis (HS) is a hereditary disease of hemolytic anemia that occurs due to the erythrocyte membrane defects caused by the gene mutation in the erythrocyte membrane protein, and its common clinical manifestations include hemolysis, anemia, jaundice, splenomegaly, etc. Dubin-Johnson syndrome (DJS), which commonly results in jaundice, is a benign hereditary disorder of bilirubin clearance that occurs only rarely. The co-occurrence of HS and DJS is extremely rare^[1] and leads to severe jaundice. We recently diagnosed and treated a case of co-occurring HS and DJS in a patient who had severe jaundice and moderate anemia intensified by the infection of the upper respiratory tract. We applied next generation sequencing (NGS) to arrive at a definite diagnosis. The case is reported as follows.

CASE PRESENTATION

Chief complaints

A 21-year-old female patient presented to our department on November 10, 2017 because of severe jaundice, severe splenomegaly, and mild anemia since birth (Table 1).

History of past illness

She did not undergo irradiation treatment. When she was two years old, the yellow staining was intensified in her skin and sclera and she started having dark brown urine. Other clinical manifestations included anemia, splenomegaly, and elevated bilirubin, but her transaminases were normal. All later clinicians that she visited could not clarify her situation any further except for giving the diagnosis of "hemolytic anemia" and did not advise any treatment either. Her history of past illness was negative. She did not receive blood transfusion or surgery. Her regular blood routine testing showed the following: WBC $8.4-10.8 \times 10^9/L$ (normal: $4-10 \times 10^9/L$), hemoglobin (HGB) $106-111 g/L$ ($110-150 g/L$), platelets (PLT) $186-241 \times 10^9/L$ ($100-300 \times 10^9/L$), percentage of neutrophils (NE%) $56.9\%-60.5\%$ (normal: $50\%-70\%$), percentage of lymphocytes (LY%) $33.1\%-34.7\%$ (normal: $20\%-40\%$), and percentage of reticulocytes (RET%) $7.8\%-11.3\%$ (normal: $0.5\%-1.5\%$). Her liver function results were: Total bilirubin (TBIL) $132-162.8 \mu mol/L$ (normal: $5.0-21.0 \mu mol/L$), direct bilirubin (DBIL) $34.4-40 \mu mol/L$ (normal: $0-3.4 \mu mol/L$), and indirect bilirubin (IBIL) $98.6-137 \mu mol/L$ (normal: $0-13.6 \mu mol/L$). She experienced intensified anemia and jaundice upon fatigue or infection. She sought further diagnosis of her situation in her current visit to our clinic.

Personal and family history

She was the only child of her family and her parents had no similar clinical manifestations including anemia, splenomegaly, and elevated bilirubin.

Physical examination

On physical examination, the patient demonstrated obvious anemic appearance and intense yellowing of the skin, without any edema. The liver was not palpable, but the spleen was palpable at 6 cm below the rib margin.

Laboratory examinations

Blood tests gave the following results: WBC $4.58 \times 10^9/L$ (normal: $4-10 \times 10^9/L$),

Table 1 The characteristics of the patient

Gender	Age	Onset age	Symptoms and signs
Female	21 years	Since birth	Anemia, severe jaundice, splenomegaly
Laboratory examination		Before treatment	After treatment
HGB (g/L)		105	114
ARC ($\times 10^{12}$ /L)		0.2083	N/E
TBIL ($\mu\text{mol/L}$)		111.8	88.69
DBIL ($\mu\text{mol/L}$)		35.4	29.9
IBIL ($\mu\text{mol/L}$)		76.4	58.79
DBIL/TBIL (%)		31.7	33.7
NGS results			
<i>A de novo</i> heterozygous mutation of the <i>SPTB</i> gene, c.2413 C > T (p.Gln805*)			
The mutation of the <i>ABCC2</i> gene from the father: c.4313+1 G > T			
The mutation of the <i>ABCC2</i> gene from the mother c.3629 G > A (R1210H)			

absolute neutrophil count (ANC) $3.22 \times 10^9/\text{L}$ (normal: $2-7 \times 10^9/\text{L}$), red blood cells (RBC) $2.64 \times 10^{12}/\text{L}$ (normal: $3.5-5 \times 10^{12}/\text{L}$), HGB 85 g/L (normal: 110-150 g/L), mean corpuscular volume 87.9 fL (normal: 80-100 fL), mean corpuscular hemoglobin 32.2 pg (normal: 27-34 pg), mean corpuscular hemoglobin concentration 366 g/L (normal: 320-360 g/L), PLTs $170 \times 10^9/\text{L}$ (normal: $100-300 \times 10^9/\text{L}$), RET% 7.89% (normal: 0.5%-1.5%), and ARC $0.2083 \times 10^{12}/\text{L}$ (normal: $0.024-0.084 \times 10^{12}/\text{L}$). The urine test gave all normal results except for elevated urobilinogen (+). The liver and kidney function tests showed: total protein 69.4 g/L (normal: 66-83 g/L), albumin 42.2 g/L (normal: 35-52 g/L), globulin 27.2 g/L (normal: 20-35 g/L), alanine aminotransferase 9.7 U/L (normal: 0-35 U/L), aspartate aminotransferase 11.6 U/L (normal: 0-35 U/L), alkaline phosphatase 50.4 U/L (normal: 30-120 U/L), γ -glutamyl transpeptidase 9.5 U/L (normal: 8-57 U/L), TBIL 111.8 $\mu\text{mol/L}$ (normal: 5.0-21.0 $\mu\text{mol/L}$), DBIL 35.4 $\mu\text{mol/L}$ (normal: 0-3.4 $\mu\text{mol/L}$), DBIL/TBIL ratio 31.7% (normal: 20%), IBIL 76.4 $\mu\text{mol/L}$ (normal: 0-13.6 $\mu\text{mol/L}$), blood urea nitrogen 2.54 mmol/L (normal: 2.8-7.6 mmol/L), creatinine 58.3 $\mu\text{mol/L}$ (normal: 49-90 $\mu\text{mol/L}$), uric acid 362 $\mu\text{mol/L}$ (normal: 154.7-357 $\mu\text{mol/L}$), and lactate dehydrogenase 189.6 U/L (normal: 0-248 U/L). Hemolysis test showed reduced plasma haptoglobin (0.375 g/L; normal: 0.5-2.0 g/L), and plasma-free hemoglobin was 37.1 mg/L (normal: 0-40 mg/L). Eosin-5'-maleimide (EMA) flow cytometry showed that the mean fluorescence intensity attenuation of the RBC EMA was 23.41% (normal: <16%). The RBC osmotic fragility (EOF) test showed that hemolysis started at 0.6% (normal: 0.44%) and completed at 0.36% (normal: 0.32%). The acidified glycerol lysis test (AGLT50) gave a result of 60 s (normal: >290 s).

The patient was found negative in the hemoglobin A2 test, anti-alkaline hemoglobin test, heat instability test, hemoglobin acetate membrane electrophoresis, direct Coombs test, cold agglutinin test, denatured globin corpuscle test, isopropanol test, methemoglobin reduction test, and acid hemolysis test. The patient had normal activities of erythrocyte pyruvate kinase, erythrocyte pyrimidine 5'-nucleotidase, 6-phosphate glucose dehydrogenase, and erythrocyte glucose phosphate isomerase, and there was no anomaly in immunoglobulin quantification, antinuclear antibody, *etc.* Iliac marrow smear showed obviously active hyperplasia, with 44% (normal: 40%-60%) of granulocytes and 48.5% (normal: 15%-25%) of erythrocytes. The peripheral blood smear was rich in small spherical RBC, which accounted for 70% of the mature RBC. Bone marrow autopsy showed relatively normal (50%) myeloproliferation based on HE and PAS staining, as well as escalated erythrocytes/granulocytes ratio. The reticular fiber dyeing result was MF-0. The karyotype was 46. An abdominal CT scan showed enlarged spleen with minor effusion. The liver had normal size, proportionate lobes, and parenchyma of uniform density. The intrahepatic and extrahepatic bile ducts showed no sign of dilation, and the hepatic portal had a clear structure. No anomaly was observed for the gallbladder, pancreas, kidneys, or abdominal cavity. Abdominal ultrasound examination showed hyperechogenic liver parenchyma, moderately enlarged spleen, as well as normal gallbladder and pancreas. Hence, as a result of the preceding clinical findings, the patient was diagnosed with HS.

Imaging examinations

However, because of the extraordinary jaundice of the patient, whole exome sequencing was carried out additionally after the diagnosis of HS.

DNA for NGS was extracted from peripheral blood of the patient and her parents. Agarose electrophoresis, Qubit 2.0 fluorometer dsDNA HS Assay (Thermo Fisher Scientific), and 2100 Bioanalyzer and Herculase II Fusion DNA Polymerase (Agilent) were used for DNA library preparation according to the instructions. Targeted fragments were captured with exome capture probes (Aligent) and sequenced on the Illumina HiSeq X platform following Illumina-provided protocols. The sequencing quality was determined with FastQC software. After data filtration, the clean reads were mapped to human reference genome (hg19) using SentieonBWA software. Then, the mapped reads were used to detect SNV and InDel with Sentieon (the same algorithm with GATK), and annotated using ANNOVAR/VEP software. All the variants were annotated with VEP software and the pathogenic variants were screened by ClinVar, OMIM, and HGMD. Function prediction of missense mutations and annotation of non-coding sequences were performed with PolyPhen-2 and Sorting Intolerant from Tolerant (SIFT).

Blood (2 mL) was drawn for Sanger sequencing from the patient and her healthy parents. All the suspicious pathogenic variants were validated in the patient and her parents using Sanger sequencing. Primers were designed with Primer 3 software, and BLAST in NCBI database was used to confirm specificity. PCR amplification product was sequenced with an ABI 3500D x DNA Analyser (Applied Biosystems, Foster City, CA, United States) and analyzed with sequencing analysis software (Thermo Fisher).

The sequencing results revealed a *de novo* heterozygous mutation of the *SPTB* gene (NM_000347.5), c.2413C > T (p.Gln805*), as well as two inherited novel heterozygous mutations of the *ABCC2* gene (NM_000392.4), c.4313+1 G > T from the father and c.3629G > A (R1210H) from the mother (Figure 1). Neither of these mutations had been observed in the Clin Var, OMIM, and HGMD databases, indicating that these variants are very rare. All three mutations were predicted to be harmful and pathogenic with PolyPhen-2 and SIFT. These mutations were identified as pathogenic variants following the 2013 ACMG guidelines^[2].

FINAL DIAGNOSIS

The final diagnosis was co-existence of HS and DJS.

TREATMENT

The patient was recommended to receive oral doses of ursodeoxycholic acid and phenobarbital in addition to splenectomy. She refused splenectomy and was then discharged.

OUTCOME AND FOLLOW-UP

The patient first took ursodeoxycholic acid in combination with phenobarbital for three months. The treatment successfully increased HGB to 114 g/L (normal: 110-150 g/L) and reduced TBIL to 88.69 µmol/L (normal: 5.0-21.0 µmol/L), DBIL to 29.9 µmol/L (normal: 0-3.4 µmol/L), DBIL/TBIL to 33.7% (normal: 20%), and IBIL to 58.79 µmol/L (normal: 0-13.6 µmol/L).

DISCUSSION

The diagnosis of HS was straightforward. Hemolytic anemia could be readily inferred since the patient experienced the symptoms since birth. Anemia, jaundice, enlarged spleen, increased reticulocytes in peripheral blood, and marrow morphology all pointed to proliferative anemia. The key evidence of HS included notable increase in the small spherical mature RBC in the peripheral blood smear, escalated RBC osmotic fragility in the EOF and AGLT50 tests, and notable defect of erythrocyte membrane protein in the EMA test. The genome sequencing revealed heterozygous mutation of the *SPTB* gene and thus verified the diagnosis of HS.

Although the patient was clearly diagnosed with moderate HS, this could not convincingly account for the severe jaundice and the significantly elevated levels of TBIL, DBIL, and IBIL. Since the imaging results clearly excluded any obstruction of intrahepatic and extrahepatic bile ducts, and the activities of all liver enzymes were

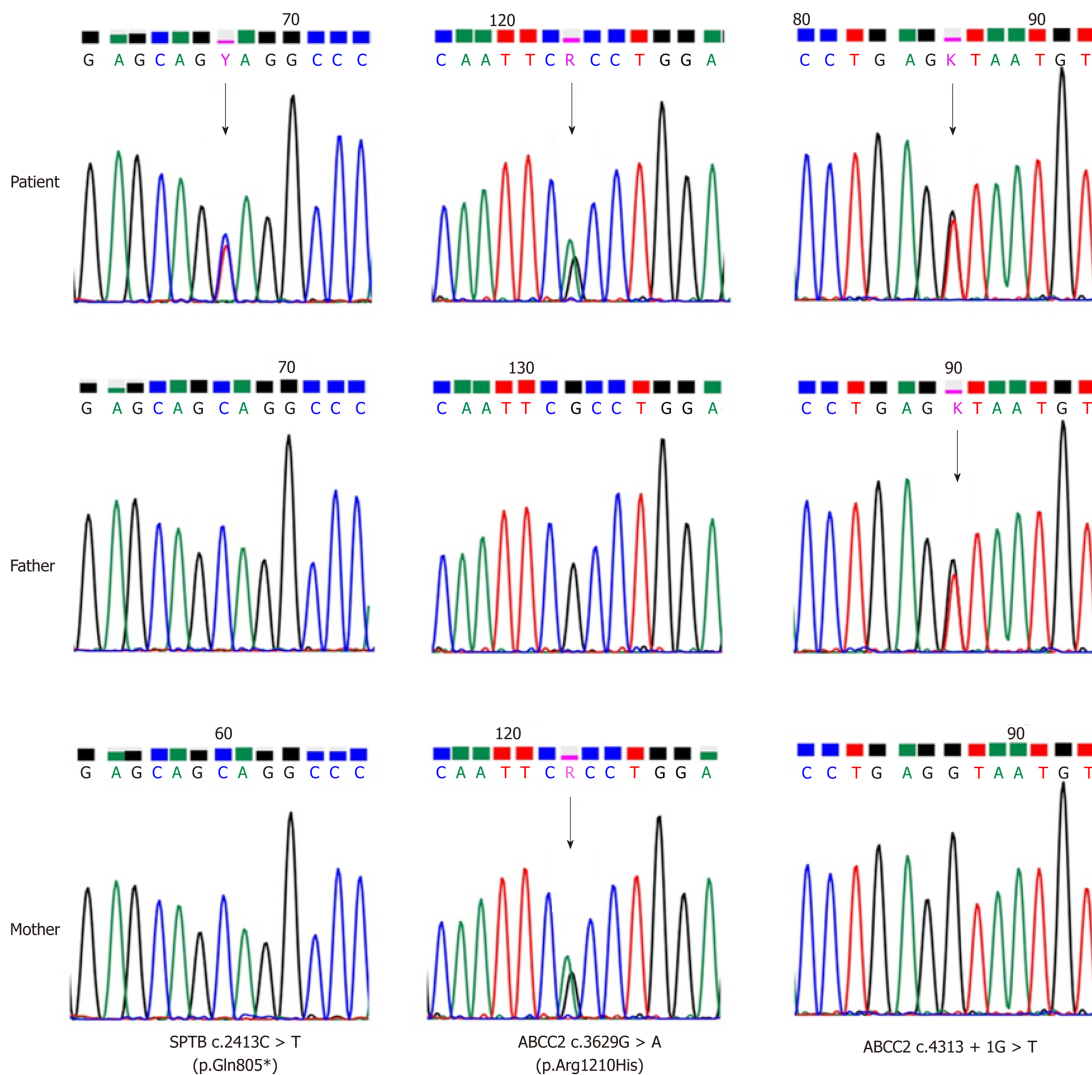


Figure 1 Sanger sequencing confirmed a *de novo* heterozygous mutation of the *SPTB* gene (NM_000347.5). c.2413 C > T (p.Gln805*), and two inherited novel heterozygous mutations of the *ABCC2* gene (NM_000392.4), c.4313+1 G > T from the father and c.3629 G > A (R1210H) from the mother, are shown.

found normal, the observed degree of hemolysis did not suffice to reasonably explain the severity of jaundice. Consequently, we suspected that another disease aside from HS was likely, and we naturally turned out attention to two hereditary disorders of bilirubin clearance, *i.e.*, DJS and the Rotor syndrome (RS), because the patient had experienced elevated DBIL since birth and showed normal liver enzymes without abnormality in the liver and bile duct images.

DJS, first reported in 1954^[3], is a rare, chronic, benign, autosomal recessive disorder characterized by elevated DBIL along with normal liver function. Its pathogenesis has been largely clarified and could be accounted by the mutation of the *ABCC2* gene.

The human *ABCC2* gene is located at chromosome 10q24, and its introns and exons have been well sequenced. The *ABCC2* gene has 32 exons that encode the *ABCC2* transporter, *i.e.*, the multidrug resistance-associated protein 2. The *ABCC2* transporter is an ATP-binding cassette transporter at the apical membrane of hepatocytes consisting of 1545 amino acids. It is the major carrier that is responsible for transporting bilirubin into bile, and it becomes activated by the ATP hydrolysis of two ATP-binding regions to expel the substrate outside the cell *via* an energy dissipation process. Mutation of the *ABCC2* gene in the DJS patients leads to defected *ABCC2* transporter and thus impaired ability to transport DBIL into the bile, and the high serum DBIL in turn results in jaundice.

To date, 34 kinds of *ABCC2* mutations have been found in DJS patients^[4-17], including 6 kinds of nonsense mutations (17.4%), 14 kinds of missense mutations (41.2%), 4 kinds of small deletions (11.8%), 4 kinds of splice mutations (11.8%), and 6 kinds of large deletions (17.4%). At least 23 mutations (67.6%) of the total 34 are predicted to be harmful. The mutations may result in the maturity disorder or positioning error of the *ABCC2* transporter and reduce the protein

activity^[18]. Compound heterozygous mutations were found in the *ABCC2* gene of this patient, which were all previously unreported missense mutations.

The c.4313+1 G > T mutation from the father was located at the boundary between the 30th exon and the 30th intron of the *ABCC2* gene (*i.e.*, the donor point). It could result in exon skipping and was predicted to be pathogenic. The c.3629 G > A (R1210H) mutation from the mother was located at the 26th exon of the *ABCC2* gene, which is responsible for expressing the cytoplasmic side of the membrane-spanning domain 2 of the *ABCC2* transporter^[5]. This mutation was also predicted to be pathogenic and could be involved in this disease. Therefore, both parents of the patient carried *ABCC2* mutations but had a normal phenotype, which is in agreement with the genetics of the DJS. Therefore, the diagnosis of DJS could be established unequivocally. More data on the *ABCC2* transporter and DJS patients are needed to clarify the relationship between the genotype and phenotype of DJS patients, since mutations occur across the entire *ABCC2* gene and no hotspot mutation has been discovered to date.

NGS is not yet a regular examination in the diagnosis of DJS. Current clinical diagnosis of DJS generally requires liver function tests, urinary coproporphyrin excretion, liver histopathology (sampled by liver puncture), and sodium bromosulfonate (BSP) test. Diagnosis can be made when the following evidence is gathered: The liver function tests show normal enzyme activities and elevated DBIL (usually 34.2–85.5 µmol/L); urinary coproporphyrin excretion show normal results and 80% of the discharged porphyrin is type I coproporphyrin; the liver histopathology showed “black liver” due to the diffusive deposition of lipofuscin-melanin complex in the hepatocytes^[19]. Although sodium bromosulfonate test is no longer used in clinical practice and has been a redundant test over many years, the retention of BSP is normal or slightly elevated at 45 min, and is further increased at 90 and 120 min, indicating that upon the maximum excretion of BSP, the transportation of BSP by the liver declines notably and the storage of BSP decreases only slightly^[19], which helps in understanding the dynamics of bilirubin metabolism.

Despite the additional cost required by NGS, we recommend adopting NGS as a regular examination for the diagnosis of DJS because of the following advantages. First, NGS is very simple to operate and circumvents the tedious procedures required in the BSP test and urinary coproporphyrin excretion. In addition, NGS commonly only requires sampling peripheral blood and is thus much safer and less invasive than the liver puncture required by histopathology examination, therefore avoiding the risk of serious complications such as peritonitis. More importantly, the high accuracy of NGS allows the direct identification of the pathogenic gene, simplifies the diagnosis procedures, and improves the efficiency, which is particularly advantageous in distinguishing DJS and RS.

RS is rare autosomal recessive disorder of bilirubin clearance. It is characterized by the disorder of hepatocytes in the storage and uptake of bilirubin due to the mutation of *SLCO1B1*/*OATP1B1* or *SLCO1B3*/*OATP1B3* genes, and it is clinically manifested as jaundice^[20]. The phenotypes of DJS and RS cannot be differentiated clinically, although RS is also diagnosed after liver function tests, urinary coproporphyrin excretion, liver histopathology (sampled by liver puncture), and BSP test. Since the current patient had elevated serum bilirubin due to HS, it was highly difficult (if possible) to determine by conventional tests if DJS or RS was occurring. However, this problem was easily solved by NGS, since the heterozygous mutation of *ABCC2* was detected while the mutations of *SLCO1B1*/*OATP1B1* and *SLCO1B3*/*OATP1B3* were excluded. Therefore, RS was ruled out for the patient, and NGS greatly simplified the diagnosis by obviating the standard cumbersome tests.

Splenectomy is the classical treatment for HS. The patient showed the indications for splenectomy since she already had moderate HS, although she declined surgery. Since DJS normally has a good prognosis, no special treatment is necessary and DJS patients only need to avoid situations that may aggravate jaundice such as fatigue and infection. Nevertheless, because the combination of DJS and HS posed a significant risk for cholelithiasis in this patient, ursodeoxycholic acid and phenobarbital are the recommended medications^[12]. This patient showed improvements after taking these two drugs.

CONCLUSION

In summary, to the best of our knowledge, the current case is probably the first case that was definitively diagnosed with the co-occurrence of HS and DJS by NGS. We suggest that inherited disorders of bilirubin clearance should be investigated if patients with inherited hemolytic anemia present with severe hyperbilirubinemia. The

routine application of NGS is also recommend to efficiently render a definite diagnosis when inherited disorders are suspected.

REFERENCES

- 1 **Korkmaz U**, Duman AE, Oğütmen Koç D, Gürbüz Y, Dındar G, Ensaroğlu F, Sener SY, Sentürk O, Hülagü S. Severe jaundice due to coexistence of Dubin-Johnson syndrome and hereditary spherocytosis: a case report. *Turk J Gastroenterol* 2011; **22**: 422-425 [PMID: [21948575](#) DOI: [10.4318/tjg.2011.0261](#)]
- 2 **Rehm HL**, Bale SJ, Bayrak-Toydemir P, Berg JS, Brown KK, Deignan JL, Friez MJ, Funke BH, Hegde MR, Lyon E; Working Group of the American College of Medical Genetics and Genomics Laboratory Quality Assurance Committee. ACMG clinical laboratory standards for next-generation sequencing. *Genet Med* 2013; **15**: 733-747 [PMID: [23887774](#) DOI: [10.1038/gim.2013.92](#)]
- 3 **Dubin IN**, Johnson FB. Chronic idiopathic jaundice with unidentified pigment in liver cells; a new clinicopathologic entity with a report of 12 cases. *Medicine (Baltimore)* 1954; **33**: 155-197 [PMID: [13193360](#) DOI: [10.1097/00005792-195409000-00001](#)]
- 4 **Wada M**, Toh S, Taniguchi K, Nakamura T, Uchiumi T, Kohno K, Yoshida I, Kimura A, Sakisaka S, Adachi Y, Kuwano M. Mutations in the canalicular multispecific organic anion transporter (cMOAT) gene, a novel ABC transporter, in patients with hyperbilirubinemia II/Dubin-Johnson syndrome. *Hum Mol Genet* 1998; **7**: 203-207 [PMID: [9425227](#) DOI: [10.1093/hmg/7.2.203](#)]
- 5 **Toh S**, Wada M, Uchiumi T, Inokuchi A, Makino Y, Horie Y, Adachi Y, Sakisaka S, Kuwano M. Genomic structure of the canalicular multispecific organic anion-transporter gene (MRP2/cMOAT) and mutations in the ATP-binding-cassette region in Dubin-Johnson syndrome. *Am J Hum Genet* 1999; **64**: 739-746 [PMID: [10053008](#) DOI: [10.1086/302292](#)]
- 6 **Mor-Cohen R**, Zivelin A, Rosenberg N, Shani M, Muallem S, Seligsohn U. Identification and functional analysis of two novel mutations in the multidrug resistance protein 2 gene in Israeli patients with Dubin-Johnson syndrome. *J Biol Chem* 2001; **276**: 36923-36930 [PMID: [11477083](#) DOI: [10.1074/jbc.M105047200](#)]
- 7 **Tate G**, Li M, Suzuki T, Mitsuya T. A new mutation of the ATP-binding cassette, sub-family C, member 2 (ABCC2) gene in a Japanese patient with Dubin-Johnson syndrome. *Genes Genet Syst* 2002; **77**: 117-121 [PMID: [12087194](#) DOI: [10.1266/ggs.77.117](#)]
- 8 **Wakusawa S**, Machida I, Suzuki S, Hayashi H, Yano M, Yoshioka K. Identification of a novel 2026G-->C mutation of the MRP2 gene in a Japanese patient with Dubin-Johnson syndrome. *J Hum Genet* 2003; **48**: 425-429 [PMID: [12884082](#) DOI: [10.1007/s10038-003-0052-0](#)]
- 9 **Shoda J**, Suzuki H, Suzuki H, Sugiyama Y, Hirouchi M, Utsunomiya H, Oda K, Kawamoto T, Matsuzaki Y, Tanaka N. Novel mutations identified in the human multidrug resistance-associated protein 2 (MRP2/ABCC2) gene in a Japanese patient with Dubin-Johnson syndrome. *Hepatol Res* 2003; **27**: 323-326 [PMID: [14662121](#) DOI: [10.1016/S1386-6346\(03\)00267-5](#)]
- 10 **Cebecauerova D**, Jirasek T, Budisova L, Mandys V, Volf V, Novotna Z, Subhanova I, Hrebicek M, Elleder M, Jirsa M. Dual hereditary jaundice: simultaneous occurrence of mutations causing Gilbert's and Dubin-Johnson syndrome. *Gastroenterology* 2005; **129**: 315-320 [PMID: [16012956](#) DOI: [10.1053/j.gastro.2004.10.009](#)]
- 11 **Machida I**, Wakusawa S, Sanae F, Hayashi H, Kusakabe A, Ninomiya H, Yano M, Yoshioka K. Mutational analysis of the MRP2 gene and long-term follow-up of Dubin-Johnson syndrome in Japan. *J Gastroenterol* 2005; **40**: 366-370 [PMID: [15870973](#) DOI: [10.1007/s00535-004-1555-y](#)]
- 12 **Lee JH**, Chen HL, Chen HL, Ni YH, Hsu HY, Chang MH. Neonatal Dubin-Johnson syndrome: long-term follow-up and MRP2 mutations study. *Pediatr Res* 2006; **59**: 584-589 [PMID: [16549534](#) DOI: [10.1203/01.pdr.0000203093.10908.bb](#)]
- 13 **Pacifico L**, Carducci C, Poggiogalle E, Caravona F, Antonozzi I, Chiesa C, Maggiore G. Mutational analysis of ABCC2 gene in two siblings with neonatal-onset Dubin Johnson syndrome. *Clin Genet* 2010; **78**: 598-600 [PMID: [21044052](#) DOI: [10.1111/j.1399-0004.2010.01497.x](#)]
- 14 **Devgun MS**, El-Nujumi AM, O'Dowd GJ, Barbu V, Poupon R. Novel mutations in the Dubin-Johnson syndrome gene ABCC2/MRP2 and associated biochemical changes. *Ann Clin Biochem* 2012; **49**: 609-612 [PMID: [23065530](#) DOI: [10.1258/acb.2012.011279](#)]
- 15 **Uchiumi T**, Tanamachi H, Kuchiwaki K, Kajita M, Matsumoto S, Yagi M, Kanki T, Kang D. Mutation and functional analysis of ABCC2/multidrug resistance protein 2 in a Japanese patient with Dubin-Johnson syndrome. *Hepatol Res* 2013; **43**: 569-575 [PMID: [23045960](#) DOI: [10.1111/j.1872-034X.2012.01103.x](#)]
- 16 **Sticova E**, Elleder M, Hulkova H, Luksan O, Sauer M, Wunschova-Moudra I, Novotny J, Jirsa M. Dubin-Johnson syndrome coinciding with colon cancer and atherosclerosis. *World J Gastroenterol* 2013; **19**: 946-950 [PMID: [23429660](#) DOI: [10.3748/wjg.v19.i6.946](#)]
- 17 **Baranguán Castro ML**, García Romero R, Miramar Gallart MD. Conjugated hyperbilirubinemia after surgery. A diagnosis of Dubin-Johnson syndrome confirmed by genetic testing. *Rev Esp Enferm Dig* 2017; **109**: 801-802 [PMID: [29032691](#) DOI: [10.17235/reed.2017.4989/2017](#)]
- 18 **Erlinger S**, Arias IM, Dhumeaux D. Inherited disorders of bilirubin transport and conjugation: new insights into molecular mechanisms and consequences. *Gastroenterology* 2014; **146**: 1625-1638 [PMID: [24704527](#) DOI: [10.1053/j.gastro.2014.03.047](#)]
- 19 **Strassburg CP**. Hyperbilirubinemia syndromes (Gilbert-Meulengracht, Crigler-Najjar, Dubin-Johnson, and Rotor syndrome). *Best Pract Res Clin Gastroenterol* 2010; **24**: 555-571 [PMID: [20955959](#) DOI: [10.1016/j.bpg.2010.07.007](#)]
- 20 **van de Steeg E**, Stránecký V, Hartmannová H, Nosková L, Hřebíček M, Wagenaar E, van Esch A, de Waart DR, Oude Elferink RP, Kenworthy KE, Sticová E, al-Edreesi M, Knisely AS, Kmoch S, Jirsa M, Schinkel AH. Complete OATP1B1 and OATP1B3 deficiency causes human Rotor syndrome by interrupting conjugated bilirubin reuptake into the liver. *J Clin Invest* 2012; **122**: 519-528 [PMID: [22232210](#) DOI: [10.1172/JCI59526](#)]



Published By Baishideng Publishing Group Inc
7041 Koll Center Parkway, Suite 160, Pleasanton, CA 94566, USA
Telephone: +1-925-2238242
E-mail: bpgoffice@wjgnet.com
Help Desk: <https://www.f6publishing.com/helpdesk>
<https://www.wjgnet.com>

