

World Journal of *Clinical Cases*

World J Clin Cases 2019 August 26; 7(16): 2134-2412



**REVIEW**

- 2134** Role of infrapatellar fat pad in pathological process of knee osteoarthritis: Future applications in treatment
Jiang LF, Fang JH, Wu LD

MINIREVIEWS

- 2143** Application of Newcastle disease virus in the treatment of colorectal cancer
Song H, Zhong LP, He J, Huang Y, Zhao YX

ORIGINAL ARTICLE**Basic Study**

- 2155** Reduced microRNA-451 expression in eutopic endometrium contributes to the pathogenesis of endometriosis
Gao S, Liu S, Gao ZM, Deng P, Wang DB

Case Control Study

- 2165** Application of self-care based on full-course individualized health education in patients with chronic heart failure and its influencing factors
Sun J, Zhang ZW, Ma YX, Liu W, Wang CY

Retrospective Study

- 2176** Predicting surgical site infections using a novel nomogram in patients with hepatocellular carcinoma undergoing hepatectomy
Tang TY, Zong Y, Shen YN, Guo CX, Zhang XZ, Zou XW, Yao WY, Liang TB, Bai XL
- 2189** Serological investigation of IgG and IgE antibodies against food antigens in patients with inflammatory bowel disease
Wang HY, Li Y, Li JJ, Jiao CH, Zhao XJ, Li XT, Lu MJ, Mao XQ, Zhang HJ
- 2204** Incidence of infectious complications is associated with a high mortality in patients with hepatitis B virus-related acute-on-chronic liver failure
Wang C, Ma DQ, Luo S, Wang CM, Ding DP, Tian YY, Ao KJ, Zhang YH, Chen Y, Meng ZJ

Clinical Trials Study

- 2217** R/S ratio in lead II, and the prognostic significance of red cell distribution width in acute coronary syndrome
Coşkun A, Eren SH

- 2227** Comparative analysis of APACHE-II and P-POSSUM scoring systems in predicting postoperative mortality in patients undergoing emergency laparotomy
Nag DS, Dembla A, Mahanty PR, Kant S, Chatterjee A, Samaddar DP, Chugh P

Observational Study

- 2238** TAZ and myostatin involved in muscle atrophy of congenital neurogenic clubfoot
Sun JX, Yang ZY, Xie LM, Wang B, Bai N, Cai AL

Prospective Study

- 2247** Effects of dual sofosbuvir/daclatasvir therapy on, chronic hepatitis C infected, survivors of childhood malignancy
El-Shabrawi MH, Sherief LM, Yakoot M, Kamal NM, Almalky MA, AbdElgawad MM, Mahfouz AA, Helmy S, Kamal EM, Attia D, El-Khayat HR

Randomized Controlled Trial

- 2256** Hypoallergenicity of a thickened hydrolyzed formula in children with cow's milk allergy
Rossetti D, Cucchiara S, Morace A, Leter B, Oliva S

SYSTEMATIC REVIEWS

- 2269** Surveillance and diagnosis of hepatocellular carcinoma: A systematic review
Pascual S, Miralles C, Bernabé JM, Irurzun J, Planells M

META-ANALYSIS

- 2287** Neuraxial adjuvants for prevention of perioperative shivering during cesarean section: A network meta-analysis following the PRISMA guidelines
Zhang YW, Zhang J, Hu JQ, Wen CL, Dai SY, Yang DF, Li LF, Wu QB

CASE REPORT

- 2302** Primary malignant melanoma of the biliary tract: A case report and literature review
Cameselle-García S, Pérez JLF, Areses MC, Castro JD, Mosquera-Reboredo J, García-Mata J
- 2309** Successful treatment of tubulointerstitial nephritis in immunoglobulin G4-related disease with rituximab: A case report
Eroglu E, Sipahioglu MH, Senel S, Ertas SK, Savas S, Ozturk F, Kocyigit I, Tokgoz B, Oymak O
- 2316** Effectiveness of vedolizumab treatment in two different anti-tumor necrosis factor alpha refractory pouchitis: A case report
Cakir OO
- 2322** Clinical outcomes and safety of high-resolution manometry guided superficial partial circular muscle myotomy in per-oral endoscopic myotomy for Jackhammer esophagus: Two cases report
Choi YI, Kim KO, Park DK, Chung JW, Kim YJ, Kwon KA

- 2330** Cardiac arrhythmias and cardiac arrest related to mushroom poisoning: A case report
Li S, Ma QB, Tian C, Ge HX, Liang Y, Guo ZG, Zhang CD, Yao B, Geng JN, Riley F
- 2336** Role of abdominal drainage in bariatric surgery: Report of six cases
Liu Y, Li MY, Zhang ZT
- 2341** A patient misdiagnosed with central serous chorioretinopathy: A case report
Wang TY, Wan ZQ, Peng Q
- 2346** Large carotid body tumor successfully resected in hybrid operating theatre: A case report
Li MQ, Zhao Y, Sun HY, Yang XY
- 2352** A huge pancreatic lipoma mimicking a well-differentiated liposarcoma: A case report and systematic literature review
Xiao RY, Yao X, Wang WL
- 2360** Ulcerative colitis complicated with colonic necrosis, septic shock and venous thromboembolism: A case report
Zhu MY, Sun LQ
- 2367** Acute pancreatitis connected with hypercalcemia crisis in hyperparathyroidism: A case report
Ma YB, Hu J, Duan YF
- 2374** Treatment of invasive fungal disease: A case report
Xiao XF, Wu JX, Xu YC
- 2384** Hepatocellular carcinoma successfully treated with ALPPS and apatinib: A case report
Liu L, Li NF, Zhang Q, Lin L
- 2393** Pseudothrombus deposition accompanied with minimal change nephrotic syndrome and chronic kidney disease in a patient with Waldenström's macroglobulinemia: A case report
Mwamunyi MJ, Zhu HY, Zhang C, Yuan YP, Yao LJ
- 2401** *Ex vivo* revascularization of renal artery aneurysms in a patient with solitary kidney: A case report
Chen XY, Zhao JC, Huang B, Yuan D, Yang Y
- 2406** Malignant syphilis accompanied with neurosyphilis in a malnourished patient: A case report
Ge G, Li DM, Qiu Y, Fu HJ, Zhang XY, Shi DM

ABOUT COVER

Editorial Board Member of *World Journal of Clinical Cases*, Manabu Watanabe, MD, PhD, Full Professor, Division of Gastroenterology and Hepatology, Department of Internal Medicine, Toho University Medical Center, Ohashi Hospital, Tokyo 153-8515, Japan

AIMS AND SCOPE

World Journal of Clinical Cases (*World J Clin Cases*, *WJCC*, online ISSN 2307-8960, DOI: 10.12998) is a peer-reviewed open access academic journal that aims to guide clinical practice and improve diagnostic and therapeutic skills of clinicians.

The primary task of *WJCC* is to rapidly publish high-quality Case Report, Clinical Management, Editorial, Field of Vision, Frontier, Medical Ethics, Original Articles, Meta-Analysis, Minireviews, and Review, in the fields of allergy, anesthesiology, cardiac medicine, clinical genetics, clinical neurology, critical care, dentistry, dermatology, emergency medicine, endocrinology, family medicine, gastroenterology and hepatology, etc.

INDEXING/ABSTRACTING

The *WJCC* is now indexed in PubMed, PubMed Central, Science Citation Index Expanded (also known as SciSearch®), and Journal Citation Reports/Science Edition. The 2019 Edition of Journal Citation Reports cites the 2018 impact factor for *WJCC* as 1.153 (5-year impact factor: N/A), ranking *WJCC* as 99 among 160 journals in Medicine, General and Internal (quartile in category Q3).

RESPONSIBLE EDITORS FOR THIS ISSUE

Responsible Electronic Editor: Ji-Hong Liu

Proofing Production Department Director: Yun-Xiaojuan Wu

NAME OF JOURNAL

World Journal of Clinical Cases

ISSN

ISSN 2307-8960 (online)

LAUNCH DATE

April 16, 2013

FREQUENCY

Semimonthly

EDITORS-IN-CHIEF

Dennis A Bloomfield, Sandro Vento

EDITORIAL BOARD MEMBERS

<https://www.wjgnet.com/2307-8960/editorialboard.htm>

EDITORIAL OFFICE

Jin-Lei Wang, Director

PUBLICATION DATE

August 26, 2019

COPYRIGHT

© 2019 Baishideng Publishing Group Inc

INSTRUCTIONS TO AUTHORS

<https://www.wjgnet.com/bpg/gerinfo/204>

GUIDELINES FOR ETHICS DOCUMENTS

<https://www.wjgnet.com/bpg/GerInfo/287>

GUIDELINES FOR NON-NATIVE SPEAKERS OF ENGLISH

<https://www.wjgnet.com/bpg/gerinfo/240>

PUBLICATION MISCONDUCT

<https://www.wjgnet.com/bpg/gerinfo/208>

ARTICLE PROCESSING CHARGE

<https://www.wjgnet.com/bpg/gerinfo/242>

STEPS FOR SUBMITTING MANUSCRIPTS

<https://www.wjgnet.com/bpg/GerInfo/239>

ONLINE SUBMISSION

<https://www.f6publishing.com>

Cardiac arrhythmias and cardiac arrest related to mushroom poisoning: A case report

Shu Li, Qing-Bian Ma, Ci Tian, Hong-Xia Ge, Yang Liang, Zhi-Guo Guo, Cheng-Duo Zhang, Bei Yao, Jia-Ning Geng, Fran Riley

ORCID number: Shu Li (0000-0002-6073-6285); Qing-Bian Ma (0000-0002-0123-3522); Ci Tian (0000-0002-6569-9364); Hong-Xia Ge (0000-0003-4162-9967); Yang Liang (0000-0002-4666-9653); Zhi-Guo Guo (0000-0003-4797-0920); Cheng-Duo Zhang (0000-0002-4178-2972); Bei Yao (0000-0002-9984-6588); Jia-Ning Geng (0000-0002-2681-7436); Fran Riley (0000-0002-0884-3585).

Author contributions: Li S and Tian C carried out the initial diagnosis and resuscitation; Ma QB, Ge HX, Liang Y, Guo ZG, and Tian C also played essential roles in providing critical healthcare throughout the hospital stay and clinical follow-up of the patient; Geng JN performed genome analysis of the mushrooms; Ma QB and Li S conceived the idea of possible publication of the case; Li S and Riley F were major contributors in the literature research and in the process of writing the manuscript; all authors read and approved the final manuscript.

Informed consent statement:

Written informed consent was obtained from the patient for anonymized information to be published in this article.

Conflict-of-interest statement: The authors declare that there is no conflict of interest.

CARE Checklist (2016) statement:

The authors have read the CARE Checklist (2016), and the manuscript was prepared and revised according to the CARE Checklist (2016).

Shu Li, Qing-Bian Ma, Ci Tian, Hong-Xia Ge, Yang Liang, Zhi-Guo Guo, Department of Emergency Medicine, Peking University Third Hospital, Beijing 100191, China

Cheng-Duo Zhang, Department of Cardiology, Peking University Third Hospital, Beijing 100191, China

Bei Yao, Department of Laboratory Medicine, Peking University Third Hospital, Beijing 100191, China

Jia-Ning Geng, Beijing Institute of Genomics, Chinese Academy of Sciences, Beijing 100101, China

Fran Riley, Department of Emergency Medicine, Maimonides Medical Center, Brooklyn, NY 11219, United States

Corresponding author: Qing-Bian Ma, MD, Associate Professor, Chairman, Chief Physician, Department of Emergency Medicine, Peking University Third Hospital, No. 49 North Garden Road, Haidian District, Beijing 100191, China. maqingbian@bjmu.edu.cn

Telephone: +86-10-82266699

Fax: +86-10-82264019

Abstract

BACKGROUND

Mushroom exposure is a global health issue. The manifestations of mushroom poisoning (MP) may vary. Some species have been reported as rhabdomyolytic, hallucinogenic, or gastrointestinal poisons. Critical or even fatal MPs are mostly attributable to *Amanita phalloides*, with the development of severe liver or renal failure. Myocardial injury and even cases mimicking ST-segment elevation myocardial infarction (STEMI) have been previously reported, while cardiac arrhythmia or cardiac arrest is not commonly seen.

CASE SUMMARY

We report a 68-year-old woman with MP who suffered from delirium, seizure, long QT syndrome on electrocardiogram (ECG), severe cardiac arrhythmias of multiple origins, and cardiac arrest. She was intubated and put on blood perfusion. Her kidney and liver functions were intact; creatine kinase-MB was mildly elevated, and then fell within normal range during her hospital stay. We sent the mushrooms she left for translation elongation factor subunit 1 α , ribosomal RNA gene sequence, and internal transcribed spacer sequence analyses. There were four kinds of mushrooms identified, two of which were

Open-Access: This article is an open-access article which was selected by an in-house editor and fully peer-reviewed by external reviewers. It is distributed in accordance with the Creative Commons Attribution Non Commercial (CC BY-NC 4.0) license, which permits others to distribute, remix, adapt, build upon this work non-commercially, and license their derivative works on different terms, provided the original work is properly cited and the use is non-commercial. See: <http://creativecommons.org/licenses/by-nc/4.0/>

Manuscript source: Unsolicited manuscript

Received: May 10, 2019

Peer-review started: May 14, 2019

First decision: June 12, 2019

Revised: June 14, 2019

Accepted: June 26, 2019

Article in press: June 27, 2019

Published online: August 26, 2019

P-Reviewer: Erkut B

S-Editor: Cui LJ

L-Editor: Wang TQ

E-Editor: Liu JH



found to be toxic.

CONCLUSION

This is the first time that we found cardiac toxicity caused by *Panaeolus subbalteatus* and *Conocybe lactea*, which were believed to be toxic to the liver, kidney, and brain. We suggest that intensive monitoring and ECG follow-up are essential to diagnose prolonged QT interval and different forms of tachycardia in MP patients, even without the development of severe liver or renal failure. The mechanisms need to be further investigated and clarified based on animal experiments and molecular signal pathways.

Key words: Mushroom poisoning; Arrhythmia; Cardiac arrest; Seizure; Case report

©The Author(s) 2019. Published by Baishideng Publishing Group Inc. All rights reserved.

Core tip: Critical or even fatal mushroom poisonings are mostly attributable to *Amanita phalloides*, with severe liver or renal failure developing. Myocardial injury was reported previously while cardiac arrhythmias of multiple origins or cardiac arrest are definitely rarely seen or reported in the literature. Also, this is the first time that we found cardiac toxicity caused by *Panaeolus subbalteatus* and *Conocybe lactea*, which were believed to be hepatic, renal, and brain toxic.

Citation: Li S, Ma QB, Tian C, Ge HX, Liang Y, Guo ZG, Zhang CD, Yao B, Geng JN, Riley F. Cardiac arrhythmias and cardiac arrest related to mushroom poisoning: A case report.

World J Clin Cases 2019; 7(16): 2330-2335

URL: <https://www.wjgnet.com/2307-8960/full/v7/i16/2330.htm>

DOI: <https://dx.doi.org/10.12998/wjcc.v7.i16.2330>

INTRADUCTION

Mycetism, widely known as mushroom poisoning (MP), is an international health care issue. Some species of mushroom are edible or even medicinal and have been proven to have antioxidative effects. Nonetheless, some species initially classified as edible were later recognized as toxic. In general, the majority of MPs are the result of misidentification while attempting to collect wild mushrooms. More unusual intentional ingestion of hallucinogenic species can occur with recreational use. The clinical manifestations of MP may vary. Fatal poisonings are mostly attributable to *Amanita phalloides*, causing liver and renal failure, while cardiac arrhythmia is not commonly seen.

Here, we present a case of MP in which the patient suffered from severe cardiac arrhythmias and cardiac arrest but was then totally cured at our hospital.

CASE PRESENTATION

Chief complaints

A 68-year-old female patient presented to the emergency department (ED) complaining of dizziness, visual changes, and slight hearing loss.

History of present illness

She had picked mushrooms 2 d ago at a roadside lawn in the community in which she lived in central Beijing. She ate cooked mushrooms for lunch 2 h prior to her admission and reported nausea, dizziness, visual and hearing changes as well as thirst 30 min after ingestion without any other symptoms.

History of past illness

She had a 10-year history of hypertension and hyperlipidemia, taking candesartan 4 mg per day and atorvastatin 10 mg per day. She denied having taken any other prescribed or over-the-counter medications, alcohol, or illegal drugs.

Physical examination

Her vital signs upon arrival were as follows: Blood pressure 194/106 mmHg, heart rate 93 beats per minute, respiratory rate 12 times per minute, body temperature 37 °C, and oxygen saturation 100% on room air. On examination in the ED, she was awake, alert, and oriented. However, she claimed to be thirsty and kept asking “Am I dying?” with a euphoric smile. Her pupils were slightly dilated, with a diameter of 5 mm on both sides. Other than that, her physical examination was negative.

Laboratory examinations

Her ED laboratory tests showed normal complete blood count and chemistry panel with sodium 142.5 mmol/L; potassium 3.78 mmol/L; magnesium 0.9 mmol/L; and normal liver, renal, and coagulative functions as well as myocardial injury markers. Her electrocardiogram (ECG) revealed sinus rhythm with a normal QT interval.

Further progress, diagnosis, treatment, and outcome

The initial management included immediate fluid resuscitation and oral gastric lavage given the assumed diagnosis of MP, and an intravenous infusion of urapidil was started for blood pressure control. Her blood pressure was 157/96 mmHg after 5 h. A blood sample was sent to the laboratory for further poison screening. However, food residue could be easily seen in her vomitus, and she began to refuse treatment and entered a stage of confusion and then intensive agitation. Therefore, a nasogastric tube was placed for the prevention of aspiration.

Later, her heart rate gradually increased to approximately 120 beats per minute, and intermittent atrial arrhythmia began, which persisted for several minutes with every episode recovering spontaneously. It was quite unexpected that a seizure suddenly developed without arrhythmia onset. It lasted for approximately 1 min, and after termination of the seizure, she immediately had pulseless ventricular tachycardia and cardiac arrest. Fortunately, she had a return of spontaneous circulation after 2 min of CPR and 1 mg epinephrine administration. She was intubated because of vomiting, prior seizure, the need for sedation, and the probability of recurrent cardiac arrest based on her unstable status. No secretions were found during intubation, and her brain CT scan showed no intracranial bleeding or ischemia. The post-cardiac arrest ECG revealed a prolonged QT interval (QT interval 360 msec when heart rate was 135 beats per minute and corrected QT interval was 540 ms, [Figure 1](#)). We put her on blood perfusion for 2 days. She was extubated, totally conscious and had no recurrence of seizure. The toxicity screen, thyroid function, and brain MR were all negative. Her creatine kinase (CK) and kinase-MB (CKMB) were elevated mildly (37 U/L and 245 U/L, respectively) and trended to the normal range after fluid resuscitation. The QT interval also returned to normal. Troponin I (TNI) was negative on serial tests during the hospital stay. She underwent uneventful hospital stay and was discharged 7 days after admission.

Identification of the mushrooms

We sent the mushroom she left for translation elongation factor subunit 1 α , ribosomal RNA gene sequence, and internal transcribed spacer sequence analyses. There were four kinds of mushrooms identified, including *Hebeloma* sp., *Psathyrella leucotephra*, *Panaeolus subbalteatus*, and *Conocybe lactea*. The latter two were found to be toxic ([Figure 2A](#) and [B](#), respectively).

DISCUSSION

There are 100000 known species of fungi worldwide. Approximately 100 of the known species of mushrooms are poisonous to humans. The incidence of MP varies a great deal with respect to the global perspective. The mortality rate reported was 10–15%, or even as high as 21.2%. The prognosis of patients varies greatly and is affected by many factors, including the type of mushroom, intake amount, ED visit time, and treatment strategy. According to the incubation period, the stages of MP are separated into early (< 6 h), delayed (6–24 h), and late (> 24 h). There is a great diversity of clinical manifestations, which are generally divided into different subtypes such as gastrointestinal, hepatic, nephrological, neuropsychiatric, hemolytic, and photoallergic, depending on the type of mushroom ingested and the toxin contained.

Panaeolus subbalteatus, also having been named *Panaeolus cinctulus* in the past, is commonly known as “Weed *Panaeolus*”. It is a very widely distributed psilocybin mushroom that causes hallucination^[1]. The dramatic effects are caused by fungi holding neurotoxins, such as muscarine (*Clitocybe* and *Inocybe* spp.) and psilocybin (*Psilocybe* and *Panaeolus* spp.). Psilocybin and related substances are potent hallucinogens producing effects similar to those of lysergic acid diethylamide (LSD). Psilocybin and/or psilocin have also been detected in *Conocybe lactea*, named *Conocybe*

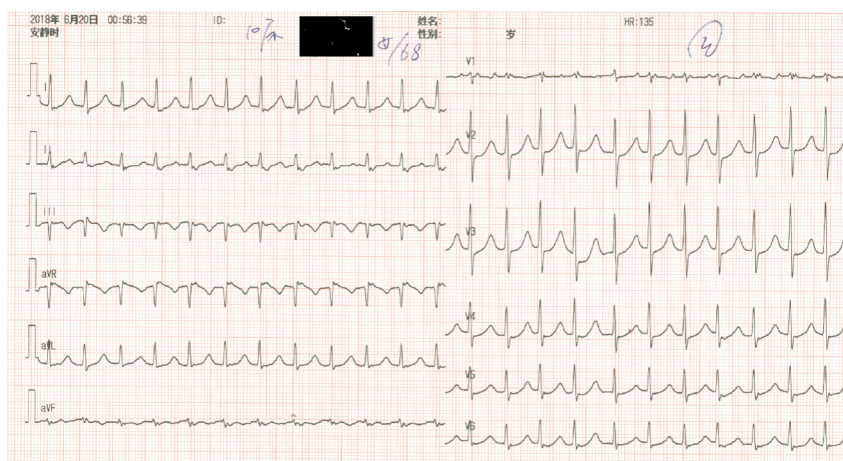


Figure 1 Electrocardiogram of the patient shortly after resuscitation.

apala or the White Duncie Cap, which was the other kind of mushroom involved in this case. They can both be found in areas with rich soil and short grass, such as pastures, playing fields, lawns, road sides, and meadows, as well as rotting manured straw or rotting vegetable remains. These “magic” mushrooms, also called “dancing mushrooms” or “laughing mushrooms” in China, are usually ingested intentionally for their hallucinogenic effects in developed countries or ingested accidentally due to being mistaken for other edible species. Symptoms occur within 20–60 min after ingestion and include a sense of altered time and space, euphoria, depersonalization, hallucinations, anxiety, agitation, mydriasis, vertigo, headache, nausea, enlarged pupils, tachycardia, flushing, fever, and seizures. Symptoms are usually maximal within 2 h and disappear within 4–6 h, although “flashback” may recur after weeks or months^[2]. Our patient had an early onset (< 6 h) of symptoms and was conscious with hearing and sight alterations upon arrival. Then, she underwent a period of euphoria, hallucination, agitation, and seizure, which were all well explained by the toxicity of psilocybin.

As known to all, the consumption of wild mushrooms may cause serious toxicity to hepatic, renal, and neurological functions. *Conocybe lactea* can also be highly toxic to liver cells, containing phallotoxins which are famous as isolated from the death cap mushroom (*Amanita phalloides*)^[3]. However, the toxic effects of MP on the cardiovascular system have been rarely investigated or reviewed systemically, and the conclusions have been controversial.

Elevated CKMB and TNI, ventricular dysfunction, and cardiogenic shock were reported in a few previous studies. All of the probable pathological mechanisms were previously based on speculation from the well-known species, *Amanita phalloides*, which has the toxicity of amatoxins, circulating antitroponin antibodies that impair myocardiocytes. Kalclik published a clinical case of a 25-year-old woman who presented with severe crushing chest pain after consumption of wild mushrooms. The ECG showed ST segment elevation in leads II, III, and aVF. Acute myocardial infarction was confirmed with profoundly elevated CKMB and TNI. Cardioangiography showed normal coronary arteries. It was thought that myocardial infarction was secondary to coronary spasm. A potential mechanism might be vasoconstrictive substances emerging as a result of endothelial damage by the toxins^[4]. Furthermore, Krzysztof once reported that the patients’ serum and urine indole alkaloids, which are agonists of the 5-HT receptors and may lead to coronary vasoconstriction, were strongly positive^[5]. Later, on the other hand, Erenler reviewed 175 patients with MP over a 2-year period, and the cardiac markers of the patients were found to be normal^[6].

Moreover, Erenler concluded that MP causes hypertension and ECG alterations in his article. Sinus tachycardia and sinus arrhythmia were the most common types of arrhythmia found in patients with MP. The prevalence of tachycardia was significantly higher in patients with late-onset symptoms (> 6 h). Furthermore, the blood pressure of the patients tended to increase as the interval between mushroom consumption and onset of symptoms prolonged. Other ECG manifestations included ST/T inversion, first degree AV block, and QT prolongation^[6]. Another case was described in an 18-year-old man who developed Wolff-Parkinson-White syndrome, paroxysmal supraventricular tachycardia, myocardial infarction, and cardiac arrest^[5]. Considering the life-threatening features of MP, Graeme reviewed the symptoms of



Figure 2 Two kinds of toxic mushrooms involved in the case. A: *Panaeolus subbalteatus*; B: *Conocybe lactea*.

palpitation, chest discomfort, dizziness, recurrent syncope, and seizure, followed by sudden death, in patients linked to mushroom ingestions. Ventricular tachycardia and ventricular fibrillation may precede death^[7]. The mechanisms of cardiovascular damage were suggested to be related to peripheral sympathomimetic stimulation by psilocybin, which were contained in both of the toxic species of mushrooms we have identified here^[5]. Unfortunately, almost none of the authors succeeded in the identification of the species of mushroom that causes unusual cardiovascular toxicity.

Our patient experienced several types of arrhythmia, including sinus tachycardia, atrial arrhythmia, ventricular tachycardia, prolonged QT interval, and cardiac arrest. Fortunately, she had a return of spontaneous circulation, and her CKMB was mildly elevated without cardiogenic shock or ventricular failure. She did not have severe liver or renal damage, except for periodic psychotic manifestations. All of her symptoms disappeared after hemoperfusion treatment. This is the first time that we found cardiac toxicity caused by *Panaeolus subbalteatus* and *Conocybe zeylanica*.

CONCLUSION

MP can be critical or fatal, even without the development of severe liver or renal failure. The patient may have sinus, atrial, or ventricular arrhythmias. Intensive monitoring and ECG follow-up are essential to catch prolonged QT interval and all kinds of tachycardia. The mechanisms need to be further investigated and clarified based on animal experiments and molecular signal pathways. Blood perfusion or hemodialysis is usually an effective treatment for severe MP.

ACKNOWLEDGEMENTS

Special thanks to Dr. Fran Riley. We worked on the manuscript together to celebrate our reunion after 27 years on the other side of the planet both working as ED doctors.

REFERENCES

- 1 **Watling R.** A panaeolus poisoning in Scotland. *Mycopathologia* 1977; **61**: 186-190 [PMID: 562983]
- 2 **Persson H.** Mushrooms. Poisoning (Part 1 of 2). *Medicine* 2016; **44**: 116-119 [DOI: 10.1016/j.mpmed.2015.11.011]
- 3 **Amandeep K,** Atri NS and Munruchi K. Diversity of species of the genus Conocybe(Bolbitiaceae, Agaricales) collected on dung from Punjab, India. *Mycosphere* 2015; **6**: 19-42 [DOI: 10.5943/mycosphere/6/1/4]
- 4 **Kalcik M,** Gursay MO, Yesin M, Ocal L, Eren H, Karakoyun S, Astarcioğlu MA, Özkan M. Coronary vasospasm causing acute myocardial infarction: an unusual result of wild mushroom poisoning. *Herz* 2015; **40**: 340-344 [PMID: 24728705 DOI: 10.1007/s00059-014-4071-8]
- 5 **Borowiak KS,** Ciechanowski K, Waloszczyk P. Psilocybin mushroom (*Psilocybe semilanceata*) intoxication with myocardial infarction. *J Toxicol Clin Toxicol* 1998; **36**: 47-49 [PMID: 9541042 DOI: 10.3109/15563659809162584]

- 6 **Erenler AK**, Doğan T, Koçak C, Ece Y. Investigation of Toxic Effects of Mushroom Poisoning on the Cardiovascular System. *Basic Clin Pharmacol Toxicol* 2016; **119**: 317-321 [PMID: [26879235](#) DOI: [10.1111/bcpt.12569](#)]
- 7 **Graeme KA**. Mycetism: a review of the recent literature. *J Med Toxicol* 2014; **10**: 173-189 [PMID: [24573533](#) DOI: [10.1007/s13181-013-0355-2](#)]



Published By Baishideng Publishing Group Inc
7041 Koll Center Parkway, Suite 160, Pleasanton, CA 94566, USA
Telephone: +1-925-2238242
Fax: +1-925-2238243
E-mail: bpgoffice@wjgnet.com
Help Desk: <https://www.f6publishing.com/helpdesk>
<https://www.wjgnet.com>

