

World Journal of *Clinical Cases*

World J Clin Cases 2020 April 6; 8(7): 1188-1342



**REVIEW**

- 1188** Sarcopenia in patients with colorectal cancer: A comprehensive review
Vergara-Fernandez O, Trejo-Avila M, Salgado-Nesme N

MINIREVIEWS

- 1203** Thoracic hydatid disease: A radiologic review of unusual cases
Saeedan MB, Aljohani IM, Alghofaily KA, Loutfi S, Ghosh S

ORIGINAL ARTICLE**Case Control Study**

- 1213** Clinical significance and prognostic value of tumor necrosis factor- α and dickkopf related protein-1 in ankylosing spondylitis
Xiong JH, Liu J, Chen J

Retrospective Study

- 1223** Reconstruction of Paprosky type IIIB acetabular bone defects using a cup-on-cup technique: A surgical technique and case series
Du YQ, Liu YP, Sun JY, Ni M, Zhou YG

Prospective Study

- 1232** Depression and myocardial injury in ST-segment elevation myocardial infarction: A cardiac magnetic resonance imaging study
Sun ZQ, Yu TT, Ma Y, Ma QM, Jiao YD, He DX, Jia-KeWu, Wen ZY, Wang XN, Hou Y, Sun ZJ

CASE REPORT

- 1241** Long-term survival of two patients with recurrent pancreatic acinar cell carcinoma treated with radiofrequency ablation: A case report
Di Marco M, Carloni R, De Lorenzo S, Grassi E, Palloni A, Formica F, Brocchi S, Filippini DM, Golfieri R, Brandi G
- 1251** Acute myeloid leukemia with t(11;19)(q23;p13.1) in a patient with a gastrointestinal stromal tumor undergoing imatinib therapy: A case report
Kim HJ, Baek SK, Maeng CH, Kim SY, Park TS, Han JJ
- 1257** CD56+ lymphoepithelioma-like carcinoma of the lung: A case report and literature review
Yang L, Liang H, Liu L, Guo L, Ying JM, Shi SS, Hu XS
- 1265** Atypical presentation of SARS-CoV-2 infection: A case report
Li RL, Chu SG, Luo Y, Huang ZH, Hao Y, Fan CH

- 1271** Spinal intraosseous schwannoma without spinal canal and neuroforamina involvement: A case report
Xu ZQ, Zhang P, Zhong ZH, Zhou W, Yu HT
- 1278** Chidamide based combination regimen for treatment of monomorphic epitheliotropic intestinal T cell lymphoma following radical operation: Two case reports
Liu TZ, Zheng YJ, Zhang ZW, Li SS, Chen JT, Peng AH, Huang RW
- 1287** Scaphoid metastasis as the first sign of occult gastroesophageal junction cancer: A case report
Zhang YJ, Wang YY, Yang Q, Li JB
- 1295** Pleural effusion in an immunocompetent host with cryptococcal pneumonia: A case report
Wu HH, Chen YX, Fang SY
- 1301** Rigid ureteroscopy in prone split-leg position for fragmentation of female ureteral stones: A case report
Huang K
- 1306** Multiple neurofibromas plus fibrosarcoma with familial NF1 pathogenicity: A case report
Wang Y, Lu XF, Chen LL, Zhang YW, Zhang B
- 1311** Severe venous thromboembolism in the puerperal period caused by thrombosis: A case report
Zhang J, Sun JL
- 1319** Disseminated histoplasmosis in primary Sjögren syndrome: A case report
Li JA, Cheng YY, Cui ZT, Jiang W, Zhang WQ, Du ZH, Gao B, Xie YY, Meng HM
- 1326** Clinical effects of apatinib mesylate for treatment of multiple brain micrometastases: Two case reports
Guo JH, Wang YY, Zhang JW, Liu PM, Hao YJ, Duan HR
- 1337** Systemic treatment for severe concentrated sulfuric acid burns in an adult male at high altitude: A case report
Zhao RM, Li Y, Chao SW, Wang HJ

ABOUT COVER

Editorial Board Member of *World Journal of Clinical Cases*, Amit Arvind Agrawal, MPhil, Professor, Department of Periodont, KBH Mahatma Gandhi Vidyamandir's Dental College and Hospital, Nasik 422003, India

AIMS AND SCOPE

The primary aim of *World Journal of Clinical Cases* (WJCC, *World J Clin Cases*) is to provide scholars and readers from various fields of clinical medicine with a platform to publish high-quality clinical research articles and communicate their research findings online.

WJCC mainly publishes articles reporting research results and findings obtained in the field of clinical medicine and covering a wide range of topics, including case control studies, retrospective cohort studies, retrospective studies, clinical trials studies, observational studies, prospective studies, randomized controlled trials, randomized clinical trials, systematic reviews, meta-analysis, and case reports.

INDEXING/ABSTRACTING

The WJCC is now indexed in PubMed, PubMed Central, Science Citation Index Expanded (also known as SciSearch®), and Journal Citation Reports/Science Edition. The 2019 Edition of Journal Citation Reports cites the 2018 impact factor for WJCC as 1.153 (5-year impact factor: N/A), ranking WJCC as 99 among 160 journals in Medicine, General and Internal (quartile in category Q3).

RESPONSIBLE EDITORS FOR THIS ISSUE

Responsible Electronic Editor: *Yan-Xia Xing*

Proofing Production Department Director: *Yun-Xiaojuan Wu*

NAME OF JOURNAL

World Journal of Clinical Cases

ISSN

ISSN 2307-8960 (online)

LAUNCH DATE

April 16, 2013

FREQUENCY

Semimonthly

EDITORS-IN-CHIEF

Dennis A Bloomfield, Bao-Gan Peng, Sandro Vento

EDITORIAL BOARD MEMBERS

<https://www.wjnet.com/2307-8960/editorialboard.htm>

EDITORIAL OFFICE

Jin-Lei Wang, Director

PUBLICATION DATE

April 6, 2020

COPYRIGHT

© 2020 Baishideng Publishing Group Inc

INSTRUCTIONS TO AUTHORS

<https://www.wjnet.com/bpg/gerinfo/204>

GUIDELINES FOR ETHICS DOCUMENTS

<https://www.wjnet.com/bpg/GerInfo/287>

GUIDELINES FOR NON-NATIVE SPEAKERS OF ENGLISH

<https://www.wjnet.com/bpg/gerinfo/240>

PUBLICATION MISCONDUCT

<https://www.wjnet.com/bpg/gerinfo/208>

ARTICLE PROCESSING CHARGE

<https://www.wjnet.com/bpg/gerinfo/242>

STEPS FOR SUBMITTING MANUSCRIPTS

<https://www.wjnet.com/bpg/GerInfo/239>

ONLINE SUBMISSION

<https://www.f6publishing.com>



Rigid ureteroscopy in prone split-leg position for fragmentation of female ureteral stones: A case report

Kai Huang

ORCID number: Kai Huang
(0000-0002-3968-0512).

Author contributions: Huang K wrote this case report.

Informed consent statement:
Consent was obtained from the patient.

Conflict-of-interest statement: We have no conflicts of interests to declare.

CARE Checklist (2016) statement:
The authors revised the manuscript according to the requirements of CARE Checklist.

Open-Access: This article is an open-access article that was selected by an in-house editor and fully peer-reviewed by external reviewers. It is distributed in accordance with the Creative Commons Attribution NonCommercial (CC BY-NC 4.0) license, which permits others to distribute, remix, adapt, build upon this work non-commercially, and license their derivative works on different terms, provided the original work is properly cited and the use is non-commercial. See: <http://creativecommons.org/licenses/by-nc/4.0/>

Manuscript source: Unsolicited manuscript

Received: October 24, 2019

Peer-review started: October 24, 2019

First decision: January 17, 2020

Revised: January 18, 2020

Accepted: March 5, 2020

Article in press: March 5, 2020

Kai Huang, Department of Urology, Clinical Medicine College, Yangzhou University, Northern Jiangsu People's Hospital, Yangzhou 225001, Jiangsu Province, China

Corresponding author: Kai Huang, PhD, Doctor, Surgeon, Surgical Oncologist, Department of Urology, Clinical Medicine College, Yangzhou University, Northern Jiangsu People's Hospital, No. 98 West Nantong Road, Yangzhou 225001, Jiangsu Province, China.
huangkai_2015@163.com

Abstract

BACKGROUND

Ureteroscopy is widely used in the treatment of ureteral stones due to the increased morbidity of urolithiasis. This is the first report of a case of ureteral calculi treated with rigid ureteroscopy in the modified prone split-leg position.

CASE SUMMARY

A 62-year-old Asian woman was diagnosed with a ureteral stone and underwent extracorporeal shock wave lithotripsy twice. However, the abdominal computer tomography scan showed persistent calculi on the right lower ureter. Her left hip movement was limited because of a left femoral neck fracture that did not receive proper treatment in a timely manner. She was unable to undergo surgery in the lithotomy position and refused to accept flexible ureteroscopy treatment. Therefore, rigid ureteroscopy was performed with her in the modified prone split-leg position. The ureteral calculi were successfully fragmented.

CONCLUSION

It is feasible to treat lower ureteral calculi in women in the prone split-leg position with the implementation of rigid ureteroscopy.

Key words: Ureteroscopy; Ureteral calculi; Lithotripsy; Prone position; Female; Case report

©The Author(s) 2020. Published by Baishideng Publishing Group Inc. All rights reserved.

Core tip: Ureteroscopy is widely used in the treatment of ureteral stones due to the increased morbidity of urolithiasis. In some special cases, ureteroscopic surgery cannot be performed by conventional positioning. This is the first report about a case of ureteral calculi treated with rigid ureteroscopy in a modified prone split-leg position. Due to the patient's hip disease, she was unable to undergo surgery in the lithotomy position. In this case, we successfully fragmented the ureteral stone. We think it is feasible to treat lower

Published online: April 6, 2020

P-Reviewer: Ekpenyong CEE,
Moralioglu S

S-Editor: Wang JL

L-Editor: Filipodia

E-Editor: Xing YX



ureteral calculi in woman in the prone split-leg position with the implementation of rigid ureteroscopy.

Citation: Huang K. Rigid ureteroscopy in prone split-leg position for fragmentation of female ureteral stones: A case report. *World J Clin Cases* 2020; 8(7): 1301-1305

URL: <https://www.wjnet.com/2307-8960/full/v8/i7/1301.htm>

DOI: <https://dx.doi.org/10.12998/wjcc.v8.i7.1301>

INTRODUCTION

In recent decades, ureteroscopic lithotripsy has become the main therapy to treat urolithiasis^[1], with reduced expenditure and higher efficiency. Most ureteroscopy is performed effectively and safely in the supine position. Here, we present a case of successful lithotripsy of a woman's distal ureteral stone by using rigid retrograde ureteroscopy in a modified prone split-leg position.

CASE PRESENTATION

Chief complaints

A 62-year-old woman was diagnosed with ureteral calculi through X-ray and ultrasound examination. While she underwent shock wave lithotripsy treatment twice and received lithagogue drugs, these therapies appeared to be ineffective.

History of present illness

She had a fracture of the left femoral neck at 50 years of age and did not receive proper treatment in a timely manner due to poverty.

Imaging examinations

A non-enhanced computed tomography scan of the abdomen revealed a 12 mm × 10 mm stone in the lower right ureter (Figure 1). Due to movement restriction in her left hip, surgery in the lithotomy position could not be performed. She also refused the choice of flexible ureteroscopy because of the greater economic burden. We finally decided to perform a rigid retrograde ureteroscopic lithotripsy in the prone split-leg position.

FINAL DIAGNOSIS

Ureteral calculi.

TREATMENT

The patient was oriented in the modified prone split-leg position during the operation after general anesthesia (Figure 2). A Fr 8/9.8 rigid ureteroscope was used to enter the upper ureteral tract alongside the guide wire (Figure 3). When the ureter stone was visualized at the lower ureteral position, a 20W Holmium YAG laser was used to fragment and dust the calculi. Subsequently, residual calculi exceeding 2 mm were removed using a nitinol stone basket. A F4.8 double J stent was then placed in the right ureter through a guide wire after evaluating the urinary tract for complications. An abdominal radiograph review showed perfect positioning of the double J ureteral stent with no visible calculi in the ureteral area (Figure 4).

OUTCOME AND FOLLOW-UP

At 2 d after ureteroscopic lithotripsy, the patient was discharged from our hospital and returned to our department 1 mo later for successful ureteral stent removal.

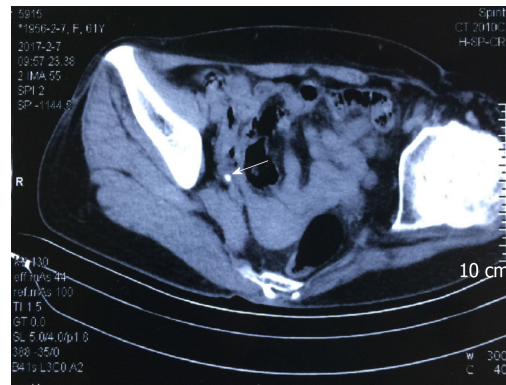


Figure 1 Computed tomography scan showing a calculi in the right ureter. Arrowhead indicates the location of ureteral calculi.

DISCUSSION

The incidence and prevalence of urolithiasis, including ureteric calculi, is increasing based on international epidemiological data^[2]. Compared with global incidences, China has a very high incidence of urinary stones^[3], which has added a considerable burden to people's health and the country's economy. Although the vital characteristics of dietary patterns and high water intake should be considered prior to any treatments, ureteroscopy performed for ureteric calculi disease has increased due to the direct effects of the rising number of urolithiasis disease cases on health resources. Since ureteroscopy was first introduced in the 1970s^[4], ureteroscopes have undergone rapid development in the past century, accompanied by various improvements in their use. The working pipeline of ureteroscopy allows the insertion of laser fibers and a basket and increases the efficiency of ureteroscopy lithotripsy. Holmium laser lithotripsy has been the preferred choice to treat ureteric calculi, especially the lower ureteric stone. Although rigid ureteroscopy is the main method applied worldwide, the emergence of a flexible ureteroscope is an important development that has changed the traditional concept of endourology^[5]. The flexible scope can reach the upper ureter, pelvis, and renal calices and dust urinary stones *via* direct vision through the ureteral canal. However, this method is not widespread in China because of its high cost, which is also why the patient in this report ultimately opted for rigid ureteroscopy and not the initially suggested flexible ureteroscopy lithotripsy, even despite her restricted left hip movement.

All of the technological advancements have extended the application of ureteroscopy. A simultaneous approach with flexible ureteroscopy and percutaneous nephrolithotomy performed in the Galdakao-modified supine Valdivia position has been reported^[6]. This position has the advantage of providing a better option for complex urolithiasis in the entire upper urinary tract. It does not require the patient to change position during the operation. Hamamoto *et al*^[7] reported that a synchronized approach with flexible ureteroscopy and minimally invasive percutaneous nephrolithotomy (mPNL) (in the prone split-leg position) achieved a 81.7% stone-free rate that was higher than mPNL (38.9%) and standard PNL (45.1%). Another report described how to manage an encrusted stent by combined endoscopic methods in the prone split-leg position^[8]. However, there have been no reports about rigid ureteroscopy for ureteric calculi in the prone position. In the present case, the patient's left hip movements were limited, which precluded normal ureteroscopy in the supine position. In addition, because of the economic burden, she was not willing to accept treatment by flexible ureteroscopy. Finally, after observing the angle of her hip joint activities, we performed the surgery in a modified prone split-leg position and successfully removed her lower ureteral calculi (Figure 3).

CONCLUSION

To the best of our knowledge, this is the first reported case of treating ureteral stones by rigid ureteroscopy in the prone split-leg position. Due to the different anatomical characteristics of the female urethra, we believe that rigid ureteroscopy can be used to treat ureteral calculi in certain situations. This includes situations like the present case where a patient cannot be operated on in the lithotomy position, which is especially applicable to the removal of lower ureteral stones in women.

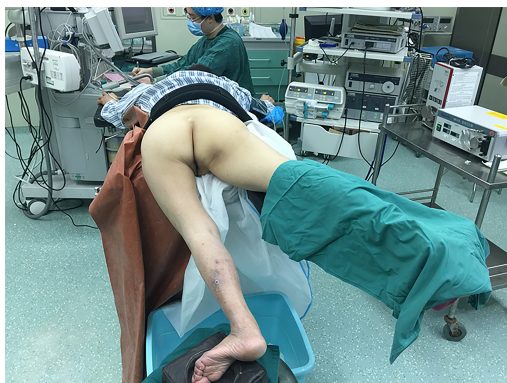

Figure 2 Patient positioning in the modified prone split-leg position due to limited movement of her left hip.

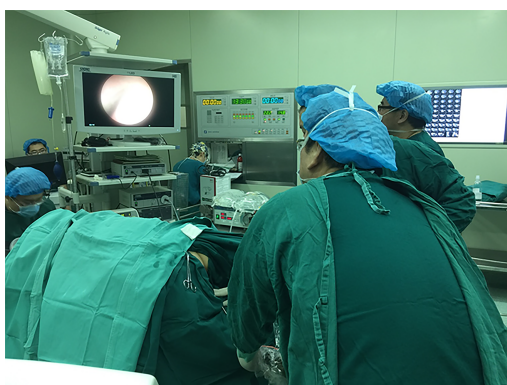


Figure 3 Ureteroscope enters the right ureter alongside the guide wire.

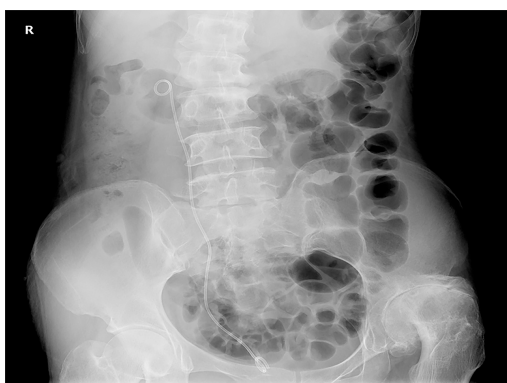

Figure 4 X-ray of kidney, ureter, and bladder shows stent position and no visible stone in ureteral area after operation.

REFERENCES

- 1 **Raheem OA**, Khandwala YS, Sur RL, Ghani KR, Denstedt JD. Burden of Urolithiasis: Trends in Prevalence, Treatments, and Costs. *Eur Urol Focus* 2017; **3**: 18-26 [PMID: [28720363](#) DOI: [10.1016/j.euf.2017.04.001](#)]
- 2 **Heers H**, Turney BW. Trends in urological stone disease: a 5-year update of hospital episode statistics. *BJU Int* 2016; **118**: 785-789 [PMID: [27128735](#) DOI: [10.1111/bju.13520](#)]
- 3 **Kasote DM**, Jagtap SD, Thapa D, Khyade MS, Russell WR. Herbal remedies for urinary stones used in India and China: A review. *J Ethnopharmacol* 2017; **203**: 55-68 [PMID: [28344029](#) DOI: [10.1016/j.jep.2017.03.038](#)]
- 4 **Pérez-Castro Ellendt E**, Martínez-Piñero JA. [Transurethral ureteroscopy. A current urological procedure]. *Arch Esp Urol* 1980; **33**: 445-460 [PMID: [7447504](#)]
- 5 **Grasso M**. Ureteropyeloscopic treatment of ureteral and intrarenal calculi. *Urol Clin North Am* 2000; **27**: 623-631 [PMID: [11098761](#)]
- 6 **Dael F**, González MS, Freire FG, Jurado A, Damia O. Percutaneous lithotripsy in Valdivia-Galdakao decubitus position: our experience. *J Endourol* 2009; **23**: 1615-1620 [PMID: [19747031](#) DOI: [10.1016/j.jep.2017.03.038](#)]

- [10.1089/end.2009.1526](https://doi.org/10.1089/end.2009.1526)]
- 7 **Hamamoto S**, Yasui T, Okada A, Taguchi K, Kawai N, Ando R, Mizuno K, Kubota Y, Kamiya H, Tozawa K, Kohri K. Endoscopic combined intrarenal surgery for large calculi: simultaneous use of flexible ureteroscopy and mini-percutaneous nephrolithotomy overcomes the disadvantageous of percutaneous nephrolithotomy monotherapy. *J Endourol* 2014; **28**: 28-33 [PMID: [23987470](https://pubmed.ncbi.nlm.nih.gov/23987470/) DOI: [10.1089/end.2013.0361](https://doi.org/10.1089/end.2013.0361)]
 - 8 **Marchini GS**, Torricelli FC, Mazzucchi E, Srougi M, Monga M. Prone split-leg position to manage encrusted ureteral stents in a single-stage procedure in women: Step-by-step surgical technique. *Can Urol Assoc J* 2015; **9**: E494-E499 [PMID: [26279723](https://pubmed.ncbi.nlm.nih.gov/26279723/) DOI: [10.5489/cuaj.2852](https://doi.org/10.5489/cuaj.2852)]



Published By Baishideng Publishing Group Inc
7041 Koll Center Parkway, Suite 160, Pleasanton, CA 94566, USA
Telephone: +1-925-3991568
E-mail: bpgoffice@wjgnet.com
Help Desk: <https://www.f6publishing.com/helpdesk>
<https://www.wjgnet.com>

