

# World Journal of *Gastroenterology*

*World J Gastroenterol* 2019 August 14; 25(30): 4043-4293



**EDITORIAL**

- 4043** Exhaled breath analysis in hepatology: State-of-the-art and perspectives  
*De Vincentis A, Vespasiani-Gentilucci U, Sabatini A, Antonelli-Incalzi R, Picardi A*

**OPINION REVIEW**

- 4051** Miniature gastrointestinal endoscopy: Now and the future  
*McGoran JJ, McAlindon ME, Iyer PG, Seibel EJ, Haidry R, Lovat LB, Sami SS*
- 4061** Issues and controversies in esophageal inlet patch  
*Ciocalteu A, Popa P, Ionescu M, Gheonea DI*

**REVIEW**

- 4074** Role of hepatocyte nuclear factor 4-alpha in gastrointestinal and liver diseases  
*Yeh MM, Bosch DE, Daoud SS*
- 4092** G protein-coupled estrogen receptor in colon function, immune regulation and carcinogenesis  
*Jacenic D, Beswick EJ, Krajewska WM, Prossnitz ER*
- 4105** *Helicobacter pylori* and cytokine gene variants as predictors of premalignant gastric lesions  
*Negovan A, Iancu M, Fülöp E, Bănescu C*
- 4125** Intestinal enteroids/organoids: A novel platform for drug discovery in inflammatory bowel diseases  
*Yoo JH, Donowitz M*

**MINIREVIEWS**

- 4148** Colorectal cancer surveillance in inflammatory bowel disease: Practice guidelines and recent developments  
*Clarke WT, Feuerstein JD*
- 4158** Elderly patients with inflammatory bowel disease: Updated review of the therapeutic landscape  
*LeBlanc JF, Wiseman D, Lakatos PL, Bessissow T*
- 4172** Reduced lysosomal acid lipase activity: A new marker of liver disease severity across the clinical continuum of non-alcoholic fatty liver disease?  
*Baratta F, Pastori D, Ferro D, Carluccio G, Tozzi G, Angelico F, Violi F, Del Ben M*
- 4181** Beneficial effects of nutritional supplements on intestinal epithelial barrier functions in experimental colitis models *in vivo*  
*Vargas-Robles H, Castro-Ochoa KF, Citalán-Madrid AF, Schnoor M*

- 4199 Multiple “Omics” data-based biomarker screening for hepatocellular carcinoma diagnosis

*Liu XN, Cui DN, Li YF, Liu YH, Liu G, Liu L*

## ORIGINAL ARTICLE

### Basic Study

- 4213 Novel magnetic compression technique for establishment of a canine model of tracheoesophageal fistula

*Gao Y, Wu RQ, Lv Y, Yan XP*

- 4222 Bone morphogenetic protein-7 represses hepatic stellate cell activation and liver fibrosis *via* regulation of TGF- $\beta$ /Smad signaling pathway

*Zou GL, Zuo S, Lu S, Hu RH, Lu YY, Yang J, Deng KS, Wu YT, Mu M, Zhu JJ, Zeng JZ, Zhang BF, Wu X, Zhao XK, Li HY*

### Retrospective Study

- 4235 Natural history of children with mild Crohn’s disease

*Sharma Y, Bousvaros A, Liu E, Stern JB*

### Observational Study

- 4246 Inflammatory bowel disease patient profiles are related to specific information needs: A nationwide survey

*Daher S, Khoury T, Benson A, Walker JR, Hammerman O, Kedem R, Naftali T, Eliakim R, Ben-Bassat O, Bernstein CN, Israeli E*

## SYSTEMATIC REVIEWS

- 4261 Frequency, localization, and types of gastrointestinal stromal tumor-associated neoplasia

*Waidhauser J, Bornemann A, Trepel M, Märkl B*

## META-ANALYSIS

- 4278 Quantitative risk of positive family history in developing colorectal cancer: A meta-analysis

*Mehraban Far P, Alshahrani A, Yaghoobi M*

## LETTER TO THE EDITOR

- 4292 Letter to the editor: Diagnosis of erythropoietic protoporphyria with severe liver injury - a case report

*Wensink D, Wagenmakers MA, Wilson JP, Langendonk JG*

**ABOUT COVER**

Editorial board member of *World Journal of Gastroenterology*, Yasemin H Balaban, MD, Doctor, Professor, Department of Gastroenterology, Hacettepe University, Ankara 06100, Turkey

**AIMS AND SCOPE**

*World Journal of Gastroenterology* (*World J Gastroenterol*, *WJG*, print ISSN 1007-9327, online ISSN 2219-2840, DOI: 10.3748) is a peer-reviewed open access journal. The *WJG* Editorial Board consists of 701 experts in gastroenterology and hepatology from 58 countries.

The primary task of *WJG* is to rapidly publish high-quality original articles, reviews, and commentaries in the fields of gastroenterology, hepatology, gastrointestinal endoscopy, gastrointestinal surgery, hepatobiliary surgery, gastrointestinal oncology, gastrointestinal radiation oncology, etc. The *WJG* is dedicated to become an influential and prestigious journal in gastroenterology and hepatology, to promote the development of above disciplines, and to improve the diagnostic and therapeutic skill and expertise of clinicians.

**INDEXING/ABSTRACTING**

The *WJG* is now indexed in Current Contents®/Clinical Medicine, Science Citation Index Expanded (also known as SciSearch®), Journal Citation Reports®, Index Medicus, MEDLINE, PubMed, PubMed Central, and Scopus. The 2019 edition of Journal Citation Report® cites the 2018 impact factor for *WJG* as 3.411 (5-year impact factor: 3.579), ranking *WJG* as 35<sup>th</sup> among 84 journals in gastroenterology and hepatology (quartile in category Q2). CiteScore (2018): 3.43.

**RESPONSIBLE EDITORS FOR THIS ISSUE**

Responsible Electronic Editor: Yan-Liang Zhang

Proofing Production Department Director: Yun-Xiaojian Wu

**NAME OF JOURNAL**

*World Journal of Gastroenterology*

**ISSN**

ISSN 1007-9327 (print) ISSN 2219-2840 (online)

**LAUNCH DATE**

October 1, 1995

**FREQUENCY**

Weekly

**EDITORS-IN-CHIEF**

Subrata Ghosh, Andrzej S Tarnawski

**EDITORIAL BOARD MEMBERS**

<http://www.wjgnet.com/1007-9327/editorialboard.htm>

**EDITORIAL OFFICE**

Ze-Mao Gong, Director

**PUBLICATION DATE**

August 14, 2019

**COPYRIGHT**

© 2019 Baishideng Publishing Group Inc

**INSTRUCTIONS TO AUTHORS**

<https://www.wjgnet.com/bpg/gerinfo/204>

**GUIDELINES FOR ETHICS DOCUMENTS**

<https://www.wjgnet.com/bpg/GerInfo/287>

**GUIDELINES FOR NON-NATIVE SPEAKERS OF ENGLISH**

<https://www.wjgnet.com/bpg/gerinfo/240>

**PUBLICATION MISCONDUCT**

<https://www.wjgnet.com/bpg/gerinfo/208>

**ARTICLE PROCESSING CHARGE**

<https://www.wjgnet.com/bpg/gerinfo/242>

**STEPS FOR SUBMITTING MANUSCRIPTS**

<https://www.wjgnet.com/bpg/GerInfo/239>

**ONLINE SUBMISSION**

<https://www.f6publishing.com>



## Frequency, localization, and types of gastrointestinal stromal tumor-associated neoplasia

Johanna Waidhauser, Anne Bornemann, Martin Trepel, Bruno Märkl

**ORCID number:** Johanna Waidhauser (0000-0003-2776-1590); Anne Bornemann (0000-0002-1798-1971); Martin Trepel (0000-0002-3358-6568); Bruno Märkl (0000-0002-7704-850X).

**Author contributions:** Waidhauser J performed literature research, collected and analyzed the data, performed statistical analysis and drafted the manuscript. Bornemann A performed literature research. Trepel M provided analytical oversight and revised the manuscript. Märkl B designed the review, was involved in literature research and statistical analysis and revised the manuscript.

**Conflict-of-interest statement:** All authors declare that no conflicting interests (including but not limited to commercial, personal, political, intellectual or religious interests) exist.

**Data sharing statement:** Statistical code, and dataset available from the corresponding author at Dryad repository, who will provide a permanent, citable and open-access home for the dataset.

**PRISMA 2009 Checklist statement:** The guidelines of the Prisma 2009 Statement have been adopted.

**Open-Access:** This is an open-access article that was selected by an in-house editor and fully peer-reviewed by external reviewers. It is distributed in accordance with the Creative Commons Attribution Non Commercial (CC BY-NC 4.0) license, which permits others to distribute, remix, adapt, build

**Johanna Waidhauser, Anne Bornemann, Bruno Märkl,** Institute of Pathology and Molecular Diagnostics, University Medical Center Augsburg, Augsburg 86156, Germany

**Johanna Waidhauser, Martin Trepel,** Department of Hematology and Clinical Oncology, University Medical Center Augsburg, Augsburg 86156, Germany

**Corresponding author:** Bruno Märkl, MD, Professor, Institute of Pathology and Molecular Diagnostics, University Medical Center Augsburg, Stenglinstrasse 2, Augsburg 86156, Germany. [bruno.maerkl@outlook.de](mailto:bruno.maerkl@outlook.de)

**Telephone:** +49-821-4002150

**Fax:** +49-821-400173199

### Abstract

#### BACKGROUND

In recent years, increasing evidence of second neoplasms associated with gastrointestinal stromal tumors (GIST) has been found. Numerous case reports, mostly retrospective studies and a few reviews, have been published. To our knowledge, however, no systematic review or meta-analysis of the existing data has been performed so far.

#### AIM

To prepare a compilation, as complete as possible, of all reported second tumor entities that have been described in association with GIST and to systematically analyze the published studies with regard to frequency, localization, and types of GIST-associated neoplasms.

#### METHODS

The MEDLINE and EBSCO databases were searched for a combination of the keywords GIST/secondary, synchronous, coincident/tumor, neoplasm, and relevant publications were selected by two independent authors.

#### RESULTS

Initially, 3042 publications were found. After deletion of duplicates, 1631 remained, and 130 papers were selected; 22 of these were original studies with a minimum of 20 patients, and 108 were case reports. In the 22 selected studies, comprising a total number of 12050 patients, an overall rate of GIST-associated neoplasias of 20% could be calculated. Most second neoplasias were found in the gastrointestinal tract (32%) and in the male and female urogenital tract (30%). The specific risk scores of GISTs associated with other tumors were significantly lower than those without associated neoplasias.



upon this work non-commercially, and license their derivative works on different terms, provided the original work is properly cited and the use is non-commercial. See: <http://creativecommons.org/licenses/by-nc/4.0/>

**Manuscript source:** Invited manuscript

**Received:** April 19, 2019

**Peer-review started:** April 19, 2019

**First decision:** June 16, 2019

**Revised:** June 22, 2019

**Accepted:** July 5, 2019

**Article in press:** July 5, 2019

**Published online:** August 14, 2019

**P-Reviewer:** Laghi A, Wilkinson MJ

**S-Editor:** Ma RY

**L-Editor:** A

**E-Editor:** Zhang YL



## CONCLUSION

In this first systematic review, we could confirm previously reported findings of a more than coincidental association between GIST and other neoplasias. The question whether there is an underlying causal association will need further investigation. Our data suggest that even GIST with a very low risk of disease progression should prompt screening for second neoplasia and subsequent frequent controls or extended staging.

**Key words:** Gastrointestinal stromal tumor; Associated; Secondary; Neoplasia; Tumor

©The Author(s) 2019. Published by Baishideng Publishing Group Inc. All rights reserved.

**Core tip:** Gastrointestinal stromal tumors (GIST) associated neoplasms have been previously reported to occur with a more than coincidental frequency. Numerous case reports, mostly retrospective studies and a few reviews have been published on this topic. In this, to our knowledge, first systematic review we analyzed 108 case reports and 22 retrospective and prospective studies with a total of 12050 patients. An overall rate of GIST-associated neoplasias of 20% could be calculated. Most second neoplasias were found in the gastrointestinal tract (32%) and in the male and female urogenital tract (30%).

**Citation:** Waidhauser J, Bornemann A, Trepel M, Märkl B. Frequency, localization, and types of gastrointestinal stromal tumor-associated neoplasia. *World J Gastroenterol* 2019; 25(30): 4261-4277

**URL:** <https://www.wjgnet.com/1007-9327/full/v25/i30/4261.htm>

**DOI:** <https://dx.doi.org/10.3748/wjg.v25.i30.4261>

## INTRODUCTION

Gastrointestinal stromal tumors (GIST) are the most common mesenchymal tumors of the digestive tract. Yearly incidence rates vary from 4.3 to 22 per million in different geographic regions, which may at least in part be caused by changing and improving diagnostic criteria and a lack of established GIST registries. In most studies, however, the yearly incidence is indicated as 10 to 15 per million<sup>[1]</sup>, fulfilling the criterion of a rare disease. Median age at diagnosis is reported to be between 60 and 69 years in most studies<sup>[1,2]</sup>. GIST are considered to develop from interstitial cells of Cajal (ICC), which play an important role in autonomous gastrointestinal movement<sup>[3]</sup>. The most common localization of GIST is the stomach, followed by other gastrointestinal tract localizations<sup>[2,4]</sup>.

Several driver mutations have been identified as playing an essential role in the development of GIST. The most frequent mutation can be found in the tyrosine kinase receptor c-kit (c-KIT), which accounts for 70%-80% of GIST<sup>[5-7]</sup> and is nowadays the most important target of medical tumor therapy in GIST patients. Other relevant mutations can be observed in the platelet-derived growth factor receptor alpha (PDGFR-α) in 5%-10%<sup>[5-7]</sup> and, in rare cases, in other genes such as neurofibromin 1 (NF1), succinate dehydrogenase (SDH), or BRAF<sup>[6,8]</sup>.

GIST can occur in the setting of genetic syndromes such as neurofibromatosis 1<sup>[9]</sup>, Carney triad<sup>[10]</sup>, or familial GIST<sup>[11]</sup> and, in these cases, frequently come along with other benign or malignant neoplasias. In recent years, though, there has been increasing evidence of second neoplasia in patients with sporadic GIST<sup>[12-15]</sup>. Several retrospective studies and case series have been published on this topic, complemented by many case reports and a few reviews, but so far to our knowledge, no meta-analysis or systematic reviews have been conducted. The aim of this first systematic review is to prepare a compilation, as complete as possible, of all reported second tumor entities that have been described in association with GIST and to systematically analyze the published studies with regard to frequency, localization, and types of GIST-associated neoplasms.

## MATERIALS AND METHODS

### Literature research

We performed a literature search in the MEDLINE and EBSCO databases, using the keywords GIST/secondary, synchronous, coincident/tumor, neoplasm. All results were transferred to the citation manager Endnote® and duplicates were deleted. The remaining results were screened by two authors with regard to suitable topic, language, and publication standard. Discrepancies were resolved after discussion with a senior third author. Case reports and case series/studies in English or German were included. Only data that was fully published was eligible. Syndromic settings as familial GIST or neurofibromatosis were excluded as well as cases involving children. Studies had to include at least 20 patients, and studies that investigated only one specific kind of second neoplasm were excluded. Second neoplasms were considered regardless of the time frame between their occurrence and the occurrence of GIST. Malignant as well as benign second neoplasms were selected. In addition, the bibliographies of all selected papers that were published between 2016 and 2019 were screened for suitable references, as were the six published reviews on this topic.

### Statistical analysis

For statistical calculations, we used SigmaPlot 13.0 (Systat, Erkrath, Germany) and Microsoft Excel (Microsoft Office 16). The chi-squared test was performed for testing the relationship between two categorical variables. A *P*-value of < 0.05 was considered significant.

### PROSPERO registration

Before starting the literature research, a registration of this systematic review in the international Prospective Register of Systematic Reviews (PROSPERO, registration number CRD42019122784) was performed.

## RESULTS

The literature search revealed a total of 3042 publications before February 2019. After deletion of duplicates, 1631 papers remained. Screening by the two authors (Waidhauser J and Bornemann A) resulted in 126 eligible papers. In addition, one study on 188 GIST patients that was performed at our institute by Mayr *et al.*<sup>[15]</sup> and had not been published by the time of the literature search was included. Of the 130 selected publications, 108 were case reports and 22 were case series or retrospective and prospective studies (Figure 1).

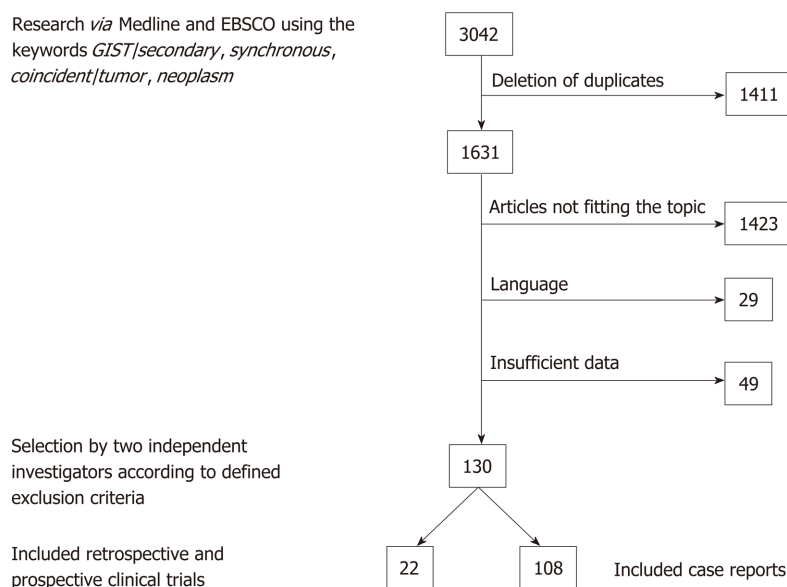
All additional neoplasms that were reported in the case reports are listed in Table 1. The most frequent types were gastric and colorectal adenocarcinomas.

Among the 22 retrospective and prospective studies, a total of 12050 patients were included. Basic information on these studies is summarized in Table 2. The number of patients in which an additional tumor to the GIST diagnosis was found was 2426 (20.1%). The median age at the diagnosis of GIST was 63 years in the total study population and 68 years in those patients with an additional tumor. The male-to-female ratio was 1.1:1 in the total population and 1.4:1 in the GIST with secondary neoplasia group. The chi-squared test revealed a significant difference for the sex distribution of *P* < 0.001 with a predominance of male gender in cases with associated neoplasia (Table 3).

Of 2248 patients, for whom the respective data were available, 253 benign (11%) and 1995 (89%) malignant neoplasias were reported, with the restriction that in some studies, only patients with malignant second neoplasias were included. Chronological considerations revealed that 50% (366 of 732) of second neoplasias occurred synchronously to GIST, 26% (187 of 732) occurred before GIST, and 24% (179 of 732) were diagnosed after GIST. Focusing on synchronous second neoplasias, a rate of 6% (366 of 5131) was detected among all GIST patients. Of these synchronous second neoplasias 77% (177 of 230) occurred in the GI-Tract and 7% (16 of 230) in the male and female urogenital tract. The distribution of different histological subtypes (spindle *vs* epithelioid *vs* mixed) revealed no differences between the GIST-only patients and the patients with another neoplasm (spindle: 78% *vs* 80%; epithelioid: 8% *vs* 6%; mixed: 14% *vs* 14%) (Table 4).

Figure 2 gives an overview of the different localizations of the GIST-associated neoplasias. The most common manifestation was seen in the gastrointestinal tract (32%), followed by urogenital and female genital tract (30%); 10% of additional tumors were found in the breast and 6% each in the lung and in the blood and lymphatic system.

Regarding the risk scores for disease progression or recurrence of GIST, there was a significantly (*P* < 0.001) higher proportion of very low- and low-risk GIST in patients



**Figure 1** Flow of analysis based on the retrieved literature. GIST: Gastrointestinal stromal tumors.

with an additional tumor (65%) compared to the GIST-only group (35%), whereas in this latter group, the portion of intermediate and high-risk patients was higher (69% vs 31%). For calculation, we used the risk scores as they were applied in the different studies, which were most frequently those according to Fletcher *et al*<sup>[4]</sup> or Miettinen *et al*<sup>[16]</sup> (Table 5).

The mutational status of driver genes in patients with GIST and associated neoplasias was reported in only four of the 22 studies, with a total of 167 patients. These patients with GIST and second tumors showed mutations in exon 11 of the KIT gene in 69%, non-exon-11 mutations of the KIT gene in 6%, mutations in the PDGFR- $\alpha$  gene in 13%, and a “wildtype” status in 13%.

Data on follow-up was very heterogeneously reported or not available in most of the included studies, which is why even a descriptive analysis was not feasible.

## DISCUSSION

In our systematic review, we detected a rate of 20.1% of second neoplasias in GIST patients, with the most frequent localization of associated tumors in the gastrointestinal tract and in the urogenital and female genital tract. Previously described rates of GIST-associated neoplasias varied between 11% and 50%<sup>[13,17]</sup>. The general probability of being diagnosed with cancer twice in a lifetime is estimated between 2% and 17% (syndromic settings or familial predisposition included)<sup>[18]</sup> or in other words with a chance of 1:9<sup>[12,19]</sup>. Compared to this number the rate of second neoplasias we found in GIST patients is obviously higher than expected. Several reasons can be considered accountable for the development of multiple tumors in one patient, for example, similar risk factors, environmental factors, or genetic predisposition, but also the higher likelihood of detection of another tumor within the examinations for staging or follow-up. In cases of sporadic GIST there are no definitely confirmed intrinsic risk factors or environmental factors. Genetic factors play a role in syndromes such as neurofibromatosis type I or Carney triad, but these patients were excluded in our study, and only patients with sporadic GIST were included. The occurrence of GIST-specific mutations such as in the c-KIT or PDGFR $\alpha$  gene that we found in the group of patients with GIST and second neoplasms were similar to those reported for GIST in general before<sup>[5-7]</sup>.

The localization of GIST-associated neoplasias with the highest frequency in the gastrointestinal tract, the urogenital, and female genital tract is consistent with previously reported findings<sup>[20,21]</sup>. In addition to a possible common underlying predisposition, the probability of detecting even small GIST during staging examinations for gastrointestinal tract tumors might be higher than in cases of, for example, lung or head and neck tumors. This might also be the explanation for the high rate of 77% of GI-tract localization in synchronous second neoplasias.

The median age of the total study population compared to the group of patients



**Table 1 Case reports: Overview of tumor entities**

<b>Tumor entity</b>	<b>Ref.</b>
<b>Gastrointestinal Tract</b>	
Gastric adenocarcinoma	[29-55]
Colorectal adenocarcinoma	[56-71]
Gastric high grade IEN	[72]
Esophagus SCC	[48,59,73]
Esophagus Small Cell Carcinoma	[39]
Gastro-esophageal junction adenocarcinoma	[74,75]
Duodenum adenocarcinoma	[76]
Papilla Vateri NET	[77]
Gastric Lipoma	[78]
Gastric NET	[79-82]
Doudenum NET	[67]
Ileum NET	[83]
Gastric Schwannoma	[84]
Colon NET	[85]
Jejunal Sarcomatoid Carcinoma	[86]
Pancreas adenosquamous carcinoma	[87,88]
Pancreas adenocarcinoma	[89,90]
Pancreas NET	[91-95]
Hepatocellular carcinoma	[96-99]
Cholangiocellular Carcinoma	[100,101]
Perivascular Epitheloid Cell Tumor Liver	[102]
<b>Urogenital Tract</b>	
Renal Cell Carcinoma	[103,104]
Renal Chromophobe Cell Carcinoma	[105]
Prostate Adenocarcinoma	[40,69,82,106,107]
Transitional Cell Carcinoma Bladder	[86]
<b>Female Genitale Tract</b>	
Ovarian Carcinoma	[108]
Ovarian Serous Adenocarcinoma	[109,110]
Uterus Leiomyoma	[91]
<b>Breast</b>	
Sarcoma	[111]
Invasive Ductal Carcinoma	[55,61,63,92]
<b>Blood/ Lymphatic</b>	
Acute Myeloid Leukemia	[112-114]
Acute Biphentotypic Leukemia	[100]
Chronic Lymphoid Leukemia	[115]
Low Grade B Cell Lymphoma Stomach	[116]
Extranodal DLBCL	[117,118]
Burkitt Lymphoma	[119]
Mantle Cell Lymphoma Appendix	[120]
MALT Lymphoma	[50,121]
Multiple Myeloma	[122]
<b>Head and Neck</b>	
Oral Melanoma	[123]
Papillary Thyroid Carcinoma	[124]
<b>Lung</b>	
Adenocarcinoma	[125-127]
SCC	[107]
NSCLC	[106]
<b>Skin</b>	

Melanoma	[128,129]
Squamous Cell Carcinoma	[130]
Merkel Cell Carcinoma	[131]
<b>Soft Tissue</b>	
Myxofibrosarcoma	[82]
Dermatofibrosarcoma	[132]
Ewing Sarkoma	[133]
<b>Others</b>	
Adrenocortical Carcinoma	[134]
Peritoneal Mesothelioma	[135]
Mesenterial Fibromatosis	[136]
Granular cell tumor	[55]

IEN: Intraepithelial neoplasia; SCC: Squamous-cell carcinoma; NET: Neuroendocrine tumor; DLBCL: Diffuse large B cell lymphoma; MALT: Mucosa associated lymphatic tissue; NSCLC: Non-small cell lung cancer.

who developed a second tumor showed a difference of five years at the time-point of GIST diagnosis, with the higher median age in the GIST with associated neoplasm group. A possible explanation for this finding could be the age-dependent risk increase for cancer in general<sup>[14]</sup>. Previously performed reviews on the topic of GIST and associated neoplasms mostly concentrated on the occurrence rate and localization of the associated tumors and, in some cases, on the outcome and follow-up<sup>[20-24]</sup>. Analysis of age or sex distribution have not been performed on larger numbers of patients. We found a significantly higher number of male patients who were diagnosed with GIST and a second neoplasia than in the total population of GIST patients. An equal sex distribution for GIST patients in general has been reported in the literature before<sup>[1]</sup>. Regarding the overall incidence of cancer worldwide, the sex distribution of patients diagnosed with cancer in 2018 is estimated at a male-to-female ratio of 1.1:1 (9.5 million new cases in men and 8.6 million new cases in women). Among gastrointestinal neoplasias, which were the most frequent GIST-associated neoplasias in our review, there is a difference in the worldwide incidence between men and women with a higher rate of gastrointestinal (GI) tumors diagnosed in men in 2018 (2.7 million cases in men *vs* 1.4 million cases in women)<sup>[25]</sup>. Whether there is a difference of distribution of the second neoplasias between sexes in our review population remains unclear. In most analyzed studies, the reported data was not sufficient to answer this question.

Several risk classification systems are used to assess the risk of disease progression or recurrence of GIST<sup>[4,16]</sup>. Most of them use the size, localization, and mitotic rate of GIST and are therefore, at least in part, comparable. By summarizing the risk categories in two groups (very low and low *vs* intermediate and high), we could find a significant difference between the GIST-only patients and those having GIST and another neoplasia by using the chi-squared test. The patients with GIST-associated neoplasias had lower risk scores, which might be due to a higher detection rate of even small GISTs with low risk scores in the setting of another neoplastic disease.

Since the establishment of targeted therapies for GIST with imatinib or second-line tyrosine kinase inhibitors, the prognosis even of advanced GIST has significantly improved<sup>[26]</sup>. On the other side, there is growing interest in the question of elevated risk of developing secondary neoplasia under the treatment with imatinib. Phan *et al.* found a higher rate of secondary tumors among GIST patients in the imatinib era than in the pre-imatinib era<sup>[27]</sup>, although the most likely reason for this is the prolonged survival even of patients with advanced GIST, as it has been described by different authors<sup>[28]</sup>. Another point that relativizes the impact of imatinib on the development of secondary tumors can be seen in our review: About 75% of associated neoplasias were diagnosed either before GIST or synchronously with GIST; furthermore, not all patients with a GIST diagnosis in advance were treated with imatinib.

In summary, in this, to our knowledge first, systematic review on the topic of secondary neoplasia in patients with GIST, we confirm the previously described elevated number of associated neoplasms and the most common localizations of this neoplasms. We found a higher median age in the GIST with second neoplasia group and significantly more male patients who developed associated tumors, whereas the risk scores of GIST in this group were significantly lower. We conclude that even very low- and low-grade GISTs should be a reason to consider frequent controls or extended staging for early detection of second neoplasias, especially in the gastrointestinal and urogenital tract. To understand whether there is an underlying

Table 2 Retrospective and prospective studies used for this investigation

Author	Year	Date of diagnosis	N	Patient characteristics				Organ systems affected by associated NPL											
				Age average (median)		Sex m/f		Number (rate) of patients with ass. NPL	GI-tract	Liver/gall bladder/pancreas	Uro-genital tract	Female genital tract	Breast	Blood/lymphatic system	Head and neck	Lung	Skin/melanoma	Soft	Other
				Total population	Pat. with ass. NPL	Total population	Pat. with ass. NPL												
Adim <i>et al</i> <sup>[137]</sup>	2011	1997-2009	78		62		9/4	13 (17%)	9	2	1		1						
Agamy <i>et al</i> <sup>[14]</sup>	2005	1997-2004	97	65	72	42/55	6/12	18 (17%)	6	3	2	3	2	2		2			
Aghdassi <i>et al</i> <sup>[138]</sup>	2018	1993-2011	104	67		54/50		44 (42%)	16	4	8		7	2				1	
Amaadour <i>et al</i> <sup>[139]</sup>	2013	1998-2006	43	62	65	15/28	1/5	6 (14%)	5				1						
Fernandez <i>et al</i> <sup>[140]</sup>	2018	1999-2016	104		64	62/42	22/10	32 (31%)	9	4	7		3	3	2	2	1	1	
Ferreira <i>et al</i> <sup>[141]</sup>	2010	1998-2006	43	62	61	15/28	1/5	6 (14%)	5				1						
Giuliani <i>et al</i> <sup>[142]</sup>	2012	2002-2010	24	66	69	12/12	5/3	8 (33%)	6		1		1						
Gonçalves <i>et al</i> <sup>[143]</sup>	2010	1998-2008	101		68		5/9	14 (14%)	8		2	2	1						1
Hechtmann <i>et al</i> <sup>[144]</sup>	2015	2009-2013	260		65	142/18	30/20	50 (19%)	2		21	1	8	8	7	1	3	3	6
Kramer <i>et al</i> <sup>[17]</sup>	2015	2006-2011	836	68	69	423/13	148/19	422 (51%)	118	20	60	22	26	23	6	8	23	2	9
Lai <i>et al</i> <sup>[145]</sup>	2016	1995-2015	749		68		77/59	136 (18%)	64	27	12	10	7	1	9	13	4	3	10
Liszka <i>et al</i> <sup>[146]</sup>	2007	1989-2006	82		64	38/44	12/10	22 (27%)	17	5			1						
Mayr <i>et al</i> <sup>[15]</sup>	2019	1998-2017	188		69			70 (37%)	23	1	17	9	5	5		2	5		3
Murphy <i>et al</i> <sup>[12]</sup>	2015	2001-2011	6112			3252/2860	727/481	1047 (17%)	208	34	432		144	80	54	99	52	48	72

Pan- dur- eng- an <i>et al</i> <sup>[147]</sup>	2010	1995- 2007	783	57		444/3 39	91/62	153 (20%)	40	8	48	14	15	12	1	10	9	9	20
Ponti <i>et al</i> <sup>[148]</sup>	2010	1988- 2007	141	66	67	77/64	20/26	46 (33%)	18	1	7	2	6	1		2	1	2	3
Ric- hter <i>et al</i> <sup>[149]</sup>	2008	1993- 2005	54	65		28/26		13 (20%)	7		3		1	1					1
Rod- riq- uenz <i>et al</i> <sup>[150]</sup>	2016	2002- 2014	128	65	68	59/69	19/27	46 (34%)	24	5	3	4	2	1	1	3		3	1
Rub- io- Cas- ade- vall <i>et al</i> <sup>[151]</sup>	2015	1996- 2006	132	65		67/53		30 (23%)	8	2	3	1	3			3			
Sevi- nc <i>et al</i> <sup>[152]</sup>	2011	2002- 2009	200		67		20/12	32 (16%)	16		5	1	2	1	2			1	4
Smi- th <i>et al</i> <sup>[13]</sup>	2016	2001- 2009	1705	63	69	885/8 20	95/86	181 (11%)											
Vas- sos <i>et al</i> <sup>[153]</sup>	2014	2000- 2009	86	66	70	50/36	27/10	37 (43%)	19	7	5			4	3		3	1	
			12050	63	68	1.1 : 1	1.4 : 1	2426 (20.1 %)	751 (32%)		706 (30%)		236 (10%)	145 (6%)	85 (4%)	145 (6%)	101 (4%)	74 (3%)	130 (5%)

genetic cause for the elevated rates of GIST-associated neoplasias, further studies will be needed.

**Table 3 Age and sex distribution**

	Total study population	GIST with associated neoplasia	No. of patients available for calculation
Age (median)	63	68	4176/1139
Sex male: Female	1.1:1	1.4:1	10444/2080

GIST: Gastrointestinal stromal tumors.

**Table 4 Characteristics of gastrointestinal stromal tumors and associated neoplasias**

Parameter	Quantification	No. of patients available for calculation
Designation of associated NPL, <i>n</i> (%)	Benigne 253 (11) Malignant 1995 (89)	2248
Chronological presentation, <i>n</i> (%)	Synchronous 366 (50) GIST first 179 (24) Ass. NPL first 187 (26)	732
Histological subtypes of GIST, <i>n</i> (%)	Spindle Epithelioid Mixed	Total population 409 (78) GIST + ass. NPL 149 (80) Total population 43 (8) GIST + ass. NPL 11 (6) Total population 73 (14) GIST + ass. NPL 25 (14)

GIST: Gastrointestinal stromal tumors.

**Table 5 Distribution of risk scores, *n* (%)**

Risk score	GIST without associated neoplasia	GIST with associated neoplasia	Total
Low and very low	123 (35)	230 (65)	353
Intermediate and high	373 (69)	165 (31)	538
Total	496	395	891

GIST: Gastrointestinal stromal tumors.



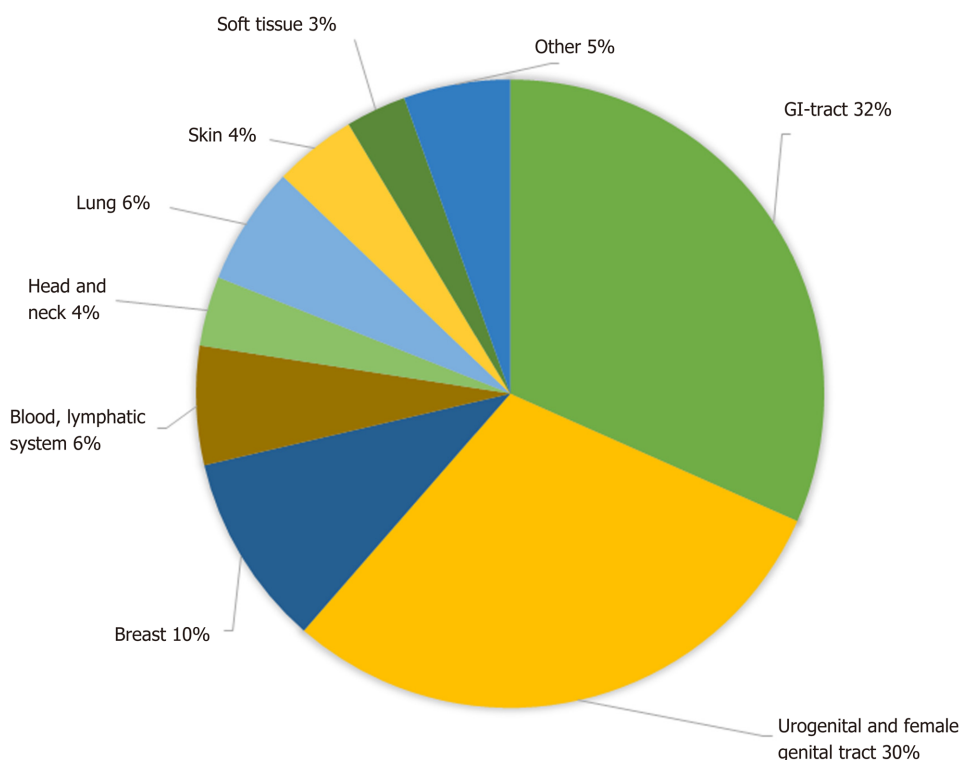


Figure 2 Localization of gastrointestinal stromal tumor-associated neoplasias. GI: Gastrointestinal.

## ARTICLE HIGHLIGHTS

### Research background

In recent years, numerous case reports, mostly retrospective studies and a few reviews on the topic of second neoplasias associated with gastrointestinal stromal tumors (GIST) have been published. To our knowledge, however, this is the first systematic review of the existing data.

### Research motivation

The aim of this review was to prepare a compilation, as complete as possible, of all reported second tumor entities that have been described in association with GIST, and to systematically analyze the published studies with regard to frequency, localization, and types of GIST-associated neoplasms.

### Research objectives

The main focus of this review was on frequency, localization, dependence of gender, age and risk classification of GIST associated neoplasias. Summarizing the data of a large number of patients could especially help in the daily clinical work with GIST patients.

### Research methods

The MEDLINE and EBSCO databases were searched for a combination of the keywords GIST/secondary, synchronous, coincident/tumor, neoplasm, and relevant publications were selected by two independent authors. All case reports were summarized according to the reported tumor entity and included clinical studies were analyzed with regard to the previously mentioned topics.

### Research results

Of the initially found 3042 publications, 130 papers were selected; 22 of these were original studies, and 108 were case reports. In the 22 selected studies, comprising a total number of 12050 patients, an overall rate of GIST-associated neoplasias of 20% could be calculated. Most second neoplasias were found in the gastrointestinal tract (32%) and in the male and female urogenital tract (30%). The male-to-female ratio revealed a predominance of male gender in cases with associated neoplasia. The specific risk scores of GISTs associated with other tumors were significantly lower than those of GIST without associated neoplasias. The question if there are specific genetic mutations that occur with a higher frequency in GIST patients with second tumors could not be answered and would be an interesting topic for future research.

### Research conclusions

GISTs are associated with other neoplasias with a rate of 20% and occur most frequently in the gastrointestinal and urogenital tract. This confirms previous findings on a larger number of

patients. GIST associated neoplasias occur with a higher likelihood in older, male patients with low grade GIST. 50% of GIST associated neoplasias are detected synchronously. Our findings should be a reason to consider frequent controls or extended staging for early detection of second neoplasias, especially in the gastrointestinal and urogenital tract.

### Research perspectives

If there is a causal relation between GIST and second tumors remains unclear. As data on genetic mutations of the GIST were reported very heterogeneously focusing on this topic could be an interesting point for future research.

## REFERENCES

- 1 **Søreide K**, Sandvik OM, Søreide JA, Giljaca V, Jureckova A, Bulusu VR. Global epidemiology of gastrointestinal stromal tumours (GIST): A systematic review of population-based cohort studies. *Cancer Epidemiol* 2016; **40**: 39-46 [PMID: 26618334 DOI: 10.1016/j.canep.2015.10.031]
- 2 **Miettinen M**, Lasota J. Gastrointestinal stromal tumors--definition, clinical, histological, immunohistochemical, and molecular genetic features and differential diagnosis. *Virchows Arch* 2001; **438**: 1-12 [PMID: 11213830 DOI: 10.1007/s004280000338]
- 3 **Hirota S**, Isozaki K. Pathology of gastrointestinal stromal tumors. *Pathol Int* 2006; **56**: 1-9 [PMID: 16398673 DOI: 10.1111/j.1440-1827.2006.01924.x]
- 4 **Fletcher CD**, Berman JJ, Corless C, Gorstein F, Lasota J, Longley BJ, Miettinen M, O'Leary TJ, Remotti H, Rubin BP, Shmookler B, Sobin LH, Weiss SW. Diagnosis of gastrointestinal stromal tumors: A consensus approach. *Hum Pathol* 2002; **33**: 459-465 [PMID: 12094370 DOI: 10.1177/106689690201000201]
- 5 **Hirota S**, Isozaki K, Moriyama Y, Hashimoto K, Nishida T, Ishiguro S, Kawano K, Hanada M, Kurata A, Takeda M, Muhammad Tunio G, Matsuzawa Y, Kanakura Y, Shinomura Y, Kitamura Y. Gain-of-function mutations of c-kit in human gastrointestinal stromal tumors. *Science* 1998; **279**: 577-580 [PMID: 9438854 DOI: 10.1126/science.279.5350.577]
- 6 **Corless CL**, Barnett CM, Heinrich MC. Gastrointestinal stromal tumours: origin and molecular oncology. *Nat Rev Cancer* 2011; **11**: 865-878 [PMID: 22089421 DOI: 10.1038/nrc3143]
- 7 **Hirota S**, Ohashi A, Nishida T, Isozaki K, Kinoshita K, Shinomura Y, Kitamura Y. Gain-of-function mutations of platelet-derived growth factor receptor alpha gene in gastrointestinal stromal tumors. *Gastroenterology* 2003; **125**: 660-667 [PMID: 12949711 DOI: 10.1016/S0016-5085(03)01046-1]
- 8 **Rubin BP**, Heinrich MC. Genotyping and immunohistochemistry of gastrointestinal stromal tumors: An update. *Semin Diagn Pathol* 2015; **32**: 392-399 [PMID: 25766843 DOI: 10.1053/j.semdp.2015.02.017]
- 9 **Miettinen M**, Fetsch JF, Sobin LH, Lasota J. Gastrointestinal stromal tumors in patients with neurofibromatosis 1: a clinicopathologic and molecular genetic study of 45 cases. *Am J Surg Pathol* 2006; **30**: 90-96 [PMID: 16330947 DOI: 10.1097/01.pas.0000176433.81079.bd]
- 10 **Carney JA**. Carney triad. *Front Horm Res* 2013; **41**: 92-110 [PMID: 23652673 DOI: 10.1159/000345672]
- 11 **Li FP**, Fletcher JA, Heinrich MC, Garber JE, Sallan SE, Curiel-Lewandrowski C, Duensing A, van de Rijn M, Schnipper LE, Demetri GD. Familial gastrointestinal stromal tumor syndrome: phenotypic and molecular features in a kindred. *J Clin Oncol* 2005; **23**: 2735-2743 [PMID: 15837988 DOI: 10.1200/jco.2005.06.009]
- 12 **Murphy JD**, Ma GL, Baumgartner JM, Madlensky L, Burgoyne AM, Tang CM, Martinez ME, Sicklick JK. Increased risk of additional cancers among patients with gastrointestinal stromal tumors: A population-based study. *Cancer* 2015; **121**: 2960-2967 [PMID: 25930983 DOI: 10.1002/cncr.29434]
- 13 **Smith MJ**, Smith HG, Mahar AL, Law C, Ko YJ. The impact of additional malignancies in patients diagnosed with gastrointestinal stromal tumors. *Int J Cancer* 2016; **139**: 1744-1751 [PMID: 27299364 DOI: 10.1002/ijc.30231]
- 14 **Agaimy A**, Wuensch PH. Gastrointestinal stromal tumours in patients with other-type cancer: a mere coincidence or an etiological association? A study of 97 GIST cases. *Z Gastroenterol* 2005; **43**: 1025-1030 [PMID: 16142610 DOI: 10.1055/s-2005-858378]
- 15 **Mayr P**, Märkl B, Agaimy A, Kriening B, Dintner S, Schenkirsch G, Schneider-Stock R. Malignancies associated with GIST: a retrospective study with molecular analysis of KIT and PDGFRA. *Langenbecks Arch Surg* 2019 [PMID: 30877378 DOI: 10.1007/s00423-019-01773-2]
- 16 **Miettinen M**, Lasota J. Gastrointestinal stromal tumors: pathology and prognosis at different sites. *Semin Diagn Pathol* 2006; **23**: 70-83 [PMID: 17193820 DOI: 10.1053/j.semdp.2006.09.001]
- 17 **Kramer K**, Wolf S, Mayer B, Schmidt SA, Agaimy A, Henne-Bruns D, Knippschild U, Schwab M, Schmieder M. Frequency, spectrum and prognostic impact of additional malignancies in patients with gastrointestinal stromal tumors. *Neoplasia* 2015; **17**: 134-140 [PMID: 25622906 DOI: 10.1016/j.neo.2014.12.001]
- 18 **Vogt A**, Schmid S, Heinemann K, Frick H, Herrmann C, Cerny T, Omlin A. Multiple primary tumours: challenges and approaches, a review. *ESMO Open* 2017; **2**: e000172 [PMID: 28761745 DOI: 10.1136/esmoopen-2017-000172]
- 19 **Rheingold SR**, Neugut AI, Meadows AT. Secondary cancers: incidence, risk factors, and management. In: Kufe DW, Pollock RE, Weichselbaum RR, Bast RC Jr, Gansler TS, Holland JF, Frei E III, editor. *Holland-Frei Cancer Medicine*. 6th edition. Hamilton: BC Decker, 2003: Chapter 159
- 20 **Agaimy A**, Wünsch PH, Sobin LH, Lasota J, Miettinen M. Occurrence of other malignancies in patients with gastrointestinal stromal tumors. *Semin Diagn Pathol* 2006; **23**: 120-129 [PMID: 17193825 DOI: 10.1053/j.semdp.2006.09.004]
- 21 **Fernández Hernández JÁ**, Olivares Ripoll V, Parrilla Paricio P. [Additional primary malignancies in patients with gastrointestinal stromal tumors. Proposal for a new classification]. *Med Clin (Barc)* 2016; **147**: 405-409 [PMID: 27431886 DOI: 10.1016/j.medcli.2016.06.006]
- 22 **Núñez-Martín R**, Cubedo Cervera R, Provencio Pulla M. Gastrointestinal stromal tumour and second tumours: A literature review. *Med Clin (Barc)* 2017; **149**: 345-350 [PMID: 28736068 DOI: 10.1016/j.medcli.2017.06.010]
- 23 **Burgoyne AM**, Somaiah N, Sicklick JK. Gastrointestinal stromal tumors in the setting of multiple tumor syndromes. *Curr Opin Oncol* 2014; **26**: 408-414 [PMID: 24840526 DOI: 10.1093/cop/26.4.408]

- 10.1097/CCO.000000000000089]
- 24 **Giuliani J**, Bonetti A. The Occurrence of Gastrointestinal Stromal Tumors and Second Malignancies. *J Gastrointest Cancer* 2015; **46**: 408-412 [PMID: 26337186 DOI: 10.1007/s12029-015-9759-3]
  - 25 **Bray F**, Ferlay J, Soerjomataram I, Siegel RL, Torre LA, Jemal A. Global cancer statistics 2018: GLOBOCAN estimates of incidence and mortality worldwide for 36 cancers in 185 countries. *CA Cancer J Clin* 2018; **68**: 394-424 [PMID: 30207593 DOI: 10.3322/caac.21492]
  - 26 **Artinyan A**, Kim J, Soriano P, Chow W, Bhatia S, Ellenhorn JD. Metastatic gastrointestinal stromal tumors in the era of imatinib: improved survival and elimination of socioeconomic survival disparities. *Cancer Epidemiol Biomarkers Prev* 2008; **17**: 2194-2201 [PMID: 18708414 DOI: 10.1158/1055-9965.EPI-08-0237]
  - 27 **Phan K**, Martires K, Kurlander DE, Gaddipati K, Xavier M. The incidence of second primary malignancies after gastrointestinal stromal tumor before and after the introduction of imatinib mesylate. *TCR* 2013; **3**: 152-159 [DOI: 10.3978/j.issn.2218-676X.2013.07.04]
  - 28 **Giuliani J**, Bonetti A. Gastrointestinal stromal tumors and second primary malignancies before and after the introduction of imatinib mesylate. *Chin J Cancer Res* 2013; **25**: 486-487 [PMID: 24255568 DOI: 10.3978/j.issn.1000-9604.2013.10.13]
  - 29 **Cinar H**, Topgul K, Kesicioglu T, Can B, Koca B, Karabicak I, Ozbalci GS. Synchronous primary adenocarcinoma and gastrointestinal stromal tumor in the stomach. *Haseki Tip Bulteni* 2014; **52**: 50-52
  - 30 **Jeong SH**, Lee YJ, Park ST, Choi SK, Hong SC, Jung EJ, Ju YT, Jeong CY, Ha WS. Synchronous Adenocarcinoma and Gastrointestinal Stromal Tumor of the Stomach Treated by a Combination of Laparoscopy-assisted Distal Gastrectomy and Wedge Resection. *J Gastric Cancer* 2011; **11**: 55-58 [PMID: 22076202 DOI: 10.5230/jgc.2011.11.1.55]
  - 31 **Kleist B**, Lasota J, Miettinen M. Gastrointestinal stromal tumor and gastric adenocarcinoma collision tumors. *Hum Pathol* 2010; **41**: 1034-1039 [PMID: 20381123 DOI: 10.1016/j.humpath.2009.11.017]
  - 32 **Kountourakis P**, Arniogiannaki N, Stavrinides I, Apostolikas N, Rigatos G. Concomitant gastric adenocarcinoma and stromal tumor in a woman with polymyalgia rheumatica. *World J Gastroenterol* 2008; **14**: 6750-6752 [PMID: 19034984]
  - 33 **Kycyer W**, Teresiak M, Lozinski C. A case of multi-focus gastric adenocarcinoma occurring synchronously with an associated gastric GIST. *Rep Pract Oncol Radiother* 2006; **11**: 97-100
  - 34 **Lee FY**, Jan YJ, Wang J, Yu CC, Wu CC. Synchronous gastric gastrointestinal stromal tumor and signet-ring cell adenocarcinoma: a case report. *Int J Surg Pathol* 2007; **15**: 397-400 [PMID: 17913950 DOI: 10.1177/1066896907302369]
  - 35 **Moran M**, Bilgic I, Dilektasli E, Albayrak L, Oruc MT, Ozmen MM. Synchronous tumors of the stomach: A case report of mixed gastrointestinal stromal tumor and adenocarcinoma. *Turk Geriatri Dergisi* 2010; **13**: 125-128
  - 36 **Munekage E**, Namikawa T, Kawanishi Y, Munekage M, Maeda H, Kitagawa H, Sakamoto K, Obatake M, Kobayashi M, Hanazaki K. Synchronous large gastrointestinal stromal tumor and adenocarcinoma in the stomach treated with imatinib mesylate followed by total gastrectomy. *J Gastroenterol Hepatol (Australia)* 2016; **31** Suppl 3: 106-107
  - 37 **Narasimhamurthy MS**, Vallachira GP, Mahadev PS. Synchronous adenocarcinoma and gastrointestinal stromal tumor in the stomach. *Saudi J Gastroenterol* 2010; **16**: 218-220 [PMID: 20616420 DOI: 10.4103/1319-3767.65196]
  - 38 **Athanassiou E**, Vamvakopoulou DN, Zacharoulis D, Paroutoglou G, Sioutopoulou D, Tepetes K, Nomikos I, Vamvakopoulos NC. Immunophenotypic evaluation of DNA mismatch repair markers in 2 cases of synchronous histomorphologically distinct gastric adenocarcinomas with gastrointestinal stromal tumors of the proximal small bowel. *Appl Immunohistochem Mol Morphol* 2010; **18**: 288-290 [PMID: 20090515 DOI: 10.1097/PAI.0b013e3181ca8fbd]
  - 39 **Fan H**, Lu P, Xu L, Qin Y, Li J. Synchronous occurrence of hereditary gastric adenocarcinoma, gastrointestinal stromal tumor, and esophageal small cell and squamous carcinoma in situ: an extremely rare case report. *BMC Cancer* 2017; **17**: 720 [PMID: 29115925 DOI: 10.1186/s12885-017-3736-0]
  - 40 **Kalender ME**, Sevinc A, Kucukdurmaz Z, Balik A, Sari I, Camci C. Gastric and prostate adenocarcinoma in a patient with metastatic gastrointestinal stromal tumor. *Onkologie* 2007; **30**: 568-570 [PMID: 17992028 DOI: 10.1159/000108640]
  - 41 **Ozgun YM**, Ergul E, Sisman IC, Kusdemir A. Gastric adenocarcinoma and GIST (collision tumors) of the stomach presenting with perforation; first report. *Bratisl Lek Listy* 2009; **110**: 504-505 [PMID: 19750991]
  - 42 **Sista F**, Abruzzese V, Schietroma M, Amicucci G. Concomitant gastrointestinal stromal tumor of the stomach and gastric adenocarcinoma in a patient with billroth 2 resection. *Case Rep Surg* 2013; **2013**: 583856 [PMID: 24455386 DOI: 10.1155/2013/583856]
  - 43 **Telugu RB**, Pushparaj M, Masih D, Pulimood A. Synchronous Appearance of Adenocarcinoma and Gastrointestinal Stromal Tumour (GIST) of the Stomach: A Case Report. *J Clin Diagn Res* 2016; **10**: ED16-ED18 [PMID: 27042477 DOI: 10.7860/JCDR/2016/17636.7289]
  - 44 **Theodosopoulos T**, Dellaportas D, Psychogiou V, Gennatas K, Kondi-Pafiti A, Gkiokas G, Papaconstantinou I, Polymeneas G. Synchronous gastric adenocarcinoma and gastrointestinal stromal tumor (GIST) of the stomach: a case report. *World J Surg Oncol* 2011; **9**: 60 [PMID: 21615935 DOI: 10.1186/1477-7819-9-60]
  - 45 **Uchiyama S**, Nagano M, Takahashi N, Hidaka H, Matsuda H, Nagaike K, Maehara N, Hotokezaka M, Chijiwa K. Synchronous adenocarcinoma and gastrointestinal stromal tumors of the stomach treated laparoscopically. *Int J Clin Oncol* 2007; **12**: 478-481 [PMID: 18071869 DOI: 10.1007/s10147-007-0684-8]
  - 46 **Villias C**, Gourgiotis S, Veloudis G, Sampaziotis D, Moreas H. Synchronous early gastric cancer and gastrointestinal stromal tumor in the stomach of a patient with idiopathic thrombocytopenic purpura. *J Dig Dis* 2008; **9**: 104-107 [PMID: 18419644 DOI: 10.1111/j.1751-2980.2008.00330.x]
  - 47 **Vogel Y**, Müller C, Uhl W, Tannapfel A. [Coexistence of multifocal gastric adenocarcinoma with signet-ring cell morphology and a gastrointestinal stromal tumour in a stomach with hp-associated gastritis]. *Z Gastroenterol* 2011; **49**: 201-206 [PMID: 21298606 DOI: 10.1055/s-0029-1245593]
  - 48 **Zhou Y**, Wu XD, Shi Q, Jia J. Coexistence of gastrointestinal stromal tumor, esophageal and gastric cardia carcinomas. *World J Gastroenterol* 2013; **19**: 2005-2008 [PMID: 23569349 DOI: 10.3748/wjg.v19.i12.2005]
  - 49 **Salemis NS**, Gourgiotis S, Tsiambas E, Karameris A, Tsohataridis E. Synchronous occurrence of advanced adenocarcinoma with a stromal tumor in the stomach: a case report. *J Gastrointest Liver Dis* 2008; **17**: 213-215 [PMID: 18568146]

- 50 **Kaffes A**, Hughes L, Hollinshead J, Katelaris P. Synchronous primary adenocarcinoma, mucosa-associated lymphoid tissue lymphoma and a stromal tumor in a *Helicobacter pylori*-infected stomach. *J Gastroenterol Hepatol* 2002; **17**: 1033-1036 [PMID: [12167128](#)]
- 51 **Yamamoto D**, Hamada Y, Tsubota Y, Kawakami K, Yamamoto C, Yamamoto M. Simultaneous development of adenocarcinoma and gastrointestinal stromal tumor (GIST) in the stomach: case report. *World J Surg Oncol* 2012; **10**: 6 [PMID: [22230934](#) DOI: [10.1186/1477-7819-10-6](#)]
- 52 **Lin YL**, Tzeng JE, Wei CK, Lin CW. Small gastrointestinal stromal tumor concomitant with early gastric cancer: a case report. *World J Gastroenterol* 2006; **12**: 815-817 [PMID: [16521203](#)]
- 53 **Chen JH**, Chen CC, Tzeng LM, Tsay SH, Chiang JH, Lu CC, Chang FY, Lee SD. Resection of triple synchronous tumors--gastric adenocarcinoma, gallbladder adenocarcinoma and stromal tumor of the stomach. *Zhonghua Yi Xue Za Zhi (Taipei)* 2001; **64**: 655-660 [PMID: [11853221](#)]
- 54 **Bircan S**, Candir O, Aydin S, Başpınar S, Bülbül M, Kapucuoglu N, Karahan N, Ciriş M. Synchronous primary adenocarcinoma and gastrointestinal stromal tumor in the stomach: a report of two cases. *Turk J Gastroenterol* 2004; **15**: 187-191 [PMID: [15492920](#)]
- 55 **Sailors JL**, French SW. The unique simultaneous occurrence of granular cell tumor, gastrointestinal stromal tumor, and gastric adenocarcinoma. *Arch Pathol Lab Med* 2005; **129**: e121-e123 [PMID: [15859656](#) DOI: [10.1043/1543-2165\(2005\)1292.0.CO;2](#)]
- 56 **Chiu HH**, Huang TC, Liu YW, Ko TL, Lu NK. Synchronous ileal stromal tumor (GIST) and colonic adenocarcinoma. *J Int Med Taiwan* 2009; **20**: 260-263
- 57 **Dimitroulopoulos D**, Fotopoulou A, Xinopoulos D, Arnogiannaki N, Korkolis D, Tsamakidis K, Kypreos D, Bassioulas S, Patsavela S, Paraskevas E. Synchronous occurrence of colorectal adenocarcinoma and colonic gastrointestinal stromal tumor (GIST). A case report. *Ann Gastroenterol* 2009; **22**: 197-200
- 58 **Efstathios P**, Athanasios P, Papaconstantinou I, Alexandros P, Frangisca S, Sotirios G, Evangelos F, Athanasios G. Coexistence of gastrointestinal stromal tumor (GIST) and colorectal adenocarcinoma: A case report. *World J Surg Oncol* 2007; **5**: 96 [PMID: [17708776](#) DOI: [10.1186/1477-7819-5-96](#)]
- 59 **Firat O**, Yazici P, Makay O, Aydin A, Tuncyurek M, Ersin S, Guler A. Co-existence of gastrointestinal stromal tumors with malign epithelial tumors: a report of two cases. *Acta Chir Belg* 2009; **109**: 629-632 [PMID: [19994809](#)]
- 60 **Gavrilidis P**, Nikolaidou A. Colon Adenocarcinoma Associated with Synchronous Extramural Gastrointestinal Stromal Tumor (GIST) of the Ileum. *Am J Case Rep* 2015; **16**: 837-839 [PMID: [26608682](#)]
- 61 **Jafferbhoy S**, Paterson H, Fineron P. Synchronous gist, colon and breast adenocarcinoma with double colonic polyp metastases. *Int J Surg Case Rep* 2014; **5**: 523-526 [PMID: [25014550](#) DOI: [10.1016/j.ijscr.2014.04.020](#)]
- 62 **Kosmidis C**, Efthimiadis C, Levva S, Anthimidis G, Baka S, Grigoriou M, Tzeveleki I, Masmanidou M, Zamboukas T, Basdanis G. Synchronous colorectal adenocarcinoma and gastrointestinal stromal tumor in Meckel's diverticulum; an unusual association. *World J Surg Oncol* 2009; **7**: 33 [PMID: [19309498](#) DOI: [10.1186/1477-7819-7-33](#)]
- 63 **Marković M**, Jurišić V, Petrović M, Dagović A, Stanković V, Mitrović S. Appearance of ductal breast and colon carcinoma with gastrointestinal stromal tumor (GIST) in a female patient: an extremely rare case. *Rom J Morphol Embryol* 2018; **59**: 613-617 [PMID: [30173272](#)]
- 64 **Melis M**, Choi EA, Anders R, Christiansen P, Fichera A. Synchronous colorectal adenocarcinoma and gastrointestinal stromal tumor (GIST). *Int J Colorectal Dis* 2007; **22**: 109-114 [PMID: [16639561](#) DOI: [10.1007/s00384-006-0089-6](#)]
- 65 **Nemes C**, Rogojan L, Surdea-Blaga T, Seicean A, Dumitrascu DL, Ciuce C. Gastrointestinal stromal tumor (GIST) associated with synchronous colon adenocarcinoma - a case report. *J Gastrointest Liver Dis* 2012; **21**: 101-103 [PMID: [22457867](#)]
- 66 **Dragan R**, Dejan S, Nebojsa M, Vinka V, Predrag S, Dragos S, Vladan Z, Dragoljub B. Synchronous appearance of gastric gastrointestinal stromal tumors and colorectal adenocarcinoma: a case report. *Hepatogastroenterology* 2011; **58**: 2171-2174 [PMID: [22234087](#) DOI: [10.5754/hge09042](#)]
- 67 **Kaur R**, Bhalla S, Nundy S, Jain S. Synchronous gastric gastrointestinal stromal tumor (GIST) and other primary neoplasms of gastrointestinal tract: report of two cases. *Ann Gastroenterol* 2013; **26**: 356-359 [PMID: [24714328](#)]
- 68 **Seshadri RA**, Singh SS, Ratnagiri R. Synchronous jejunal gastrointestinal stromal tumor and primary adenocarcinoma of the colon. *Indian J Surg* 2012; **74**: 196-198 [PMID: [23543778](#) DOI: [10.1007/s12262-011-0236-3](#)]
- 69 **Suzuki T**, Suwa K, Hanyu K, Okamoto T, Fujita T, Yanaga K. Large gastrointestinal stromal tumor and advanced adenocarcinoma in the rectum coexistent with an incidental prostate carcinoma: A case report. *Int J Surg Case Rep* 2014; **5**: 640-642 [PMID: [25052916](#) DOI: [10.1016/j.ijscr.2014.06.012](#)]
- 70 **Trajkovska E**, Janevska V, Spasevska L, Janevski V, Zhivadinovik J, Petrushevska G, Dukova B. Synchronous occurrence of ileal stromal tumor (GIST) and colonic adenocarcinoma: a case report. *Pril (Makedon Akad Nauk Umet Odd Med Nauki)* 2015; **36**: 219-223 [PMID: [26076794](#)]
- 71 **Kumar K**, Rowsell C, Law C, Ko YJ. Coexistence of gastrointestinal stromal tumour and colorectal adenocarcinoma: Two case reports. *J Gastrointest Oncol* 2011; **2**: 50-54 [PMID: [22811828](#) DOI: [10.3978/j.issn.2078-6891.2010.029](#)]
- 72 **Mou YP**, Xu XW, Xie K, Zhou W, Zhou YC, Chen K. Laparoscopic wedge resection of synchronous gastric intraepithelial neoplasia and stromal tumor: a case report. *World J Gastroenterol* 2010; **16**: 5005-5008 [PMID: [20954290](#)]
- 73 **Spinelli GP**, Miele E, Tomao F, Rossi L, Pasciuti G, Zullo A, Zoratto F, Nunnari J, Pisanelli GC, Tomao S. The synchronous occurrence of squamous cell carcinoma and gastrointestinal stromal tumor (GIST) at esophageal site. *World J Surg Oncol* 2008; **6**: 116 [PMID: [18986537](#) DOI: [10.1186/1477-7819-6-116](#)]
- 74 **Alkaaki A**, Abdulhadi B, Aljiffry M, Nassif M, Al-Maghrabi H, Maghrabi AA. Coexistence of Primary GEJ Adenocarcinoma and Pedunculated Gastric Gastrointestinal Stromal Tumor. *Case Rep Surg* 2018; **2018**: 4378368 [PMID: [29992077](#) DOI: [10.1155/2018/4378368](#)]
- 75 **Grigor'eva VD**, Guliaeva EN. [The combined use of dry-air carbon dioxide baths and applications of peloids at low temperatures in the rehabilitation of patients with psoriatic arthritis]. *Vopr Kurortol Fizioter Lech Fiz Kult* 1998; **25**: 25-28 [PMID: [9560999](#) DOI: [10.1016/S1607-551X\(99\)70525-X](#)]
- 76 **Blandamura S**, Alessandrini L, Bertorelle R, Simonato F, Guzzardo V, Valentini E, Angriman I, Fassina A. Multiple sporadic gastrointestinal stromal tumors concomitant with ampullary adenocarcinoma: a case report with KIT and PDGFRA mutational analysis and miR-221/222 expression profile. *Pathol Res Pract* 2014; **210**: 392-396 [PMID: [24674454](#) DOI: [10.1016/j.prp.2014.01.019](#)]



- 77 **Koçer NE**, Kayaselçuk F, Calışkan K, Uluşan S. Synchronous GIST with osteoclast-like giant cells and a well-differentiated neuroendocrine tumor in Ampulla Vateri: coexistence of two extremely rare entities. *Pathol Res Pract* 2007; **203**: 667-670 [PMID: [17656040](#) DOI: [10.1016/j.prp.2007.04.012](#)]
- 78 **Al-Brahim N**, Radhi J, Gately J. Synchronous epithelioid stromal tumour and lipoma in the stomach. *Can J Gastroenterol* 2003; **17**: 374-375 [PMID: [12813603](#) DOI: [10.1155/2003/627090](#)]
- 79 **Cirillo F**. Neuroendocrine tumors and their association with rare tumors: observation of 4 cases. *Eur Rev Med Pharmacol Sci* 2010; **14**: 577-588 [PMID: [20707247](#)]
- 80 **Ding J**, Sun P, Cai XY, Fei SH, Wu J, Qi YK, Liu ZB, Yuan L, He YJ, Song H, Chen WX. Synchronous poorly-differentiated neuroendocrine carcinoma and gastrointestinal stromal tumor of the stomach: a case report with immunohistochemical and molecular genetic analyses of KIT and PDGFRA. *Int J Clin Exp Pathol* 2014; **7**: 9076-9080 [PMID: [25674291](#)]
- 81 **Samaras VD**, Foukas PG, Triantafyllou K, Leontara V, Tsapralis D, Tsompanidi EM, Machairas A, Panayiotides IG. Synchronous well differentiated neuroendocrine tumour and gastrointestinal stromal tumour of the stomach: a case report. *BMC Gastroenterol* 2011; **11**: 27 [PMID: [21435225](#) DOI: [10.1186/1471-230X-11-27](#)]
- 82 **Tan E**, Friedman M, Coppola D. Occurrence of Multiple Tumors in a Patient. *Cancer Control* 2015; **22**: 505-507 [PMID: [26678978](#) DOI: [10.1177/107327481502200417](#)]
- 83 **Buragas M**, Kidd M, Modlin IM, Cha C. Multiple gastrointestinal stromal tumors and synchronous ileal carcinoids. *Nat Clin Pract Oncol* 2005; **2**: 166-70; quiz 1 p following 170 [PMID: [16264910](#) DOI: [10.1038/ncponc0108](#)]
- 84 **Cho H**, Watanabe T, Aoyama T, Hayashi T, Yamada T, Ogata T, Yoshikawa T, Tsuburaya A, Sekiguchi H, Nakamura Y, Sakuma Y, Kameda Y, Miyagi Y. Small bud of probable gastrointestinal stromal tumor within a laparoscopically-resected gastric schwannoma. *Int J Clin Oncol* 2012; **17**: 294-298 [PMID: [21850386](#) DOI: [10.1007/s10147-011-0296-1](#)]
- 85 **Amoruso M**, Papagni V, Picciariello A, Pinto VL, D'Abbicco D, Margari A. Intestinal occlusion by stenotic neuroendocrine tumours of left colon and concomitant association with small bowel gastrointestinal stromal tumours: A case report. *Int J Surg Case Rep* 2018; **53**: 182-185 [PMID: [30408742](#) DOI: [10.1016/j.ijscr.2018.10.034](#)]
- 86 **Pata F**, Sengodan M, Tang CB, Kadirkamanathan SS, Harvey M, Zaitoun A, Petkar M, Rotundo A. Concomitant jejunal sarcomatoid carcinoma and gastric GIST in patient with polymyalgia rheumatica: A case report. *Int J Surg Case Rep* 2013; **4**: 449-452 [PMID: [23548706](#) DOI: [10.1016/j.ijscr.2013.02.007](#)]
- 87 **Dasanu CA**, Mesologites T, Trikudanathan G. Synchronous tumors: adenosquamous carcinoma of pancreas and GIST of stomach. *J Gastrointest Cancer* 2011; **42**: 186-189 [PMID: [20623381](#) DOI: [10.1007/s12029-010-9187-3](#)]
- 88 **He JJ**, Ding KF, Zheng L, Xu JH, Li J, Wu YL, Sun LF, Zhou DE, Zheng S. Adenosquamous carcinoma of the uncinate process of the pancreas with synchronous gastrointestinal stromal tumor of the stomach: Case report and review of the literature. *Oncol Lett* 2012; **4**: 1191-1194 [PMID: [23197997](#) DOI: [10.3892/ol.2012.902](#)]
- 89 **Fiore M**, de Stefano G, Coppola N, Giorgio A. Synchronous and metachronous gastric gist with pancreatic adenocarcinoma: report of 2 cases and a review of literature. *Gastroenterol Hepatol Bed Bench* 2015; **8**: 298-301 [PMID: [26468351](#)]
- 90 **Shen ZL**, Wang S, Ye YJ, Wang YL, Sun KK, Yang XD, Jiang KW. Carcinosarcoma of pancreas with liver metastasis combined with gastrointestinal stromal tumour of the stomach: is there a good prognosis with the complete resection? *Eur J Cancer Care (Engl)* 2010; **19**: 118-123 [PMID: [19486125](#) DOI: [10.1111/j.1365-2354.2008.00977.x](#)]
- 91 **Arabadzhieva E**, Yonkov A, Bonev S, Bulanov D, Taneva I, Vlahova A, Dikov T, Dimitrova V. A rare case with synchronous gastric gastrointestinal stromal tumor, pancreatic neuroendocrine tumor, and uterine leiomyoma. *World J Surg Oncol* 2016; **14**: 287 [PMID: [27846844](#) DOI: [10.1186/s12957-016-1051-x](#)]
- 92 **Tavares AB**, Viveiros FA, Cidade CN, Maciel J. Gastric GIST with synchronous neuroendocrine tumour of the pancreas in a patient without neurofibromatosis type 1. *BMJ Case Rep* 2012; **2012** [PMID: [22675144](#) DOI: [10.1136/bcr.2012.5895](#)]
- 93 **Ueda K**, Hijioka M, Lee L, Igarashi H, Niina Y, Osoegawa T, Nakamura K, Takahashi S, Aishima S, Ohtsuka T, Takayanagi R, Ito T. A synchronous pancreatic neuroendocrine tumor and duodenal gastrointestinal stromal tumor. *Intern Med* 2014; **53**: 2483-2488 [PMID: [25366007](#)]
- 94 **Alabraba E**, Bramhall S, O'Sullivan B, Mahon B, Taniere P. Pancreatic insulinoma co-existing with gastric GIST in the absence of neurofibromatosis-1. *World J Surg Oncol* 2009; **7**: 18 [PMID: [19216788](#) DOI: [10.1186/1477-7819-7-18](#)]
- 95 **Haugvik SP**, Rosok BI, Edwin B, Gladhaug IP, Mathisen Ø. Concomitant Nonfunctional Pancreatic Neuroendocrine Tumor and Gastric GIST in a Patient Without Neurofibromatosis Type 1. *J Gastrointest Cancer* 2012; **43** Suppl 1: S171-S174 [PMID: [22083533](#) DOI: [10.1007/s12029-011-9344-3](#)]
- 96 **Felekouras E**, Athanasios P, Vgenopoulou S, Papaconstantinou I, Prassas E, Giannopoulos A, Griniatsos J. Coexistence of hepatocellular carcinoma (HCC) and c-Kit negative gastrointestinal stromal tumor (GIST): a case report. *South Med J* 2008; **101**: 948-951 [PMID: [18708986](#) DOI: [10.1097/SMJ.0b013e31817f027b](#)]
- 97 **Ferreira E Mora H**, Pinto de Sousa J, Devesa V, Barbosa J, Costa J, Portugal R, Costa Maia J. Gastrointestinal stromal tumor of the stomach and hepatocellular carcinoma: An unusual association. *Int J Surg Case Rep* 2015; **12**: 75-77 [PMID: [26026880](#) DOI: [10.1016/j.ijscr.2015.05.020](#)]
- 98 **Yamashita K**, Baba Y, Kurashige J, Iwatsuki M, Imai K, Hashimoto D, Sakamoto Y, Chikamoto A, Yoshida N, Beppu T, Baba H. Co-occurrence of liver metastasis of gastrointestinal stromal tumor and hepatocellular carcinoma: a case report. *Surg Case Rep* 2016; **2**: 86 [PMID: [27586263](#) DOI: [10.1186/s40792-016-0212-z](#)]
- 99 **Jaworski R**, Jastrzebski T, Swierblewski M, Drucis K, Kobierska-Gulida G. Coexistence of hepatocellular carcinoma and gastrointestinal stromal tumor: a case report. *World J Gastroenterol* 2006; **12**: 665-667 [PMID: [16489690](#)]
- 100 **Mrzljak A**, Košuta I, Škrtić A, Kardum-Skelin I, Vrhovac R. Metachronous gastrointestinal stromal tumor and acute leukemia after liver transplantation for cholangiocellular carcinoma: is there a link? *Case Rep Oncol* 2013; **6**: 163-168 [PMID: [23626555](#) DOI: [10.1159/000348817](#)]
- 101 **Nam SJ**, Choi HS, Kim ES, Keum B, Jeon YT, Chun HJ. Synchronous occurrence of gastrointestinal stromal tumor and intrahepatic cholangiocarcinoma: A case report. *Oncol Lett* 2015; **9**: 165-168 [PMID: [25435952](#) DOI: [10.3892/ol.2014.2703](#)]
- 102 **Paiva CE**, Moraes Neto FA, Agaimy A, Custodio Domingues MA, Rogatto SR. Perivascular epithelioid



- cell tumor of the liver coexisting with a gastrointestinal stromal tumor. *World J Gastroenterol* 2008; **14**: 800-802 [PMID: [18205275](#)]
- 103 **Gundes E**, Kucukkartallar T, Colak MH, Kartal A, Esen HH. Gastrointestinal stromal tumor in the stomach co-existent with renal cell carcinoma. *Erciyes Tip Dergisi* 2014; **36**: 47-50
  - 104 **Torous VF**, Su A, Lu DY, Dry SM. Adult Patient with Synchronous Gastrointestinal Stromal Tumor and Xp11 Translocation-Associated Renal Cell Carcinoma: A Unique Case Presentation with Discussion and Review of Literature. *Case Rep Urol* 2015; **2015**: 814809 [PMID: [26246933](#) DOI: [10.1155/2015/814809](#)]
  - 105 **Jiang Q**, Zhang Y, Zhou YH, Hou YY, Wang JY, Li JL, Li M, Tong HX, Lu WQ. A novel germline mutation in SDHA identified in a rare case of gastrointestinal stromal tumor complicated with renal cell carcinoma. *Int J Clin Exp Pathol* 2015; **8**: 12188-12197 [PMID: [26722403](#)]
  - 106 **Comandini D**, Damiani A, Pastorino A. Synchronous GISTs associated with multiple sporadic tumors: a case report. *Drugs Context* 2017; **6**: 212307 [PMID: [29167690](#) DOI: [10.7573/dic.212307](#)]
  - 107 **Rebegea LF**, Pătrașcu A, Miron D, Dumitru ME, Firescu D. Metachronous gastrointestinal stromal tumor associated with other neoplasia - case presentation. *Rom J Morphol Embryol* 2016; **57**: 1429-1435 [PMID: [28174815](#)]
  - 108 **Favero G**, Pfiffer T, Riedlinger WF, Chiantera V, Schneider A. Uncommon synchronous association between ovarian carcinoma and gastrointestinal stromal tumor: a case study and literature review. *Tumori* 2013; **99**: e70-e72 [PMID: [23748833](#) DOI: [10.1700/1283.14211](#)]
  - 109 **Li W**, Wu X, Wang N, Yin D, Zhang SL. Gastrointestinal stromal tumor with synchronous isolated parenchymal splenic metastasis of ovarian cancer. *Chin Med J (Engl)* 2011; **124**: 4372-4375 [PMID: [22340419](#)]
  - 110 **Damiani GR**, Coco L, Monfreda L, Gaetani M, Barnaba M, Germinario S, Loverro G. A rare case of coexistence of ovarian cancer and gastrointestinal stromal tumor. *Giornale Italiano di Ostetricia e Ginecologia* 2011; **33**: 255-258
  - 111 **Sharma M BK**, Barad AK, Padu K, Singh K S, Singh Th SC. Spontaneous Perforation as a First Presentation of Ileal Gastrointestinal Stromal Tumour (GIST) with Synchronous Breast Sarcoma. *J Clin Diagn Res* 2014; **8**: ND07-ND09 [PMID: [24995213](#) DOI: [10.7860/JCDR/2014/7219.4401](#)]
  - 112 **Joo YB**, Choi SH, Kim SK, Shim B, Kim MS, Kim YJ. Synchronous development of KIT positive acute myeloid leukemia in a patient with gastrointestinal stromal tumor. *Korean J Hematol* 2010; **45**: 66-69 [PMID: [21120166](#) DOI: [10.5045/kjh.2010.45.1.66](#)]
  - 113 **Gao NA**, Guo NJ, Yu WZ, Wang XX, Sun JR, Yu N, Liu RT, Liu XD, Liu ZY, Feng R. Synchronous occurrence of gastrointestinal stromal tumor and acute myeloid leukemia: A case report and review of the literature. *Oncol Lett* 2016; **11**: 2977-2980 [PMID: [27123049](#) DOI: [10.3892/ol.2016.4353](#)]
  - 114 **Sonmez M**, Arslan M, Cobanoglu U, Kavgaci H, Ozbas HM, Aydin F, Ovali E, Omay SB. Association of gastrointestinal stromal tumor and acute myeloid leukemia preceded by myelodysplastic syndrome with refractory anemia. *Tumori* 2009; **95**: 240-242 [PMID: [19579873](#)]
  - 115 **Herbers AH**, Keuning JJ. Staging for CLL-type non-Hodgkin's lymphoma reveals a gastrointestinal stromal tumour. *Neth J Med* 2005; **63**: 74-75 [PMID: [15766012](#)]
  - 116 **Pamukçuoğlu M**, Budakoğlu B, Han O, Tad M, Oksüzöğlu B, Abali H, Zengin N. An extraordinary case in whom gastrointestinal stromal tumor and low-grade malignant lymphoma are seen together in the stomach. *Med Oncol* 2007; **24**: 351-353 [PMID: [17873313](#)]
  - 117 **Ludmir EB**, Gutschenritter T, Pinnix CC, Gunther JR, Nastoupil LJ, Khoury JD, Medeiros LJ, Dabaja BS, Milgrom SA. Coincident primary breast lymphoma and gastrointestinal stromal tumor: case series and molecular mechanisms. *Onco Targets Ther* 2018; **11**: 8937-8942 [PMID: [30573980](#) DOI: [10.2147/OTT.S159843](#)]
  - 118 **Takahashi T**, Maruyama Y, Saitoh M, Itoh H, Yoshimoto M, Tsujisaki M, Nakayama M. Synchronous Occurrence of Diffuse Large B-cell Lymphoma of the Duodenum and Gastrointestinal Stromal Tumor of the Ileum in a Patient with Immune Thrombocytopenic Purpura. *Intern Med* 2016; **55**: 2951-2956 [PMID: [27746431](#) DOI: [10.2169/internalmedicine.55.6712](#)]
  - 119 **Au WY**, Wong WM, Khoo US, Liang R. Challenging and unusual cases: Case 2. Concurrent gastrointestinal stromal tumor and Burkitt's lymphoma. *J Clin Oncol* 2003; **21**: 1417-1418 [PMID: [12663737](#) DOI: [10.1200/jco.2003.05.181](#)]
  - 120 **Rahimi K**, Gologan A, Haliotis T, Lamoureux E, Chetty R. Gastrointestinal stromal tumor with autonomic nerve differentiation and coexistent mantle cell lymphoma involving the appendix. *Int J Clin Exp Pathol* 2008; **2**: 608-613 [PMID: [19636397](#)]
  - 121 **Salar A**, Ramón JM, Barranco C, Nieto M, Prats M, Serrano S, Besses C. Double diagnosis in cancer patients and cutaneous reaction related to gemcitabine: CASE 1. Synchronous mucosa-associated lymphoid tissue lymphoma and gastrointestinal stromal tumors of the stomach. *J Clin Oncol* 2005; **23**: 7221-7223 [PMID: [16192606](#) DOI: [10.1200/jco.2005.08.158](#)]
  - 122 **Tzilveris D**, Gatopoulou A, Zervas K, Katodritou E, Patakiouta F, Tarpagos A, Katsos I. Development of multiple myeloma in a patient with gastrointestinal stromal tumor treated with imatinib mesylate: a case report. *World J Gastroenterol* 2007; **13**: 2011-2013 [PMID: [17461509](#)]
  - 123 **Nagai K**, Matsumura Y, Nomura J, Inui M, Tagawa T. A case of double cancer involving oral malignant melanoma and gastrointestinal stromal tumor (GIST). *Int J Oral Maxillofac Surg* 2005; **34**: 328-330 [PMID: [15741044](#) DOI: [10.1016/j.ijom.2004.06.008](#)]
  - 124 **Arnogiannaki N**, Martzoukou I, Kountourakis P, Dimitriadis E, Papathanasaki A, Nastoulis E, Gazalidou M, Fida A, Apostolikas N, Agnantis NJ. Synchronous presentation of GISTs and other primary neoplasms: a single center experience. *In Vivo* 2010; **24**: 109-115 [PMID: [20133985](#)]
  - 125 **Miyoshi T**, Mori R, Amano S, Sumitomo H, Aoyama M, Inoue S, Hino N, Wada D. Efficacy of erlotinib and imatinib in a patient with a rectal gastrointestinal stromal tumor and synchronous pulmonary adenocarcinoma: A case report. *J Med Invest* 2016; **63**: 144-148 [PMID: [27040071](#) DOI: [10.2152/jmi.63.144](#)]
  - 126 **Jiang MJ**, Weng SS, Cao Y, Li XF, Wang LH, Xu JH, Yuan Y. Metachronous Primary Adenocarcinoma of Lung During Adjuvant Imatinib Mesylate Therapy for Gastrointestinal Stromal Tumor of Stomach: A Case Report. *Medicine (Baltimore)* 2015; **94**: e1484 [PMID: [26356712](#) DOI: [10.1097/MD.0000000000001484](#)]
  - 127 **Wada Y**, Koizumi T, Yokoyama T, Urushihata K, Yamamoto H, Hanaoka M, Kubo K. Synchronous gastrointestinal stromal tumor and primary lung adenocarcinoma. *Intern Med* 2012; **51**: 2407-2410 [PMID: [22975558](#) DOI: [10.2169/internalmedicine.51.7888](#)]
  - 128 **Brummel N**, Awad Z, Frazier S, Liu J, Rangnekar N. Perforation of metastatic melanoma to the small bowel with simultaneous gastrointestinal stromal tumor. *World J Gastroenterol* 2005; **11**: 2687-2689

- [PMID: 15849837]
- 129 **Su YY**, Chiang NJ, Wu CC, Chen LT. Primary gastrointestinal stromal tumor of the liver in an anorectal melanoma survivor: A case report. *Oncol Lett* 2015; **10**: 2366-2370 [PMID: 26622853 DOI: 10.3892/ol.2015.3561]
  - 130 **Inayat F**, Saif MW. New Drug and Possible New Toxicity - Squamous Cell Carcinoma Following Imatinib in Patients with Gastrointestinal Stromal Tumors. *Anticancer Res* 2016; **36**: 6201-6204 [PMID: 27793952 DOI: 10.21873/anticancer.11214]
  - 131 **Wollina U**, Hansel G, Zimmermann F, Schönlebe J, Nowak A. Merkel cell carcinoma of the lower leg with retroperitoneal GIST: a very rare association. *Wien Klin Wochenschr* 2015; **127**: 402-405 [PMID: 25943418 DOI: 10.1007/s00508-014-0660-z]
  - 132 **McCarthy CJ**, O'Brien GC, Cummins RJ, Kay EW, Broe PJ. GIST with a twist--upregulation of PDGF-B resulting in metachronous gastrointestinal stromal tumor and dermatofibrosarcoma protuberans. *J Gastrointest Surg* 2010; **14**: 398-403 [PMID: 19936851 DOI: 10.1007/s11605-009-1088-z]
  - 133 **Kondo S**, Yamaguchi U, Sakurai S, Ikezawa Y, Chuman H, Tateishi U, Furuta K, Hasegawa T. Cytogenetic confirmation of a gastrointestinal stromal tumor and ewing sarcoma/primitive neuroectodermal tumor in a single patient. *Jpn J Clin Oncol* 2005; **35**: 753-756 [PMID: 16332719 DOI: 10.1093/jjco/hyi197]
  - 134 **Kovecsi A**, Jung I, Bara T, Bara T, Azamfirei L, Kovacs Z, Gurzu S. First Case Report of a Sporadic Adrenocortical Carcinoma With Gastric Metastasis and a Synchronous Gastrointestinal Stromal Tumor of the Stomach. *Medicine (Baltimore)* 2015; **94**: e1549 [PMID: 26376405 DOI: 10.1097/MD.0000000000001549]
  - 135 **de la Torre J**, Banerjee S, Baumgartner J, Lin GY, Burgoyne AM, Kirane A, Sicklick J. Tumor Symbiosis: Gastrointestinal Stromal Tumor as a Host for Primary Peritoneal Mesothelioma. *J Gastrointest Surg* 2019; **23**: 879-881 [PMID: 30132292 DOI: 10.1007/s11605-018-3918-3]
  - 136 **Lee CK**, Hadley A, Desilva K, Smith G, Goldstein D. When is a GIST not a GIST? A case report of synchronous metastatic gastrointestinal stromal tumor and fibromatosis. *World J Surg Oncol* 2009; **7**: 8 [PMID: 19159438 DOI: 10.1186/1477-7819-7-8]
  - 137 **Adim SB**, Filiz G, Kanat O, Yerci O. Simultaneous occurrence of synchronous and metachronous tumors with gastrointestinal stromal tumors. *Bratisl Lek Listy* 2011; **112**: 623-625 [PMID: 22180988]
  - 138 **Aghdassi A**, Christoph A, Dombrowski F, Döring P, Barth C, Christoph J, Lerch MM, Simon P. Gastrointestinal Stromal Tumors: Clinical Symptoms, Location, Metastasis Formation, and Associated Malignancies in a Single Center Retrospective Study. *Dig Dis* 2018; **36**: 337-345 [PMID: 29870973 DOI: 10.1159/000489556]
  - 139 **Amaadour L**, Oualla K, Benbrahim Z, Najib R, Benhammane H, Chad A, Arifi S, Mellas N, El Mesbahi O. Synchronous gastrointestinal stromal tumors and other primary cancers: Case series of a single institution experience. *Ann Oncol* 2013; **4**: iv73
  - 140 **Fernández JA**, Olivares V, Gómez-Ruiz AJ, Ferri B, Frutos MD, Soria T, Torres G, Parrilla P. Additional malignancies in patients with gastrointestinal stromal tumors (GIST): incidence, pathology and prognosis according to a time of occurrence-based classification. *Clin Transl Oncol* 2019; **21**: 646-655 [PMID: 30368726 DOI: 10.1007/s12094-018-1966-5]
  - 141 **Ferreira SS**, Werutsky G, Toneto MG, Alves JM, Piantá CD, Breunig RC, Brondani da Rocha A, Grivicich I, Garicochea B. Synchronous gastrointestinal stromal tumors (GIST) and other primary cancers: case series of a single institution experience. *Int J Surg* 2010; **8**: 314-317 [PMID: 20380900 DOI: 10.1016/j.ijsu.2010.03.008]
  - 142 **Giuliani J**, Marzola M, Indelli M, Aliberti C, Sartori S, Lanza G, Lelli G, Frassoldati A. Gastrointestinal stromal tumors and other malignancies: a case series. *J Gastrointest Cancer* 2012; **43**: 634-637 [PMID: 22350927 DOI: 10.1007/s12029-012-9371-8]
  - 143 **Gonçalves R**, Linhares E, Albagli R, Valadão M, Vilhena B, Romano S, Ferreira CG. Occurrence of other tumors in patients with GIST. *Surg Oncol* 2010; **19**: e140-e143 [PMID: 20675121 DOI: 10.1016/j.suronc.2010.06.004]
  - 144 **Hechtman JF**, DeMatteo R, Nafa K, Chi P, Arcila ME, Dogan S, Oultache A, Chen W, Hameed M. Additional Primary Malignancies in Patients with Gastrointestinal Stromal Tumor (GIST): A Clinicopathologic Study of 260 Patients with Molecular Analysis and Review of the Literature. *Ann Surg Oncol* 2015; **22**: 2633-2639 [PMID: 25564173 DOI: 10.1245/s10434-014-4332-z]
  - 145 **Lai BR**, Wu YT, Kuo YC, Hsu HC, Chen JS, Chen TC, Wu RC, Chiu CT, Yeh CN, Yeh TS. Targeted ultra-deep sequencing unveils a lack of driver-gene mutations linking non-hereditary gastrointestinal stromal tumors and highly prevalent second primary malignancies: random or nonrandom, that is the question. *Oncotarget* 2016; **7**: 83270-83277 [PMID: 27806309 DOI: 10.18632/oncotarget.12452]
  - 146 **Liszka L**, Zielińska-Pajak E, Pajak J, Golka D, Huszno J. Coexistence of gastrointestinal stromal tumors with other neoplasms. *J Gastroenterol* 2007; **42**: 641-649 [PMID: 17701127 DOI: 10.1007/s00535-007-2082-4]
  - 147 **Pandurengan RK**, Dumont AG, Araujo DM, Ludwig JA, Ravi V, Patel S, Garber J, Benjamin RS, Strom SS, Trent JC. Survival of patients with multiple primary malignancies: a study of 783 patients with gastrointestinal stromal tumor. *Ann Oncol* 2010; **21**: 2107-2111 [PMID: 20348145 DOI: 10.1093/annonc/mdq078]
  - 148 **Ponti G**, Luppi G, Martorana D, Rossi G, Losi L, Bertolini F, Sartori G, Pellacani G, Seidenari S, Boni E, Neri TM, Silini E, Tamburini E, Maiorana A, Conte PF. Gastrointestinal stromal tumor and other primary metachronous or synchronous neoplasms as a suspicion criterion for syndromic setting. *Oncol Rep* 2010; **23**: 437-444 [PMID: 20043105]
  - 149 **Richter KK**, Schmid C, Thompson-Fawcett M, Settmacher U, Altendorf-Hofmann A. Long-term follow-up in 54 surgically treated patients with gastrointestinal stromal tumours. *Langenbecks Arch Surg* 2008; **393**: 949-955 [PMID: 18338179 DOI: 10.1007/s00423-008-0318-2]
  - 150 **Rodriguez MG**, Rossi S, Ricci R, Martini M, Larocca M, Dipasquale A, Quirino M, Schinzari G, Basso M, D'Argento E, Strippoli A, Barone C, Cassano A. Gastrointestinal stromal tumors (GISTs) and second malignancies: A novel "sentinel tumor"? A monoinstitutional, STROBE-compliant observational analysis. *Medicine (Baltimore)* 2016; **95**: e4718 [PMID: 27661019 DOI: 10.1097/MD.0000000000004718]
  - 151 **Rubió-Casadevall J**, Borràs JL, Carmona-García MC, Ameijide A, Gonzalez-Vidal A, Ortiz MR, Bosch R, Riu F, Parada D, Martí E, Miró J, Sirvent JJ, Galceran J, Marcos-Gragera R. Correlation between mutational status and survival and second cancer risk assessment in patients with gastrointestinal stromal tumors: a population-based study. *World J Surg Oncol* 2015; **13**: 47 [PMID: 25885906 DOI: 10.1186/s12957-015-0474-0]

- 152 **Sevinc A**, Seker M, Bilici A, Ozdemir NY, Yildiz R, Ustaalioglu BO, Kalender ME, Dane F, Karaca H, Gemici C, Gumus M, Buyukberber S. Co-existence of gastrointestinal stromal tumors with other primary neoplasms. *Hepatogastroenterology* 2011; **58**: 824-830 [PMID: [21830398](#)]
- 153 **Vassos N**, Agaimy A, Hohenberger W, Croner RS. Coexistence of gastrointestinal stromal tumours (GIST) and malignant neoplasms of different origin: prognostic implications. *Int J Surg* 2014; **12**: 371-377 [PMID: [24632413](#) DOI: [10.1016/j.ijssu.2014.03.004](#)]



Published By Baishideng Publishing Group Inc  
7041 Koll Center Parkway, Suite 160, Pleasanton, CA 94566, USA  
Telephone: +1-925-2238242  
Fax: +1-925-2238243  
E-mail: [bpgoffice@wjgnet.com](mailto:bpgoffice@wjgnet.com)  
Help Desk: <http://www.f6publishing.com/helpdesk>  
<http://www.wjgnet.com>

