


World Journal of *Gastroenterology*

World J Gastroenterol 2019 July 14; 25(26): 3283-3467



**OPINION REVIEW**

- 3283** Diuretic window hypothesis in cirrhosis: Changing the point of view
Brito-Azevedo A
- 3291** Fluoroquinolones for the treatment of latent *Mycobacterium tuberculosis* infection in liver transplantation
Silva JT, San-Juan R, Fernández-Ruiz M, Aguado JM

REVIEW

- 3299** Reactivation of hepatitis B virus infection in patients with hemo-lymphoproliferative diseases, and its prevention
Sagnelli C, Pisaturo M, Calò F, Martini S, Sagnelli E, Coppola N
- 3313** Current status of endoscopic retrograde cholangiopancreatography in patients with surgically altered anatomy
Krutsri C, Kida M, Yamauchi H, Iwai T, Imaizumi H, Koizumi W

MINIREVIEWS

- 3334** Choledochal cysts: Similarities and differences between Asian and Western countries
Baison GN, Bonds MM, Helton WS, Kozarek RA
- 3344** Gastro-duodenal disease in Africa: Literature review and clinical data from Accra, Ghana
Archampong TN, Asmah RH, Richards CJ, Martin VJ, Bayliss CD, Botão E, David L, Beleza S, Carrilho C
- 3359** Screening of aptamers and their potential application in targeted diagnosis and therapy of liver cancer
Zhang GQ, Zhong LP, Yang N, Zhao YX

ORIGINAL ARTICLE**Basic Study**

- 3370** Drug-eluting fully covered self-expanding metal stent for dissolution of bile duct stones *in vitro*
Huang C, Cai XB, Guo LL, Qi XS, Gao Q, Wan XJ
- 3380** Raddeanin A promotes apoptosis and ameliorates 5-fluorouracil resistance in cholangiocarcinoma cells
Guo SS, Wang Y, Fan QX
- 3392** Identification of differentially expressed genes regulated by methylation in colon cancer based on bioinformatics analysis
Liang Y, Zhang C, Dai DQ

Retrospective Study

- 3408** Histologic features and genomic alterations of primary colorectal adenocarcinoma predict growth patterns of liver metastasis
Wu JB, Sarmiento AL, Fiset PO, Lazaris A, Metrakos P, Petrillo S, Gao ZH

Observational Study

- 3426** International normalized ratio and Model for End-stage Liver Disease score predict short-term outcome in cirrhotic patients after the resolution of hepatic encephalopathy
Hu XP, Gao J

SYSTEMATIC REVIEWS

- 3438** Synchronous resection of esophageal cancer and other organ malignancies: A systematic review
Papaconstantinou D, Tsilimigras DI, Moris D, Michalinos A, Mastoraki A, Mpali E, Hasemaki N, Bakopoulos A, Filippou D, Schizas D

META-ANALYSIS

- 3450** Genetic testing *vs* microforceps biopsy in pancreatic cysts: Systematic review and meta-analysis
Faias S, Pereira L, Luís Á, Chaves P, Cravo M

ABOUT COVER

Editorial board member of *World Journal of Gastroenterology*, Andrew Stewart Day, MD, Professor, Paediatrics Department, University of Otago, Christchurch 8041, New Zealand

AIMS AND SCOPE

World Journal of Gastroenterology (*World J Gastroenterol*, *WJG*, print ISSN 1007-9327, online ISSN 2219-2840, DOI: 10.3748) is a peer-reviewed open access journal. The *WJG* Editorial Board consists of 701 experts in gastroenterology and hepatology from 58 countries.

The primary task of *WJG* is to rapidly publish high-quality original articles, reviews, and commentaries in the fields of gastroenterology, hepatology, gastrointestinal endoscopy, gastrointestinal surgery, hepatobiliary surgery, gastrointestinal oncology, gastrointestinal radiation oncology, etc. The *WJG* is dedicated to become an influential and prestigious journal in gastroenterology and hepatology, to promote the development of above disciplines, and to improve the diagnostic and therapeutic skill and expertise of clinicians.

INDEXING/ABSTRACTING

The *WJG* is now indexed in Current Contents®/Clinical Medicine, Science Citation Index Expanded (also known as SciSearch®), Journal Citation Reports®, Index Medicus, MEDLINE, PubMed, PubMed Central, and Scopus. The 2019 edition of Journal Citation Report® cites the 2018 impact factor for *WJG* as 3.411 (5-year impact factor: 3.579), ranking *WJG* as 35th among 84 journals in gastroenterology and hepatology (quartile in category Q2). CiteScore (2018): 3.43.

RESPONSIBLE EDITORS FOR THIS ISSUE

Responsible Electronic Editor: Yan-Liang Zhang

Proofing Production Department Director: Yun-Xiaojian Wu

NAME OF JOURNAL

World Journal of Gastroenterology

ISSN

ISSN 1007-9327 (print) ISSN 2219-2840 (online)

LAUNCH DATE

October 1, 1995

FREQUENCY

Weekly

EDITORS-IN-CHIEF

Subrata Ghosh, Andrzej S. Tarnawski

EDITORIAL BOARD MEMBERS

<http://www.wjgnet.com/1007-9327/editorialboard.htm>

EDITORIAL OFFICE

Ze-Mao Gong, Director

PUBLICATION DATE

July 14, 2019

COPYRIGHT

© 2019 Baishideng Publishing Group Inc

INSTRUCTIONS TO AUTHORS

<https://www.wjgnet.com/bpg/gerinfo/204>

GUIDELINES FOR ETHICS DOCUMENTS

<https://www.wjgnet.com/bpg/GerInfo/287>

GUIDELINES FOR NON-NATIVE SPEAKERS OF ENGLISH

<https://www.wjgnet.com/bpg/gerinfo/240>

PUBLICATION MISCONDUCT

<https://www.wjgnet.com/bpg/gerinfo/208>

ARTICLE PROCESSING CHARGE

<https://www.wjgnet.com/bpg/gerinfo/242>

STEPS FOR SUBMITTING MANUSCRIPTS

<https://www.wjgnet.com/bpg/GerInfo/239>

ONLINE SUBMISSION

<https://www.f6publishing.com>



Basic Study

Drug-eluting fully covered self-expanding metal stent for dissolution of bile duct stones *in vitro*

Chao Huang, Xiao-Bo Cai, Li-Li Guo, Xiao-Sheng Qi, Qiang Gao, Xin-Jian Wan

ORCID number: Chao Huang (0000-0003-0926-8276); Xiao-Bo Cai (0000-0003-4217-3383); Li-Li Guo (0000-0003-2424-9006); Xiao-Sheng Qi (0000-0002-4545-6656); Qiang Gao (0000-0002-5885-1532); Xin-Jian Wan (0000-0002-8750-4708).

Author contributions: Huang C designed and mainly carried out all the experiments; Qi XS, Guo LL, and Gao Q assisted in carrying out the experiments; Wan XJ supervised the study; Huang C wrote the paper; Wan XJ together with Cai XB revised the article.

Supported by the National Natural Science Foundation of China, No. 81470904; and Shanghai Committee of Science and Technology, No. 14411963000.

Institutional review board statement: This study was approved by the Ethics Committee of Shanghai General Hospital, Shanghai Jiaotong University School of Medicine.

Institutional animal care and use committee statement: All experimental procedures were approved by the Animal Care and Use Committee of Shanghai Jiaotong University School of Medicine.

Conflict-of-interest statement: All authors declare no conflicts of interest related to this article.

Data sharing statement: No additional data are available.

ARRIVE guidelines statement: The authors have read the ARRIVE guidelines, and the manuscript

Chao Huang, Xiao-Bo Cai, Li-Li Guo, Xin-Jian Wan, Department of Gastroenterology, Shanghai General Hospital, Shanghai Jiaotong University School of Medicine, Shanghai 201620, China

Chao Huang, Xiao-Bo Cai, Li-Li Guo, Xin-Jian Wan, Shanghai Key Laboratory for Pancreatic Diseases, Shanghai General Hospital, Shanghai Jiaotong University School of Medicine, Shanghai 201620, China

Xiao-Sheng Qi, Department of General Surgery, Shanghai General Hospital, Shanghai Jiaotong University School of Medicine, Shanghai 201620, China

Qiang Gao, State Key Laboratory for Modification of Chemical Fibers and Polymer Materials, College of Chemistry, Chemical Engineering and Biotechnology, Donghua University, Shanghai 201620, China

Corresponding author: Xin-Jian Wan, PhD, Chief Doctor, Department of Gastroenterology, Shanghai General Hospital, Shanghai Jiaotong University School of Medicine, No. 650, Xinsongjiang Road, Shanghai 201620, China. XinJian_Wan_shsy@163.com
Telephone: +86-21-6324-8460
Fax: +86-21-6324-8460

Abstract

BACKGROUND

The treatment of difficult common bile duct stones (CBDS) remains a big challenge around the world. Biliary stenting is a widely accepted rescue method in patients with failed stone extraction under endoscopic retrograde cholangiopancreatography. Fully covered self-expanding metal stent (FCSEMS) has gained increasing attention in the management of difficult CBDS.

AIM

To manufacture a drug-eluting FCSEMS, which can achieve controlled release of stone-dissolving agents and speed up the dissolution of CBDS.

METHODS

Customized covered nitinol stents were adopted. Sodium cholate (SC) and disodium ethylene diamine tetraacetic acid (EDTA disodium, EDTA for short) were used as stone-dissolving agents. Three different types of drug-eluting stents were manufactured by dip coating (Stent I), coaxial electrospinning (Stent II), and dip coating combined with electrospinning (Stent III), respectively. The drug-release behavior and stone-dissolving efficacy of these stents were evaluated *in vitro* to sort out the best manufacturing method. And the selected stone-dissolving stents were further put into porcine CBD to evaluate their biosecurity.

was prepared and revised according to the ARRIVE guidelines.

Open-Access: This article is an open-access article which was selected by an in-house editor and fully peer-reviewed by external reviewers. It is distributed in accordance with the Creative Commons Attribution Non Commercial (CC BY-NC 4.0) license, which permits others to distribute, remix, adapt, build upon this work non-commercially, and license their derivative works on different terms, provided the original work is properly cited and the use is non-commercial. See: <http://creativecommons.org/licenses/by-nc/4.0/>

Manuscript source: Unsolicited manuscript

Received: April 25, 2019

Peer-review started: April 25, 2019

First decision: May 16, 2019

Revised: May 26, 2019

Accepted: May 31, 2019

Article in press: June 1, 2019

Published online: July 14, 2019

P-Reviewer: Ali FEM, Sultan AM

S-Editor: Yan JP

L-Editor: Wang TQ

E-Editor: Zhang YL



RESULTS

Stent I and Stent II had obvious burst release of drugs in the first 5 d while Stent III presented controlled and sustainable drug release for 30 d. In still buffer, the final stone mass-loss rate of each group was $5.19\% \pm 0.69\%$ for naked FCSEMS, $20.37\% \pm 2.13\%$ for Stent I, $24.57\% \pm 1.45\%$ for Stent II, and $33.72\% \pm 0.67\%$ for Stent III. In flowing bile, the final stone mass-loss rate of each group was $5.87\% \pm 0.25\%$ for naked FCSEMS, $6.36\% \pm 0.48\%$ for Stent I, $6.38\% \pm 0.37\%$ for Stent II, and $8.15\% \pm 0.27\%$ for Stent III. Stent III caused the most stone mass-loss no matter in still buffer or in flowing bile, which was significantly higher than those of other groups ($P < 0.05$). *In vivo*, Stent III made no difference from naked FCSEMS in serological analysis ($P > 0.05$) and histopathological examination ($P > 0.05$).

CONCLUSION

The novel SC and EDTA-eluting FCSEMS is efficient in diminishing CBDS *in vitro*. When conventional endoscopic techniques fail to remove difficult CBDS, SC and EDTA-eluting FCSEMS implantation may be considered a promising alternative.

Key words: Common bile duct stone; Drug-eluting stent; Fully covered self-expanding metal stent; Electrospinning; Nanofiber film

©The Author(s) 2019. Published by Baishideng Publishing Group Inc. All rights reserved.

Core tip: The idea of delivering stone-dissolving agents to the location of common bile duct stones (CBDS) *via* biliary stent is first introduced by our research group. Based on our previous work and updated progress in the endoscopic field, we have further modified our previous version and present a brand-new stone-dissolving fully covered self-expanding metal stent, which is expected to serve as an alternative in the management of difficult CBDS.

Citation: Huang C, Cai XB, Guo LL, Qi XS, Gao Q, Wan XJ. Drug-eluting fully covered self-expanding metal stent for dissolution of bile duct stones *in vitro*. *World J Gastroenterol* 2019; 25(26): 3370-3379

URL: <https://www.wjgnet.com/1007-9327/full/v25/i26/3370.htm>

DOI: <https://dx.doi.org/10.3748/wjg.v25.i26.3370>

INTRODUCTION

Biliary stenting is a widely accepted rescue method in patients with failed stone extraction under endoscopic retrograde cholangiopancreatography (ERCP) and plastic biliary stents are commonly used around the world^[1,2]. It is worth noting that fully covered self-expanding metal stents (FCSEMS) have been used in the management of difficult common bile duct stones (CBDS) and have gained satisfactory clinical outcome^[3-7]. In the research of Garcia-Cano's group^[3], FCSEMS implantation was adopted after an ERCP session without complete CBDS extraction. Successful biliary drainage was obtained in all 29 cases. After a median of 199.5 d of follow-up, FCSEMS was removed in 16 patients with a complete CBDS extraction in 15 (93.7%) cases. Another research reported that after 6.4-wk FCSEMS insertion, stent patency rate was 100% (36/36) and success rate of first attempt to clear CBDS was 80.6% (29/36)^[4].

Both sodium cholate (SC) and disodium ethylene diamine tetraacetic acid (EDTA) have been found to be able to dissolve biliary stones^[8-11]. In our previous studies, we have developed a drug-eluting plastic stent (PS) by the method of dip coating, which is able to release EDTA and SC, and the novel stent has been proved to effectively dissolve CBDS *ex vivo* and in a live porcine CBDS model^[12,13]. But we also observed that the drug-loaded coating outside the PS might fall off during application, which could weaken the stone-dissolving effect of the stent. We have tried coaxial electrospinning, one method to produce drug-loaded nanofiber film, instead of dip coating to manufacture drug-loaded stent; however, burst release of drug became another issue and the stone-dissolving effect was barely satisfactory^[14].

Sustainable drug release and unobstructed bile drainage are desired in stone-dissolving stents. In this study, we aimed to modify our stone-dissolving stents. PS was replaced by FCSEMS since FCSEMS can provide more effective drainage and is becoming a promising alternative in the bridge therapy for difficult CBDS. And a new method of manufacturing drug-loaded stent was tested to overcome the problem of coating falling off and burst release of drug.

MATERIALS AND METHODS

Preparation of drug-eluting stents

Customized nitinol stents (Micro-Tech Co., Ltd., Nanjing, China), which are 2 cm long, 6 mm wide at the proximal end, 5 mm wide at the waist, and 4 mm wide at the distal end and covered with silicone membrane, were used in this study (Figure 1A). Polycaprolactone (PCL) was adopted as drug carrier and 100 mg SC and EDTA at a molar ratio of 1:1 were loaded on stents. Three different types of SC and EDTA-eluting stents were manufactured by dip coating, coaxial electrospinning, or dip coating combined with electrospinning, which were assigned as Stent I, Stent II, and Stent III, respectively (Figure 1A). Naked nitinol stent served as a control. By dip coating, naked nitinol stents were immersed in mixed solution of PCL and SC and EDTA, and air dried in fuming cupboard. Then, the above-mentioned steps were repeated for several times until the stents reached the expected drug-loading. The steps of coaxial electrospinning was the same as we described in our previous study^[14]. For dip coating combined with electrospinning, after dip coating, another super-thin layer of PCL was coated outside the drug-loaded stents by electrospinning. Every drug-eluting stent was weighed before and after they were coated. The mass of coating (mg) was calculated as mass of coated FCSEMS (mg) – mass of naked FCSEMS (mg), and the drug-loading efficiency (%) was calculated as drug loading/coating mass × 100%.

Drug release in vitro

Three kinds of drug-eluting stents loaded with 100 mg SC and EDTA and naked nitinol stents (stents without drugs) were immersed in 10 mL phosphate-buffered saline (PBS, 0.01 M, pH 7.4) in 15 mL tubes ($n = 6$ in each group). All the tubes were placed in a shaker incubator at an oscillator frequency of 60 rpm at 37 °C. After predetermined incubation time of 1, 2, 3, 4, 5, 10, 15, 20, 25, or 30 d, 1 mL of the buffer in each tube was collected and replaced with 1 mL of fresh PBS. The collected buffer was measured by high-performance liquid chromatography (HPLC) to figure out how much SC and EDTA were released into PBS. Cumulative drug release percentage (%) was calculated as actual drug release/drug loading capacity × 100%.

Dissolution of biliary stone in still buffer in vitro

CBDS were obtained from patients with choledocholithiasis who underwent choledocholithotomy at Shanghai General Hospital, and informed consent was obtained from all patients. The collected stones were rinsed with saline and then air-dried for one month. CBDS (mass in 100 mg) together with one of four FCSEMS were placed into 10 mL PBS in 15 mL tubes ($n = 6$ in each group) and the PBS in each tube was changed daily. All the tubes were also placed in a shaker incubator at an oscillator frequency of 60 rpm at 37 °C. Stone-dissolving efficacy of drug-eluting stents was assessed by calculating mass loss ratio of stones at predetermined incubation time of 1, 2, 3, 4, 5, 10, 15, 20, 25, or 30 d. The stones were dried in a homeothermal dryer at 60 °C for 24 h before they were weighed. Weight loss ratio (%) was calculated as [(original weight – residual weight)/original weight] × 100%.

Dissolution of biliary stone in flowing bile in vitro

In order to mimic the biological environment in the CBD with bile flow, we collected some computed tomography and MRCP images of patients with CBDS and made an *in vitro* human-scale simulated CBD as bile perfusion model with the help of 3D-printing (Figure 1B). Human bile was obtained from patients who underwent endoscopic nasobiliary drainage. One stent and one CBDS (mass in 100 mg) were put into the CBD model together and a total of 1000 mL of human bile was perfused into each CBD model every day (Figure 1C, $n = 6$ in each group). After 5, 10, 15, 20, 25, or 30 d of bile perfusion, mass loss ratio of stones in each group was calculated as described above.

Biosecurity of SC/EDTA-eluting FCSEMS in vivo

All experimental procedures were approved by the Animal Care and Use Committee of Shanghai Jiaotong University School of Medicine. A total of 10 male miniature pigs

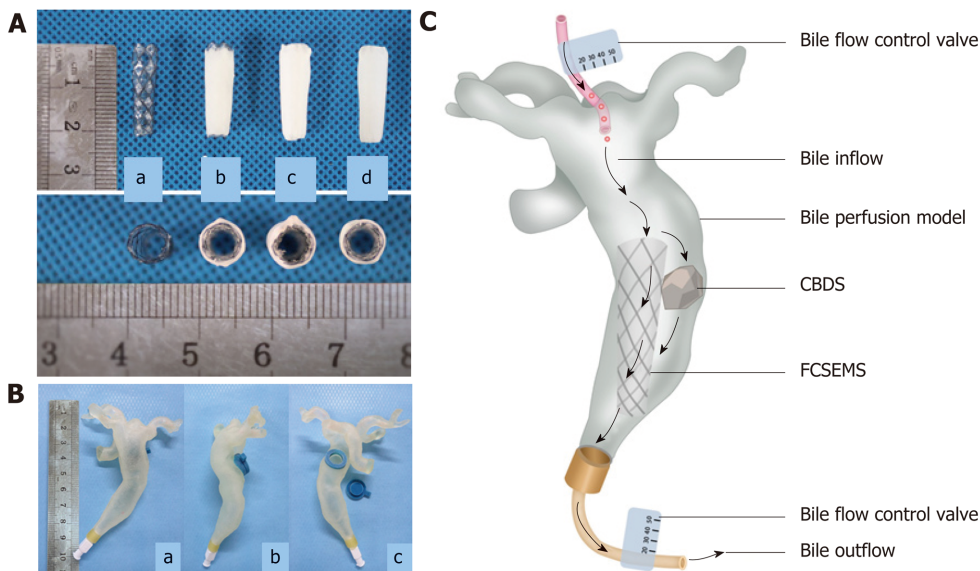


Figure 1 Pictures of stents and common bile duct model. A: Picture of covered nitinol stent and drug-eluting stents manufactured by dip coating, coaxial electrospinning, and dip coating combined with electrospinning (a: Covered nitinol stent without drug load; b: Drug-eluting stent manufactured by dip coating; c: Drug-eluting stent manufactured by coaxial electrospinning; d: Drug-eluting stent manufactured by dip coating combined with electrospinning); B: *In vitro* common bile duct (CBD) model manufactured by 3D printing technology (a: Front view; b: Lateral view; c: Back view, one stent and one stone can be put inside the model through the hole on the back); C: Picture illustrating dissolution of biliary stone in flowing bile in bile perfusion model. One stent and one CBD stone (mass in 100 mg) were put into the CBD model together and a total of 1000 mL human bile was perfused into each CBD model every day, that is, 1000 mL human bile will flow through the stent and stone every day. In this way, we get to know whether our stent can exert the stone-dissolving effect in flowing bile. CBD: Common bile duct; CBDS: Common bile duct stone.

aged 1-2 years and weighing 15-20 kg were included in the study and randomly assigned to two groups ($n = 5$ each). The animals were acclimatized to laboratory conditions (23 °C, 12 h/12 h light/dark, 50% humidity, *ad libitum* access to food and water) for 2 wk prior to experimentation. Naked FCSEMS and Stent III were involved in this part. The porcine CBD was partially ligated for one week *via* laparoscopy and one stent was put into the dilated porcine CBD above the papilla through open surgery (Figure 2). All the procedures were conducted under general anesthesia. Serum samples were collected before stent insertion, 15 and 30 d after stent insertion and tested. After 1-mo follow-up, all the animals were sacrificed. Specimens, including the gallbladder, CBD, duodenal wall, liver, and kidney were collected. Hematoxylin and eosin (HE) staining was conducted on all the specimens for histopathological examination. And two senior pathologists helped read the HE slides and grade the severity of inflammation on a scale from mild (+), moderate (++) to severe (+++), according to the numbers and range of infiltrated inflammatory cells.

Statistical analysis

Statistical analyses were performed using SAS 8e (SAS Institute, Cary, NC, United States). Data are presented as the mean \pm standard deviation (SD). Student's *t*-test was used to compare continuous quantitative data between two groups and difference among multiple groups was detected by analysis of variance (ANOVA). For ranked data, rank sum test was applied. $P < 0.05$ was considered statistically significant.

RESULTS

Characteristics of the SC and EDTA-eluting FCSEMS

All the drug-eluting FCSEMS possessed a smooth surface and good patency (Figure 1A). In terms of coating mass and thickness, there was a significant difference among the three groups ($P < 0.05$). As shown in Table 1, with the same drug loading and drug-loaded material, the average coating mass and thickness of Stent II were both greater than those of Stent I and Stent III ($P < 0.05$), while there was no significant difference between Stent I and Stent III ($P > 0.05$). The drug-loading efficiency was much lower in Stent II than in another two groups. In other words, given the same coating mass, Stent II had the least drug loading capacity.

Drug release behavior

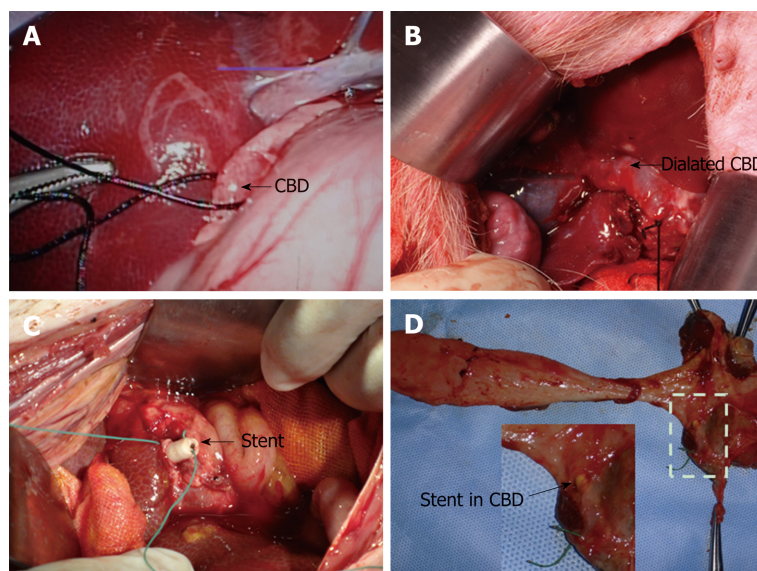


Figure 2 Key steps to put stent into porcine common bile duct. A: The porcine common bile duct (CBD) was partially ligated via laparoscopy; B: The porcine CBD was dilated after one-week ligation; C: Naked fully covered self-expanding metal stent or Stent III was put into the porcine CBD through choledochotomy. To avoid stent migration, stents were sewed on the CBD walls with special care when closing the CBD and the ligation was removed thereafter; D: After the animals were sacrificed, all the stents were still in the bile duct without migration. CBD: Common bile duct.

Release behaviors of SC and EDTA-eluting FCSEMS and naked FCSEMS are presented in **Figure 3A**. Naked FCSEMS were not loaded with drugs, so neither SC nor EDTA was detected. In terms of Stent I, the cumulative release of SC and EDTA reached $46.50\% \pm 2.50\%$ of the total loaded drug on day 1, $76.72\% \pm 1.30\%$ on day 5, and $80.12\% \pm 1.80\%$ on day 15; however, no more drugs were released thereafter. In terms of Stent II, the cumulative release of SC and EDTA reached $65.20\% \pm 2.38\%$ of the total loaded drug on day 1 and $76.51\% \pm 1.97\%$ on day 5, then no more drugs were released. By contrast, Stent III only released $11.29\% \pm 1.88\%$ of the total loaded drug on day 1, $45.21\% \pm 2.77\%$ on day 5, and $80.14\% \pm 1.86\%$ on day 30. In sum, Stent I and Stent II had obvious burst release of drugs while Stent III presented controlled drug release as we expected.

Stone dissolution in still buffer

The dissolution curve is showed in **Figure 3B**. Naked FCSEMS only caused a little loss of stone mass ($5.19\% \pm 0.69\%$) at the end of observation, which might be due to the dissolution of bile pigments of stones into the buffer. Stone mass-loss rate of Stent I reached $9.74\% \pm 1.14\%$ on day 1, which gradually increased to $20.37\% \pm 2.13\%$ on day 5; however, no more mass loss was seen thereafter. The situation was similar in Stent II. Stone mass loss was detected only in the first 5 d and the maximum stone mass-loss rate of Stent II was $24.57\% \pm 1.45\%$. As to Stent III, stone mass-loss rate on day 1 only reached $4.11\% \pm 1.67\%$, and stone mass loss in the first five days was lower than those of Stent I and Stent II. However, stone mass loss of Stent III gradually increased in the next 25 d and come to a final stone mass-loss rate of $33.72\% \pm 0.67\%$. In terms of final stone mass-loss rate, there were differences among the three groups ($P < 0.05$). The final stone mass-loss rate of Stent III was significantly higher than those of Stent I and Stent II ($P < 0.05$), and there existed no difference between Stent I and Stent II. In other words, with the same drug loading, Stent III possessed the best stone-dissolving effect in still buffer.

Stone dissolution in flowing bile

Stone mass loss could be observed throughout the whole experiment in all the groups (**Figure 3C**). In the first 5 d, naked FCSEMS gained $2.61\% \pm 0.58\%$ of stone mass loss, while Stent I, Stent II, and Stent III gained $3.32\% \pm 0.62\%$, $3.47\% \pm 0.83\%$, and $2.82\% \pm 0.37\%$, respectively. The stone mass loss ratio of naked FCSEMS was statistically lower than those of Stent I and Stent II ($P < 0.05$), but similar to that of Stent III ($P > 0.05$). However, there existed no difference in stone mass loss ratio between any two of Stent I, Stent II, and Stent III. At the end of observation, the stone mass loss ratio of naked FCSEMS, Stent I, Stent II, and Stent III was $5.87\% \pm 0.25\%$, $6.36\% \pm 0.48\%$, $6.38\% \pm 0.37\%$, and $8.15\% \pm 0.27\%$, respectively. The final stone mass loss ratio of naked

Table 1 Parameters of drug-eluting stents manufactured by three different methods (mean \pm SD)

	Drug-loaded material	Drug load (mg)	Coating mass (mg)	Coating thickness (mm)	Drug-loading efficiency (%)
Stent I (<i>n</i> = 6)	PCL	50	49.78 \pm 0.09 ^b	0.48 \pm 0.05 ^b	50
Stent II (<i>n</i> = 6)	PCL	50	74.98 \pm 0.12 ^c	0.79 \pm 0.05 ^c	33.3
Stent III (<i>n</i> = 6)	PCL	50	50.01 \pm 0.11	0.57 \pm 0.03	50

PCL: Polycaprolactone. Stent I *vs* Stent II, ^a*P* < 0.05,^b*P* < 0.01; Stent I *vs* Stent III, ^c*P* < 0.05, ^d*P* < 0.01; Stent II *vs* Stent III, ^e*P* < 0.05,^f*P* < 0.01.

FCSEMS was lower than those of the other three groups (naked FCSEMS *vs* Stent I, *P* < 0.05; naked FCSEMS *vs* Stent II, *P* < 0.01; naked FCSEMS *vs* Stent III, *P* < 0.01). Stent I and Stent II had similar stone mass loss ratio (*P* > 0.05), both of which were remarkably lower than that of Stent III (*P* < 0.01).

Serological analysis and histopathological examination

In view of better stone-dissolving effect in flowing bile, Stent III was included in the animal experiment and naked FCSEMS acted as a control. Since we failed to place one stent together with one stone into porcine CBD through choledochotomy due to high mortality of miniature pigs (3/3) in our preliminary experiment, only the stents were placed into CBD in this study. All animals survived well after the stent placement. Comparing all the observed serological indicators (listed in Table 2) between the two groups, there were no difference before nor after the stent placement (*P* > 0.05 for all); comparing all the indicators before and after the stent placement in the same group, no difference was observed in both groups (*P* > 0.05 for all).

HE staining demonstrated that the gallbladder in both groups presented mild to moderate inflammatory cell infiltration and the CBD in both groups had mild to severe inflammatory cell infiltration. No necrosis or fibrosis was seen in the gallbladder and CBD. The inflammatory response rankings of the gallbladder and CBD in both groups are listed in Table 3, and there existed no statistical difference between the two groups (*P* > 0.05). Besides, the duodenal wall, liver, and kidney were normal in both groups (Figure 4).

DISCUSSION

The treatment of difficult CBDS remains a big challenge around the world. The idea of delivering stone-dissolving agents to the location of CBDS *via* biliary stent is first introduced by our research group. Based on our previous work and updated progress in the endoscopic field, we presented a brand-new stone-dissolving FCSEMS.

Choice of stents

The primary goal of stent implantation in patients with CBDS is to release biliary obstruction. In this study, stone mass loss in flowing bile was observed throughout the whole experiment in all four groups, which indicated that unobstructed bile duct with flowing bile might contribute to the dissolution of CBDS. PS are usually deployed across the duodenal papilla and the incidence of duodenobiliary reflux is not rare, leading to recurrent choledocholithiasis and bile infection. Limited drainage lumen and biliary infection make PS clogged easily^[15,16] so that PS needs to be replaced periodically. Compared with PS, FCSEMS have several advantages as follows. First, FCSEMS have a bigger inner diameter, providing larger drainage volume and decreasing the possibility of stent occlusion. Second, FCSEMS with a retrieval lasso can be put above the duodenal papilla without disturbing the physiological function of the Oddi's sphincter, thus reducing the chance of biliary infection caused by duodenal-biliary reflux^[6,17]. What is more, the self-expanding performance and flexibility of nitinol stents allow larger contact area between stent and stone(s), which might increase the friction between them and speed up the disintegration of CBDS, thus facilitating later bile duct clearance. The research of Kwon *et al*^[18] also suggested that stents with a wide contact surface with the stones were clinically more effective in reducing the stone size. In short, we presumed that FCSEMS exceed PS in maintaining fluent bile flow and disintegrating CBDS. Unfortunately, this idea cannot be verified in this study and no one has made a comparison between PS and FCSEMS in the management of CBDS yet. It is also worth noting that when the FCSEMS is put entirely in the CBD, there exists the problem of stent migration^[4]. Risks related to

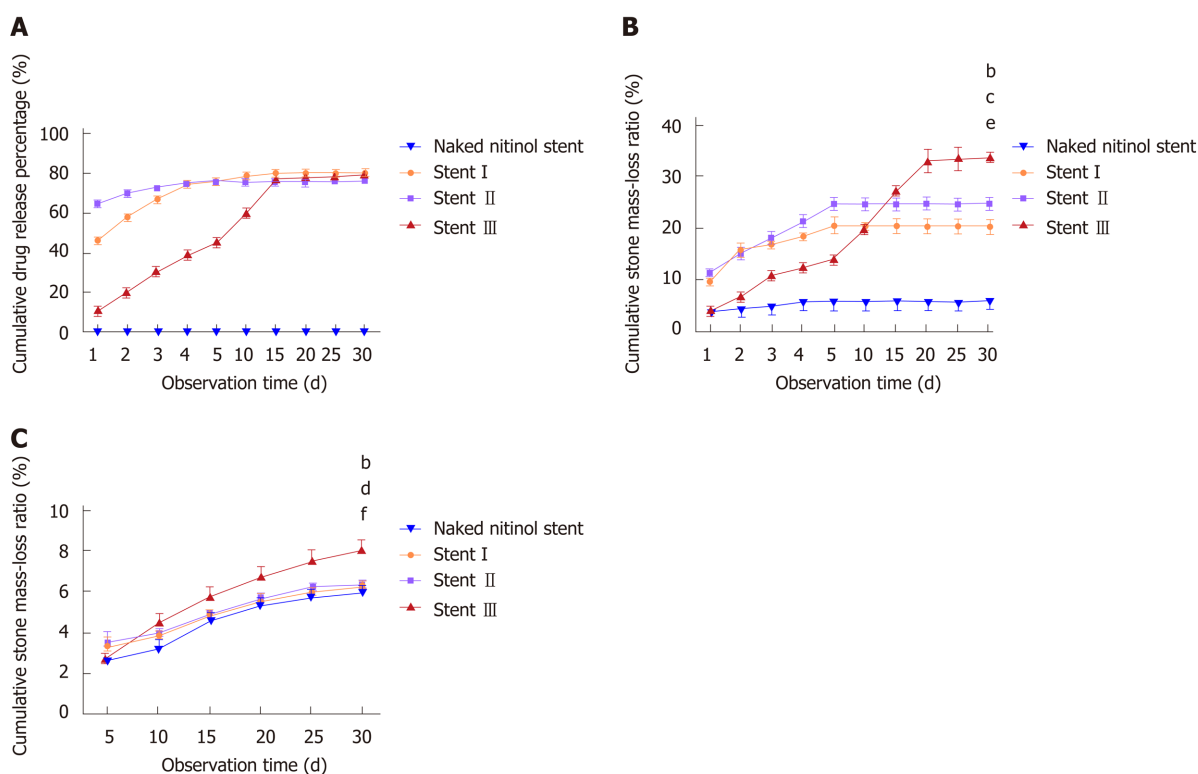


Figure 3 Drug release behavior and stone-dissolving efficacy of different stents. A: Drug release curves of three types of drug-eluting stents and stents without drug load; B: Stone mass loss curves of three types of drug-eluting stents and stents without drug load in still buffer; C: Stone mass loss curves of three types of drug-eluting stents and stents without drug load in flowing bile. Naked fully covered self-expanding metal stent vs Stent III, ^a $P < 0.05$, ^b $P < 0.01$; Stent I vs Stent III, ^c $P < 0.05$, ^d $P < 0.01$; Stent II vs Stent III, ^e $P < 0.05$, ^f $P < 0.01$.

FCSEMS insertion above the papilla need to be further evaluated.

Choice of manufacture method

Stent I and Stent II had most of their drugs released in the first 5 d, and stone mass loss in still buffer was only detected in the first 5 d. Stent III performed continuous and steady release of drugs for 30 d, and stone mass loss in still buffer gradually increased with time. What is more, Stent III gained the highest stone mass-loss rate among all the groups in flowing bile. It is not difficult to draw the conclusion that better stone-dissolving outcome is related to the sustainable drug release.

Another super-thin layer of PCL was the only difference between Stent I and Stent III, therefore, we deemed that this layer of PCL contributed to the controlled drug release. Another compact layer of PCL means that drug molecules have a longer way to go to get into the water surrounding the stent, in other words, the release of drugs slows down to some extent. Comparing with burst drug release, gradual release of drugs in each day let the CBDS have more contact time with the drugs, and the litholytic effect accumulates day by day.

With the same drug loading, the drug-loaded coating of Stent I and Stent III was thinner, which made Stent I and Stent III lighter and more practical. As set forth, drug-loaded stent manufactured by dip coating had the problem of coating falling off, however, this phenomenon was not observed on Stent I. And we believe that one well-knit layer of PCL by electrospinning could prevent this potential trouble. And the further *in vivo* experiment demonstrated that Stent III as well as naked FCSEMS was characterized with good biosecurity in mini-pigs.

The present study was subject to several limitations. First, the stones in this study were obtained from human CBD, however, we did not tell cholesterol stones, pigmented stones, or mixed stones apart. If we want to figure out the composition of one specific stone, this stone needs to be grinded down into fine power and be tested, which made the stone classification impossible before all the experiments. Second, we failed to place one stent together with one stone into porcine CBD through choledochotomy due to high mortality of miniature pigs (3/3) in our preliminary experiment and only the stents were placed into CBD in this study. The disintegration of stone caused by mechanical friction between FCSEMS and stone could not be fully evaluated.

In conclusion, EDTA and SC-eluting stent can speed up the disintegration of CBDS

Table 2 Serology of experimental animals before and after stent placement (mean \pm SD)

	Naked FCSEMS (n = 6)			Stent III (n = 6)		
	Day 0	Day 15	Day 30	Day 0	Day 15	Day 30
ALT (U/L)	33.06 \pm 7.31	29.93 \pm 8.22	32.10 \pm 5.97	33.16 \pm 6.14	30.50 \pm 3.41	35.66 \pm 5.51
AST (U/L)	29.60 \pm 3.82	34.86 \pm 7.28	34.66 \pm 8.73	48.64 \pm 18.81	28.06 \pm 4.00	29.37 \pm 3.33
Alb (g/L)	30.80 \pm 5.33	31.50 \pm 6.07	32.56 \pm 5.43	32.44 \pm 5.37	34.6 \pm 0.81	34.54 \pm 6.26
TBIL (umol/L)	1.32 \pm 0.38	1.95 \pm 0.54	1.80 \pm 0.37	1.68 \pm 0.26	2.14 \pm 0.65	1.74 \pm 0.55
TBA (umol/L)	16.43 \pm 7.24	16.83 \pm 9.50	13.30 \pm 3.55	16.56 \pm 8.58	9.21 \pm 1.90	16.90 \pm 9.35
γ -GT (U/L)	44.04 \pm 9.29	41.36 \pm 3.59	42.62 \pm 7.18	47.40 \pm 7.60	42.38 \pm 3.74	41.16 \pm 9.57
ALP (U/L)	167.02 \pm 42.32	138.33 \pm 47.60	144.12 \pm 40.23	158.4 \pm 60.56	124.20 \pm 31.39	163.00 \pm 28.91
Cre (umol/L)	47.90 \pm 12.16	46.06 \pm 9.27	48.00 \pm 13.94	39.12 \pm 12.96	49.72 \pm 10.50	60.02 \pm 19.71
Ca (mmol/L)	2.89 \pm 0.28	2.57 \pm 0.01	2.86 \pm 0.33	2.60 \pm 0.52	2.75 \pm 0.53	2.81 \pm 0.29
Mg (mmol/L)	1.01 \pm 0.08	0.93 \pm 0.06	1.14 \pm 0.27	1.28 \pm 0.21	1.00 \pm 0.22	1.04 \pm 0.25

FCSEMS: Fully covered self-expanding metal stent; ALT: Alanine aminotransferase; AST: Aspartate aminotransferase; TBIL: Total bilirubin; TBA: Total bile acids; γ -GT: γ -glutamine transaminase; Alb: Albumin; ALP: Alkaline phosphatase; Cre: Creatinine.

in vitro and it works better when the drugs are controlled released. Given the successful application of FCSEMS in the management of difficult CBDs, the combination of controlled EDTA and SC release and FCSEMS might be a promising alternative.

Table 3 Classification of inflammation in different tissues after stent placement

	Gallbladder		CBD	
	Naked FCSEMS	Stent III	Naked FCSEMS	Stent III
	(n = 5)	(n = 5)	(n = 5)	(n = 5)
-	0	0	0	0
+	2	3	1	1
++	3	2	3	2
+++	0	0	1	2
Z-value	0.48		-0.34	
P-value	0.36		0.65	

CBD: Common bile duct; FCSEMS: Fully covered self-expanding metal stent. Mild (+), moderate (++), and severe (+++).

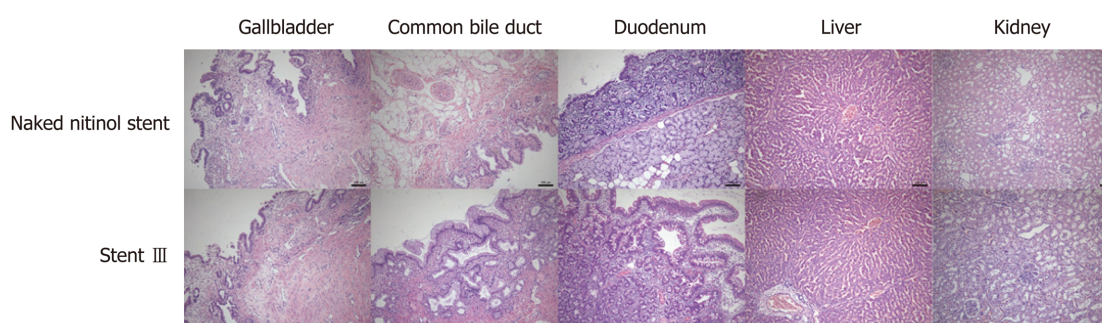


Figure 4 Pictures of hematoxylin and eosin staining of gallbladder, common bile duct, duodenum, liver, and kidney tissues after 30-d placement of naked fully covered self-expanding metal stent or Stent III in the porcine common bile duct (100-fold magnification).

ARTICLE HIGHLIGHTS

Research background

The treatment of difficult common bile duct stones (CBDS) remains a big challenge around the world and there is no consensus on the management of difficult CBDS.

Research motivation

In our previous studies, we have developed a drug-eluting plastic stent (PS) which is able to release disodium ethylene diamine tetraacetic acid (EDTA) and sodium cholate (SC), and the stent has been proved to effectively dissolve CBDS *ex vivo* and in a live porcine CBDS model. However, there are several shortcomings in our previous version, thus we aimed to modify our stone-dissolving stents in this study.

Research objectives

This study aimed to manufacture a drug-eluting metal stent, which can achieve controlled release of stone-dissolving agents and speed up the dissolution of CBDS, thus providing a promising alternative for the management of difficult CBDS.

Research methods

In this study, three different methods were used to manufacture the drug-eluting stents. The drug-release behavior and stone-dissolving efficacy of these stents was evaluated *in vitro* to sort out the best manufacturing method. And the selected stone-dissolving stents were further put into porcine CBD to evaluate their biosecurity.

Research results

We found that the stent manufactured by dip coating combined with electrospinning was characterized by sustainable drug release, better stone-dissolving efficacy, and good biosecurity. However, we failed to establish the CBDS model in miniature pigs and the disintegration of stone caused by mechanical friction between fully covered self-expanding metal stent (FCSEMS) and stone could not be fully evaluated.

Research conclusions

The novel SC and EDTA-eluting FCSEMS is efficient in diminishing CBDS *in vitro* and is

characterized by good biosecurity. The idea of delivering stone-dissolving agents to the location of CBDs via biliary stent is feasible. When conventional endoscopic techniques fail to remove difficult CBDs, SC and EDTA-eluting FCSEMS implantation may be considered a promising alternative.

Research perspectives

In the future research, a live porcine CBDs model needs to be established so that the disintegration of stone caused by mechanical friction between FCSEMS and stone could be fully evaluated. And we can compare which stent works better in disintegrating CBDs, PS, or FCSEMS.

REFERENCES

- 1 **Yasuda I**, Itoi T. Recent advances in endoscopic management of difficult bile duct stones. *Dig Endosc* 2013; **25**: 376-385 [PMID: 23650878 DOI: 10.1111/den.12118]
- 2 **Ogura T**, Higuchi K. A review of treatment options for bile duct stones. *Expert Rev Gastroenterol Hepatol* 2016; **10**: 1271-1278 [PMID: 27410721 DOI: 10.1080/17474124.2016.1212658]
- 3 **García-Cano J**, Reyes-Guevara AK, Martínez-Pérez T, Valiente-González L, Martínez-Fernández R, Viñuelas-Chicano M, Gómez-Ruiz CJ, Morillas-Ariño J, Pérez-Vigara G, Pérez-García JJ, Pérez-Sola Á. Fully covered self-expanding metal stents in the management of difficult common bile duct stones. *Rev Esp Enferm Dig* 2013; **105**: 7-12 [PMID: 23548005]
- 4 **Hartery K**, Lee CS, Doherty GA, Murray FE, Cullen G, Patchett SE, Mulcahy HE. Covered self-expanding metal stents for the management of common bile duct stones. *Gastrointest Endosc* 2017; **85**: 181-186 [PMID: 27262891 DOI: 10.1016/j.gie.2016.05.038]
- 5 **Cho E**, Park CH, Jun CH, Kim HS, Choi SK, Rew JS. Self-expandable metal stents for the extraction of common bile duct stones in patients receiving dual antiplatelet agents: A pilot study. *Surg Endosc* 2018; **32**: 1077-1081 [PMID: 28733742 DOI: 10.1007/s00464-017-5743-2]
- 6 **Ueda T**, Kikuyama M, Kodama Y, Kurokawa T. Short-Term Biliary Stent Placement Contributing Common Bile Duct Stone Disappearance with Preservation of Duodenal Papilla Function. *Gastroenterol Res Pract* 2016; **2016**: 6153893 [PMID: 27247568 DOI: 10.1155/2016/6153893]
- 7 **Jun CH**, Park CH, Jeon J, Park IH, Lee HJ, Park SY, Kim HS, Choi SK, Rew JS. Feasibility of self-expandable metal stents for preservation of sphincter of Oddi function in patients with common bile duct stones: A pilot study. *Gastrointest Endosc* 2015; **82**: 719-723 [PMID: 25887719 DOI: 10.1016/j.gie.2015.01.034]
- 8 **Sohrabi A**, Max MH, Hershey CD. Cholate sodium infusion for retained common bile duct stones. *Arch Surg* 1979; **114**: 1169-1172 [PMID: 485827]
- 9 **Dai KY**, Montet JC, Zhao XM, Amic J, Montet AM. Dissolution of human brown pigment biliary stones. *J Hepatol* 1989; **9**: 301-311 [PMID: 2514227 DOI: 10.1016/0168-8278(89)90138-4]
- 10 **Klueppelberg U**, Baumgaertel H, Schudsziarra V, Swobodnik W. Dissolution of bile duct stones by a hydrophilized glyceromonooctanoic-bile-acid-EDTA emulsion. *Klin Wochenschr* 1991; **69**: 76-82 [PMID: 1902880 DOI: 10.1007/BF01666820]
- 11 **Wosiewicz U**, Sabinski F, Haus C, Güldütuna S, Leuschner U. Experimental dissolution of pigment gallstone material using alkaline EDTA and adjuvant bile salts/non-bile salt detergents, thiols and urea, with respect to local chemolitholysis. *J Hepatol* 1992; **14**: 7-15 [PMID: 1737918 DOI: 10.1016/0168-8278(92)90124-8]
- 12 **Cai XB**, Zhang WX, Wan XJ, Yang Q, Qi XS, Wang XP, Lu LG. The effect of a novel drug-eluting plastic stent on biliary stone dissolution in an ex vivo bile perfusion model. *Gastrointest Endosc* 2014; **79**: 156-162 [PMID: 24125512 DOI: 10.1016/j.gie.2013.09.013]
- 13 **Cai XB**, Zhang WX, Zhang RL, Dong Yuan X, Yang Q, Qi XS, Li BW, Qin Qian Y, Wang XP, Lu LG, Xu ZJ, Wan XJ. Safety and efficacy of a novel plastic stent coated with stone-dissolving agents for the treatment of biliary stones in a porcine model. *Endoscopy* 2015; **47**: 457-461 [PMID: 25479561 DOI: 10.1055/s-0034-1390772]
- 14 **Gao Q**, Huang C, Sun B, Aqeel BM, Wang J, Chen W, Mo X, Wan X. Fabrication and characterization of metal stent coating with drug-loaded nanofiber film for gallstone dissolution. *J Biomater Appl* 2016; **31**: 784-796 [PMID: 27698255 DOI: 10.1177/0885328216671239]
- 15 **Donelli G**, Guaglianone E, Di Rosa R, Fiocca F, Basoli A. Plastic biliary stent occlusion: Factors involved and possible preventive approaches. *Clin Med Res* 2007; **5**: 53-60 [PMID: 17456835 DOI: 10.3121/cmr.2007.683]
- 16 **Sung JY**, Leung JW, Shaffer EA, Lam K, Olson ME, Costerton JW. Ascending infection of the biliary tract after surgical sphincterotomy and biliary stenting. *J Gastroenterol Hepatol* 1992; **7**: 240-245 [PMID: 1611012 DOI: 10.1111/j.1440-1746.1992.tb00971.x]
- 17 **Hu B**, Leung JW, Gao DJ, Wang TT, Wu J. Management of benign biliary strictures with a novel retrievable self-expandable metal stent. *J Dig Dis* 2014; **15**: 146-153 [PMID: 24528634 DOI: 10.1111/1751-2980.12117]
- 18 **Kwon CI**, Kim G, Jeong S, Choi SH, Ko KH, Lee DH, Cho JY, Hong SP. Experimental study on the friction effect of plastic stents for biliary stone fragmentation (with video). *Dig Endosc* 2018; **30**: 107-113 [PMID: 28622426 DOI: 10.1111/den.12906]



Published By Baishideng Publishing Group Inc
7041 Koll Center Parkway, Suite 160, Pleasanton, CA 94566, USA
Telephone: +1-925-2238242
Fax: +1-925-2238243
E-mail: bpgoffice@wjgnet.com
Help Desk: <http://www.f6publishing.com/helpdesk>
<http://www.wjgnet.com>

