




Contents lists available at ScienceDirect

JPRAS Open

journal homepage: <http://www.journals.elsevier.com/jpras-open>

Case report

Complications 15 years after breast augmentation with polyacrylamide

Habib M. Ghasemi^{a,*}, Tine E. Damsgaard^a, Lars B. Stolle^b,
Bekka O. Christensen^a^a Department of Plastic Surgery, Aarhus University Hospital, Aarhus, Denmark^b Department of Plastic Surgery, Odense University Hospital, Odense, Denmark

ARTICLE INFO

Article history:

Received 23 March 2015

Accepted 30 April 2015

Available online 9 May 2015

Keywords:

Polyacrylamide hydrogel

Breast augmentation

Complications

Filler

Cosmetic

Case report

ABSTRACT

Polyacrylamide hydrogel (PAAG) has been used as an injectable, permanent filler for soft-tissue augmentation for more than two decades. Several complications have been reported worldwide. In this case report, we present a woman with long-term complications 15 years after bilateral breast augmentation with PAAG injections.

© 2015 The Authors. Published by Elsevier Ltd on behalf of British Association of Plastic, Reconstructive and Aesthetic Surgeons. This is an open access article under the CC BY-NC-ND license (<http://creativecommons.org/licenses/by-nc-nd/4.0/>).

Introduction

Fillers for the augmentation and correction of soft-tissue contours are increasing in popularity, and numerous biomaterials have been developed. The fillers can be grouped as biodegradable, nonbio-degradable (permanent), and combinations thereof.¹

Polyacrylamide hydrogel (PAAG) is a permanent filler that may be used to correct soft-tissue contours in the face or in breast augmentation.² PAAG is a jellylike, transparent substance containing approximately 2.5% cross-linked polyacrylamide and 97.5% water. Since the discovery of PAAG, it has been widely used for industrial purposes and in ophthalmologic procedures. It was first used for

* Corresponding author. Department of Plastic Surgery, Aarhus University Hospital, Noerrebrogade 44, 8000 Aarhus C, Denmark. Tel.: +45 31206395.

E-mail address: habib@dadlnet.dk (H.M. Ghasemi).

<http://dx.doi.org/10.1016/j.jpra.2015.04.002>

2352-5878/© 2015 The Authors. Published by Elsevier Ltd on behalf of British Association of Plastic, Reconstructive and Aesthetic Surgeons. This is an open access article under the CC BY-NC-ND license (<http://creativecommons.org/licenses/by-nc-nd/4.0/>).

“cosmetic purposes” in the 1990s when Ukrainian surgeons started using PAAG for breast augmentation.³ In 2001, it attained European community certification, and since then it has been in clinical use.

PAAG is considered to be a safe tissue filler.^{4,5} However, an increasing number of complications after PAAG injection have been reported.^{6,8} In this case report, we present a 47-year-old woman who experienced complications 15 years after bilateral breast augmentation with PAAG injections.

Case report

A 44-year-old, Ukrainian woman presented with a tender and painful left breast, exhibiting asymmetry and palpable masses in March 2009 (Figure 1). In 1994, she underwent a bilateral breast augmentation with the permanent filler PAAG. According to the patient, the breasts lost their volume slightly over the years. In August 2008, a subcutaneous nodule measuring 5 × 5 cm emerged in the medial lower quadrant of her left breast. After a mammography showed that the nodule was benign, the nodule was excised. Six months later, the area of excision was filled with a liquid substance, which was again removed surgically. Culture of the removed material showed no bacterial contamination. A few weeks later, a fistula formed at the area of excision, and the patient was treated with antibiotics without any effect. In March 2009, the patient was referred to the Department of Plastic Surgery, Aarhus University Hospital.

A blood sample from March 2009 showed increased levels of CRP (C-reactive protein) (1889 nmol/l), sedimentation reaction (49 mm), and leukocytes ($11.6 \times 10^9/L$). Magnetic resonance imaging (MRI) scan showed a large amount of fluid in the pectoral muscle and in the retro-pectoral space, mostly on the right side (Figure 3). Another MRI scan, 8 months later, showed decreased collection of fluid on the right side but increased collection of fluid on the left side, thus indicating further migration of the filler (Figure 4).

Two years later, in September 2011, the left breast was still painful and twice its original size. In April 2012, the patient underwent surgery. An incision was made in the inframammary sulcus on the left side, and through subpectoral dissection 930 cc of yellow, clear liquid containing white nodules was removed from the encapsulated cavity. Postoperatively, the patient received 400 mg of moxifloxacin orally daily for 7 days as recommended by the distributor (Contura, Copenhagen, Denmark). The drains were removed 36 h after the operation, and she was discharged the first postoperative day (Figure 2). Neither a regular culture nor PCR analysis of the samples removed during surgery revealed any pathogens.

Two months postoperatively, the left breast was asymptomatic and natural looking. The right breast, however, was enlarged and tender. The patient is still being followed up in the outpatient clinic with regular clinical and radiological examinations.

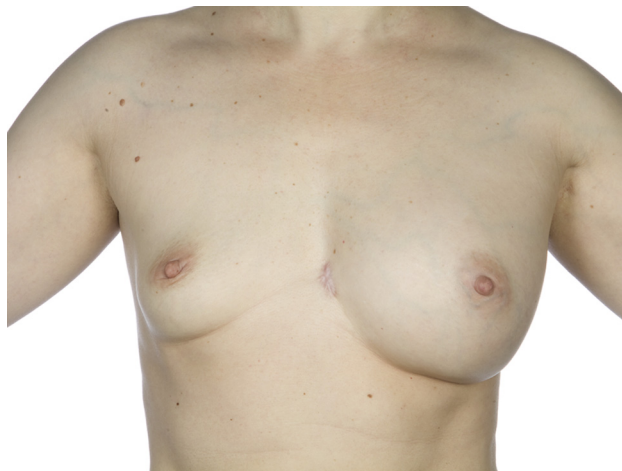

Figure 1. Swelling of the left breast before operation (September 2011).

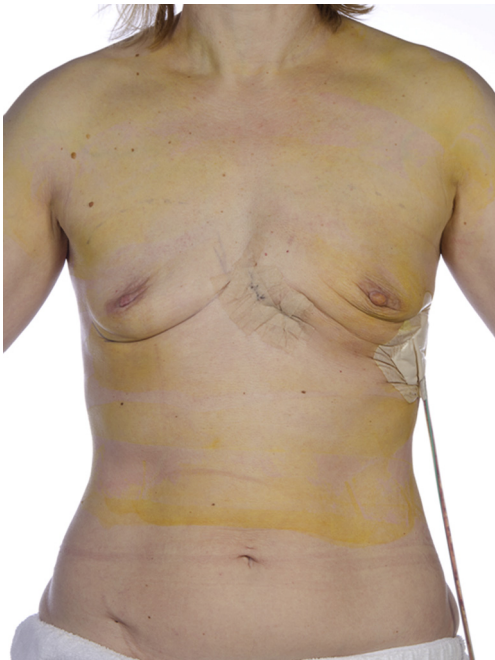

Figure 2. The day after surgical drainage of PAAG from the left breast (April 2012).

Discussion

In a study by Unukovych et al, 106 patients with PAAG breast augmentation were examined.⁷ They found that the most frequently reported complications are pain, subcutaneous nodules, breast deformities due to swelling, migration, and fistula formation. The patient in this case report experienced all the above mentioned complications.

This case report confirms that PAAG may be a potentially dangerous filler for breast augmentation, causing substantial irreversible damage to the breast in previously healthy women.^{6,10} Different

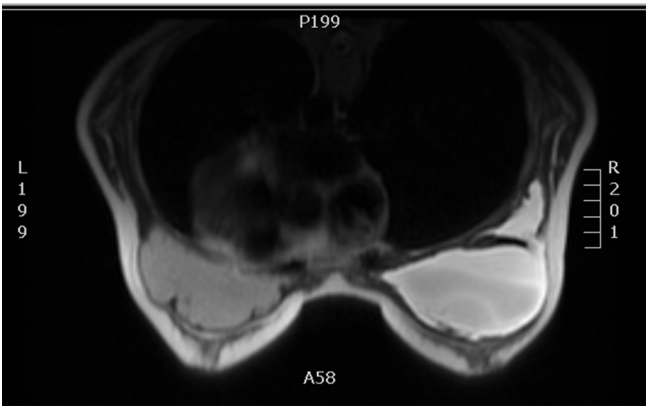


Figure 3. Large amount of fluid mostly on the right side (March 2009).

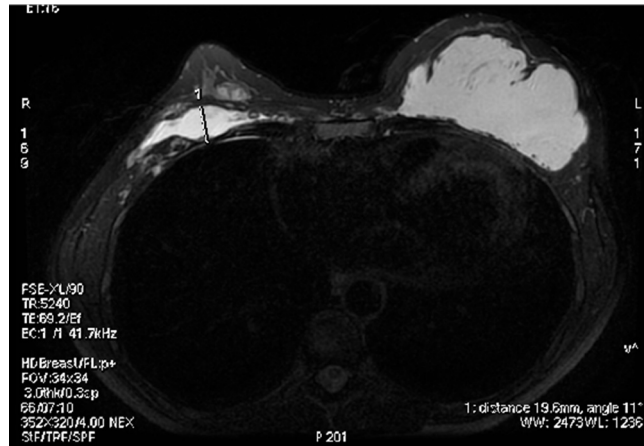


Figure 4. Migration of the fluid to the left breast (November 2009).

attempts have been made to treat the complications. A case study by Amin et al reports that steroids may reduce the foreign body reaction and eventually make it disappear.⁸ According to Cheng NX et al, antibiotics have no effect, because microorganisms are very seldom isolated from the tissue samples⁶ as in this case. Complete gel evacuation using aspiration is very difficult, as the PAAG is scattered diffusely into the breast tissue and pectoralis muscle. Even after several suction procedures, residual gel may remain in the breast tissue.⁹

The only effective treatment of complications is to remove the PAAG surgically. Evacuation of the main part of the gel is possible by incision and drainage. In order to remove all the PAAG and the damaged tissue, a subcutaneous mastectomy may be necessary as a last option.^{3,7}

With the increasing interest and availability of fillers for cosmetic use, it is to be expected that complications of fillers in general will occur more frequently. Therefore, it is important to gather all possible information about these serious complications and their possible treatment.

Conflicts of interest

None.

Funding

None.

References

- Mauricio M, Berthold R. *Injectable Fillers in Aesthetic Medicine*. Germany: Springer-Verlag; 2006.
- Rauso R, Freda N, Parlato V, et al. Polyacrylamide gel injection for treatment of human immunodeficiency virus-associated lipoatrophy: 18 months follow-up. *Dermatol Surg*. 2011;37:1584–1589.
- Patlazhan G, Unukovych D, Pshenishnov K. Breast reconstruction and treatment algorithm for patients with complications after polyacrylamide gel injections: a 10-year experience. *Aesthetic Plast Surg*. 2013;37:312–320.
- Pallua N, Wolter TP. A 5-year assessment of safety and aesthetic results after facial soft-tissue augmentation with polyacrylamide hydrogel (Aquamid): a prospective multicenter study of 251 patients. *Plast Reconstr Surg*. 2010;125:1797–1804.
- Narins RS, Coleman WP, Rohrich R, et al. 12-Month controlled study in the United States of the safety and efficacy of a permanent 2.5% polyacrylamide hydrogel soft-tissue filler. *Dermatol Surg*. 2010;36:1819–1829.
- Cheng NX, Wang YL, Wang JH, et al. Complications of breast augmentation with injected hydrophilic polyacrylamide gel. *Aesthetic Plast Surg*. 2002;26:375–382.
- Unukovych D, Khrapach V, Wickman M, et al. Polyacrylamide gel injections for breast augmentation: management of complications in 106 patients, a multicenter study. *World J Surg*. 2012;36:695–701.
- Amin SP, Marmur ES, Goldberg DJ. Complications from injectable polyacrylamide gel, a new nonbiodegradable soft tissue filler. *Dermatol Surg*. 2004;30:1507–1509.

9. Qiao Q, Wang X, Sun J, et al. Management for postoperative complications of breast augmentation by injected polyacrylamide hydrogel. *Aesthet Plast Surg*. 2005;29:156–161.
10. Xu C, Cao M, Bao B, et al. Tissue degeneration 7 years after breast augmentation with injected polyacrylamide hydrogel (PAAG). *Aesthetic Plast Surg*. 2012;36:160–162.