

World Journal of *Clinical Cases*

World J Clin Cases 2019 October 6; 7(19): 2916-3167



**REVIEW**

- 2916** DNA methylation detection methods used in colorectal cancer
Zhan YX, Luo GH

ORIGINAL ARTICLE**Case Control Study**

- 2930** Expression and predictive value of miR-489 and miR-21 in melanoma metastasis
Mo H, Guan J, Yuan ZC, Lin X, Wu ZJ, Liu B, He JL

Observational Study

- 2942** Association of stiff-person syndrome with autoimmune endocrine diseases
Lee YY, Chen IW, Chen ST, Wang CC
- 2953** Hyperthyroid heart disease in pregnancy: Retrospective analysis of a case series and review of the literature
Shan D, Bai Y, Chen QH, Wu YX, Chen Q, Hu YY
- 2963** Changes of serum inflammatory factors and miR-145 expression in patients with osteoarthritis before and after treatment and their clinical value
Wang XZ, Li WX

Prospective Study

- 2976** Immediate muscle strengthening by an end-effector type gait robot with reduced real-time use of leg muscles: A case series and review of literature
Hwang CH

Randomized Clinical Trial

- 2986** Comparison of perceived pain and patients' satisfaction with traditional local anesthesia and single tooth anesthesia: A randomized clinical trial
Al-Obaida MI, Haider M, Hashim R, AlGheriri W, Celur SL, Al-Saleh SA, Al-Madi EM

SYSTEMATIC REVIEW

- 2995** Treatment of laryngopharyngeal reflux disease: A systematic review
Lechien JR, Mouawad F, Barillari MR, Nacci A, Khoddami SM, Enver N, Raghunandhan SK, Calvo-Henriquez C, Eun YG, Saussez S

CASE REPORT

- 3012** Keratoconus in a patient with Alport syndrome: A case report
Moshirfar M, Skanchy DF, Gomez AT, Ronquillo YC, Buckner B, Hoopes PC

- 3018** Successful multidisciplinary clinical approach and molecular characterization by whole transcriptome sequencing of a cardiac myxofibrosarcoma: A case report
Saponara M, Indio V, Pizzi C, Serban ED, Urbini M, Astolfi A, Paolisso P, Suarez SM, Nannini M, Pacini D, Agostini V, Leone O, Ambrosini V, Tarantino G, Fanti S, Niro F, Buia F, Attinà D, Pantaleo MA
- 3027** Laparoscopic hysterectomy as optimal approach for 5400 grams uterus with associated polycythemia: A case report
Macciò A, Chiappe G, Lavra F, Sanna E, Nieddu R, Madeddu C
- 3033** Malignant sweat gland tumor of breast arising in pre-existing benign tumor: A case report
An JK, Woo JJ, Hong YO
- 3039** Bronchobiliary fistula after ramucirumab treatment for advanced gastric cancer: A case report
Kim HB, Na YS, Lee HJ, Park SG
- 3047** Severe heterotopic ossification in a seronegative spondyloarthritis patient after cervical Bryan disc arthroplasty: A case report
Huang CW, Tang CL, Pan HC, Tzeng CY, Tsou HK
- 3055** Underlying IgM heavy chain amyloidosis in treatment-refractory IgA nephropathy: A case report
Wu HT, Wen YB, Ye W, Liu BY, Shen KN, Gao RT, Li MX
- 3062** Diagnosis of myocardial infarction with nonobstructive coronary arteries in a young man in the setting of acute myocardial infarction after endoscopic retrograde cholangiopancreatography: A case report
Li D, Li Y, Wang X, Wu Y, Cui XY, Hu JQ, Li B, Lin Q
- 3069** Hemophagocytic lymphohistiocytosis complicated by polyserositis: A case report
Zhu P, Ye Q, Li TH, Han T, Wang FM
- 3074** Hair regrowth following fecal microbiota transplantation in an elderly patient with alopecia areata: A case report and review of the literature
Xie WR, Yang XY, Xia HHX, Wu LH, He XX
- 3082** How should congenital absence of cruciate ligaments be treated? A case report and literature review
Lu R, Zhu DP, Chen N, Sun H, Li ZH, Cao XW
- 3090** Kaposi's sarcoma manifested as lower gastrointestinal bleeding in a HIV/HBV-co-infected liver cirrhosis patient: A case report
Zhou QH, Guo YZ, Dai XH, Zhu B
- 3098** Primary renal synovial sarcoma: A case report
Cai HJ, Cao N, Wang W, Kong FL, Sun XX, Huang B
- 3104** Type I neurofibromatosis with spindle cell sarcoma: A case report
Zhang Y, Chao JJ, Liu XF, Qin SK

- 3111** Primary hypoparathyroidism accompanied by rhabdomyolysis induced by infection: A case report
Ding LN, Wang Y, Tian J, Ye LF, Chen S, Wu SM, Shang WB
- 3120** Effects of combined rTMS and visual feedback on the rehabilitation of supernumerary phantom limbs in a patient with spinal cord injury: A case report
Lu YS, Tong P, Guo TC, Ding XH, Zhang S, Zhang XJ
- 3126** Clear cell sarcoma of soft tissue in pleural cavity: A case report
Chen YT, Yang Z, Li H, Ni CH
- 3132** Primary hyperparathyroidism in a woman with multiple tumors: A case report
Hui CC, Zhang X, Sun JR, Deng DT
- 3138** Gastric adenocarcinoma mimicking a submucosal tumor: A case report
Cheng XL, Liu H
- 3145** Hypereosinophilia, mastectomy, and nephrotic syndrome in a male patient: A case report
Wu J, Li P, Chen Y, Yang XH, Lei MY, Zhao L
- 3153** Flapless immediate implant placement into fresh molar extraction socket using platelet-rich fibrin: A case report
Sun XL, Mudalal M, Qi ML, Sun Y, Du LY, Wang ZQ, Zhou YM
- 3160** Advanced primary amelanotic malignant melanoma of the esophagus: A case report
Zhang RX, Li YY, Liu CJ, Wang WN, Cao Y, Bai YH, Zhang TJ

ABOUT COVER

Editorial Board Member of *World Journal of Clinical Cases*, Enver Zerem, MD, PhD, Professor, Department of Medical Science, Academy of Sciences and Arts of Bosnia and Herzegovina, University Clinical Centre Tuzla, Tuzla 75000, Bosnia and Herzegovina

AIMS AND SCOPE

The primary aim of *World Journal of Clinical Cases* (*WJCC*, *World J Clin Cases*) is to provide scholars and readers from various fields of clinical medicine with a platform to publish high-quality clinical research articles and communicate their research findings online.

WJCC mainly publishes case reports, case series, and articles reporting research results and findings obtained in the field of clinical medicine and covering a wide range of topics including diagnostic, therapeutic, and preventive modalities.

INDEXING/ABSTRACTING

The *WJCC* is now indexed in PubMed, PubMed Central, Science Citation Index Expanded (also known as SciSearch®), and Journal Citation Reports/Science Edition. The 2019 Edition of Journal Citation Reports cites the 2018 impact factor for *WJCC* as 1.153 (5-year impact factor: N/A), ranking *WJCC* as 99 among 160 journals in Medicine, General and Internal (quartile in category Q3).

RESPONSIBLE EDITORS FOR THIS ISSUE

Responsible Electronic Editor: *Yan-Xia Xing*

Proofing Production Department Director: *Xiang Li*

NAME OF JOURNAL

World Journal of Clinical Cases

ISSN

ISSN 2307-8960 (online)

LAUNCH DATE

April 16, 2013

FREQUENCY

Semimonthly

EDITORS-IN-CHIEF

Dennis A Bloomfield, Bao-Gan Peng, Sandro Vento

EDITORIAL BOARD MEMBERS

<https://www.wjgnet.com/2307-8960/editorialboard.htm>

EDITORIAL OFFICE

Jin-Lei Wang, Director

PUBLICATION DATE

October 6, 2019

COPYRIGHT

© 2019 Baishideng Publishing Group Inc

INSTRUCTIONS TO AUTHORS

<https://www.wjgnet.com/bpg/gerinfo/204>

GUIDELINES FOR ETHICS DOCUMENTS

<https://www.wjgnet.com/bpg/GerInfo/287>

GUIDELINES FOR NON-NATIVE SPEAKERS OF ENGLISH

<https://www.wjgnet.com/bpg/gerinfo/240>

PUBLICATION MISCONDUCT

<https://www.wjgnet.com/bpg/gerinfo/208>

ARTICLE PROCESSING CHARGE

<https://www.wjgnet.com/bpg/gerinfo/242>

STEPS FOR SUBMITTING MANUSCRIPTS

<https://www.wjgnet.com/bpg/GerInfo/239>

ONLINE SUBMISSION

<https://www.f6publishing.com>

Diagnosis of myocardial infarction with nonobstructive coronary arteries in a young man in the setting of acute myocardial infarction after endoscopic retrograde cholangiopancreatography: A case report

Dong Li, Yan Li, Xuan Wang, Yang Wu, Xiao-Yun Cui, Ji-Qiang Hu, Bin Li, Qian Lin

ORCID number: Dong Li (0000-0001-8367-1739); Yan Li (0000-0002-7619-2809); Xuan Wang (0000-0002-6278-1880); Yang Wu (0000-0002-0736-7791); Xiao-Yun Cui (0000-0002-1478-4657); Ji-Qiang Hu (0000-0003-0830-9216); Bin Li (0000-0002-6535-5246); Qian Lin (0000-0001-8999-2146).

Author contributions: Li D coordinated the clinical care of the patient and collected the samples; Wang X, Wu Y, Cui XY, Hu JQ, Li B, and Lin Q analysed the data; Li D wrote the first draft of the manuscript and was involved in all stages of manuscript revision; Li Y contributed to the revision of the draft and to proofreading; all authors read and approved the final manuscript.

Supported by Beijing University of Chinese Medicine 1166 Development Program for Junior Scientists, No. 030903010331.

Informed consent statement: Written informed consent was obtained from the patient for the publication of this case report and any accompanying images.

Conflict-of-interest statement: The authors declare no conflicts of interest.

CARE Checklist (2016) statement: The authors have read the CARE Checklist (2013), and the manuscript was prepared and revised according to the CARE

Dong Li, Yan Li, Xuan Wang, Yang Wu, Xiao-Yun Cui, Ji-Qiang Hu, Bin Li, Department of Cardiac Intensive Care Unit, Dongfang Hospital, Beijing University of Chinese Medicine, Beijing 100078, China

Qian Lin, Dongzhimen Hospital, Beijing University of Chinese Medicine, Beijing 100700, China

Corresponding author: Qian Lin, MD, Vice President, Chief Physician, Professor, Dongzhimen Hospital, Beijing University of Chinese Medicine, 5 Hai Yun Cang, Dongcheng District, Beijing, 100700, China. erzitaba@163.com

Telephone: +86-10-67689757

Abstract

BACKGROUND

Acute myocardial infarction (AMI) is characterized by chest pain as well as cardiac troponin I (cTnI) and electrocardiography (ECG) changes. Recently, clinical researchers have used the term "MINOCA" to indicate myocardial infarction with nonobstructive coronary arteries. To the best of our knowledge, no report has documented MINOCA in a young patient after choledocholithiasis by endoscopic retrograde cholangiopancreatography (ERCP).

CASE SUMMARY

An 18-year-old Chinese man presented to the cardiac intensive care unit with chest pain radiating to the left shoulder for 1 h after choledocholithiasis by ERCP and the following treatment. ECG showed a sinus rhythm with ST-segment elevation in the II, III, and aVF leads compared with the baseline. Laboratory data revealed cTnI levels of 67.55 ng/mL and 80 ng/mL at the peak (relative index below 0.034 ng/mL) and creatine kinase-MB levels of 56 U/L and 543 U/L at the peak (relative index below 24 U/L). AMI was suspected, and coronary angiography was performed the second day. The results revealed a smooth angiographic appearance of all arteries. The patient had been diagnosed with gallstones and cholecystitis for four years but had not accepted treatment. He had abdominal pain and bloating a week previously and underwent ERCP and subsequent treatments on the second day of admission; 1.4 cm × 1.6 cm of stones were removed from his common bile duct during surgery. The results of his laboratory tests at admission revealed abnormal alanine aminotransferase,

Checklist (2016).

Open-Access: This article is an open-access article which was selected by an in-house editor and fully peer-reviewed by external reviewers. It is distributed in accordance with the Creative Commons Attribution Non Commercial (CC BY-NC 4.0) license, which permits others to distribute, remix, adapt, build upon this work non-commercially, and license their derivative works on different terms, provided the original work is properly cited and the use is non-commercial. See: <http://creativecommons.org/licenses/by-nc/4.0/>

Manuscript source: Unsolicited manuscript

Received: May 7, 2019

Peer-review started: May 10, 2019

First decision: August 1, 2019

Revised: September 5, 2019

Accepted: September 11, 2019

Article in press: September 11, 2019

Published online: October 6, 2019

P-Reviewer: Tabibian JH

S-Editor: Dou Y

L-Editor: Wang TQ

E-Editor: Xing YX



aspartate aminotransferase, glutamyl transpeptidase, total bile acid, total bilirubin, direct bilirubin, and indirect bilirubin levels. His temperature, heart rate, blood pressure, and body mass index were normal. His echocardiographic examination revealed no obvious abnormalities in the structure and movement of the ventricular wall and an estimated left ventricular ejection fraction of 57% after the heart attack. His cholesterol and triglycerides were within normal ranges, and his low-density lipoprotein cholesterol was 2.23 mmol/L (normal range 2.03-3.34 mmol). Further testing after AMI revealed nothing remarkable in his erythrocyte sedimentation rate, thyroid function, and tumour markers.

CONCLUSION

We ultimately made a diagnosis of MINOCA caused by coronary artery spasm, which seemed to be the most suitable diagnosis of this young patient. We are concerned that the heart attack may have been induced by the ERCP rather than occurred coincidentally afterward, so we should investigate the timing of the event further. Additional studies are needed to unravel the underlying pathophysiology.

Key words: Myocardial infarction with nonobstructive coronary arteries; Acute myocardial infarction; Choledocholithiasis; Endoscopic retrograde cholangiopancreatography; Case report

©The Author(s) 2019. Published by Baishideng Publishing Group Inc. All rights reserved.

Core tip: This is a case report about a young man who were ultimately diagnosed with myocardial infarction with nonobstructive coronary arteries, but initially diagnosed with acute myocardial infarction (AMI). AMI is characterized by chest pain as well as cardiac troponin I and electrocardiography changes. In recent years, clinical researchers have used “MINOCA” to characterize myocardial infarction with non-obstructive coronary arteries. As far as we know, no report has documented this type in a young patient after choledocholithiasis by endoscopic retrograde cholangiopancreatography.

Citation: Li D, Li Y, Wang X, Wu Y, Cui XY, Hu JQ, Li B, Lin Q. Diagnosis of myocardial infarction with nonobstructive coronary arteries in a young man in the setting of acute myocardial infarction after endoscopic retrograde cholangiopancreatography: A case report. *World J Clin Cases* 2019; 7(19): 3062-3068

URL: <https://www.wjgnet.com/2307-8960/full/v7/i19/3062.htm>

DOI: <https://dx.doi.org/10.12998/wjcc.v7.i19.3062>

INTRODUCTION

Acute myocardial infarction (AMI) is characterized by chest pain as well as cardiac troponin I (cTnI) and electrocardiography (ECG) changes. Recently, clinical researchers have used the term “MINOCA” to refer to myocardial infarction with nonobstructive coronary arteries. This condition has been confirmed in several large AMI registries in which 1%-13% of AMI cases occurred in the absence of obstructive coronary artery disease (CAD), prompting clinical researchers to coin the term MINOCA. The European Society of Cardiology working group on MINOCA has produced a position paper describing the associated clinical features and mechanisms, detailing an assessment pathway for its evaluation and stimulating research into its mechanisms and treatment^[1] (Figure 1).

MINOCA has various causes. In this report, we present the case of a young patient who was first diagnosed with AMI after choledocholithiasis by endoscopic retrograde cholangiopancreatography (ERCP).

CASE PRESENTATION

Chief complaints

An 18-year-old Chinese man presented to the cardiac intensive care unit with chest

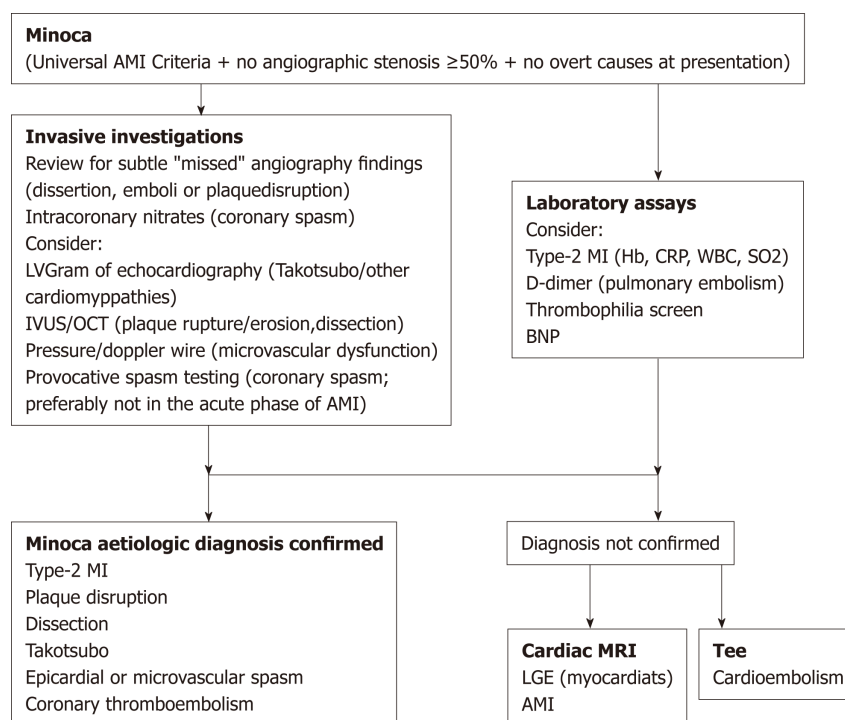


Figure 1 European Society of Cardiology working group position paper on myocardial infarction with nonobstructive coronary arteries. MINOCA: Myocardial infarction with nonobstructive coronary arteries; BNP: Brain natriuretic peptide; CRP: C-reactive protein; WBC: White blood cells; AMI: Acute myocardial infarction.

pain radiating to the left shoulder for 1 h after choledocholithiasis by ERCP and the subsequent treatment.

History of present illness

The patient had abdominal pain and bloating accompanied by nausea a week prior to his admission to the hospital.

History of past illness

The patient had been diagnosed with gallstones and cholecystitis for four years but had not accepted treatment.

Personal and family history

The young man reported no history of smoking, alcohol consumption, or use of medications. There was no personal or family history of CAD, hypertension, or obesity.

Physical examination upon admission

His temperature, heart rate, blood pressure, and body mass index were normal. His blood pressure was 130/70 mmHg symmetrically in both arms, and his pulse was 60 beats per minute. His physical examination was normal. ECG showed a sinus rhythm with ST-segment elevation in the II, III, and aVF leads compared with the baseline (Figure 2).

Laboratory examinations

The laboratory data showed cTnI levels of 67.55 ng/mL and 80 ng/mL at the peak (relative index below 0.034 ng/mL) and creatine kinase-MB (CK-MB) levels of 56 U/L and 183.6 U/L at the peak (relative index below 24 U/L). The results of his laboratory tests at baseline, including routine blood and urine tests, blood lipid and glucose levels, renal function tests, coagulation factors, and electrolytes, were within the normal ranges. His cholesterol and triglyceride levels were within the normal ranges, and his low-density lipoprotein cholesterol level was 2.23 mmol/L (normal range 2.03-3.34 mmol). Further tests after the AMI revealed nothing remarkable in the erythrocyte sedimentation rate, thyroid function, or tumour markers.

Imaging examinations

The chest X-ray and abdominal and reproductive organ ultrasound examinations were normal. His echocardiographic examination showed no obvious abnormalities

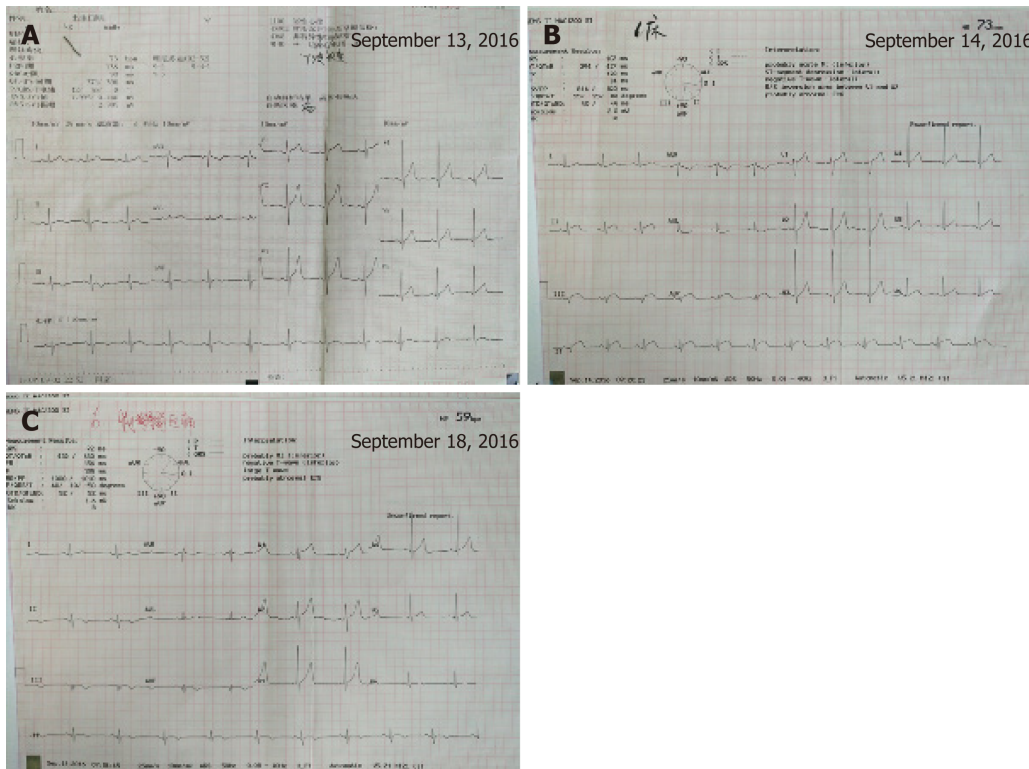


Figure 2 Changes in electrocardiography from September 13 to 18 during the acute myocardial infarction. A: Electrocardiography on September 13, 2016; B: Electrocardiography on September 14, 2016; C: Electrocardiography on September 18, 2016.

in the structure or movement of the ventricular wall and an estimated left ventricular ejection fraction of 57%.

He had been diagnosed with gallstones and cholecystitis for the previous four years. Despite the low risk of cardiovascular disease in his history, AMI was suspected, and coronary angiography was performed the second day (the chest pain stopped 1 h later and lasted for 2 h in all). The results revealed a smooth angiographic appearance of all arteries (Figure 3). The patient was transferred to the cardiac intensive care unit and treated accordingly. He received secondary preventive treatment for coronary heart disease during the following week and left the coronary care unit after all his laboratory parameters returned to within the normal ranges seven days later (Figure 4).

FINAL DIAGNOSIS

We ultimately made a diagnosis of MINOCA caused by coronary artery spasm, as it seemed to be the most suitable diagnosis for this young patient.

TREATMENT

The young man was treated with aspirin, angiotensin converting enzyme (ACE) inhibitors, and statins in hospital. He underwent treatments including ERCP, endoscopic sphincterotomy, pancreaticobiliary dilatation, removal of stones, and endoscopic nasobiliary drainage (ENBD) on the second day after his admission to the hospital, and 1.4 cm × 1.6 cm of stones were removed from his common bile duct during surgery. He received lidocaine anaesthesia in the throat during treatment, without any discomfort during or after the treatment. The results of his laboratory tests at admission revealed an alanine aminotransferase level of 459.6 U/L (normal range 9-50 U/L), aspartate aminotransferase level of 257.2 U/L (normal range 15-40 U/L), glutamyl transpeptidase level of 421.7 U/L (normal range 10-60 U/L), total bile acid level of 101.86 μmol (normal range 0-10 μmol), total bilirubin level of 182.21 μmol (normal range 5-21 μmol), direct bilirubin level of 99.10 μmol (normal range 0.2-6.0 μmol), and indirect bilirubin level of 83.1 μmol (normal range 3.4-15.5 μmol).

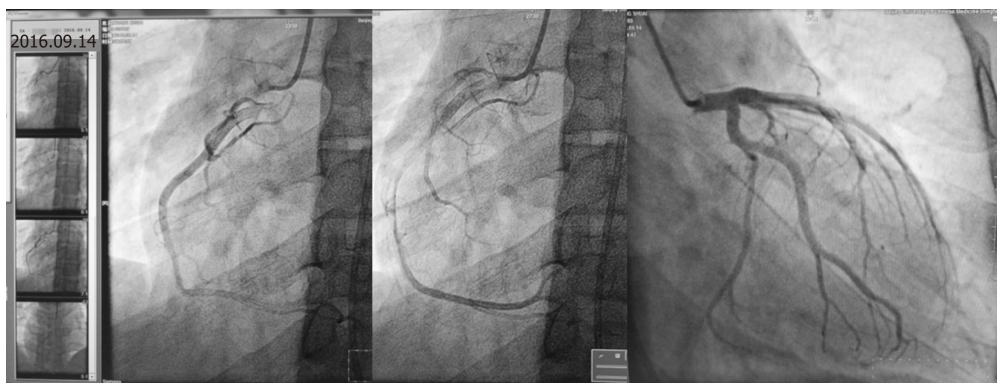


Figure 3 Results of coronary angiography.

OUTCOME AND FOLLOW-UP

We telephoned the patient two years later, and he told us that he felt normal and did not take any medicine after the third month after discharge.

DISCUSSION

The young man had no conventional risk factors for AMI, making this case unique. All common risk factors, such as smoking, hyperlipidaemia, a family history of CAD, hypertension, diabetes mellitus, and obesity, were excluded^[2,3]. More importantly, coronary angiography in this young patient did not reveal signs of occlusion, stenosis, or thrombosis, so we believe that he did not experience a classic myocardial infarction. This phenomenon has been confirmed in several large AMI registries in which 1%-13% of AMI cases occurred in the absence of obstructive CAD, prompting clinical researchers to coin the term MINOCA. The diagnostic criteria for MINOCA include: (A) The universal definition of AMI; (B) Nonobstructive coronary arteries on angiography (no stenosis $\geq 50\%$); and (C) No clinically overt cause of the acute clinical presentation^[1]. The apparent increase in cTnI in this young patient needs to be explained in the absence of a diagnosis of AMI. The potential aetiologies include coronary causes, noncoronary causes, and extracardiac disorders^[1]. The coronary angiography revealed a smooth angiographic appearance of all the arteries, and the laboratory data were nearly within the normal ranges; thus, we can exclude coronary causes and those associated with extracardiac disorders. Among all the noncoronary causes, Takotsubo cardiomyopathy and myocarditis have been reported in some cases.

This young patient had been diagnosed with gallstones and cholecystitis for four years, but we do not have evidence to confirm a relationship between AMI and common bile duct stones. His AMI occurred early during the morning following the ERCP and subsequent treatments, so we attempted to determine whether there was a relationship between the treatments and AMI. ERCP and the following treatments are primary tools for the treatment of biliary and pancreatic ductal diseases. The common adverse events are post-ERCP pancreatitis, cholangitis, post-sphincterotomy bleeding, post-sphincterotomy perforation, and sedation-related cardiopulmonary compromises. There were no related reports regarding a relationship between ERCP and AMI^[4].

In our further research, we found some case reports on AMI after ERCP and the subsequent treatments, as well as after surgery to remove gallstones. One case was an 85-year-old woman who was admitted for obstructive jaundice and underwent ERCP, ENBD, and then surgery for common bile duct stones; that patient experienced Takotsubo cardiomyopathy after the surgery^[5]. The other case was an 86-year-old woman diagnosed with Takotsubo cardiomyopathy following cholecystectomy at Mayo Clinic, which was the second case of Takotsubo cardiomyopathy reported to be associated with cholecystectomy^[6]. One case-review series reported patients with Takotsubo cardiomyopathy. The syndrome more often affects postmenopausal women (82% to 100%; mean age, 62 to 75 years). Patients commonly present with ST-segment elevation in the precordial leads, chest pain, relatively minor elevation of cardiac enzyme and biomarker levels, and transient apical systolic left ventricular dysfunction despite the absence of obstructive epicardial coronary disease^[7]. In our young patient, his echocardiographic and ECG examinations did not show changes

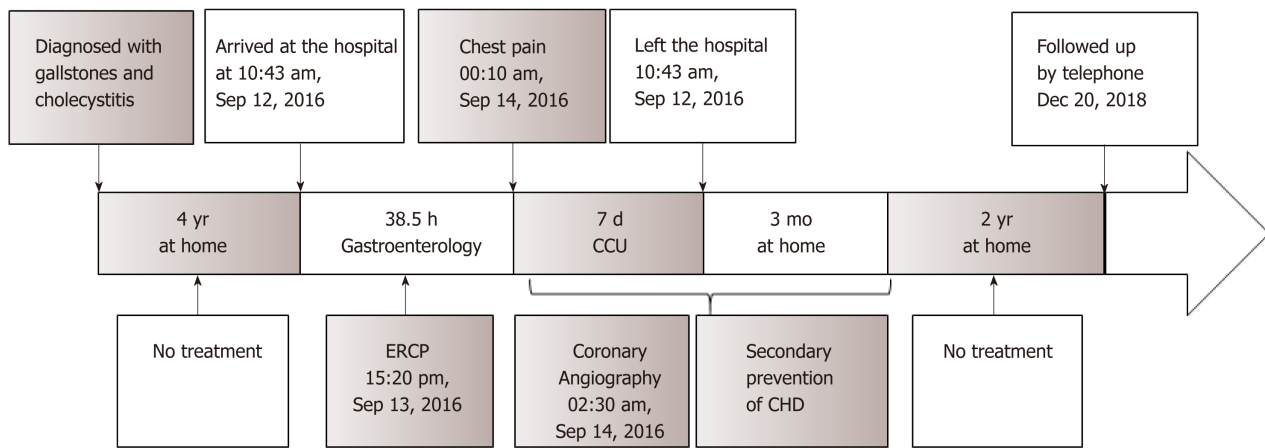


Figure 4 Timeline of the patient. CCU: Coronary care unit; CHD: Coronary heart disease; ERCP: Endoscopic retrograde cholangiopancreatography.

typical of Takotsubo cardiomyopathy or myocarditis. Therefore, we did not diagnose him with either of those conditions.

The patient's heart attack occurred at midnight, so we should consider coronary artery spasm. Coronary artery spasm may potentially contribute to the pathogenesis of AMI in patients with obstructive CAD and particularly warrants close consideration in those with MINOCA. A diagnosis of vasospastic angina can be made if spontaneous episodes of resting angina are associated with ST-segment changes that respond promptly to short-acting nitrates. However, provocative spasm testing should generally be avoided in the acute phase of AMI. Another reason might be coronary thromboembolism, which may be a contributory mechanism underlying AMI in the context of plaque disruption or coronary artery spasm or may be the cause of MI in the absence of these factors. Coronary emboli may occur as a result of iatrogenic air emboli^[1]. However, coronary thromboembolism has not been reported with ERCP treatments, making this aetiology unlikely^[4].

CONCLUSION

We ultimately made a diagnosis of MINOCA caused by coronary artery spasm, as it seemed to be the most suitable diagnosis for this young patient. A coronary artery spasm usually leads to changes in the ECG, and we observed ST-segment elevations in the II, III, and aVF leads during the angina. However, we still have some questions that could not be resolved. The chest pain lasted for two hours, but what caused the elevations in cTnI and CK-MB? If the myocardium was severely injured, why could we not observe that on echocardiography? We telephoned the patient two years later, and he told us that he felt normal and did not take any medicine after the third month after discharge. There are small trials that suggest the benefit of aspirin, ACE inhibitors, and statins, but there is a lack of appropriately designed clinical outcome trials to inform management decisions. The management and treatment of MINOCA patients should follow the cause of AMI in each individual case. Further studies are still needed to unravel the underlying pathophysiology.

REFERENCES

- 1 Agewall S, Beltrame JF, Reynolds HR, Niessner A, Rosano G, Caforio AL, De Caterina R, Zimarino M, Roffi M, Kjeldsen K, Atar D, Kaski JC, Sechtem U, Tornvall P; WG on Cardiovascular Pharmacotherapy. ESC working group position paper on myocardial infarction with non-obstructive coronary arteries. *Eur Heart J* 2017; **38**: 143-153 [PMID: 28158518 DOI: 10.1093/eurheartj/ehw149]
- 2 Huang J, Qian HY, Li ZZ, Zhang JM. Comparison of clinical features and outcomes of patients with acute myocardial infarction younger than 35 years with those older than 65 years. *Am J Med Sci* 2013; **346**: 52-55 [PMID: 23328834 DOI: 10.1097/MAJ.0b013e318265e33e]
- 3 Wong CP, Loh SY, Loh KK, Ong PJ, Foo D, Ho HH. Acute myocardial infarction: Clinical features and outcomes in young adults in Singapore. *World J Cardiol* 2012; **4**: 206-210 [PMID: 22761974 DOI: 10.4330/wjc.v4.i6.206]
- 4 Chavalitdhamrong D, Donepudi S, Pu L, Draganov PV. Uncommon and rarely reported adverse events of endoscopic retrograde cholangiopancreatography. *Dig Endosc* 2014; **26**: 15-22 [PMID: 24118211 DOI: 10.1053/j.gie.2014.03.011]

- 10.1111/den.12178]
- 5 **Tori M**, Ueshima S, Nakahara M. A case of takotsubo cardiomyopathy after surgery for common bile duct stones. *Case Rep Gastroenterol* 2008; **2**: 91-95 [PMID: [21490845](#) DOI: [10.1159/000118799](#)]
 - 6 **Jensen JB**, Malouf JF. Takotsubo cardiomyopathy following cholecystectomy: a poorly recognized cause of acute reversible left ventricular dysfunction. *Int J Cardiol* 2006; **106**: 390-391 [PMID: [16337048](#) DOI: [10.1016/j.ijcard.2004.11.040](#)]
 - 7 **Bybee KA**, Kara T, Prasad A, Lerman A, Barsness GW, Wright RS, Rihal CS. Systematic review: transient left ventricular apical ballooning: a syndrome that mimics ST-segment elevation myocardial infarction. *Ann Intern Med* 2004; **141**: 858-865 [PMID: [15583228](#) DOI: [10.7326/0003-4819-141-11-200412070-00010](#)]



Published By Baishideng Publishing Group Inc
7041 Koll Center Parkway, Suite 160, Pleasanton, CA 94566, USA
Telephone: +1-925-2238242
E-mail: bpgoffice@wjgnet.com
Help Desk: <https://www.f6publishing.com/helpdesk>
<https://www.wjgnet.com>

