

Sphincterotomy by triple lumen needle knife using guide wire in patients with Billroth II gastrectomy

Su Bum Park, Hyung Wook Kim, Dae Hwan Kang, Cheol Woong Choi, Ki Tae Yoon, Mong Cho, Byeong Jun Song

Su Bum Park, Hyung Wook Kim, Dae Hwan Kang, Cheol Woong Choi, Ki Tae Yoon, Mong Cho, Byeong Jun Song, Department of Internal Medicine, Pusan National University School of Medicine and Research Institute for Convergence of Biomedical Science and Technology, Pusan National University Yangsan Hospital, Yangsan-si, Gyeongsangnam-do 626-770, South Korea

Author contributions: Park SB and Kim HW contributed equally to this work; Kim HW performed the procedures; Kang DH and Choi CW designed the research; Park SB, Yoon KT, Cho M, and Song BJ analyzed data; Park SB and Kim HW wrote the paper.

Correspondence to: Hyung Wook Kim, MD, PhD, Department of Internal Medicine, Pusan National University School of Medicine and Research Institute for Convergence of Biomedical Science and Technology, Pusan National University Yangsan Hospital, Beomeo-ri, Mulgeum-eup, Yangsan-si, Gyeongsangnam-do 626-770, South Korea. mdkhwook@gmail.com
Telephone: +82-55-3601534 Fax: +82-55-3601536

Received: July 29, 2013 Revised: October 5, 2013

Accepted: November 3, 2013

Published online: December 28, 2013

Abstract

AIM: To investigate the usefulness of a guide wire and triple lumen needle knife for removing stones in Billroth II (B-II) gastrectomy patients.

METHODS: Endoscopic sphincterotomy in patients with B-II gastrectomy is challenging. We used a new guide wire technique involving sphincterotomy by triple lumen needle knife through a forward-viewing endoscopy. This technique was performed in nine patients between August 2010 and June 2012. Sphincterotomy as described above was performed. Adequate sphincterotomy, successful stone removal, and complications were investigated prospectively.

RESULTS: Sphincterotomy by triple lumen needle knife using guide wire was successful in all nine patients. Sphincterotomy started towards the 4-5 o'clock direction

and continued to the upper margin of the papillary roof. Complete stone removal in one session was achieved in all patients. There were no procedure related complications, such as bleeding, pancreatitis, or perforation.

CONCLUSION: In patients with B-II gastrectomy, guide wire using sphincterotomy by triple lumen needle knife through a forward-viewing endoscopy seems to be an effective and safe procedure for the removal of common bile duct stones.

© 2013 Baishideng Publishing Group Co., Limited. All rights reserved.

Key words: Billroth II gastrectomy; Endoscopic sphincterotomy; Forward-viewing endoscopy; Guide wire; Triple lumen needle knife

Core tip: Guide wire using sphincterotomy by triple lumen needle knife through a forward-viewing endoscopy seems to be a safe, easy, and effective method for removing common bile duct stones in patients with B-II gastrectomy.

Park SB, Kim HW, Kang DH, Choi CW, Yoon KT, Cho M, Song BJ. Sphincterotomy by triple lumen needle knife using guide wire in patients with Billroth II gastrectomy. *World J Gastroenterol* 2013; 19(48): 9405-9409 Available from: URL: <http://www.wjgnet.com/1007-9327/full/v19/i48/9405.htm> DOI: <http://dx.doi.org/10.3748/wjg.v19.i48.9405>

INTRODUCTION

Endoscopic sphincterotomy (EST) is essential for the endoscopic removal of common bile duct (CBD) stones. However, EST is more difficult in an altered anatomy, such as Billroth II (B-II) gastrectomy, in which the major papillae are inverted^[1]. To overcome this problem, several techniques

and specialized accessories have been devised, including Soehendra sphincterotome^[2], Sohma sphincterotome^[3], needle knife sphincterotomy guided by a biliary endoprosthesis^[4,5], S-shape sphincterotome^[6], and papillary balloon dilation^[7,8]. These methods may be more difficult to control and frequently produce complications^[5-7].

Large balloon papillary dilation after minor EST with newly developed papillotomes, such as rotatable papillotome^[9] and scissors papillotome^[10], has been reported for the removal of CBD stones in B-II gastrectomy. The triple lumen needle knife, which is capable of accepting a guidewire in one channel while simultaneously injecting and/or cutting in other lumens, is used primarily for pre-cut sphincterotomy or fistulotomy in difficult cases of deep cannulation of the bile duct. These characteristics allow the simultaneous maintenance of the guide wire in CBD and sphincterotomy without the assistance of other accessories. Additionally, a guide wire positioned in the CBD can make sphincterotomy by triple lumen needle knife easier.

Herein, we detail our technique and present experiences of guide wire sphincterotomy using a triple lumen needle knife through forward-viewing endoscopy in patients with B-II gastrectomy.

MATERIALS AND METHODS

Patients

From August 2010 to June 2012, endoscopic retrograde cholangiopancreatography (ERCP) for removal of CBD stones was performed on 469 patients. Of these patients, 20 with B-II gastrectomy underwent ERCP. Eleven patients who had previous EST procedures ($n = 5$), failure to reach major papilla ($n = 4$), and needle knife fistulotomy due to difficult cannulation ($n = 2$) were excluded. The remaining nine patients (6 men and 3 women; mean age 66.3 years) were enrolled. The same endoscopist performed all procedures. All patients provided written informed consent for their participation and the study was approved by the Institutional Review Board of Pusan National University Yansan Hospital.

Technique

All ERCP procedures were performed under conscious sedation and coverage using prophylactic antibiotics with a model GIF-H260 cap-attached forward-viewing endoscopy apparatus (Olympus Optical, Tokyo, Japan). A transparent cap (Distal Attachments D-201-11804; Olympus) was attached to the tip of the endoscope. Selective cannulation of the CBD was achieved using a cannulation catheter with a straight tip. A 0.025-inch guide wire (Jagwire; Boston Scientific, Natick, MA) was advanced through the catheter into the CBD. The catheter was then removed, and a triple lumen needle knife (Microknife™ XL; Boston Scientific) was introduced into the major papilla over the guide wire. The needle tip was controlled with a length of 2-3 mm (Figure 1A), and sphincterotomy was performed along the guide wire

as a guidance mark directed at 4-5 o'clock with sophisticated maneuver of the needle knife and endoscopy (Figure 1B). The model PSD-30 electrosurgical unit (Olympus) was used at a setting of blended one current with a power setting of 30 W/s for both the cutting and coagulation currents (cut: coagulation ratio of 3:1). During sphincterotomy, the pattern of cutting in the current method closely resembles the action of a pair of cutting scissors. Although the direction of the needle tip was toward the 1-2 o'clock direction, sphincterotomy toward the 4-5 o'clock direction was possible because the guide wire acted as a guide when the needle knife approached the bile duct pathway. At this time, the cap enabled us to perform safe and effective sphincterotomy by keeping a visual field during the procedure. After sphincterotomy to the upper margin of the papillary roof (Figure 1C), a stone retrieval basket or balloon catheter was used to extract CBD stones (Figure 1D). In cases when EST was insufficient in extracting the stone, papillary balloon dilation or mechanical lithotripsy was used in an attempt to remove the stone. To assess the efficacy and safety of this technique, we evaluated the sphincterotomy of the desired direction, use of balloon dilation or mechanical lithotripsy, successful stone removal, and complications after ERCP.

RESULTS

ERCP with B-II gastrectomy was performed in 20 patients by the same endoscopist. Nine patients (6 men and 3 women) underwent EST using a guide wire and triple lumen needle knife sphincterotomy. The mean age of patients was 66.3 (range, 56-85) years. The mean size and number of stones were 7.89 (range, 5-12) and 1.78 (range, 1-4) mm, respectively (Table 1).

Sphincterotomy in the 4-5 o'clock direction and to the upper margin of the papillary roof were successful in all nine patients (100%). Complete endoscopic stone removal was achieved in a single session in all patients. Papillary balloon dilatation was performed in only one patient owing to the large CBD stones (12 mm diameter) and stenosis in the distal CBD they exhibited. No mechanical lithotripsy was performed in any patient (Table 1). Serum amylase and lipase were measured before and after the procedure (4 and 24 h, respectively). Complete blood count and a liver function test were performed the morning after the procedure. There were no complications, such as bleeding, pancreatitis, or perforation.

DISCUSSION

Diagnostic and therapeutic ERCP in patients with B-II gastrectomy can be hindered by difficulties in the identification and intubation of the afferent loop, negotiation of abrupt turns in the afferent loop, cannulation, and adequate sphincterotomy of papilla due to inverted position^[11-14]. In particular, the standard pull-type sphincterotome cannot cut toward the 6 o'clock position^[15,16]. To

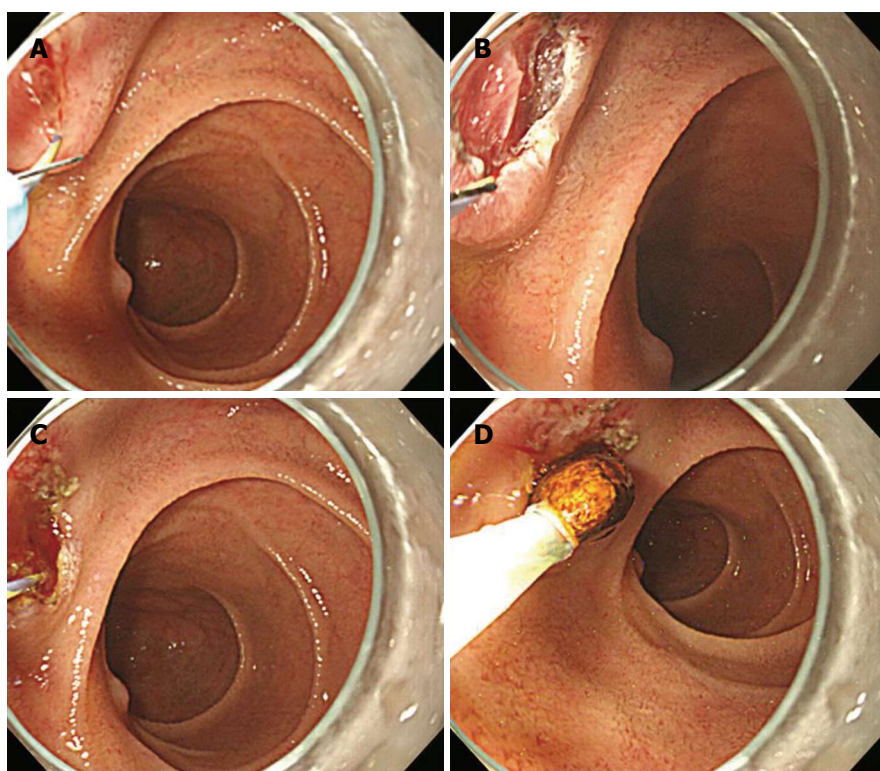


Figure 1 Guide wire using sphincterotomy by triple lumen needle knife. A: A triple lumen needle knife was introduced into the major papilla over the guidewire and the tip of needle was then controlled with 2-3 mm length; B: Sphincterotomy was performed along the guide wire as a guidance mark directed in the 4-5 o'clock direction with sophisticated maneuver of needle knife and endoscopy; C: Sphincterotomy to the upper margin of the papillary roof was performed; D: A stone was removed by basket without balloon dilation or mechanical lithotripsy.

Table 1 Baseline characteristics of patients and treatment outcomes

Patient No.	Age (yr)	Sex	Stone		Procedure sessions	Balloon dilation (size, mm)	Stone removal	Complications
			Size, mm	No.				
1	63	F	12	4	1	12	Success	None
2	69	M	5	2	1	0	Success	None
3	56	M	6	2	1	0	Success	None
4	68	F	10	2	1	0	Success	None
5	67	M	5	1	1	0	Success	None
6	65	M	8	1	1	0	Success	None
7	65	M	10	1	1	0	Success	None
8	59	F	10	2	1	0	Success	None
9	85	M	5	1	1	0	Success	None

overcome this problem, several devices and techniques have been developed using the push-type papillotome, such as the Sohma^[3] and Soehendra sphincterotomes^[2]. These refinements allow proper orientation of the wire for the CBD and needle knife with guided techniques using a nasobiliary drain^[17], cannula, or endoprosthesis^[5]. However, effective push-type sphincterotomes or needle knives are, as yet, not as readily available as the standard pull-type sphincterotome.

Recently devised methods to resolve these problems rely on large balloon papillary dilation after minor EST with newly developed papillotomes^[18-21], such as the rotatable papillotome^[9] and scissors papillotome^[10]. These methods are user-friendly, but difficult to use in performing major EST.

Another problem is the difficulty of handling the side-viewing duodenoscope through the afferent loop in a retrograde maneuver; the result is a high rate of failed procedures and serious complications that include perforation of the small bowel^[22-24]. The side-viewing duodenoscope has the advantages of allowing an en-face view of papilla and an elevator to adjust the direction of accessories. However, the apparatus is not useful in B-II anastomosis and increases the risk of perforation while passing the tortuous jejunum^[14] and in cases of previous jejunal enteroanastomosis (Braun's anastomosis)^[25].

This method contrasts with existing methods in three ways. First, a triple lumen needle knife was used instead of a push-type sphincterotome or rotatable papillotome. The obvious advantage of this knife is the simultaneous

use of the needle knife and guide wire through the same device, which provides an indication of where and how deeply to cut, as well as avoiding blind or inappropriate cutting under direct vision of the cutting device and the presence of a clear guide. This enables a large sphincterotomy that can still be safely performed even when done by a less experienced endoscopist. Actually, sphincterotomy in all patients reached the upper margin of the papillary roof and most CBD stones were removed without papillary balloon dilatation or mechanical lithotripsy, although most were small. These findings clearly showed different results compared with other studies^[9,10]. In the current study, papillary large balloon dilation was performed in one patient as a rescue method due to a large CBD stone and distal CBD stricture, but mechanical lithotripsy was not necessary. Additionally, bleeding, pancreatitis and perforation after sphincterotomy did not occur in all patients.

Secondly, conventional guide wire was used instead of nasobiliary drain, a cannula, or endoprosthesis. A guide wire already inserted in the bile duct can reduce the time of removal and subsequent reintroduction of the endoscope or insertion of a plastic stent. Also, this technique is cost-effective compared with endoprosthesis-guided sphincterotomy using a plastic stent, as a guide wire permits directed movement in the bile duct and control of the depth of incision, similar to the role of a plastic stent in endoprosthesis-guided sphincterotomy.

Thirdly, a forward-viewing endoscope was used instead of the side-viewing version. The forward-viewing endoscope in patients with Billroth II gastrectomy makes selective bile duct cannulation easier, as the endoscope and cannula are in line with the CBD^[13,26]. Therefore, the lack of an elevator in forward-viewing endoscopes is only a slight disadvantage, and not a major factor in determining the success rate of cannulation and subsequent procedure. Also, a forward-viewing endoscope makes it easier to introduce the afferent loop and find the correct route, as well as making it easier to control for negotiating the acute angles of the anastomoses than side-viewing endoscope. These advantages were related with low complication rates in another study^[14], and no complications, such as perforation, were noted in the current study.

Despite the several advantages of the current method, some problems remain. If the endoscopic approach to major papilla is difficult, biliary cannulation and sphincterotomy are also difficult. Therefore, for effective application of this technique, the endoscopy tip must be approached near the major papilla.

In patients with B-II gastrectomy, we do not yet know which type of sphincterotomy is superior. The several techniques and accessories each have their own drawbacks. Currently, treatment strategy guided by personal preference or level of experience with specific techniques may be necessary. Our results support the use of the guide wire and triple lumen needle knife technique previously described as one option in patients with B-II gastrectomy. The technique is especially attractive when less experienced endoscopists perform sphincterotomy in patients with B-II gastrectomy.

In conclusion, guide wire using sphincterotomy by triple

lumen needle knife through a forward-viewing endoscopy seems to be a safe, easy, and effective method for removing CBD stones in patients with B-II gastrectomy. Further studies may be needed to compare the safety and efficacy of the technique in order to confirm our findings.

COMMENTS

Background

Endoscopic sphincterotomy is more difficult in an altered anatomy; the authors suggested a new technique by guide wire and triple lumen needle knife.

Research frontiers

Recently introduced methods have their limitations due to their difficulty in being controlled. Guide wire technique involving sphincterotomy by triple lumen needle knife through a forward-viewing endoscopy can be used more easily.

Innovations and breakthroughs

The authors demonstrated the effectiveness and safety of removing common bile duct (CBD) stones in patients with Billroth II (B-II) gastrectomy, although those that were removed were small in size.

Applications

Guide wire using sphincterotomy by triple lumen needle knife through a forward-viewing endoscopy are a feasible and effective intervention for removing CBD stones in patients with B-II gastrectomy.

Peer review

This is a clinical study to evaluate the efficiency of a new technique for removing common bile duct stones in patients with gastrectomy. This is an important and novel topic in clinics.

REFERENCES

- 1 Al-Kawas FH, Geller AJ. A new approach to sphincterotomy in patients with Billroth II gastrectomy. *Gastrointest Endosc* 1996; **43**: 253-255 [PMID: 8857146 DOI: 10.1016/S0016-5107(96)70328-0]
- 2 Soehendra N, Kempeneers I, Reynders-Frederix V. [A new papillotomy for the Billroth II stomach]. *Dtsch Med Wochenschr* 1980; **105**: 362-363 [PMID: 7363771]
- 3 Rosseland AR, Osnes M, Kruse A. Endoscopic sphincterotomy (EST) in patients with Billroth II Gastrectomy. *Endoscopy* 1981; **13**: 19-24 [PMID: 7460864 DOI: 10.1055/s-2007-1021635]
- 4 Siegel JH, Cohen SA, Kasmin FE, Veerappan A. Stent-guided sphincterotomy. *Gastrointest Endosc* 1994; **40**: 567-572 [PMID: 7988820 DOI: 10.1016/S0016-5107(94)70254-3]
- 5 van Buuren HR, Boender J, Nix GA, van Blankenstein M. Needle-knife sphincterotomy guided by a biliary endoprosthesis in Billroth II gastrectomy patients. *Endoscopy* 1995; **27**: 229-232 [PMID: 7664700 DOI: 10.1055/s-2007-1005676]
- 6 Hintze RE, Veltzke W, Adler A, Abou-Rebyeh H. Endoscopic sphincterotomy using an S-shaped sphincterotome in patients with a Billroth II or Roux-en-Y gastrojejunostomy. *Endoscopy* 1997; **29**: 74-78 [PMID: 9101142 DOI: 10.1055/s-2007-1004078]
- 7 Bergman JJ, van Berkel AM, Bruno MJ, Fockens P, Rauws EA, Tijssen JG, Tytgat GN, Huibregtse K. A randomized trial of endoscopic balloon dilation and endoscopic sphincterotomy for removal of bile duct stones in patients with a prior Billroth II gastrectomy. *Gastrointest Endosc* 2001; **53**: 19-26 [PMID: 11154484 DOI: 10.1067/mge.2001.110454]
- 8 Jang HW, Lee KJ, Jung MJ, Jung JW, Park JY, Park SW, Song SY, Chung JB, Bang S. Endoscopic papillary large balloon dilatation alone is safe and effective for the treatment of difficult choledocholithiasis in cases of Billroth II gastrectomy: a single center experience. *Dig Dis Sci* 2013; **58**: 1737-1743 [PMID: 23392745 DOI: 10.1007/s10620-013-2580-6]
- 9 Kim GH, Kang DH, Song GA, Heo J, Park CH, Ha TI, Kim KY, Lee HJ, Kim ID, Choi SH, Song CS. Endoscopic removal of bile-duct stones by using a rotatable papillotome and a large-balloon dilator in patients with a Billroth II gastrectomy (with video). *Gastrointest Endosc* 2008; **67**: 1134-1138 [PMID: 18407269]

- DOI: 10.1016/j.gie.2007.12.016]
- 10 **Choi HJ**, Moon JH, Ko BM, Kim YJ, Cheon YK, Cho YD, Lee MS, Shim CS. Endoscopic stone removal using a scissors papillotome followed by papillary balloon dilation in patients with Billroth II gastrectomy - a case series. *Endoscopy* 2009; **41**: 993-996 [PMID: 19866399 DOI: 10.1055/s-0029-1215126]
 - 11 **Lin LF**, Siau CP, Ho KS, Tung JC. ERCP in post-Billroth II gastrectomy patients: emphasis on technique. *Am J Gastroenterol* 1999; **94**: 144-148 [PMID: 9934745 DOI: 10.1016/S0002-9270(98)00666-2]
 - 12 **Dolay K**, Soylu A. Easy sphincterotomy in patients with Billroth II gastrectomy: a new technique. *Turk J Gastroenterol* 2008; **19**: 109-113 [PMID: 19110666]
 - 13 **Safrany L**, Neuhaus B, Portocarrero G, Krause S. Endoscopic sphincterotomy in patients with Billroth II gastrectomy. *Endoscopy* 1980; **12**: 16-22 [PMID: 7353556 DOI: 10.1055/s-2007-1021704]
 - 14 **Kim MH**, Lee SK, Lee MH, Myung SJ, Yoo BM, Seo DW, Min YI. Endoscopic retrograde cholangiopancreatography and needle-knife sphincterotomy in patients with Billroth II gastrectomy: a comparative study of the forward-viewing endoscope and the side-viewing duodenoscope. *Endoscopy* 1997; **29**: 82-85 [PMID: 9101144 DOI: 10.1055/s-2007-1004080]
 - 15 **Park CH**, Lee WS, Joo YE, Kim HS, Choi SK, Rew JS. Cap-assisted ERCP in patients with a Billroth II gastrectomy. *Gastrointest Endosc* 2007; **66**: 612-615 [PMID: 17725957 DOI: 10.1016/j.gie.2007.04.024]
 - 16 **Lee TH**, Hwang JC, Choi HJ, Moon JH, Cho YD, Yoo BM, Park SH, Kim JH, Kim SJ. One-Step Transpapillary Balloon Dilation under Cap-Fitted Endoscopy without a Preceding Sphincterotomy for the Removal of Bile Duct Stones in Billroth II Gastrectomy. *Gut Liver* 2012; **6**: 113-117 [PMID: 22375180 DOI: 10.5009/gnl.2012.6.1.113]
 - 17 **Ricci E**, Berton G, Conigliaro R, Contini S, Mortilla MG, Bedogni G. Endoscopic sphincterotomy in Billroth II patients: an improved method using a diathermic needle as sphincterotome and a nasobiliary drain as guide. *Gastrointest Endosc* 1989; **35**: 47-50 [PMID: 2920885 DOI: 10.1016/S0016-5107(89)72686-9]
 - 18 **Itoi T**, Sofuni A, Itokawa F. Large dilating balloon to allow endoscope insertion for successful endoscopic retrograde cholangiopancreatography in patients with surgically altered anatomy (with video). *J Hepatobiliary Pancreat Sci* 2010; **17**: 725-728 [PMID: 20458504 DOI: 10.1007/s00534-010-0291-3]
 - 19 **Itoi T**, Ishii K, Itokawa F, Kurihara T, Sofuni A. Large balloon papillary dilation for removal of bile duct stones in patients who have undergone a billroth ii gastrectomy. *Dig Endosc* 2010; **22** Suppl 1: S98-S102 [PMID: 20590782 DOI: 10.1111/j.1443-1661.2010.00955.x]
 - 20 **Park SY**, Park CH, Yoon KW, Cho SB, Lee WS, Joo YE, Kim HS, Choi SK, Rew JS. Endoscopic large-diameter balloon dilation after fistulotomy for the removal of bile duct stones in a difficult cannulation. *Gastrointest Endosc* 2009; **69**: 955-959 [PMID: 19327486 DOI: 10.1016/j.gie.2008.12.048]
 - 21 **Choi CW**, Choi JS, Kang DH, Kim BG, Kim HW, Park SB, Yoon KT, Cho M. Endoscopic papillary large balloon dilation in Billroth II gastrectomy patients with bile duct stones. *J Gastroenterol Hepatol* 2012; **27**: 256-260 [PMID: 21793902 DOI: 10.1111/j.1440-1746.2011.06863.x]
 - 22 **Gregg A**, Schaal HJ, Müller I, Peiper HJ. [Mammography in the diagnosis and treatment of non-puerperal mastitis (author's transl)]. *Rofo* 1979; **130**: 342-347 [PMID: 155579]
 - 23 **Wilkinson ML**, Engelman JL, Hanson PJ. Intestinal perforation after ERCP in Billroth II partial gastrectomy. *Gastrointest Endosc* 1994; **40**: 389-390 [PMID: 8056259]
 - 24 **Faylona JM**, Qadir A, Chan AC, Lau JY, Chung SC. Small-bowel perforations related to endoscopic retrograde cholangiopancreatography (ERCP) in patients with Billroth II gastrectomy. *Endoscopy* 1999; **31**: 546-549 [PMID: 10533739 DOI: 10.1055/s-1999-61]
 - 25 **Osnes M**, Rosseland AR, Aabakken L. Endoscopic retrograde cholangiography and endoscopic papillotomy in patients with a previous Billroth-II resection. *Gut* 1986; **27**: 1193-1198 [PMID: 3781333 DOI: 10.1136/gut.27.10.1193]
 - 26 **Fujita K**, Myojo S, Yoshida S, Kawase Y. Endoscopic sphincterotomy using a pull-type sphincterotome with an attached stabilizer in patients with Billroth II gastrectomy. *Endoscopy* 2011; **43** Suppl 2 UCTN: E47-E48 [PMID: 21287447 DOI: 10.1055/s-0030-1256082]

P- Reviewers: Csendes A, Jawad MA, Wang Z

S- Editor: Zhai HH **L- Editor:** Rutherford A **E- Editor:** Liu XM





Published by **Baishideng Publishing Group Co., Limited**
Flat C, 23/F., Lucky Plaza,
315-321 Lockhart Road, Wan Chai, Hong Kong, China
Fax: +852-65557188
Telephone: +852-31779906
E-mail: bpgoffice@wjgnet.com
<http://www.wjgnet.com>



ISSN 1007-9327



9 771007 932045