

World Journal of *Clinical Cases*

World J Clin Cases 2019 September 6; 7(17): 2413-2657





MINIREVIEWS

- 2413** Multifocal G1-G2 gastric neuroendocrine tumors: Differentiating between Type I, II and III, a clinicopathologic review
Algashaamy K, Garcia-Buitrago M
- 2420** Attention deficit hyperactivity disorder and comorbidity: A review of literature
Gnanavel S, Sharma P, Kaushal P, Hussain S

ORIGINAL ARTICLE

Case Control Study

- 2427** Dietary manipulation and testosterone replacement therapy may explain changes in body composition after spinal cord injury: A retrospective case report
Gorgey AS, Lester RM, Ghatas MP, Sistrun SN, Lavis T

Retrospective Study

- 2438** Risk factors, clinical features, and short-term prognosis of spontaneous fungal peritonitis in cirrhosis: A matched case-control study
Huang CH, Pang LT, Xu LC, Ge TT, Xu QM, Chen Z
- 2450** Incidence of portal vein thrombosis after splenectomy and its influence on transjugular intrahepatic portosystemic shunt stent patency
Dong F, Luo SH, Zheng LJ, Chu JG, Huang H, Zhang XQ, Yao KC

Observational Study

- 2463** Multiplex gene expression profile in inflamed mucosa of patients with Crohn's disease ileal localization: A pilot study
Giudici F, Lombardelli L, Russo E, Cavalli T, Zambonin D, Logiodice F, Kullolli O, Giusti L, Bargellini T, Fazi M, Biancone L, Scaringi S, Clemente AM, Perissi E, Delfino G, Torcia MG, Ficari F, Tonelli F, Piccinni MP, Malentacchi C

Prospective Study

- 2477** Analysis of the postoperative hemostatic profile of colorectal cancer patients subjected to liver metastasis resection surgery
Perez Navarro G, Pascual Bellosta AM, Ortega Lucea SM, Serradilla Martín M, Ramirez Rodriguez JM, Martinez Ubieta J

SYSTEMATIC REVIEW

- 2487** Systematic review of ablative therapy for the treatment of renal allograft neoplasms
Favi E, Raison N, Ambrogi F, Delbue S, Clementi MC, Lamperti L, Perego M, Bischeri M, Ferraresso M

CASE REPORT

- 2505** Subcutaneous sarcoidosis of the upper and lower extremities: A case report and review of the literature
Mehrzaad R, Festa J, Bhatt R
- 2513** Atypical cutaneous lesions in advanced-stage Hodgkin lymphoma: A case report
Massaro F, Ferrari A, Zendri E, Zanelli M, Merli F
- 2519** Characteristics of multiple nodules in a patient with pulmonary Langerhans cell histiocytosis: A case report
Kanaji N, Tokunaga Y, Ishikawa R, Watanabe N, Kadowaki N
- 2526** Impact of continuous local lavage on pancreatic juice-related postoperative complications: Three case reports
Hori T, Ogawa K, Yamamoto H, Harada H, Matsumura K, Yamamoto M, Yamada M, Yazawa T, Kuriyama K, Tani M, Yasukawa D, Kamada Y, Aisu Y, Tani R, Aoyama R, Nakayama S, Sasaki Y, Nishimoto K, Zaima M
- 2536** Adult intussusception caused by colonic anisakis: A case report
Choi YI, Park DK, Cho HY, Choi SJ, Chung JW, Kim KO, Kwon KA, Kim YJ
- 2542** Robotic-assisted resection of ovarian tumors in children: A case report and review of literature
Xie XX, Wang N, Wang ZH, Zhu YY, Wang JR, Wang XQ
- 2549** Synovial sarcoma in the plantar region: A case report and literature review
Gao J, Yuan YS, Liu T, Lv HR, Xu HL
- 2556** Severe serous cavity bleeding caused by acquired factor V deficiency associated with lymphatic leakage in a hemodialysis patient: A case report
Zhao WB, Chen YR, Luo D, Lin HC, Long B, Wu ZY, Peng H
- 2562** Supermicrosurgery in fingertip defects-split tibial flap of the second toe to reconstruct multiple fingertip defects: A case report
Wang KL, Zhang ZQ, Buckwalter JA, Yang Y
- 2567** Ultrasound-guided fascia iliaca compartment block combined with general anesthesia for amputation in an acute myocardial infarction patient after percutaneous coronary intervention: A case report
Ling C, Liu XQ, Li YQ, Wen XJ, Hu XD, Yang K
- 2573** Rare spontaneous intrahepatic portosystemic shunt in hepatitis B-induced cirrhosis: A case report
Tan YW, Sheng JH, Tan HY, Sun L, Yin YM
- 2580** Imaging of mixed epithelial and stromal tumor of the kidney: A case report and review of the literature
Ye J, Xu Q, Zheng J, Wang SA, Wu YW, Cai JH, Yuan H
- 2587** Allogenic tooth transplantation using 3D printing: A case report and review of the literature
Xu HD, Miron RJ, Zhang XX, Zhang YF

- 2597** Fecal microbiota transplantation as an effective initial therapy for pancreatitis complicated with severe *Clostridium difficile* infection: A case report
Hu Y, Xiao HY, He C, Lv NH, Zhu L
- 2605** Organ-associated pseudosarcomatous myofibroblastic proliferation with ossification in the lower pole of the kidney mimicking renal pelvic carcinoma: A case report
Zhai TY, Luo BJ, Jia ZK, Zhang ZG, Li X, Li H, Yang JJ
- 2611** Treating aplasia cutis congenita in a newborn with the combination of ionic silver dressing and moist exposed burn ointment: A case report
Lei GF, Zhang JP, Wang XB, You XL, Gao JY, Li XM, Chen ML, Ning XQ, Sun JL
- 2617** Cause of postprandial vomiting - a giant retroperitoneal ganglioneuroma enclosing large blood vessels: A case report
Zheng X, Luo L, Han FG
- 2623** Carcinoma ex pleomorphic adenoma of the trachea: A case report
Gao HX, Li Q, Chang WL, Zhang YL, Wang XZ, Zou XX
- 2630** Wilson disease associated with immune thrombocytopenia: A case report and review of the literature
Ma TJ, Sun GL, Yao F, Yang ZL
- 2637** Calcifying fibrous tumor of the mediastinum: A case report
Qi DJ, Zhang QF
- 2644** Brachiocephalic artery stenting through the carotid artery: A case report and review of the literature
Xu F, Wang F, Liu YS
- 2652** An extremely rare pedunculated lipoma of the hypopharynx: A case report
Sun Q, Zhang CL, Liu ZH

ABOUT COVER

Editorial Board Member of *World Journal of Clinical Cases*, Marianna Luongo, MD, Doctor, Surgeon, Department of Neurosurgery, Azienda Ospedaliera Regionale San Carlo, Potenza 85100, Italy

AIMS AND SCOPE

The primary aim of *World Journal of Clinical Cases* (WJCC, *World J Clin Cases*) is to provide scholars and readers from various fields of clinical medicine with a platform to publish high-quality clinical research articles and communicate their research findings online.

WJCC mainly publishes case reports, case series, and articles reporting research results and findings obtained in the field of clinical medicine and covering a wide range of topics including diagnostic, therapeutic, and preventive modalities.

INDEXING/ABSTRACTING

The WJCC is now indexed in PubMed, PubMed Central, Science Citation Index Expanded (also known as SciSearch®), and Journal Citation Reports/Science Edition. The 2019 Edition of Journal Citation Reports cites the 2018 impact factor for WJCC as 1.153 (5-year impact factor: N/A), ranking WJCC as 99 among 160 journals in Medicine, General and Internal (quartile in category Q3).

RESPONSIBLE EDITORS FOR THIS ISSUE

Responsible Electronic Editor: *Yan-Xia Xing*

Proofing Production Department Director: *Yun-Xiaojuan Wu*

NAME OF JOURNAL

World Journal of Clinical Cases

ISSN

ISSN 2307-8960 (online)

LAUNCH DATE

April 16, 2013

FREQUENCY

Semimonthly

EDITORS-IN-CHIEF

Dennis A Bloomfield, Bao-Gan Peng, Sandro Vento

EDITORIAL BOARD MEMBERS

<https://www.wjgnet.com/2307-8960/editorialboard.htm>

EDITORIAL OFFICE

Jin-Lei Wang, Director

PUBLICATION DATE

September 6, 2019

COPYRIGHT

© 2019 Baishideng Publishing Group Inc

INSTRUCTIONS TO AUTHORS

<https://www.wjgnet.com/bpg/gerinfo/204>

GUIDELINES FOR ETHICS DOCUMENTS

<https://www.wjgnet.com/bpg/GerInfo/287>

GUIDELINES FOR NON-NATIVE SPEAKERS OF ENGLISH

<https://www.wjgnet.com/bpg/gerinfo/240>

PUBLICATION MISCONDUCT

<https://www.wjgnet.com/bpg/gerinfo/208>

ARTICLE PROCESSING CHARGE

<https://www.wjgnet.com/bpg/gerinfo/242>

STEPS FOR SUBMITTING MANUSCRIPTS

<https://www.wjgnet.com/bpg/GerInfo/239>

ONLINE SUBMISSION

<https://www.f6publishing.com>



Robotic-assisted resection of ovarian tumors in children: A case report and review of literature

Xiao-Xiao Xie, Ning Wang, Zi-Hao Wang, Yue-Yue Zhu, Jing-Ru Wang, Xian-Qiang Wang

ORCID number: Xiao-Xiao Xie (0000-0002-7938-4232); Ning Wang (0000-0002-8911-6100); Zi-Hao Wang (0000-0001-7241-6169); Yue-Yue Zhu (0000-0002-1156-8510); Jing-Ru Wang (0000-0001-6759-7882); Xian-Qiang Wang (0000-0002-8914-6545).

Author contributions: Xie XX and Wang N contribute equally to this article and should be considered as co-first authors; Xie XX and Wang XQ performed the operation; Xie XX, and Wang N designed this case report; Wang ZH and Wang XQ wrote this paper; Zhu YY and Wang JR was responsible for sorting the data.

Informed consent statement: Informed consent was obtained from the patient.

Conflict-of-interest statement: The authors declare that they have no conflict of interest.

CARE Checklist (2016) statement: The manuscript was prepared and revised according to the CARE Checklist (2016).

Open-Access: This article is an open-access article which was selected by an in-house editor and fully peer-reviewed by external reviewers. It is distributed in accordance with the Creative Commons Attribution Non Commercial (CC BY-NC 4.0) license, which permits others to distribute, remix, adapt, build upon this work non-commercially, and license their derivative works on different terms, provided the original work is properly cited and the use is non-commercial. See:

Xiao-Xiao Xie, Department of Obstetrics and Gynecology, PLA General Hospital, Beijing 100853, China

Ning Wang, Xian-Qiang Wang, Department of Pediatrics, PLA General Hospital, Beijing 100853, China

Zi-Hao Wang, The Fourth Military Medical University, Xi'an 710032, Shanxi Province, China

Yue-Yue Zhu, Jing-Ru Wang, Southern Medical University, Guangzhou 510515, Guangdong Province, China

Corresponding author: Xian-Qiang Wang, MD, PhD, Attending Doctor, Surgeon, Department of Pediatric, PLA General Hospital, No. 28, Fuxing Road, Haidian District, Beijing 100853, China. wxq301@gmail.com
Telephone: +86-10-66938418
Fax: +86-10-66938418

Abstract

BACKGROUND

Ovarian tumors are common gynecological diseases in children, and the most commonly seen ovarian tumors are germ cell tumors. Robotic surgery is the new access for children ovarian tumors.

CASE SUMMARY

From June to October 2017, 4 children with ovarian tumors were admitted and treated in the Department of Pediatric Surgery of People's Liberation Army General Hospital. The mean age, height, and weight of these patients were 7.5 (1-13) years old, 123.75 (71-164) cm, and 36.8 (8.5-69.5) kg, respectively. Robotic-assisted resection of ovarian tumors was performed for all 4 patients. The 3-port approach was used for robotic manipulation. The surgical procedures were as follows. After creation of the pneumoperitoneum, the robotic scope was placed to explore and find the left ovarian tumor. The trocars for robotic arms 1 and 2 were placed at the sites to the lower right and left of the port of the scope. The tumor capsule in the fallopian tube was incised, and the tumor was completely stripped by an electric hook along the junction of the tumor and the capsule. The resected tumor was completely removed using an endobag. The average docking time of the robotic system was 18.5 min, the average operative time was 120 min, and the average blood loss was 20 mL. No drainage tube was placed except in one patient with a mucinous tumor of the ovary. No fever, pelvic fluid, or intestinal obstruction was reported after surgery. No antibiotics were used during the perioperative period, and the average length of hospital stay after surgery was 3

<http://creativecommons.org/licenses/by-nc/4.0/>

Manuscript source: Unsolicited manuscript

Received: May 14, 2019

Peer-review started: May 21, 2019

First decision: July 30, 2019

Revised: August 11, 2019

Accepted: August 20, 2019

Article in press: August 20, 2019

Published online: September 6, 2019

P-Reviewer: Sharma RA, Mayer RJ, Yoon DH

S-Editor: Zhang L

L-Editor: Wang TQ

E-Editor: Qi LL



d.

CONCLUSION

Robotic-assisted resection of ovarian tumors is a simple, safe, and effective surgical procedure for selected patients.

Key words: Children; Robotic surgery; Ovarian tumor resection; Case report

©The Author(s) 2019. Published by Baishideng Publishing Group Inc. All rights reserved.

Core tip: Ovarian tumors are common gynecological diseases in children, and 4 children with ovarian tumors were treated using a robotic surgical system in the Department of Pediatric Surgery of People's Liberation Army General Hospital. There are no reports available on the use of robotic surgery systems to treat ovarian tumors in children in China. We think that robotic-assisted resection of ovarian tumors in children is feasible and promising.

Citation: Xie XX, Wang N, Wang ZH, Zhu YY, Wang JR, Wang XQ. Robotic-assisted resection of ovarian tumors in children: A case report and review of literature. *World J Clin Cases* 2019; 7(17): 2542-2548

URL: <https://www.wjgnet.com/2307-8960/full/v7/i17/2542.htm>

DOI: <https://dx.doi.org/10.12998/wjcc.v7.i17.2542>

INTRODUCTION

Ovarian tumors are common gynecological diseases in children, and the most commonly seen ovarian tumors are germ cell tumors^[1]. Ovarian mature cystic teratomas, also known as dermoid cysts, are the most common germ cell tumor, and they are also the most common benign tumors of the ovary^[2]. Malignant germ cell tumors are relatively rare, but these malignant tumors usually have a high degree of malignancy. The proportion of malignancy is negatively associated with the age of the child (younger patients often have a greater likelihood of having malignant tumors)^[3].

With the rapid development of minimally invasive surgery in recent years, robotic surgery systems have been widely used in many surgical procedures in adults^[4-8]. However, due to the large age differences between pediatric patients, robotic surgery for children remains in the exploratory stage.

No reports are available on the use of robotic surgery systems to treat ovarian tumors in children in China. However, foreign medical centers have reported their experience in this field^[9]. From June to October 2017, 4 children with ovarian tumors were treated using a robotic surgical system in the Department of Pediatric Surgery of People's Liberation Army General Hospital. This study retrospectively analyzed the clinical data and surgical procedures of these patients and aimed to explore the feasibility and safety of robotic surgery systems in children with ovarian tumors, as well as to provide preliminary experience with its clinical application.

CASE PRESENTATION

Chief complaints

Four children were admitted to the hospital with mass in lower abdomen.

History of present illness

The mean age, height, and weight of these patients were 7.5 (1-13) years old, 123.75 (71-164) cm, and 36.8 (8.5-69.5) kg, respectively. The Basic data of patients see [Table 1](#).

Physical examination

The patient exhibited mass in lower abdomen.

Imaging examination

Ultrasonography revealed cystic mass in the lower abdomen.

Table 1 Basic data of patients, size of tumor and perioperative pathology

Case	Age	Height cm	Weight kg	Tumor cm	Side	Pathology
1	8	120	22.3	13.4	Right	Ovarian mature cystic teratoma
2	1	71	8.5	5.4	Right	Ovarian mature cystic teratoma
3	13	164	69.5	21	Left	Mucinous tumor of the ovary
4	8	140	47	11.6	Right	Ovarian teratoma

FINAL DIAGNOSIS

Ovarian tumors.

Preoperative diagnosis and treatment plan

For the treatment of ovarian tumors, Robotic-assisted resection was performed under general anesthesia. All of the patients were indicated for robotic surgery without contraindications. And the patients were fully informed and signed an informed consent form.

TREATMENT

Anesthesia and body position

Routine bowel preparation was performed before surgery. Total intravenous anesthesia was administered with tracheal intubation. The end-tidal CO₂ concentration was conventionally monitored. The patient was placed in the supine position and was restrained with tape or bandages. The direct trocar entry technique was used to create the pneumoperitoneum. The conventional CO₂ pneumoperitoneum pressure was maintained at 8 mm-10 mm Hg, but the recommended pressure was 6 mm-8 mm Hg in the neonates. The upper limit of pneumoperitoneum pressure was used to create the pneumoperitoneum to fully expose the abdominal cavity. After introducing robotic instruments, the pressure was reduced to the lower limit, and excellent exposure was achieved.

Trocar placement

A 12 mm trocar was directly inserted into the abdominal cavity at a site 5 cm to 10 cm above the umbilicus to create a pneumoperitoneum with placement of the robotic scope. An 8 mm trocar was placed at a site 1 cm below the right costal margin in the anterior axillary line and was used for arm 1 (Figure 1). An 8 mm trocar was placed at a site 1 cm below the left costal margin in the anterior axillary line and used for arm 2 (Figure 1).

Preparation of the robotic surgical system: First, the surgical robotic arms of the robotic surgery system were placed on the patient's leg side, and the connection between the surgical robotic arms and the trocar is described as follows: (1) The robotic arm of the scope was connected to the 12 mm trocar above the umbilicus, and the robotic scope was inserted; (2) The two robotic arms were connected to the left and right 8 mm trocars, respectively. A monopolar electrocoagulation hook or a robotic ultrasonic knife was mounted on one side, and a bipolar electrocoagulation hook was mounted on the other side.

Basic steps of the procedure (on the right side in a patient)

After successful anesthesia, the anesthesiologist placed the radial artery catheter. The urinary catheter was placed. The patient was placed in the lithotomy position with the feet elevated above the head. The operative field was routinely disinfected with iodine and draped. The pneumoperitoneum needle was inserted above the umbilicus to create a pneumoperitoneum with pressure of 13 cm H₂O. A 12 mm trocar and the robotic scope were placed. The exploration showed that the diameter of the left ovarian tumor was approximately 10 cm, and the right ovary was unremarkable. No pelvic or abdominal metastasis or malignant ascites was observed. The trocars for robotic arms 1 and 2 were placed to the lower right and lower left to the port of the scope, respectively. The robotic scope and the instrument arm were inserted and connected from the foot side.

The tumor capsule on the fallopian tube was circularly incised at a site approximately 3 cm from the infundibulum of the fallopian tube, and the tumor was

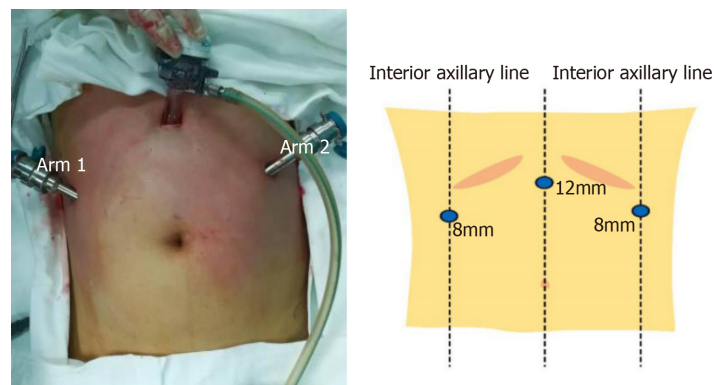


Figure 1 Trocar placement during surgery.

completely stripped with an electric hook along the junction of the tumor and the capsule. The examination was repeated to confirm no active bleeders in the fallopian tube stump and residual ovarian capsule. Robotic arms 1 and 2 were withdrawn. The incision for arm 1 was extended. The resected tumor of the left ovary was placed in an endobag, in which the tumor was punctured to rupture. Clear liquid flowed out, and hair and fat were visible inside. The resected tumor was completely removed using an endobag.

The procedure went well. The patient returned to the ward after surgery. No blood transfusion was needed.

Perioperative parameters

All 4 patients successfully underwent the robotic-assisted surgery, and there was no conversion to open surgery. The average docking time of the robotic system was 18.5 min, the average operative time was 120 min, and the average blood loss was 20 mL. No drainage tubes were placed except in a patient with a mucinous tumor of the ovary.

OUTCOME AND FOLLOW-UP

On the first day after surgery, the patients were allowed to ambulate and were provided with a liquid diet. On the second day, the patients were offered a semiliquid diet and were allowed to perform normal daily activities. No fever, pelvic fluid, or intestinal obstructions were reported after surgery. No antibiotics were used, and no complications (Clavien III or higher) occurred. The average length of hospital stay after surgery was 3 d.

No serious complications or recurrences were observed after the 6-mo follow-up.

DISCUSSION

In 2005, the United States Food and Drug Administration approved robotic surgery systems for gynecological surgery. Over the past 10 years, robotic surgery systems have been widely used in the surgical treatment of adult gynecologic tumors^[10-12]. Robotic gynecological surgery in the treatment of benign and malignant gynecological tumors has been highly praised by gynecologists at home and abroad^[13-16]. Robotic surgery in children was first used in urology^[17], and since then, an increasing number of surgeons have reported the use of robotic surgery in various fields of pediatric surgery.

In this group of patients, the robotic arms were used to accurately complete exposure of the ovary, dissection of blood vessels, resection of the tumor, hemostasis of the wound, and removal of the specimen. During stripping of the cysts, the cysts were not ruptured in the 4 patients, and the blood loss was small. The morphology of the ovary was maintained, which is beneficial to the recovery of postoperative ovarian function.

In gynecological treatment, laparoscopic ovarian cystectomy is one of the most widely used procedures^[18]. Laparoscopic ovarian cystectomy is a toilless procedure for separation of the tumor, and surgeons have sufficient understanding of the anatomy. Therefore, laparoscopic ovarian cystectomy is an ideal procedure for using

robotic surgery systems. In this study, the procedures were performed over a period of 4 months. In these 4 procedures, the docking time of the robotic system and the operative time of the robotic surgery decreased as the surgeons accumulated more experience. The procedure was prolonged in a few cases, but a prolonged operation time can be accepted, considering the benefits of minimally invasive surgery. Some studies have shown that^[19-21], in the treatment of complex gynecological diseases, the learning curve with robotic surgery is shorter and easier than that with laparoscopic surgery, and the operator can complete the surgical task quickly and accurately.

We summarize the experience of using the Da Vinci system in pediatric gynecological surgery as follows. First, Chang *et al*^[22] reported that the successful operation with robotic surgery requires four elements: A good understanding of the surgical procedure, superb surgical skills and frequent training, teamwork, and trocar placement. We agree with this statement and suggest that the most critical step is the placement of trocars, especially for children. In the early stage of this study, we noted that improper placement of the trocars would limit robotic manipulation in the abdominal cavity and increase the chances of instrument conflicts due to the small surface area of the abdominal wall of children and the relatively small space in the abdominal cavity. Therefore, the rational placement of the trocars is essential for a smooth operation. Second, unlike adult gynecological surgery, in which 4 robotic arms can be used, surgeons often only use 3 robotic arms in the majority of pediatric gynecological surgeries. Most pediatric gynecological surgeries can be completed using two operating arms. If the fourth arm is added, it will require more space and interfere with the operation of other arms in the pelvis, thereby increasing difficulty of the manipulation of the other arms. We suggest that, according to the experience of Finkelstein *et al*^[23], the distance between the anterior superior iliac spine (> 13 cm) should first be evaluated before surgery to confirm that there is sufficient space to operate smoothly. Third, the standard operation of the robotic surgical system is to insert the trocar for the scope first and then insert the trocars for the robotic arms. The improvement that we made is to insert the trocars for the robotic arms on both sides first and then insert the trocar for the scope. This operation order is simple, safe, and consistent with the experience in previous reports. Fourth, children's abdominal walls are relatively thin and mobile. In the first few cases in this study, trocar detachment occurred and affected the operation of robotic surgery. The experience in some centers is to directly suture the trocar to the abdominal wall. We do not usually use this method. According to the position and degree of movement of the robotic arm, the position of the trocar's remote center is adjusted appropriately. The trocar should be placed in the abdominal cavity deeply or at least reach the remote center if the robotic arm needs to be moved in a large range, or it should reach the edge of the remote center if the robotic arm requires moving in a small range. Fifth, less pressure for the pneumoperitoneum was required for children's robotic surgery than with conventional laparoscopic surgery to achieve the same exposure effect. The main reason is that the abdominal wall can be retracted outward by the robotic arm to enlarge the space in the abdominal cavity. The principle of this method is to create a pneumoperitoneum with the abdominal wall hanging up. Therefore, the requirements of the body position are not as strict as those of conventional laparoscopic surgery^[22].

There have been some controversies with robotic surgery in children. The population is relatively smaller in children than in adults. The number of accumulated procedures in children is difficult to compare with that in adults, which could lead to an imbalance between the efficiency and the cost. Cundy *et al*^[24] suggested that robotic surgery in children is driven more by technology and industry than by clinical demand. Currently, there is no literature directly demonstrating the applicability of robotic surgery in children. As Peters^[25] commented, "similar to children, new technologies, do not emerge in a mature form but, rather, require time for development and refinement".

Robotic surgery is undoubtedly a trend in minimally invasive surgery, and its emergence is not limited to itself. With the emergence of robotic surgery, a series of technological innovations will follow. Pediatric surgery-specific robotic techniques are on the rise, and the pediatric cardiac bioengineering laboratory led by Damian *et al*^[26] is working on the invention of a small implantable robot; microrobots and nanorobots will be able to enter the human body to complete surgical tasks under wireless control without any awareness of patients^[27].

CONCLUSION

Robotic-assisted resection of ovarian tumors is a simple, safe, and effective surgical procedure for selected pediatric patients. In centers where robotic surgery services are

newly available, robotic-assisted resection of ovarian tumors is a suitable entry-level procedure.

REFERENCES

- 1 Vaysse C, Delsol M, Carfagna L, Bouali O, Combelles S, Lemasson F, Le Mandat A, Castex MP, Pasquet M, Moscovici J, Guitard J, Pienkowski C, Rubie H, Galinier P, Vaysse P. Ovarian germ cell tumors in children. Management, survival and ovarian prognosis. A report of 75 cases. *J Pediatr Surg* 2010; **45**: 1484-1490 [PMID: 20638529 DOI: 10.1016/j.jpedsurg.2009.11.026]
- 2 Outwater EK, Siegelman ES, Hunt JL. Ovarian teratomas: tumor types and imaging characteristics. *Radiographics* 2001; **21**: 475-490 [PMID: 11259710 DOI: 10.1148/radiographics.21.2.g01mr09475]
- 3 Kokoska ER, Keller MS, Weber TR. Acute ovarian torsion in children. *Am J Surg* 2000; **180**: 462-465 [PMID: 11182398 DOI: 10.1016/s0002-9610(00)00503-1]
- 4 Yao Y. Current status and prospects of robotic surgery for gynecologic tumor. *Zhongguofuqiangjing Waikexue* 2013; **6**: 330-333
- 5 Tseng SI, Huang CW, Huang TY. Robotic-assisted transanal repair of rectourethral fistula. *Endoscopy* 2019; **51**: E96-E97 [PMID: 30754051 DOI: 10.1055/a-0826-4220]
- 6 Tinelli A, Malvasi A, Gustapane S, Buscarini M, Gill IS, Stark M, Nezhat FR, Mettler L. Robotic assisted surgery in gynecology: current insights and future perspectives. *Recent Pat Biotechnol* 2011; **5**: 12-24 [PMID: 21517747 DOI: 10.2174/187220811795655913]
- 7 Marengo F, Larrain D, Babilonti L, Spinillo A. Learning experience using the double-console da Vinci surgical system in gynecology: a prospective cohort study in a University hospital. *Arch Gynecol Obstet* 2012; **285**: 441-445 [PMID: 21779771 DOI: 10.1007/s00404-011-2005-8]
- 8 Wong J, Murtaugh T, Lakra A, Cooper HJ, Shah RP, Geller JA. Robotic-assisted unicompartmental knee replacement offers no early advantage over conventional unicompartmental knee replacement. *Knee Surg Sports Traumatol Arthrosc* 2019; **27**: 2303-2308 [PMID: 30747237 DOI: 10.1007/s00167-019-05386-6]
- 9 Nakib G, Calcaterra V, Scorletti F, Romano P, Goruppi I, Mencherini S, Avolio L, Pelizzo G. Robotic assisted surgery in pediatric gynecology: promising innovation in mini invasive surgical procedures. *J Pediatr Adolesc Gynecol* 2013; **26**: e5-e7 [PMID: 23158752 DOI: 10.1016/j.jpog.2012.09.009]
- 10 Matanes E, Lauterbach R, Boulus S, Amit A, Lowenstein L. Robotic laparoendoscopic single-site surgery in gynecology: A systematic review. *Eur J Obstet Gynecol Reprod Biol* 2018; **231**: 1-7 [PMID: 30317138 DOI: 10.1016/j.ejogrb.2018.10.006]
- 11 Aloisi A, Tseng JH, Sandadi S, Callery R, Feinberg J, Kuhn T, Gardner GJ, Sonoda Y, Brown CL, Jewell EL, Barakat RR, Leitao MM. Is Robotic-Assisted Surgery Safe in the Elderly Population? An Analysis of Gynecologic Procedures in Patients \geq 65 Years Old. *Ann Surg Oncol* 2019; **26**: 244-251 [PMID: 30421046 DOI: 10.1245/s10434-018-6997-1]
- 12 Das D, Propst K, Wechter ME, Kho RM. Evaluation of Positioning Devices for Optimization of Outcomes in Laparoscopic and Robotic-Assisted Gynecologic Surgery. *J Minim Invasive Gynecol* 2019; **26**: 244-252.e1 [PMID: 30176363 DOI: 10.1016/j.jmig.2018.08.027]
- 13 Yao Y, Li X, Yang Y, Liu Z, Yan H, Yan Z, Chen L, Wang J. [Robotic surgery in the management of early ovarian malignancy tumors]. *Zhonghua Fu Chan Ke Za Zhi* 2015; **50**: 603-607 [PMID: 26675184 DOI: 10.3760/cma.j.issn.0529-567x.2015.08.008]
- 14 Zanagnolo V, Garbi A, Achilarré MT, Minig L. Robot-assisted Surgery in Gynecologic Cancers. *J Minim Invasive Gynecol* 2017; **24**: 379-396 [PMID: 28104497 DOI: 10.1016/j.jmig.2017.01.006]
- 15 Conrad LB, Ramirez PT, Burke W, Naumann RW, Ring KL, Munsell MF, Frumovitz M. Role of Minimally Invasive Surgery in Gynecologic Oncology: An Updated Survey of Members of the Society of Gynecologic Oncology. *Int J Gynecol Cancer* 2015; **25**: 1121-1127 [PMID: 25860841 DOI: 10.1097/IGC.0000000000000450]
- 16 Gala RB, Margulies R, Steinberg A, Murphy M, Lukban J, Jeppson P, Aschkenazi S, Olivera C, South M, Lowenstein L, Schaffer J, Balk EM, Sung V; Society of Gynecologic Surgeons Systematic Review Group. Systematic review of robotic surgery in gynecology: robotic techniques compared with laparoscopy and laparotomy. *J Minim Invasive Gynecol* 2014; **21**: 353-361 [PMID: 24295923 DOI: 10.1016/j.jmig.2013.11.010]
- 17 Heller K, Gutt C, Schaeff B, Beyer PA, Markus B. Use of the robot system Da Vinci for laparoscopic repair of gastro-oesophageal reflux in children. *Eur J Pediatr Surg* 2002; **12**: 239-242 [PMID: 12369000 DOI: 10.1055/s-2002-34489]
- 18 Raicevic M, Saxena AK. Review of Laparoscopic Management of Mature Cystic Teratoma of Ovaries in Children. *J Indian Assoc Pediatr Surg* 2019; **24**: 92-96 [PMID: 31105392 DOI: 10.4103/jiaps.JIAPS_246_17]
- 19 Morice P, Leary A, Creutzberg C, Abu-Rustum N, Darai E. Endometrial cancer. *Lancet* 2016; **387**: 1094-1108 [PMID: 26354523 DOI: 10.1016/S0140-6736(15)00130-0]
- 20 Hassan SO, Dudhia J, Syed LH, Patel K, Farshidpour M, Cunningham SC, Kowdley GC. Conventional Laparoscopic vs Robotic Training: Which is Better for Naive Users? A Randomized Prospective Crossover Study. *J Surg Educ* 2015; **72**: 592-599 [PMID: 25687957 DOI: 10.1016/j.jsurg.2014.12.008]
- 21 Moore LJ, Wilson MR, Waine E, Masters RS, McGrath JS, Vine SJ. Robotic technology results in faster and more robust surgical skill acquisition than traditional laparoscopy. *J Robot Surg* 2015; **9**: 67-73 [PMID: 26530974 DOI: 10.1007/s11701-014-0493-9]
- 22 Chang C, Steinberg Z, Shah A, Gundeti MS. Patient positioning and port placement for robot-assisted surgery. *J Endourol* 2014; **28**: 631-638 [PMID: 24548088 DOI: 10.1089/end.2013.0733]
- 23 Finkelstein JB, Levy AC, Silva MV, Murray L, Delaney C, Casale P. How to decide which infant can have robotic surgery? Just do the math. *J Pediatr Urol* 2015; **11**: 170.e1-170.e4 [PMID: 25824875 DOI: 10.1016/j.jpuro.2014.11.020]
- 24 Cundy TP, Marcus HJ, Hughes-Hallett A, Khurana S, Darzi A. Robotic surgery in children: adopt now, await, or dismiss? *Pediatr Surg Int* 2015; **31**: 1119-1125 [PMID: 26416688 DOI: 10.1007/s00383-015-3800-2]
- 25 Peters CA. Pediatric robotic-assisted surgery: too early an assessment? *Pediatrics* 2009; **124**: 1680-1681 [PMID: 19948633 DOI: 10.1542/peds.2009-2562]
- 26 Damian DD, Arabagi S, Fabozzo A, Ngo P, Jennings R, Manfredi M, Dupont PE. Robotic implant to

- apply tissue traction forces in the treatment of esophageal atresia. *ICRA* 2014; 786-782 [DOI: [10.1109/ICRA.2014.6906944](https://doi.org/10.1109/ICRA.2014.6906944)]
- 27 **Bergeles C**, Yang GZ. From passive tool holders to microsurgeons: safer, smaller, smarter surgical robots. *IEEE Trans Biomed Eng* 2014; **61**: 1565-1576 [PMID: [24723622](https://pubmed.ncbi.nlm.nih.gov/24723622/) DOI: [10.1109/TBME.2013.2293815](https://doi.org/10.1109/TBME.2013.2293815)]



Published By Baishideng Publishing Group Inc
7041 Koll Center Parkway, Suite 160, Pleasanton, CA 94566, USA
Telephone: +1-925-2238242
E-mail: bpgoffice@wjgnet.com
Help Desk: <https://www.f6publishing.com/helpdesk>
<https://www.wjgnet.com>

