

World Journal of *Clinical Cases*

World J Clin Cases 2019 September 26; 7(18): 2658-2915



**OPINION REVIEW**

- 2658** Effective use of the Japan Narrow Band Imaging Expert Team classification based on diagnostic performance and confidence level
Hirata D, Kashida H, Iwatate M, Tochio T, Teramoto A, Sano Y, Kudo M

MINIREVIEWS

- 2666** Low fermentable oligosaccharides, disaccharides, monosaccharides, and polyols diet in children
Fodor I, Man SC, Dumitrascu DL
- 2675** High-resolution colonic manometry and its clinical application in patients with colonic dysmotility: A review
Li YW, Yu YJ, Fei F, Zheng MY, Zhang SW

ORIGINAL ARTICLE**Retrospective Study**

- 2687** Predictors of rebleeding and in-hospital mortality in patients with nonvariceal upper digestive bleeding
Lazăr DC, Ursoniu S, Goldiș A
- 2704** Analgesic effect of parecoxib combined with ropivacaine in patients undergoing laparoscopic hepatectomy
Huang SS, Lv WW, Liu YF, Yang SZ
- 2712** Prognostic significance of 14v-lymph node dissection to D2 dissection for lower-third gastric cancer
Zheng C, Gao ZM, Sun AQ, Huang HB, Wang ZN, Li K, Gao S

Observational Study

- 2722** Wall shear stress can improve prediction accuracy for transient ischemic attack
Liu QY, Duan Q, Fu XH, Jiang M, Xia HW, Wan YL

Prospective Study

- 2734** Characterization of microbiota in systemic-onset juvenile idiopathic arthritis with different disease severities
Dong YQ, Wang W, Li J, Ma MS, Zhong LQ, Wei QJ, Song HM

SYSTEMATIC REVIEWS

- 2746** Sinusoidal obstruction syndrome: A systematic review of etiologies, clinical symptoms, and magnetic resonance imaging features
Zhang Y, Jiang HY, Wei Y, Song B

META-ANALYSIS

- 2760 Respiratory training interventions improve health status of heart failure patients: A systematic review and network meta-analysis of randomized controlled trials
Wang MH, Yeh ML

CASE REPORT

- 2776 *Mycobacterium chimaera* infections following cardiac surgery in Treviso Hospital, Italy, from 2016 to 2019: Cases report
Inojosa WO, Giobbia M, Muffato G, Minniti G, Baldasso F, Carniato A, Farina F, Forner G, Rossi MC, Formentini S, Rigoli R, Scotton PG
- 2787 Giant squamous cell carcinoma of the gallbladder: A case report
Junior MAR, Favaro MDL, Santin S, Silva CM, Iamarino APM
- 2794 Liver re-transplantation for donor-derived neuroendocrine tumor: A case report
Mrzljak A, Kocman B, Skrtic A, Furac I, Popic J, Franusic L, Zunec R, Mayer D, Mikulic D
- 2802 Calcifying fibrous tumor originating from the gastrohepatic ligament that mimicked a gastric submucosal tumor: A case report
Kwan BS, Cho DH
- 2808 Pancreatitis, panniculitis, and polyarthritis syndrome caused by pancreatic pseudocyst: A case report
Jo S, Song S
- 2815 Glomus tumor of uncertain malignant potential of the brachial plexus: A case report
Thanindrarn P, Chobpenthai T, Phorkhar T, Nelson SD
- 2823 Conservative pulp treatment for Oehlers type III dens invaginatus: A case report
Lee HN, Chen YK, Chen CH, Huang CY, Su YH, Huang YW, Chuang FH
- 2831 Propofol pump controls nonconvulsive status epilepticus in a hepatic encephalopathy patient: A case report
Hor S, Chen CY, Tsai ST
- 2838 Teriparatide as nonoperative treatment for femoral shaft atrophic nonunion: A case report
Tsai MH, Hu CC
- 2843 Successful repair of acute type A aortic dissection during pregnancy at 16th gestational week with maternal and fetal survival: A case report and review of the literature
Chen SW, Zhong YL, Ge YP, Qiao ZY, Li CN, Zhu JM, Sun LZ
- 2851 Inferior pancreaticoduodenal artery pseudoaneurysm in a patient with calculous cholecystitis: A case report
Xu QD, Gu SG, Liang JH, Zheng SD, Lin ZH, Zhang PD, Yan J

- 2857** ALK-positive anaplastic large cell lymphoma of the thoracic spine occurring in pregnancy: A case report
Yang S, Jiang WM, Yang HL
- 2871** Multiple gastric adenocarcinoma of fundic gland type: A case report
Chen O, Shao ZY, Qiu X, Zhang GP
- 2879** Repair of the portal vein using a hepatic ligamentum teres patch for laparoscopic pancreaticoduodenectomy: A case report
Wei Q, Chen QP, Guan QH, Zhu WT
- 2899** Pleomorphic lipoma in the anterior mediastinum: A case report
Mao YQ, Liu XY, Han Y
- 2905** Guillain-Barré syndrome in a patient with multiple myeloma after bortezomib therapy: A case report
Xu YL, Zhao WH, Tang ZY, Li ZQ, Long Y, Cheng P, Luo J
- 2910** Bowen's disease on the palm: A case report
Yu SR, Zhang JZ, Pu XM, Kang XJ

ABOUT COVER

Editorial Board Member of *World Journal of Clinical Cases*, Shao-Ping Yu, MD, Associate Professor, Chief Doctor, Department of Gastroenterology and Hepatology, Dongguan Kanghua Hospital, Dongguan 523080, Guangdong Province, China

AIMS AND SCOPE

The primary aim of *World Journal of Clinical Cases* (*WJCC*, *World J Clin Cases*) is to provide scholars and readers from various fields of clinical medicine with a platform to publish high-quality clinical research articles and communicate their research findings online.

WJCC mainly publishes case reports, case series, and articles reporting research results and findings obtained in the field of clinical medicine and covering a wide range of topics including diagnostic, therapeutic, and preventive modalities.

INDEXING/ABSTRACTING

The *WJCC* is now indexed in PubMed, PubMed Central, Science Citation Index Expanded (also known as SciSearch®), and Journal Citation Reports/Science Edition. The 2019 Edition of Journal Citation Reports cites the 2018 impact factor for *WJCC* as 1.153 (5-year impact factor: N/A), ranking *WJCC* as 99 among 160 journals in Medicine, General and Internal (quartile in category Q3).

RESPONSIBLE EDITORS FOR THIS ISSUE

Responsible Electronic Editor: Ji-Hong Liu

Proofing Production Department Director: Yun-Xiaoqian Wu

NAME OF JOURNAL

World Journal of Clinical Cases

ISSN

ISSN 2307-8960 (online)

LAUNCH DATE

April 16, 2013

FREQUENCY

Semimonthly

EDITORS-IN-CHIEF

Dennis A Bloomfield, Bao-Gan Peng, Sandro Vento

EDITORIAL BOARD MEMBERS

<https://www.wjgnet.com/2307-8960/editorialboard.htm>

EDITORIAL OFFICE

Jin-Lei Wang, Director

PUBLICATION DATE

September 26, 2019

COPYRIGHT

© 2019 Baishideng Publishing Group Inc

INSTRUCTIONS TO AUTHORS

<https://www.wjgnet.com/bpg/gerinfo/204>

GUIDELINES FOR ETHICS DOCUMENTS

<https://www.wjgnet.com/bpg/GerInfo/287>

GUIDELINES FOR NON-NATIVE SPEAKERS OF ENGLISH

<https://www.wjgnet.com/bpg/gerinfo/240>

PUBLICATION MISCONDUCT

<https://www.wjgnet.com/bpg/gerinfo/208>

ARTICLE PROCESSING CHARGE

<https://www.wjgnet.com/bpg/gerinfo/242>

STEPS FOR SUBMITTING MANUSCRIPTS

<https://www.wjgnet.com/bpg/GerInfo/239>

ONLINE SUBMISSION

<https://www.f6publishing.com>



Retrospective Study

Analgesic effect of parecoxib combined with ropivacaine in patients undergoing laparoscopic hepatectomy

Shan-Shan Huang, Wei-Wei Lv, Yan-Feng Liu, Shao-Zhong Yang

ORCID number: Shan-Shan Huang (0000-0001-5587-9989); Wei-Wei Lv (0000-0001-9012-1436); Yan-Feng Liu (0000-0001-9053-2104); Shao-Zhong Yang (0000-0003-4958-1232).

Author contributions: Huang SS and Lv WW contributed equally to this work and should be considered as co-first authors; Yang SZ and Liu YF designed and performed the research; Yang SZ and Lv WW analyzed the data and wrote the paper.

Institutional review board

statement: This study was reviewed and approved by the Ethics Committee of Qilu Hospital of Shandong University.

Informed consent statement: All the patients provided informed consent.

Conflict-of-interest statement: No conflict of interest.

Open-Access: This article is an open-access article which was selected by an in-house editor and fully peer-reviewed by external reviewers. It is distributed in accordance with the Creative Commons Attribution Non Commercial (CC BY-NC 4.0) license, which permits others to distribute, remix, adapt, build upon this work non-commercially, and license their derivative works on different terms, provided the original work is properly cited and the use is non-commercial. See: <http://creativecommons.org/licenses/by-nc/4.0/>

Manuscript source: Unsolicited manuscript

Shan-Shan Huang, Shao-Zhong Yang, Department of Anesthesiology, Qilu Hospital of Shandong University, Jinan 250012, Shandong Province, China

Wei-Wei Lv, Department of Radiology, Qilu Hospital of Shandong University, Jinan 250012, Shandong Province, China

Yan-Feng Liu, Department of General Surgery, Qilu Hospital of Shandong University, Jinan 250012, Shandong Province, China

Corresponding author: Shao-Zhong Yang, MD, MSc, Attending Doctor, Department of Anesthesiology, Qilu Hospital of Shandong University, Cultural West Road, Lixia District, Jinan 250012, Shandong Province, China. yszzyang@163.com

Telephone: +86-531-82166458

Fax: +86-531-82166471

Abstract

BACKGROUND

Currently, there is no uniform standard for analgesia during laparoscopic hepatectomy. Most of the analgesia schemes adopt epidural analgesia after laparotomy. Although the analgesia is effective, it has a great impact on the recovery of patients after laparoscopic hepatectomy and is not completely suitable for analgesia after laparoscopic hepatectomy. Although multimodal perioperative analgesia can significantly relieve postoperative pain, there is no relevant study of parecoxib combined with ropivacaine for post-laparoscopic hepatectomy analgesia.

AIM

To study the analgesic effect of the preoperative intravenous injection of parecoxib combined with long-acting local anesthetic ropivacaine for incision infiltration in patients undergoing laparoscopic hepatectomy.

METHODS

Forty-eight patients undergoing laparoscopic hepatectomy were randomly divided into a combined group (parecoxib combined with ropivacaine) and a control group. The visual analogue scale (VAS) at rest and during movement was used to compare the analgesic effect of the two groups. Meanwhile, the cumulative sufentanil, the recovery time for enterokinesia, the length of postoperative hospital stay, and the adverse reactions (nausea and vomiting) were recorded and compared between the two groups.

RESULTS

Received: June 15, 2019
Peer-review started: June 18, 2019
First decision: July 30, 2019
Revised: August 19, 2019
Accepted: August 26, 2019
Article in press: August 26, 2019
Published online: September 26, 2019

P-Reviewer: Sharma RA, Mayer RJ
S-Editor: Wang JL
L-Editor: Wang TQ
E-Editor: Liu JH



The change tendency in VAS scores for both groups was similar after operation. At rest, the VAS scores of the combined group were significantly lower than those of the control group at 0, 6, 12, 24 and 36 h, and during movement, the VAS scores of the combined group were significantly lower than those of the control group at 0, 6, 12, and 24 h. The recovery time for enterokinesia in the combined group was 2.9 d, which was significantly shorter than that in the control group. The cumulative sufentanil in the combined group decreased significantly at 24, 36, and 48 h after operation.

CONCLUSION

Preoperative intravenous injection of parecoxib combined with ropivacaine for incision infiltration is a simple and effective method for postoperative analgesia in laparoscopic hepatectomy, which could relieve pain and promote recovery.

Key words: Analgesic effect; Parecoxib; Ropivacaine; Laparoscopic hepatectomy

©The Author(s) 2019. Published by Baishideng Publishing Group Inc. All rights reserved.

Core tip: Forty-eight patients undergoing laparoscopic hepatectomy were randomly divided into a combined group (parecoxib combined with ropivacaine) and a control group. A visual analogue scale at rest and during movement was used to compare the analgesic effect of the two groups. Preoperative intravenous injection of parecoxib combined with the long-acting local anesthetic ropivacaine for incision infiltration is a simple and effective method for postoperative analgesia in patients undergoing laparoscopic hepatectomy, which could relieve postoperative pain and promote postoperative recovery.

Citation: Huang SS, Lv WW, Liu YF, Yang SZ. Analgesic effect of parecoxib combined with ropivacaine in patients undergoing laparoscopic hepatectomy. *World J Clin Cases* 2019; 7(18): 2704-2711

URL: <https://www.wjnet.com/2307-8960/full/v7/i18/2704.htm>

DOI: <https://dx.doi.org/10.12998/wjcc.v7.i18.2704>

INTRODUCTION

Since the first laparoscopic hepatectomy was reported in 1991, this minimally invasive surgery has been introduced into the field of liver surgery^[1]. With the advances of technology in more than 20 years and the improvement of surgical experience and new operative equipment, laparoscopic hepatectomy has gradually replaced open hepatectomy with incomparable advantages. Patients can quickly recover to normal function with minimal abdominal wall injury^[2,3]. Nevertheless, the persistent pain due to the laparoscopy itself and the postoperative trauma affect the recovery of patients, prolong the hospital stay, and cause stress reactions and related complications, including cardiovascular and cerebrovascular accidents as well as gastrointestinal and neuroendocrine dysfunction^[4,5].

Currently, there is no uniform standard for analgesia during laparoscopic hepatectomy. Most of the analgesia schemes adopt epidural analgesia after laparotomy. Although the analgesia is effective, it has a great impact on the recovery of patients after laparoscopic hepatectomy and is not completely suitable for analgesia after laparoscopic hepatectomy^[6]. Recently, it has been reported that local wound infiltration with ropivacaine in open hepatectomy can significantly reduce postoperative pain and the stress response and accelerate postoperative recovery^[7]. Preoperative intravenous use of parecoxib plays an important role in preemptive analgesia by inhibiting the expression of COX-2 and the synthesis of prostaglandins in the central nervous system^[8]. Although multimodal perioperative analgesia can significantly relieve postoperative pain, there is no relevant study of parecoxib combined with ropivacaine for post-laparoscopic hepatectomy analgesia.

Therefore, this study aimed to observe the analgesic effect of preoperative intravenous injection of the highly selective COX-2 inhibitor parecoxib combined with the long-acting local anesthetic ropivacaine for incision infiltration in patients undergoing laparoscopic hepatectomy.

MATERIALS AND METHODS

Clinical data

Forty-eight consecutive patients who underwent laparoscopic hepatectomy from January 2016 to December 2018 were included. The inclusion criteria included grades I–III according to the American Society of Anesthesiologists Physical Status Classification System (ASA), no history of motion sickness, nausea and vomiting, and chronic pain. Patients with gastroduodenal ulcer or coagulation dysfunction, or patients who were taking analgesics before operation were excluded from the study. This study was approved by the local Hospital Ethics Committee. Informed consent was obtained from all patients. The patients were randomly divided into two groups according to different analgesic methods: Combined group (parecoxib with ropivacaine, $n = 24$) and control group ($n = 24$). The specific clinical data of the patients are shown in [Table 1](#).

Surgical procedure and analgesic methods

Preoperative Child-Pugh grade of liver function in both groups was grade A, and tracheal intubation plus combined intravenous inhalation was used. The combined group and the control group were given 20 mg of parecoxib or the same amount of saline intravenously 20 min before induction of anesthesia. Laparoscopic hepatectomy was performed by the same surgical team. Four to 5 puncture holes were assigned in the abdomen wall according to the location of the resected liver and the Joel-Cohen incision was used to take the specimen in which the length depended on the size of the specimen. In the combined group, 7.5 mg/mL ropivacaine solution was used for puncture incision infiltration, while in the control group, isotonic saline solution was used. When the abdominal puncture and Joel-Cohen incision were closed at the end of the operation, the subcutaneous tissue and deep myofascial and parietal peritoneum were infiltrated with a 20 mL solution. In addition, one or two abdominal drainage tubes were routinely placed near the hepatic section surface and fixed on the abdominal skin. Local infiltration of ropivacaine or saline was also given around the drainage tube.

All patients were given patient-controlled analgesia (PCA) to relieve pain after operation. Two hundred milliliters of 1 µg/mL of sufentanil was used in the analgesic pump. The flow rate of the pump was 2 mL/h with a bolus of 0.5 mL and 15 min of locking time. At the end of the operation, the PCA pump was inserted into the intravenous infusion tube. Sufentanil was routinely removed 48 h after the operation, and its cumulative use was recorded.

Observation indexes

The visual analogue scale (VAS) was used to compare the analgesic effects of the two groups. The VAS scores were recorded at 0, 6, 12, 24, 36 and 48 h after the operation by those who did not know the grouping. The cumulative sufentanil, the recovery time for enterokinesia, the length of postoperative hospital stay, and the adverse reactions (nausea and vomiting) were recorded and compared between the two groups.

Statistical analysis

Statistical analyses were performed with SPSS 20.0 (SPSS Inc., Chicago, IL, United States). The measurement data are expressed as the mean \pm SD. The *t*-test was used to compare the measurement data between the two groups, and the χ^2 test was used to calculate the counting data. $P < 0.05$ was considered statistically significant.

RESULTS

Comparison of clinical data between the two groups

All the operations were successfully completed, and all the patients recovered smoothly. Liver function recovered to normal status after the operation and all patients were discharged uneventfully. No complications such as bleeding or bile leakage occurred. The total incision length of the combined group was 8.194 ± 0.415 cm, while that of the control group was 7.992 ± 0.422 cm ($P = 0.101$). The operative times in the combined group and control group were 136.083 ± 11.836 min and 135.833 ± 11.484 min, respectively ($P = 0.941$). There were also no significant differences in age, gender, body weight, ASA grade, intraoperative bleeding, or maximum diameter of tumors between the two groups ([Table 1](#)).

Comparison of analgesic effect between the two groups

Table 1 Demographic characteristics of the combined group and control group

Characteristic	Combined group	Control group	t/χ^2 value	P-value
Age (yr)	48.958 ± 12.685	50.208 ± 9.86	-0.381	0.705
Gender				
Male/Female	10/14	15/9	2.087	0.149
Body weight (kg)	68.368 ± 9.738	64.451 ± 8.652	1.473	0.148
ASA grade			0.543	0.762
I/II/III	4/15/5	6/13/5		
Incision length (cm)	8.194 ± 0.415	7.992 ± 0.422	1.674	0.101
Operative time	136.083 ± 11.836	135.833 ± 11.484	0.074	0.941
Intraoperative bleeding volume	81.716 ± 14.737	79.116 ± 14.575	0.615	0.542
Maximum diameter of tumors	12.641 ± 5.075	10.705 ± 4.816	1.356	0.182

ASA: American Society of Anesthesiologists.

The change tendency of VAS scores of the combined group and the control group were similar after operation. The VAS scores increased gradually, peaked at 24 h, and then decreased. At rest, the VAS scores of the combined group were significantly lower than those of the control group at 0, 6, 12, 24, and 36 h, while the VAS scores of the two groups had no significant difference at 48 h (Figure 1A). On movement, the VAS scores of the combined group were significantly lower than those of the control group at 0, 6, 12, and 24 h. The VAS score of the two groups had no significant difference at 36 and 48 h (Figure 1B). This indicated that the combination of parecoxib and ropivacaine could help patients get out of bed early and reduce their pain experience (Table 2).

Comparison of postoperative recovery between the two groups

The recovery time for enterokinesia in the combined group was 2.944 ± 0.896 d, which was significantly shorter than that in the control group ($P < 0.001$). Similarly, the length of hospital stay in the combined group was significantly shorter than that in the control group ($P = 0.001$). All these suggested that the combination of parecoxib and ropivacaine can promote the recovery of patients after operation (Table 3).

Comparison of cumulative sufentanil between the two groups

Sufentanil at 1 µg/mL was delivered with an analgesic pump and any uncomfortable syndromes were monitored and recorded immediately. There was no significant difference in cumulative sufentanil at 6 and 12 h after operation, but there was a significant difference at 24, 36, and 48 h, especially at 24 and 36 h (Table 1, Figure 2). However, there was no significant difference in postoperative complications such as nausea and vomiting between the two groups (Table 3).

DISCUSSION

Since its inception in the 1990s, more than 3000 patients worldwide have undergone laparoscopic hepatectomy^[9]. Compared with the traditional open hepatectomy, the advantages are less bleeding, incision, and pain, faster recovery of gastrointestinal function, and shorter hospital stay^[10,11]. Nevertheless, some patients after operation still suffer from visceral pain, wound prickling, shoulder pain, diaphragmatic abdominal pain, and other discomforts due to the visceral and incision trauma, carbon dioxide stimulation of abdominal visceral nerve and somatic nerve, intraoperative diaphragm traction, and other adverse factors^[4,5]. Insufficient postoperative analgesia can affect the early mobilization, delay intestinal function recovery, prolong recovery time and hospital stays, delay wound healing, and increase the risk of venous thromboembolism. Conversely, effective analgesia after operation is particularly important for patients to promote the recovery of gastrointestinal function, reduce complications, and shorten the length of hospital stay. It is an important part of accelerated rehabilitation surgery^[12].

Preemptive analgesia refers to taking certain measures to block the noxious stimulation and to reduce the sensitivity of the central nervous system and peripheral nervous system to these stimulations in order to relieve pain or postoperative analgesia, make the analgesic effect more obvious, and reduce the dosage of

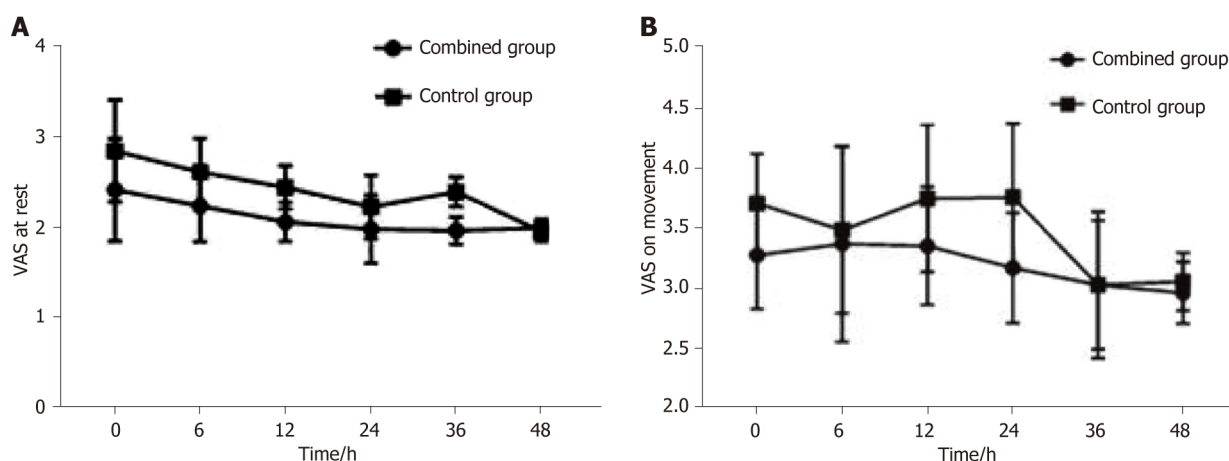


Figure 1 Visual analogue scale scores. A: Visual analogue scale (VAS) scores at rest during the first 48 h after surgery; B: VAS scores on movement during the first 48 h after surgery. VAS: Visual analogue scale.

analgesics^[13,14]. When the body tissues are traumatized, inflammatory mediators will be released. Prostaglandins are made through the conversion of arachidonic acid catalyzed by COX-2, which can directly lead to pain, increase the permeability of blood vessels, dilate blood vessels, create edema tissue, increase the sensitivity of effector receptors, and decrease the pain threshold, leading to peripheral hyperalgesia^[15]. With the highly selective inhibitory action on COX-2, parecoxib blocks the synthesis of prostaglandins in peripheral and central regions, increases the pain threshold, inhibits hypersensitivity of pain threshold, and produces anti-inflammatory and analgesic effects. It has been reported recently that parecoxib has a good analgesic effect in laparoscopic hepatectomy^[16]. However, parecoxib used in the above study was given after surgery. In our study, parecoxib was used 20 min before anesthesia induction. This not only achieved preemptive analgesic effects but also reduced the dosage of parecoxib, alleviating the side effects of medication to some extent.

Incision infiltration anesthesia is an effective and important component of multimodal postoperative analgesics, which is used in many types of surgery, including lumbar surgery, breast surgery, and inguinal hernia repair^[17-19]. Local anesthetics used at the edge of the incision can block the influx of abdominal pain, reduce the sensitivity of spinal dorsal horn neurons, and provide an analgesic effect by inhibiting the spread of harmful impulses in the incision^[20]. In addition, local anesthetics can inhibit local inflammation and pain receptor conduction and sensitivity in wound injury^[21]. Ropivacaine, as a long-acting amide local anesthetic, is widely used in local anesthesia and postoperative analgesia. Its lipophilic reduction is related to the reduction of central nervous system toxicity and the incidence of cardiac toxicity^[22]. Postoperative pain comes from the superficial structure of abdominal pain and peritoneal muscle and fascia structure, so local infiltration of ropivacaine can achieve long-term local analgesia. In this study, preoperative analgesia with parecoxib and local infiltration anesthesia with ropivacaine after operation were applied. The results showed that the combination of parecoxib and ropivacaine could effectively reduce the pain at rest and during movement after operation and promote the postoperative recovery, allowing for early discharge from the hospital. Moreover, in this study, using the Joel-Cohen incision could avoid transecting the abdominal muscles. This incision minimized the pain stimuli and considered the cosmetic results.

Opioids are commonly used intravenously for postoperative analgesia. Long-term use has potential addiction risks and serious side effects such as nausea, vomiting, constipation, respiratory depression, excessive sedation, and liver dysfunction^[23]. Therefore, reducing the dosage and usage time of opioids is an appropriate way to avoid potential serious side effects. Our study showed that the cumulative sufentanil in the combined group decreased significantly. Meanwhile, the recovery time for enterokinesia in the combined group was shorter than that in the control group. This may be related to sufentanil inhibiting intestinal motility by binding to μ -2 and κ receptors in the intestine^[24].

The sample size of this study is relatively small and needs to be included in future studies to further confirm the results of this study. In conclusion, preoperative intravenous injection of parecoxib combined with the long-acting local anesthetic ropivacaine for incision infiltration is a simple and effective method of postoperative

Table 2 Visual analogue scale scores at rest and during movement, and cumulative sufentanil in the combined group and control group

Characteristic	0 h	6 h	12 h	24 h	36 h	48 h
VAS score at rest						
Combined group	2.421 ± 0.568	2.24 ± 0.394	2.064 ± 0.215	1.984 ± 0.379	1.967 ± 0.152	1.997 ± 0.095
Control group	2.853 ± 0.566	2.619 ± 0.373	2.448 ± 0.24	2.233 ± 0.353	2.398 ± 0.163	1.957 ± 0.108
<i>t</i>	-2.636	-3.427	-5.824	-2.353	-9.456	1.349
<i>P</i> -value	0.011	0.001	< 0.001	0.023	< 0.001	0.184
VAS score during movement						
Combined group	3.281 ± 0.451	3.375 ± 0.816	3.359 ± 0.492	3.176 ± 0.461	3.033 ± 0.538	2.967 ± 0.257
Control group	3.715 ± 0.41	3.49 ± 0.695	3.754 ± 0.614	3.764 ± 0.617	3.033 ± 0.61	3.061 ± 0.24
<i>t</i>	-3.491	-2.228	-2.46	-3.738	-0.003	-1.301
<i>P</i> -value	0.001	0.037	0.018	0.001	0.998	0.2
Cumulative sufentanil (μg)						
Combined group	-	15.731 ± 2.472	30.315 ± 4.015	44.339 ± 6.361	60.661 ± 3.773	88.13 ± 7.49
Control group	-	15.288 ± 2.072	30.085 ± 5.884	50.408 ± 6.056	70.325 ± 5.423	94.01 ± 8.329
<i>t</i>	-	0.673	0.159	-3.385	-7.166	-2.572
<i>P</i> -value	-	0.504	0.875	0.001	< 0.001	0.013

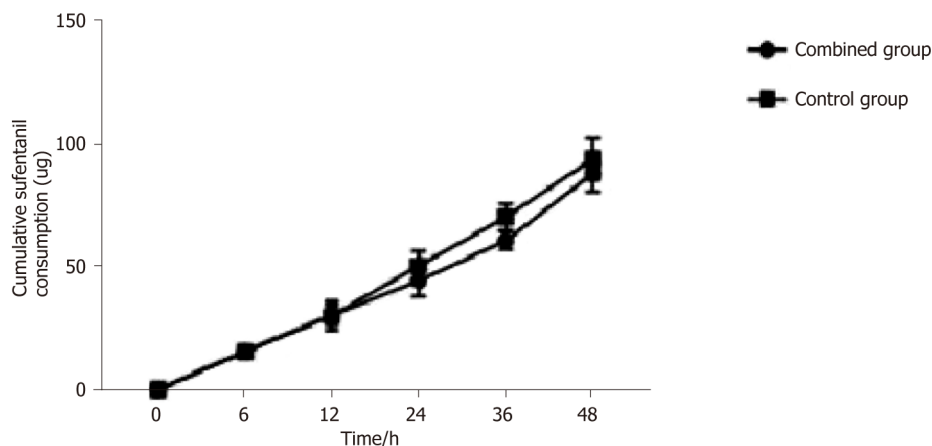
VAS: Visual analogue scale.

analgesia to relieve postoperative pain and promote postoperative recovery after laparoscopic hepatectomy.

Table 3 Recovery time for enterokinesia, postoperative nausea and vomiting, and hospital stay of the two groups

Characteristic	Combined group	Control group	<i>t</i>	<i>P</i> -value
Recovery time for enterokinesia (d)	2.944 ± 0.896	3.954 ± 0.944	-3.804	< 0.001
PONA			0.3345	0.8460
No PONA	13	11		
Nausea without vomiting	6	7		
Nausea with vomiting	5	6		
Hospital stay (d)	8.625 ± 2.505	11.986 ± 3.908	-3.548	0.001

PONA: Postoperative nausea and vomiting.

**Figure 2** Cumulative sufentanil during the first 48 h after surgery.

ARTICLE HIGHLIGHTS

Research background

The analgesic effect of the preoperative intravenous injection of parecoxib combined with long-acting local anesthetic ropivacaine for incision infiltration in patients undergoing laparoscopic hepatectomy is still unknown.

Research motivation

Analgesic effect of parecoxib combined with ropivacaine in patients undergoing laparoscopic hepatectomy may be promising.

Research objectives

To study the analgesic effect of the preoperative intravenous injection of parecoxib combined with long-acting local anesthetic ropivacaine for incision infiltration in laparoscopic hepatectomy patients.

Research methods

Laparoscopic hepatectomy patients were randomly divided into a combined group (parecoxib combined with ropivacaine) and a control group. The visual analogue scale (VAS) at rest and during movement was used to compare the analgesic effect of the two groups. The cumulative sufentanil, the recovery time for enterokinesia, the length of postoperative hospital stay, and the adverse reactions were recorded and compared between the two groups.

Research results

The VAS scores of the combined group were significantly lower than those of the control group. The recovery time for enterokinesia in the combined group was significantly shorter than that in the control group. The cumulative sufentanil in the combined group decreased significantly at 24, 36, and 48 h after operation.

Research conclusions

Preoperative intravenous injection of parecoxib combined with the long-acting local anesthetic ropivacaine for incision infiltration is a simple and effective method for postoperative analgesia in laparoscopic hepatectomy patients. And it could relieve postoperative pain and promote postoperative recovery.

Research perspectives

Injection of parecoxib combined with the long-acting local anesthetic ropivacaine for incision infiltration is useful for hepatectomy recovery.

REFERENCES

- 1 Reich H, McGlynn F, DeCaprio J, Budin R. Laparoscopic excision of benign liver lesions. *Obstet Gynecol* 1991; **78**: 956-958 [PMID: 1833688]
- 2 Abu Hilal M, Di Fabio F, Teng MJ, Lykoudis P, Primrose JN, Pearce NW. Single-centre comparative study of laparoscopic versus open right hepatectomy. *J Gastrointest Surg* 2011; **15**: 818-823 [PMID: 21380633 DOI: 10.1007/s11605-011-1468-z]
- 3 Dagher I, Di Giuro G, Dubrez J, Lainas P, Smadja C, Franco D. Laparoscopic versus open right hepatectomy: a comparative study. *Am J Surg* 2009; **198**: 173-177 [PMID: 19268902 DOI: 10.1016/j.amjsurg.2008.09.015]
- 4 Wightman JA. A prospective survey of the incidence of postoperative pulmonary complications. *Br J Surg* 1968; **55**: 85-91 [PMID: 5635926 DOI: 10.1002/bjs.1800550202]
- 5 Latimer RG, Dickman M, Day WC, Gunn ML, Schmidt CD. Ventilatory patterns and pulmonary complications after upper abdominal surgery determined by preoperative and postoperative computerized spirometry and blood gas analysis. *Am J Surg* 1971; **122**: 622-632 [PMID: 4939329 DOI: 10.1016/0002-9610(71)90290-X]
- 6 Kelliher L, Jones C, Dickinson M, Scott M, Quiney N. Epidural anaesthesia and analgesia for liver resection. *Anaesthesia* 2013; **68**: 975-976 [PMID: 24047358 DOI: 10.1111/anae.12364]
- 7 Sun JX, Bai KY, Liu YF, Du G, Fu ZH, Zhang H, Yang JH, Wang B, Wang XY, Jin B. Effect of local wound infiltration with ropivacaine on postoperative pain relief and stress response reduction after open hepatectomy. *World J Gastroenterol* 2017; **23**: 6733-6740 [PMID: 29085218 DOI: 10.3748/wjg.v23.i36.6733]
- 8 Schug SA, Joshi GP, Camu F, Pan S, Cheung R. Cardiovascular safety of the cyclooxygenase-2 selective inhibitors parecoxib and valdecoxib in the postoperative setting: an analysis of integrated data. *Anesth Analg* 2009; **108**: 299-307 [PMID: 19095866 DOI: 10.1213/ane.0b013e31818ca3ac]
- 9 Nguyen KT, Gamblin TC, Geller DA. World review of laparoscopic liver resection-2,804 patients. *Ann Surg* 2009; **250**: 831-841 [PMID: 19801936 DOI: 10.1097/SLA.0b013e3181b0c4df]
- 10 Goh BKP, Syn N, Teo JY, Guo YX, Lee SY, Cheow PC, Chow PKH, Ooi LLPJ, Chung AYF, Chan CY. Perioperative Outcomes of Laparoscopic Repeat Liver Resection for Recurrent HCC: Comparison with Open Repeat Liver Resection for Recurrent HCC and Laparoscopic Resection for Primary HCC. *World J Surg* 2019; **43**: 878-885 [PMID: 30361747 DOI: 10.1007/s00268-018-4828-y]
- 11 Tsai KY, Chen HA, Wang WY, Huang MT. Long-term and short-term surgical outcomes of laparoscopic versus open liver resection for hepatocellular carcinoma: might laparoscopic approach be better in early HCC? *Surg Endosc* 2019; **33**: 1131-1139 [PMID: 30043170 DOI: 10.1007/s00464-018-6372-0]
- 12 Ni TG, Yang HT, Zhang H, Meng HP, Li B. Enhanced recovery after surgery programs in patients undergoing hepatectomy: A meta-analysis. *World J Gastroenterol* 2015; **21**: 9209-9216 [PMID: 26290648 DOI: 10.3748/wjg.v21.i30.9209]
- 13 Raja S DC, Shetty AP, Subramanian B, Kanna RM, Rajasekaran S. A prospective randomized study to analyze the efficacy of balanced pre-emptive analgesia in spine surgery. *Spine J* 2019; **19**: 569-577 [PMID: 30359764 DOI: 10.1016/j.spinee.2018.10.010]
- 14 Lieblich S. Pre-Emptive Analgesia. *J Oral Maxillofac Surg* 2017; **75**: 245-246 [PMID: 28328429 DOI: 10.1016/j.joms.2016.12.002]
- 15 Bajaj P, Ballary CC, Dongre NA, Baliga VP, Desai AA. Role of parecoxib in pre-emptive analgesia: comparison of the efficacy and safety of pre- and postoperative parecoxib in patients undergoing general surgery. *J Indian Med Assoc* 2004; **102**: 272, 274, 276-278 [PMID: 15636035]
- 16 Liu Y, Song X, Sun D, Wang J, Lan Y, Yang G, Meng F, Wang Y, Cui Y, Zhang B, Li X, Liu L. Evaluation of Intravenous Parecoxib Infusion Pump of Patient-Controlled Analgesia Compared to Fentanyl for Postoperative Pain Management in Laparoscopic Liver Resection. *Med Sci Monit* 2018; **24**: 8224-8231 [PMID: 30439866 DOI: 10.12659/MSM.913182]
- 17 Byager N, Hansen MS, Mathiesen O, Dahl JB. The analgesic effect of wound infiltration with local anaesthetics after breast surgery: a qualitative systematic review. *Acta Anaesthesiol Scand* 2014; **58**: 402-410 [PMID: 24617619 DOI: 10.1111/aas.12287]
- 18 Kjærgaard M, Moïnche S, Olsen KS. Wound infiltration with local anesthetics for post-operative pain relief in lumbar spine surgery: a systematic review. *Acta Anaesthesiol Scand* 2012; **56**: 282-290 [PMID: 22260370 DOI: 10.1111/j.1399-6576.2011.02629.x]
- 19 Scott NB. Wound infiltration for surgery. *Anaesthesia* 2010; **65** Suppl 1: 67-75 [PMID: 20377548 DOI: 10.1111/j.1365-2044.2010.06241.x]
- 20 Brennan TJ, Zahn PK, Pogatzki-Zahn EM. Mechanisms of incisional pain. *Anesthesiol Clin North Am* 2005; **23**: 1-20 [PMID: 15763408 DOI: 10.1016/j.atc.2004.11.009]
- 21 Kawamata M, Takahashi T, Kozuka Y, Nawa Y, Nishikawa K, Narimatsu E, Watanabe H, Namiki A. Experimental incision-induced pain in human skin: effects of systemic lidocaine on flare formation and hyperalgesia. *Pain* 2002; **100**: 77-89 [PMID: 12435461 DOI: 10.1016/S0304-3959(02)00233-6]
- 22 Kuthiala G, Chaudhary G. Ropivacaine: A review of its pharmacology and clinical use. *Indian J Anaesth* 2011; **55**: 104-110 [PMID: 21712863 DOI: 10.4103/0019-5049.79875]
- 23 White PF. The changing role of non-opioid analgesic techniques in the management of postoperative pain. *Anesth Analg* 2005; **101**: S5-22 [PMID: 16334489 DOI: 10.1213/01.ANE.0000177099.28914.A7]
- 24 Ducrotté P, Caussé C. The Bowel Function Index: a new validated scale for assessing opioid-induced constipation. *Curr Med Res Opin* 2012; **28**: 457-466 [PMID: 22236136 DOI: 10.1185/03007995.2012.657301]



Published By Baishideng Publishing Group Inc
7041 Koll Center Parkway, Suite 160, Pleasanton, CA 94566, USA
Telephone: +1-925-2238242
E-mail: bpgoffice@wjgnet.com
Help Desk: <https://www.f6publishing.com/helpdesk>
<https://www.wjgnet.com>

