

# World Journal of *Clinical Cases*

*World J Clin Cases* 2019 September 26; 7(18): 2658-2915



**OPINION REVIEW**

- 2658** Effective use of the Japan Narrow Band Imaging Expert Team classification based on diagnostic performance and confidence level  
*Hirata D, Kashida H, Iwatate M, Tochio T, Teramoto A, Sano Y, Kudo M*

**MINIREVIEWS**

- 2666** Low fermentable oligosaccharides, disaccharides, monosaccharides, and polyols diet in children  
*Fodor I, Man SC, Dumitrascu DL*
- 2675** High-resolution colonic manometry and its clinical application in patients with colonic dysmotility: A review  
*Li YW, Yu YJ, Fei F, Zheng MY, Zhang SW*

**ORIGINAL ARTICLE****Retrospective Study**

- 2687** Predictors of rebleeding and in-hospital mortality in patients with nonvariceal upper digestive bleeding  
*Lazăr DC, Ursoniu S, Goldiș A*
- 2704** Analgesic effect of parecoxib combined with ropivacaine in patients undergoing laparoscopic hepatectomy  
*Huang SS, Lv WW, Liu YF, Yang SZ*
- 2712** Prognostic significance of 14v-lymph node dissection to D2 dissection for lower-third gastric cancer  
*Zheng C, Gao ZM, Sun AQ, Huang HB, Wang ZN, Li K, Gao S*

**Observational Study**

- 2722** Wall shear stress can improve prediction accuracy for transient ischemic attack  
*Liu QY, Duan Q, Fu XH, Jiang M, Xia HW, Wan YL*

**Prospective Study**

- 2734** Characterization of microbiota in systemic-onset juvenile idiopathic arthritis with different disease severities  
*Dong YQ, Wang W, Li J, Ma MS, Zhong LQ, Wei QJ, Song HM*

**SYSTEMATIC REVIEWS**

- 2746** Sinusoidal obstruction syndrome: A systematic review of etiologies, clinical symptoms, and magnetic resonance imaging features  
*Zhang Y, Jiang HY, Wei Y, Song B*

**META-ANALYSIS**

- 2760** Respiratory training interventions improve health status of heart failure patients: A systematic review and network meta-analysis of randomized controlled trials  
*Wang MH, Yeh ML*

**CASE REPORT**

- 2776** *Mycobacterium chimaera* infections following cardiac surgery in Treviso Hospital, Italy, from 2016 to 2019: Cases report  
*Inojosa WO, Giobbia M, Muffato G, Minniti G, Baldasso F, Carniato A, Farina F, Forner G, Rossi MC, Formentini S, Rigoli R, Scotton PG*
- 2787** Giant squamous cell carcinoma of the gallbladder: A case report  
*Junior MAR, Favaro MDL, Santin S, Silva CM, Iamarino APM*
- 2794** Liver re-transplantation for donor-derived neuroendocrine tumor: A case report  
*Mrzljak A, Kocman B, Skrtic A, Furac I, Popic J, Franusic L, Zunec R, Mayer D, Mikulic D*
- 2802** Calcifying fibrous tumor originating from the gastrohepatic ligament that mimicked a gastric submucosal tumor: A case report  
*Kwan BS, Cho DH*
- 2808** Pancreatitis, panniculitis, and polyarthritides syndrome caused by pancreatic pseudocyst: A case report  
*Jo S, Song S*
- 2815** Glomus tumor of uncertain malignant potential of the brachial plexus: A case report  
*Thanindrarn P, Chobpenthai T, Phorkhar T, Nelson SD*
- 2823** Conservative pulp treatment for Oehlers type III dens invaginatus: A case report  
*Lee HN, Chen YK, Chen CH, Huang CY, Su YH, Huang YW, Chuang FH*
- 2831** Propofol pump controls nonconvulsive status epilepticus in a hepatic encephalopathy patient: A case report  
*Hor S, Chen CY, Tsai ST*
- 2838** Teriparatide as nonoperative treatment for femoral shaft atrophic nonunion: A case report  
*Tsai MH, Hu CC*
- 2843** Successful repair of acute type A aortic dissection during pregnancy at 16<sup>th</sup> gestational week with maternal and fetal survival: A case report and review of the literature  
*Chen SW, Zhong YL, Ge YP, Qiao ZY, Li CN, Zhu JM, Sun LZ*
- 2851** Inferior pancreaticoduodenal artery pseudoaneurysm in a patient with calculous cholecystitis: A case report  
*Xu QD, Gu SG, Liang JH, Zheng SD, Lin ZH, Zhang PD, Yan J*

- 2857** ALK-positive anaplastic large cell lymphoma of the thoracic spine occurring in pregnancy: A case report  
*Yang S, Jiang WM, Yang HL*
- 2864** Endoscopic mucosal resection of a bile duct polyp: A case report  
*Yang S, Yang L, Wang XY, Yang YM*
- 2871** Multiple gastric adenocarcinoma of fundic gland type: A case report  
*Chen O, Shao ZY, Qiu X, Zhang GP*
- 2879** Repair of the portal vein using a hepatic ligamentum teres patch for laparoscopic pancreatoduodenectomy: A case report  
*Wei Q, Chen QP, Guan QH, Zhu WT*
- 2888** Drug coated balloon angioplasty for renal artery stenosis due to Takayasu arteritis: Report of five cases  
*Bi YH, Ren JZ, Yi MF, Li JD, Han XW*
- 2894** Entrapment of the temporal horn secondary to postoperative gamma-knife radiosurgery in intraventricular meningioma: A case report  
*Liu J, Long SR, Li GY*
- 2899** Pleomorphic lipoma in the anterior mediastinum: A case report  
*Mao YQ, Liu XY, Han Y*
- 2905** Guillain-Barré syndrome in a patient with multiple myeloma after bortezomib therapy: A case report  
*Xu YL, Zhao WH, Tang ZY, Li ZQ, Long Y, Cheng P, Luo J*
- 2910** Bowen's disease on the palm: A case report  
*Yu SR, Zhang JZ, Pu XM, Kang XJ*

**ABOUT COVER**

Editorial Board Member of *World Journal of Clinical Cases*, Shao-Ping Yu, MD, Associate Professor, Chief Doctor, Department of Gastroenterology and Hepatology, Dongguan Kanghua Hospital, Dongguan 523080, Guangdong Province, China

**AIMS AND SCOPE**

The primary aim of *World Journal of Clinical Cases* (WJCC, *World J Clin Cases*) is to provide scholars and readers from various fields of clinical medicine with a platform to publish high-quality clinical research articles and communicate their research findings online.

WJCC mainly publishes articles reporting research results and findings obtained in the field of clinical medicine and covering a wide range of topics, including case control studies, retrospective cohort studies, retrospective studies, clinical trials studies, observational studies, prospective studies, randomized controlled trials, randomized clinical trials, systematic reviews, meta-analysis, and case reports.

**INDEXING/ABSTRACTING**

The WJCC is now indexed in PubMed, PubMed Central, Science Citation Index Expanded (also known as SciSearch®), and Journal Citation Reports/Science Edition. The 2019 Edition of Journal Citation Reports cites the 2018 impact factor for WJCC as 1.153 (5-year impact factor: N/A), ranking WJCC as 99 among 160 journals in Medicine, General and Internal (quartile in category Q3).

**RESPONSIBLE EDITORS FOR THIS ISSUE**

Responsible Electronic Editor: Ji-Hong Liu

Proofing Production Department Director: Yun-Xiaojuan Wu

**NAME OF JOURNAL**

*World Journal of Clinical Cases*

**ISSN**

ISSN 2307-8960 (online)

**LAUNCH DATE**

April 16, 2013

**FREQUENCY**

Semimonthly

**EDITORS-IN-CHIEF**

Dennis A Bloomfield, Bao-Gan Peng, Sandro Vento

**EDITORIAL BOARD MEMBERS**

<https://www.wjgnet.com/2307-8960/editorialboard.htm>

**EDITORIAL OFFICE**

Jin-Lei Wang, Director

**PUBLICATION DATE**

September 26, 2019

**COPYRIGHT**

© 2019 Baishideng Publishing Group Inc

**INSTRUCTIONS TO AUTHORS**

<https://www.wjgnet.com/bpg/gerinfo/204>

**GUIDELINES FOR ETHICS DOCUMENTS**

<https://www.wjgnet.com/bpg/GerInfo/287>

**GUIDELINES FOR NON-NATIVE SPEAKERS OF ENGLISH**

<https://www.wjgnet.com/bpg/gerinfo/240>

**PUBLICATION MISCONDUCT**

<https://www.wjgnet.com/bpg/gerinfo/208>

**ARTICLE PROCESSING CHARGE**

<https://www.wjgnet.com/bpg/gerinfo/242>

**STEPS FOR SUBMITTING MANUSCRIPTS**

<https://www.wjgnet.com/bpg/GerInfo/239>

**ONLINE SUBMISSION**

<https://www.f6publishing.com>

## Effective use of the Japan Narrow Band Imaging Expert Team classification based on diagnostic performance and confidence level

Daizen Hirata, Hiroshi Kashida, Mineo Iwatate, Tomomasa Tochio, Akira Teramoto, Yasushi Sano, Masatoshi Kudo

**ORCID number:** Daizen Hirata (0000-0001-7255-6129); Hiroshi Kashida (0000-0002-7186-600X); Mineo Iwatate (0000-0003-3782-3687); Tomomasa Tochio (0000-0003-3082-3721); Akira Teramoto (0000-0003-4031-3012); Yasushi Sano (0000-0002-3352-5757); Masatoshi Kudo (0000-0002-4102-3474).

**Author contributions:** Hirata D, Kashida H, Sano Y and Kudo M designed research; Hirata D, Iwatate M, Tochio T, Teramoto A and Sano Y performed research; Hirata D and Iwatate M performed literature review; Hirata D and Iwatate M analyzed data; Hirata D wrote the paper; Kashida H and Kudo M contributed critical revision and editing.

**Conflict-of-interest statement:** No potential conflicts of interest. No financial support.

**Data sharing statement:** No additional data are available.

**Open-Access:** This article is an open-access article which was selected by an in-house editor and fully peer-reviewed by external reviewers. It is distributed in accordance with the Creative Commons Attribution Non Commercial (CC BY-NC 4.0) license, which permits others to distribute, remix, adapt, build upon this work non-commercially, and license their derivative works on different terms, provided the original work is properly cited and the use is non-commercial. See: <http://creativecommons.org/licenses/by-nc/4.0/>

**Daizen Hirata, Mineo Iwatate, Tomomasa Tochio, Akira Teramoto, Yasushi Sano,** Gastrointestinal Center and Institute of Minimally-invasive Endoscopic Care, Sano Hospital, Kobe 6550031, Japan

**Daizen Hirata, Hiroshi Kashida, Masatoshi Kudo,** Department of Gastroenterology and Hepatology, Kindai University, Osaka 5895811, Japan

**Corresponding author:** Daizen Hirata, MD, Doctor, Gastrointestinal Center and Institute of Minimally-invasive Endoscopic Care, Sano Hospital, 2-5-1 Shimizugaoka, Tarumi-ku, Kobe 6550031, Japan. [daizenhirata@gmail.com](mailto:daizenhirata@gmail.com)

**Telephone:** +81-78-7851000

**Fax:** +81-78-7850077

### Abstract

Five years have passed since the Japan Narrow Band Imaging Expert Team (JNET) classification was proposed in 2014. However, the diagnostic performance of this classification has not yet been established. We conducted a retrospective study and a systematic search of Medical Literature Analysis and Retrieval System On-Line. There were three retrospective single center studies about the diagnostic performance of this classification. In order to clarify this issue, we reviewed our study and three previous studies. This review revealed the diagnostic performance in regards to three important differentiations. (1) Neoplasia from non-neoplasia; (2) malignant neoplasia from benign neoplasia; and (3) deep submucosal invasive cancer (D-SMC) from other neoplasia. The sensitivity in differentiating neoplasia from non-neoplasia was 98.1%-99.8%. The specificity in differentiating malignant neoplasia from benign neoplasia was 84.7%-98.2% and the specificity in the differentiation D-SMC from other neoplasia was 99.8%-100.0%. This classification would enable endoscopists to identify almost all neoplasia, to appropriately determine whether to perform en bloc resection or not, and to avoid unnecessary surgery. This article is the first review about the diagnostic performance of the JNET classification. Previous reports about the diagnostic performance have all been retrospective single center studies. A large-scale prospective multicenter evaluation study is awaited for the validation.

**Key words:** Japan Narrow Band Imaging Expert Team; Classification; Magnifying endoscopy; Narrow-band imaging; Validation; Diagnostic performance; Colonoscopy; Colorectal neoplasms

**Manuscript source:** Invited Manuscript

**Received:** June 4, 2019

**Peer-review started:** June 4, 2019

**First decision:** July 21, 2019

**Revised:** August 18, 2019

**Accepted:** August 27, 2019

**Article in press:** August 26, 2019

**Published online:** September 26, 2019

**P-Reviewer:** Eyraud D

**S-Editor:** Tang JZ

**L-Editor:** Filipodia

**E-Editor:** Qi LL



©The Author(s) 2019. Published by Baishideng Publishing Group Inc. All rights reserved.

**Core tip:** This is the first review of the Japan Narrow Band Imaging Expert Team classification regarding the diagnostic performance. There are three important differentiations: neoplasia from non-neoplasia, malignant neoplasia from benign neoplasia, and deep submucosal invasive cancer (D-SMC) from other neoplasia. The sensitivity in differentiating neoplasia from non-neoplasia was 98.1%-99.8%. The specificity in differentiating malignant neoplasia from benign neoplasia was 84.7%-98.2% and the specificity in differentiating D-SMC from other neoplasia was 99.8%-100.0%. This classification will enable endoscopists to identify almost all neoplasia, to appropriately determine whether to perform en bloc resection or not, and to avoid unnecessary surgery.

**Citation:** Hirata D, Kashida H, Iwatate M, Tochio T, Teramoto A, Sano Y, Kudo M. Effective use of the Japan Narrow Band Imaging Expert Team classification based on diagnostic performance and confidence level. *World J Clin Cases* 2019; 7(18): 2658-2665

**URL:** <https://www.wjgnet.com/2307-8960/full/v7/i18/2658.htm>

**DOI:** <https://dx.doi.org/10.12998/wjcc.v7.i18.2658>

## INTRODUCTION

The Sano classification was proposed as the first Narrow Band Imaging (NBI) classification in 2006<sup>[1]</sup>. Following this, three classifications were proposed in Japan<sup>[2-4]</sup>. Colon Tumor NBI Interest Group proposed the Narrow Band Imaging International Colorectal Endoscopic (NICE) classification in 2009 (Figure 1). The NICE classification is easily applicable and can be used without magnification. However, previous validation studies revealed two problems with the NICE classification. One was that the confidence rate was reported to be only 50%-75%<sup>[5,6]</sup> though the diagnostic performance was acceptable in cases with high confidence. This means that the amount of polyps that can be diagnosed by the NICE classification is not high enough. The other problem was that endoscopists could not differentiate malignant neoplasia [high grade intramucosal neoplasia (HGIN) and invasive cancer] from benign neoplasia [low grade intramucosal neoplasia (LGIN)] using the NICE classification. This differentiation is clinically valuable for deciding treatment options because the invasion depth of malignant neoplasia should be evaluated by the specimen obtained en-bloc by endoscopic mucosal resection (EMR) or endoscopic submucosal dissection (ESD). In 2014, the Japan Narrow Band Imaging Expert Team (JNET) classification was published and showed the NBI diagnosis with magnification had the potential to increase the confidence rate and enable endoscopists to differentiate malignant neoplasia from benign neoplasia<sup>[7,8]</sup>.

The JNET classification consists of 4 categories; JNET type 1, type 2A, type 2B, and type 3. Each type represents the histological features of the polyps, and they are categorized by focusing on two specific features, the vessel pattern and the surface pattern (Figure 2). JNET type 1 refers to hyperplastic polyps and sessile serrated polyps. Type 2A refers to LGIN and type 2B corresponds to HGIN or shallow submucosal invasive cancer (S-SMC). Type 3 refers to deep submucosal invasive cancer (D-SMC).

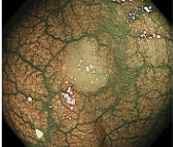
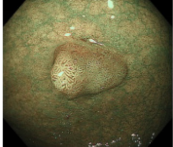
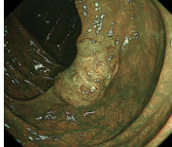
The aim of this review is to reveal the diagnostic performance and the confidence level of the JNET classification. Since there were no previous studies concerning the diagnostic performance and the confidence level of the JNET classification, we analyzed them based on the study data compiled at Sano hospital.

In this review we evaluate the diagnostic performance of the JNET classification and its confidence level (high or low) based on data from the study conducted at Sano Hospital from March 2015 to September 2018, and also those from the systematic review carried out in Medical Literature Analysis and Retrieval System On-Line (MEDLINE) from January 2014 through March 2019.

## OUR STUDY

We investigated the diagnostic performance of the JNET classification including its



	Type 1	Type 2	Type 3
<b>Color</b>	Same or lighter than background	Browner relative to background (verify color arises from vessels)	Brown to dark brown relative to background; sometimes patchy whiter areas
<b>Vessels</b>	None, or isolated lacy vessels may be present coursing across the lesion	Brown vessels surrounding white structures <sup>2</sup>	Has area(s) of disrupted or missing vessels
<b>Surface pattern</b>	Dark or white spots of uniform size, or homogeneous absence of pattern	Oval, tubular or branched white structures <sup>2</sup> surrounded by brown vessels	Amorphous or absent surface pattern
<b>Most likely pathology</b>	<b>Hyperplastic &amp; SSP<sup>3</sup></b>	<b>Adenoma<sup>4</sup></b>	<b>Deep submucosal invasive cancer</b>
<b>Endoscopic image</b>			

**Figure 1 Narrow Band Imaging International Colorectal Endoscopic classification**<sup>1</sup>.<sup>1</sup>Can be applied using colonoscopes with/ without optical (zoom) magnification. <sup>2</sup>These structures (regular or irregular) may represent the pits and the epithelium of the crypt opening. <sup>3</sup>In the WHO classification, sessile serrated polyp and sessile serrated adenoma are synonymous. <sup>4</sup>Type 2 consists of Vienna classification types 3, 4 and superficial 5 (all adenomas with either low or high grade dysplasia, or with superficial submucosal carcinoma). The presence of high grade dysplasia or superficial submucosal carcinoma may be suggested by an irregular vessel or surface pattern, and is often associated with atypical morphology. SSP: Sessile serrated polyp.

confidence level (high or low) at Sano Hospital from March 2015 to September 2018. In this study, all colorectal polyps were diagnosed using the JNET classification before endoscopic resection or surgery. NBI magnifying observation was performed by 5 experts and 3 trainees. “High-confidence diagnosis” is defined as a diagnosis that the endoscopist has confidence of more than 90% probability. Both the endoscopic diagnosis and confidence level were recorded in real time during the colonoscopy, and the histopathological diagnosis was reported by an expert pathologist. We evaluated the relation between the JNET type, its confidence level, and the histopathological diagnosis for all polyps as the primary endpoint. The diagnostic performance and the high confidence rate were analyzed based on this data. We evaluated the diagnostic performance in differentiating “neoplasia (type 2A) from non-neoplasia (type 1)”, “Malignant neoplasia (type 2B, 3) vs Benign neoplasia (type 2A)”, and “Deep submucosal invasive cancer (type 3) from other neoplasia (type 2A, 2B)”.

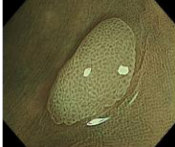
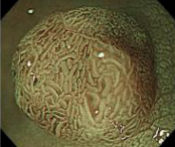
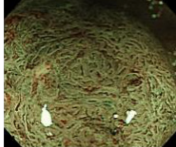
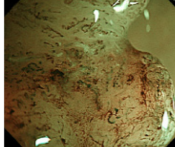
## LITERATURE SEARCH

For the purpose of this review, a systematic search was carried out in MEDLINE from January 2014 through March 2019. Keywords included “the Japan NBI Expert Team” or “JNET classification” by two endoscopists. Non-English articles were excluded. Fourteen articles were selected. Non-original articles were also excluded. The full texts of 12 original articles were reviewed. Articles about the diagnostic performance were included. Articles about other modalities and other issues such as study protocol and treatment were excluded. Finally, 3 original articles were selected and included in this study (Figure 3)<sup>[9-11]</sup>.

## DIAGNOSTIC PERFORMANCE WITH ITS CONFIDENCE LEVEL IN OUR STUDY

The authors examined 6138 colorectal polyps which were diagnosed using the JNET classification before endoscopic resection or surgery from March 2015 to September 2018. The histopathological diagnosis of the 6138 polyps were 979 hyperplastic polyps, 244 sessile serrated polyps, 4642 LGIN, 214 HGIN or S-SMC, and 59 D-SMC. Five thousand six hundred twenty-four polyps were diagnosed with high confidence. The high confidence rate was 91.6%. The relation between the JNET classification (with or without confidence level) and the histopathological diagnosis is shown in Table 1. Rate of correspondence between each JNET type and the histopathological diagnosis was 85.4%.



	Type 1	Type 2A	Type 2B	Type 3
<b>Vessel pattern</b>	•Invisible <sup>1</sup>	•Regular caliber •Regular distribution (meshed/spiral pattern) <sup>2</sup>	•Variable caliber •Irregular distribution	•Loose vessel areas •Interruption of thick vessels
<b>Surface pattern</b>	•Regular dark or white spots •Similar to surrounding normal mucosa	•Regular (tubular/branched/papillary)	•Irregular or obscure	•Amorphous areas
<b>Most likely histology</b>	Hyperplastic polyp/ Sessile serrated polyp	Low grade intramucosal neoplasia	High grade intramucosal neoplasia/ Shallow submucosal invasive cancer <sup>3</sup>	Deep submucosal invasive cancer
<b>Endoscopic image</b>				

**Figure 2 The Japan Narrow Band Imaging Expert Team classification.**<sup>1</sup>If visible, the caliber in the lesion is similar to surrounding normal mucosa. <sup>2</sup>Micro-vessels are often distributed in a punctate pattern and well-ordered reticular or spiral vessels may not be observed in depressed lesions. <sup>3</sup>Deep submucosal invasive cancer may be included.

## PREVIOUS REPORTS ABOUT THE DIAGNOSTIC PERFORMANCE OF THE JAPAN NARROW BAND IMAGING EXPERT TEAM CLASSIFICATION

Three articles about the diagnostic performance were reviewed in this study. These articles and our study are summarized in [Table 2](#)<sup>[9-11]</sup>.

Sumimoto *et al*<sup>[9]</sup> conducted a retrospective analysis of 2933 colorectal lesions (136 hyperplastic polyps/sessile serrated polyps, 1926 LGIN, 571 HGIN, 87 S-SMC, and 213 D-SMC). The accuracy of type 1, 2A, 2B, and 3 were 99.3%, 77.1%, 78.1%, and 96.6% respectively.

Komeda *et al*<sup>[10]</sup> performed a retrospective image evaluation study in 199 colorectal lesions (14 hyperplastic polyps/sessile serrated polyps, 127 LGIN, 22 HGIN, 19 S-SMC, and 17 D-SMC). The accuracy of type 1, 2A, 2B, and 3 were 98.5%, 90.9%, 87.4%, and 94.0%, respectively. They also analyzed of the relation between the macroscopic type and the diagnostic performance. They concluded that the JNET classification was useful for the diagnosis of hyperplastic polyps, sessile serrated polyps, LGIN, HGIN and D-SMC, but not S-SMC.

Minoda *et al*<sup>[11]</sup> conducted a retrospective image evaluation study of 40 colorectal lesions involving 22 doctors (11experts and 11 non-gastrointestinal trainees). The average diagnostic accuracy was 76.6% for the experts and 61.4% for the trainees, though the relation between the JNET classification and the histopathological diagnosis was not disclosed. They concluded that the JNET classification was useful for differentiating malignant polyps from benign ones for every doctor. They also revealed orientation and training were necessary to use this system adequately even for experienced colonoscopists.

## THE DIAGNOSTIC PERFORMANCE OF THE JAPAN NARROW BAND IMAGING EXPERT TEAM CLASSIFICATION

The diagnostic performance is important in determining the treatment strategy. In particular, the three differentiations: neoplasia (type 2A) *vs* non neoplasia (type 1), malignant neoplasia (type 2B, 3) *vs* benign neoplasia (type 2A), and deep submucosal invasive cancer (type 3) from other neoplasia (type 2A, 2B). The details of each diagnostic performance are shown in [Table 3-5](#). We analyzed the diagnostic performance for each differentiation in our study and the previous reports. Minoda's report was excluded in these analyses, since necessary details and relations were not disclosed.

### Neoplasia (type 2A) *vs* non neoplasia (type 1)

The diagnostic performance in differentiating neoplasia (type 2A) from non-neoplasia (type 1) is directly associated with the necessity of endoscopic treatment. Type 2A polyps should be resected by polypectomy. However, it is usually not necessary to resect type1 polyps. The sensitivity, the accuracy and the negative predictive value (NPV) were 98.1%-99.8%, 88.8%-99.0%, and 88.9%-99.1%, respectively. According to this classification, endoscopists can identify almost all neoplasia.

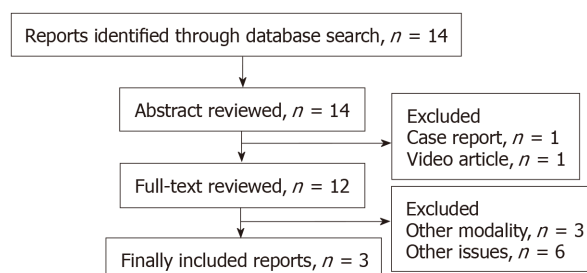


Figure 3 Flow diagram of study selection.

In high confidence cases, counting 93.1% among all polyps, they were high enough to enable “Detect InSpec ChAractrise Resect and Discard strategy”, according to “Preservation and incorporation of valuable endoscopic innovations initiative” from American Society For Gastrointestinal Endoscopy<sup>[12,13]</sup>.

### **Malignant neoplasia (type 2B, 3) vs benign neoplasia (type 2A)**

The diagnostic performance in differentiating malignant neoplasia from benign neoplasia is associated with the necessity of en bloc resection. While type 2A polyps can be treated by piecemeal EMR or polypectomy, type 2B polyps should be resected en bloc to obtain a precise histologic diagnosis from the specimen. The accuracy, specificity, and NPV of this diagnosis are 80.7%-96.1%, 84.7%-98.2%, and 87.0%-97.7%, respectively. This is considered beneficial in diagnosing polyps as malignant neoplasm. By using the JNET classification, endoscopist can appropriately determine whether to perform en bloc resection or not.

### **Deep submucosal invasive cancer (type 3) from other neoplasia (type 2A, 2B)**

The diagnostic performance in differentiating deep submucosal invasive cancer from other neoplasia is associated with the necessity of surgical resection. As for this distinction, the specificity was extremely high being 99.8%-100.0%. The JNET classification enables endoscopists to avoid unnecessary surgery for non-invasive neoplasia. In our study, the unnecessary surgeries were only two cases. On the other hand, 10.6%-23.9% of type 2B lesions were D-SMCs, and 0.0%-5.1% of type 3 lesions were S-SMCs. Additional magnifying chromoendoscopy is recommended in cases where it is difficult to differentiate between shallow and deep submucosal invasive cancers.

## **DISCUSSION**

This is the first review concerning the diagnostic performance of the JNET classification taking account of the confidence level. Based on this review, we propose treatment strategy for colorectal localized lesions using the JNET classification with its confidence level (Figure 4).

Type 1 polyps generally do not need resection except for sessile serrated polyps<sup>[14]</sup>. Type 2A polyps shall be resected by polypectomy or EMR. Utsumi *et al*<sup>[15]</sup> reported that additional chromoendoscopy in type 1 and 2A polyps with low confidence prediction did not improve accuracy enough. Therefore, additional chromoendoscopy is considered to be unnecessary in order to differentiate type from type 1.

Whereas type 2A polyps can be resected by piecemeal EMR, type 2B polyps should be resected en bloc by EMR or ESD to obtain a precise histologic diagnosis concerning the invasion depth and determining endoscopic curability. Our review revealed the usefulness of the JNET classification, in that it accurately differentiated malignant polyps (type 2B, 3) from benign (type 2A). It should be noted that 37.3%-70.6% of deep submucosal invasive cancers showed type 2B findings, magnifying chromoendoscopy is recommended before high-risk endoscopic resection for deep submucosal invasive cancer in type 2B polyps, if it is available. Type 3 lesions were diagnosed to be D-SMC with more than 99% specificity in our review, and therefore they are indicated for surgical resection.

The JNET classification is considered to have as high diagnostic performance as the NICE classification. However, there have been no studies directly comparing the JNET classification with the NICE classification. For comparison with the NICE classification, we evaluated the diagnostic performance with high confidence prediction and the high confidence rate in regards to two differentiations; “Neoplasia *vs* non neoplasia” and “Deep submucosal invasive cancer *vs* other neoplasia” (Table

**Table 1** The relation between the Japan Narrow Band Imaging Expert Team classification and the histopathological diagnosis at Sano Hospital

OA (HC), <i>n</i>	HP, SSP	LGIN	HGIN, S-SMC	D-SMC
Type 1	653 (564)	90 (48)	0	0
Type 2A	570 (440)	4459 (4289)	119 (118)	0
Type 2B	0	93 (42)	93 (65)	22 (21)
Type 3	0	0	2 (2)	37 (35)

OA: Overall cases; HC: High confidence cases; HP: Hyperplastic polyp; SSP: Sessile serrated polyp; LGIN: Low grade intramucosal neoplasia; HGIN: High grade intramucosal neoplasia; S-SMC: Shallow submucosal invasive cancer; D-SMC: Deep submucosal invasive cancer.

**Table 2** Reports about diagnostic performance of the Japan Narrow Band Imaging Expert Team Classification

First author	Cases, <i>n</i>	Participants
Sumimoto <i>et al</i> <sup>[9]</sup>	2933	3 experts
Komeda <i>et al</i> <sup>[10]</sup>	199	3 experts
Minoda <i>et al</i> <sup>[11]</sup>	40	11 experts and 11 non-GI trainees
Our study	6138	5 experts and 3 trainees

**Table 3** Neoplasia (type 2A) vs non neoplasia (type 1)

First author	Sumimoto	Komeda
Accuracy, %	99.0	98.0
Sensitivity, %	99.8	99.3
Specificity, %	87.5	85.7
PPV, %	99.1	98.5
NPV, %	97.5	92.3

PPV: Positive predictive value; NPV: Negative predictive value.

6). In both differentiations, the high confidence rate in the JNET classification was significantly higher than that of the NICE classification. It may demonstrate the JNET classification is clearer and easier to use than the NICE classification for the endoscopists. Magnifying observation may increase the high confidence rate of endoscopic diagnosis.

The JNET classification is compatible with the NICE classification in that both classifications are divided into three major categories (type 1, 2, and 3) corresponding to the similar histopathology. The NICE type 2 corresponds approximately to the JNET type 2A and type 2B. Thanks to this similarity, endoscopists using the NICE classification should be able to use the JNET classification easily. A video article explaining typical examples and key points will help to adopt the JNET classification<sup>[16]</sup>.

The limitation in this review is that there were only 3 articles about the diagnostic performance of the JNET classification. The previous studies were all retrospective single center studies. A large-scale prospective multicenter validation study of the JNET classification is awaited in the future. About the comparison the JNET classification with the NICE classification, though it is better to compare in the same endoscopic and histopathologic center, we did not such a comparative trial yet.

We predict that the JNET classification will provide endoscopists with a useful treatment strategy based on precise histopathological predictions and a higher confidence level for optical diagnosis.

## CONCLUSION

The JNET classification enables endoscopists to identify almost all neoplasia, to appropriately determine whether to perform en bloc resection or not, and to avoid unnecessary surgery.

**Table 4 Malignant neoplasia (type 2B, 3) vs benign neoplasia (type 2A)**

First author	Sumimoto	Komeda	Our study
Accuracy, %	80.7	91.9	96.1
Sensitivity, %	71.9	81.0	56.4
Specificity, %	84.7	96.9	98.2
PPV, %	67.8	92.2	62.3
NPV, %	87.0	91.9	97.7

PPV: Positive predictive value; NPV: Negative predictive value.

**Table 5 Deep submucosal invasive cancer (type 3) vs other neoplasia (type 2A, 2B)**

First author	Sumimoto	Komeda	Our study
Accuracy, %	96.4	93.5	99.6
Sensitivity, %	55.4	29.4	62.7
Specificity, %	99.8	100.0	100.0
PPV, %	95.2	100.0	94.9
NPV, %	96.4	93.4	99.6

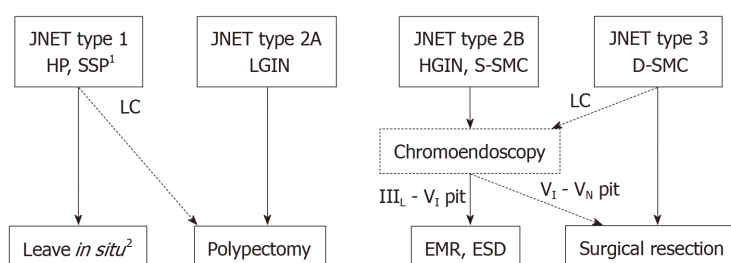
PPV: Positive predictive value; NPV: Negative predictive value.

**Table 6 Comparison with Narrow Band Imaging International Colorectal Endoscopic classification**

Diagnosis	Neoplasia vs non neoplasia <sup>1</sup>		Deep submucosal invasive cancer vs other neoplasia <sup>2</sup>	
Classification	JNET	NICE <sup>[5]</sup>	JNET	NICE <sup>[6]</sup>
Overall, <i>n</i>	5891	236	4825	400
Accuracy, %	91.3	89	96.8	90
Sensitivity, %	99.0	98	51.0	92
Specificity, %	56.2	69	99.1	88
PPV, %	91.2	87	74.5	88
NPV, %	92.2	95	97.6	92
High confidence rate, %	93.1	75	92.9	

<sup>1</sup>Neoplasia vs non neoplasia; JNET 1 vs 2A,2B and NICE 1 vs 2.

<sup>2</sup>Deep submucosal invasive cancer vs other neoplasia; JNET 2A,2B vs 3 and NICE 2 vs 3. PPV: Positive predictive value; NPV: Negative predictive value; JNET: Japan Narrow Band Imaging Expert Team; NICE: Narrow Band Imaging International Colorectal Endoscopic.



**Figure 4 Treatment strategy of colorectal lesions using the Japan Narrow Band Imaging Expert Team classification.**<sup>1</sup>Any polyps suspected of SSPs should be resected by endoscopic treatment. <sup>2</sup>Hyperplastic polyps less than 5mm in size are commonly left *in situ*. HP: Hyperplastic polyp; SSP: Sessile serrated polyp; LGIN: Low grade intramucosal neoplasia; HGIN: High grade intramucosal neoplasia; S-SMC: Shallow submucosal invasive cancer; D-SMC: Deep submucosal invasive cancer; LC: Low confidence.

## REFERENCES

- 1 Sano Y, Horimatsu T, Fu KI, Katagiri A, Muto M, Ishikawa H. Magnifying observation of microvascular architecture of colorectal lesions using a narrow band imaging system. *Dig Endosc* 2006; **18** Suppl 1: S44-S51 [DOI: [10.1111/j.1443-1661.2006.00621.x](https://doi.org/10.1111/j.1443-1661.2006.00621.x)]
- 2 Wada Y, Kudo SE, Kashida H, Ikehara N, Inoue H, Yamamura F, Ohtsuka K, Hamatani S. Diagnosis of colorectal lesions with the magnifying narrow-band imaging system. *Gastrointest Endosc* 2009; **70**: 522-531 [PMID: [19576581](https://pubmed.ncbi.nlm.nih.gov/19576581/) DOI: [10.1016/j.gie.2009.01.040](https://doi.org/10.1016/j.gie.2009.01.040)]
- 3 Nikami T, Saito S, Tajiri H, Ikegami M. The evaluation of histological atypia and depth of invasion of colorectal lesions using magnified endoscopy with narrow-band imaging. *Gastroenterol Endosc* 2009; **51**: 10-19 [DOI: [10.11280/gee.51.10](https://doi.org/10.11280/gee.51.10)]
- 4 Hirata M, Tanaka S, Oka S, Kaneko I, Yoshida S, Yoshihara M, Chayama K. Magnifying endoscopy with narrow band imaging for diagnosis of colorectal tumors. *Gastrointest Endosc* 2007; **65**: 988-995 [PMID: [17324407](https://pubmed.ncbi.nlm.nih.gov/17324407/) DOI: [10.1016/j.gie.2006.07.046](https://doi.org/10.1016/j.gie.2006.07.046)]
- 5 Hewett DG, Kaltenbach T, Sano Y, Tanaka S, Saunders BP, Ponchon T, Soetikno R, Rex DK. Validation of a simple classification system for endoscopic diagnosis of small colorectal polyps using narrow-band imaging. *Gastroenterology* 2012; **143**: 599-607.e1 [PMID: [22609383](https://pubmed.ncbi.nlm.nih.gov/22609383/) DOI: [10.1053/j.gastro.2012.05.006](https://doi.org/10.1053/j.gastro.2012.05.006)]
- 6 Hayashi N, Tanaka S, Hewett DG, Kaltenbach TR, Sano Y, Ponchon T, Saunders BP, Rex DK, Soetikno RM. Endoscopic prediction of deep submucosal invasive carcinoma: validation of the narrow-band imaging international colorectal endoscopic (NICE) classification. *Gastrointest Endosc* 2013; **78**: 625-632 [PMID: [23910062](https://pubmed.ncbi.nlm.nih.gov/23910062/) DOI: [10.1016/j.gie.2013.04.185](https://doi.org/10.1016/j.gie.2013.04.185)]
- 7 Sano Y, Tanaka S, Kudo SE, Saito S, Matsuda T, Wada Y, Fujii T, Ikematsu H, Uraoka T, Kobayashi N, Nakamura H, Hotta K, Horimatsu T, Sakamoto N, Fu KI, Tsuruta O, Kawano H, Kashida H, Takeuchi Y, Machida H, Kusaka T, Yoshida N, Hirata I, Terai T, Yamano HO, Kaneko K, Nakajima T, Sakamoto T, Yamaguchi Y, Tamai N, Nakano N, Hayashi N, Oka S, Iwatate M, Ishikawa H, Murakami Y, Yoshida S, Saito Y. Narrow-band imaging (NBI) magnifying endoscopic classification of colorectal tumors proposed by the Japan NBI Expert Team. *Dig Endosc* 2016; **28**: 526-533 [PMID: [26927367](https://pubmed.ncbi.nlm.nih.gov/26927367/) DOI: [10.1111/den.12644](https://doi.org/10.1111/den.12644)]
- 8 Iwatate M, Sano Y, Tanaka S, Kudo SE, Saito S, Matsuda T, Wada Y, Fujii T, Ikematsu H, Uraoka T, Kobayashi N, Nakamura H, Hotta K, Horimatsu T, Sakamoto N, Fu KI, Tsuruta O, Kawano H, Kashida H, Takeuchi Y, Machida H, Kusaka T, Yoshida N, Hirata I, Terai T, Yamano HO, Nakajima T, Sakamoto T, Yamaguchi Y, Tamai N, Nakano N, Hayashi N, Oka S, Ishikawa H, Murakami Y, Yoshida S, Saito Y; Japan NBI Expert Team (JNET). Validation study for development of the Japan NBI Expert Team classification of colorectal lesions. *Dig Endosc* 2018; **30**: 642-651 [PMID: [29603399](https://pubmed.ncbi.nlm.nih.gov/29603399/) DOI: [10.1111/den.13065](https://doi.org/10.1111/den.13065)]
- 9 Sumimoto K, Tanaka S, Shigita K, Hirano D, Tamaru Y, Ninomiya Y, Asayama N, Hayashi N, Oka S, Arihiro K, Yoshihara M, Chayama K. Clinical impact and characteristics of the narrow-band imaging magnifying endoscopic classification of colorectal tumors proposed by the Japan NBI Expert Team. *Gastrointest Endosc* 2017; **85**: 816-821 [PMID: [27460392](https://pubmed.ncbi.nlm.nih.gov/27460392/) DOI: [10.1016/j.gie.2016.07.035](https://doi.org/10.1016/j.gie.2016.07.035)]
- 10 Komeda Y, Kashida H, Sakurai T, Asakuma Y, Tribonias G, Nagai T, Kono M, Minaga K, Takenaka M, Arizumi T, Hagiwara S, Matsui S, Watanabe T, Nishida N, Chikugo T, Chiba Y, Kudo M. Magnifying Narrow Band Imaging (NBI) for the Diagnosis of Localized Colorectal Lesions Using the Japan NBI Expert Team (JNET) Classification. *Oncology* 2017; **93** Suppl 1: 49-54 [PMID: [29258091](https://pubmed.ncbi.nlm.nih.gov/29258091/) DOI: [10.1159/000481230](https://doi.org/10.1159/000481230)]
- 11 Minoda Y, Ogino H, Chinen T, Ihara E, Haraguchi K, Akiho H, Takizawa N, Aso A, Tomita Y, Esaki M, Komori K, Otsuka Y, Iwasa T, Ogawa Y. Objective validity of the Japan Narrow-Band Imaging Expert Team classification system for the differential diagnosis of colorectal polyps. *Dig Endosc* 2019 [PMID: [30861599](https://pubmed.ncbi.nlm.nih.gov/30861599/) DOI: [10.1111/den.13393](https://doi.org/10.1111/den.13393)]
- 12 Ignjatovic A, East JE, Suzuki N, Vance M, Guenther T, Saunders BP. Optical diagnosis of small colorectal polyps at routine colonoscopy (Detect InSpect ChAracterise Resect and Discard; DISCARD trial): a prospective cohort study. *Lancet Oncol* 2009; **10**: 1171-1178 [PMID: [19910250](https://pubmed.ncbi.nlm.nih.gov/19910250/) DOI: [10.1016/S1470-2045\(09\)70329-8](https://doi.org/10.1016/S1470-2045(09)70329-8)]
- 13 Rex DK, Kahi C, O'Brien M, Levin TR, Pohl H, Rastogi A, Burgart L, Imperiale T, Ladabaum U, Cohen J, Lieberman DA. The American Society for Gastrointestinal Endoscopy PIVI (Preservation and Incorporation of Valuable Endoscopic Innovations) on real-time endoscopic assessment of the histology of diminutive colorectal polyps. *Gastrointest Endosc* 2011; **73**: 419-422 [PMID: [21353837](https://pubmed.ncbi.nlm.nih.gov/21353837/) DOI: [10.1016/j.gie.2011.01.023](https://doi.org/10.1016/j.gie.2011.01.023)]
- 14 Sano W, Sano Y, Iwatate M, Hasuike N, Hattori S, Kosaka H, Ikumoto T, Kotaka M, Fujimori T. Prospective evaluation of the proportion of sessile serrated adenoma/polyps in endoscopically diagnosed colorectal polyps with hyperplastic features. *Endosc Int Open* 2015; **3**: E354-E358 [PMID: [26357681](https://pubmed.ncbi.nlm.nih.gov/26357681/) DOI: [10.1055/s-0034-1391948](https://doi.org/10.1055/s-0034-1391948)]
- 15 Utsumi T, Iwatate M, Sunakawa H, Teramoto A, Hirata D, Hattori S, Sano W, Hasuike N, Ichikawa K, Fujimori T, Sano Y. Additional chromoendoscopy for colorectal lesions initially diagnosed with low confidence by magnifying narrow-band imaging: Can it improve diagnostic accuracy? *Dig Endosc* 2018; **30** Suppl 1: 45-50 [PMID: [29658652](https://pubmed.ncbi.nlm.nih.gov/29658652/) DOI: [10.1111/den.13055](https://doi.org/10.1111/den.13055)]
- 16 Sano Y, Hirata D, Saito Y. Japan NBI Expert Team classification: Narrow-band imaging magnifying endoscopic classification of colorectal tumors. *Dig Endosc* 2018; **30**: 543-545 [PMID: [29656581](https://pubmed.ncbi.nlm.nih.gov/29656581/) DOI: [10.1111/den.13072](https://doi.org/10.1111/den.13072)]



Published By Baishideng Publishing Group Inc  
7041 Koll Center Parkway, Suite 160, Pleasanton, CA 94566, USA  
Telephone: +1-925-2238242  
E-mail: [bpgoffice@wjgnet.com](mailto:bpgoffice@wjgnet.com)  
Help Desk: <https://www.f6publishing.com/helpdesk>  
<https://www.wjgnet.com>

