

# World Journal of *Clinical Cases*

*World J Clin Cases* 2019 September 26; 7(18): 2658-2915



**OPINION REVIEW**

- 2658** Effective use of the Japan Narrow Band Imaging Expert Team classification based on diagnostic performance and confidence level  
*Hirata D, Kashida H, Iwatate M, Tochio T, Teramoto A, Sano Y, Kudo M*

**MINIREVIEWS**

- 2666** Low fermentable oligosaccharides, disaccharides, monosaccharides, and polyols diet in children  
*Fodor I, Man SC, Dumitrascu DL*
- 2675** High-resolution colonic manometry and its clinical application in patients with colonic dysmotility: A review  
*Li YW, Yu YJ, Fei F, Zheng MY, Zhang SW*

**ORIGINAL ARTICLE****Retrospective Study**

- 2687** Predictors of rebleeding and in-hospital mortality in patients with nonvariceal upper digestive bleeding  
*Lazăr DC, Ursoniu S, Goldiș A*
- 2704** Analgesic effect of parecoxib combined with ropivacaine in patients undergoing laparoscopic hepatectomy  
*Huang SS, Lv WW, Liu YF, Yang SZ*
- 2712** Prognostic significance of 14v-lymph node dissection to D2 dissection for lower-third gastric cancer  
*Zheng C, Gao ZM, Sun AQ, Huang HB, Wang ZN, Li K, Gao S*

**Observational Study**

- 2722** Wall shear stress can improve prediction accuracy for transient ischemic attack  
*Liu QY, Duan Q, Fu XH, Jiang M, Xia HW, Wan YL*

**Prospective Study**

- 2734** Characterization of microbiota in systemic-onset juvenile idiopathic arthritis with different disease severities  
*Dong YQ, Wang W, Li J, Ma MS, Zhong LQ, Wei QJ, Song HM*

**SYSTEMATIC REVIEWS**

- 2746** Sinusoidal obstruction syndrome: A systematic review of etiologies, clinical symptoms, and magnetic resonance imaging features  
*Zhang Y, Jiang HY, Wei Y, Song B*

**META-ANALYSIS**

- 2760** Respiratory training interventions improve health status of heart failure patients: A systematic review and network meta-analysis of randomized controlled trials  
*Wang MH, Yeh ML*

**CASE REPORT**

- 2776** *Mycobacterium chimaera* infections following cardiac surgery in Treviso Hospital, Italy, from 2016 to 2019: Cases report  
*Inojosa WO, Giobbia M, Muffato G, Minniti G, Baldasso F, Carniato A, Farina F, Forner G, Rossi MC, Formentini S, Rigoli R, Scotton PG*
- 2787** Giant squamous cell carcinoma of the gallbladder: A case report  
*Junior MAR, Favaro MDL, Santin S, Silva CM, Iamarino APM*
- 2794** Liver re-transplantation for donor-derived neuroendocrine tumor: A case report  
*Mrzljak A, Kocman B, Skrtic A, Furac I, Popic J, Franusic L, Zunec R, Mayer D, Mikulic D*
- 2802** Calcifying fibrous tumor originating from the gastrohepatic ligament that mimicked a gastric submucosal tumor: A case report  
*Kwan BS, Cho DH*
- 2808** Pancreatitis, panniculitis, and polyarthritides syndrome caused by pancreatic pseudocyst: A case report  
*Jo S, Song S*
- 2815** Glomus tumor of uncertain malignant potential of the brachial plexus: A case report  
*Thanindrarn P, Chobpenthai T, Phorkhar T, Nelson SD*
- 2823** Conservative pulp treatment for Oehlers type III dens invaginatus: A case report  
*Lee HN, Chen YK, Chen CH, Huang CY, Su YH, Huang YW, Chuang FH*
- 2831** Propofol pump controls nonconvulsive status epilepticus in a hepatic encephalopathy patient: A case report  
*Hor S, Chen CY, Tsai ST*
- 2838** Teriparatide as nonoperative treatment for femoral shaft atrophic nonunion: A case report  
*Tsai MH, Hu CC*
- 2843** Successful repair of acute type A aortic dissection during pregnancy at 16<sup>th</sup> gestational week with maternal and fetal survival: A case report and review of the literature  
*Chen SW, Zhong YL, Ge YP, Qiao ZY, Li CN, Zhu JM, Sun LZ*
- 2851** Inferior pancreaticoduodenal artery pseudoaneurysm in a patient with calculous cholecystitis: A case report  
*Xu QD, Gu SG, Liang JH, Zheng SD, Lin ZH, Zhang PD, Yan J*

- 2857** ALK-positive anaplastic large cell lymphoma of the thoracic spine occurring in pregnancy: A case report  
*Yang S, Jiang WM, Yang HL*
- 2871** Multiple gastric adenocarcinoma of fundic gland type: A case report  
*Chen O, Shao ZY, Qiu X, Zhang GP*
- 2879** Repair of the portal vein using a hepatic ligamentum teres patch for laparoscopic pancreaticoduodenectomy: A case report  
*Wei Q, Chen QP, Guan QH, Zhu WT*
- 2899** Pleomorphic lipoma in the anterior mediastinum: A case report  
*Mao YQ, Liu XY, Han Y*
- 2905** Guillain-Barré syndrome in a patient with multiple myeloma after bortezomib therapy: A case report  
*Xu YL, Zhao WH, Tang ZY, Li ZQ, Long Y, Cheng P, Luo J*
- 2910** Bowen's disease on the palm: A case report  
*Yu SR, Zhang JZ, Pu XM, Kang XJ*

**ABOUT COVER**

Editorial Board Member of *World Journal of Clinical Cases*, Shao-Ping Yu, MD, Associate Professor, Chief Doctor, Department of Gastroenterology and Hepatology, Dongguan Kanghua Hospital, Dongguan 523080, Guangdong Province, China

**AIMS AND SCOPE**

The primary aim of *World Journal of Clinical Cases* (*WJCC*, *World J Clin Cases*) is to provide scholars and readers from various fields of clinical medicine with a platform to publish high-quality clinical research articles and communicate their research findings online.

*WJCC* mainly publishes case reports, case series, and articles reporting research results and findings obtained in the field of clinical medicine and covering a wide range of topics including diagnostic, therapeutic, and preventive modalities.

**INDEXING/ABSTRACTING**

The *WJCC* is now indexed in PubMed, PubMed Central, Science Citation Index Expanded (also known as SciSearch®), and Journal Citation Reports/Science Edition. The 2019 Edition of Journal Citation Reports cites the 2018 impact factor for *WJCC* as 1.153 (5-year impact factor: N/A), ranking *WJCC* as 99 among 160 journals in Medicine, General and Internal (quartile in category Q3).

**RESPONSIBLE EDITORS FOR THIS ISSUE**

Responsible Electronic Editor: Ji-Hong Liu

Proofing Production Department Director: Yun-Xiaoqian Wu

**NAME OF JOURNAL**

*World Journal of Clinical Cases*

**ISSN**

ISSN 2307-8960 (online)

**LAUNCH DATE**

April 16, 2013

**FREQUENCY**

Semimonthly

**EDITORS-IN-CHIEF**

Dennis A Bloomfield, Bao-Gan Peng, Sandro Vento

**EDITORIAL BOARD MEMBERS**

<https://www.wjgnet.com/2307-8960/editorialboard.htm>

**EDITORIAL OFFICE**

Jin-Lei Wang, Director

**PUBLICATION DATE**

September 26, 2019

**COPYRIGHT**

© 2019 Baishideng Publishing Group Inc

**INSTRUCTIONS TO AUTHORS**

<https://www.wjgnet.com/bpg/gerinfo/204>

**GUIDELINES FOR ETHICS DOCUMENTS**

<https://www.wjgnet.com/bpg/GerInfo/287>

**GUIDELINES FOR NON-NATIVE SPEAKERS OF ENGLISH**

<https://www.wjgnet.com/bpg/gerinfo/240>

**PUBLICATION MISCONDUCT**

<https://www.wjgnet.com/bpg/gerinfo/208>

**ARTICLE PROCESSING CHARGE**

<https://www.wjgnet.com/bpg/gerinfo/242>

**STEPS FOR SUBMITTING MANUSCRIPTS**

<https://www.wjgnet.com/bpg/GerInfo/239>

**ONLINE SUBMISSION**

<https://www.f6publishing.com>

## Conservative pulp treatment for Oehlers type III dens invaginatus: A case report

Hui-Na Lee, Yuk-Kwan Chen, Cheng-Hui Chen, Chun-Yin Huang, Ying-Hui Su, Ying-Wei Huang, Fu-Hsiung Chuang

**ORCID number:** Hui-Na Lee (0000-0002-9024-517X); Yuk-Kwan Chen (0000-0001-9152-6056); Cheng-Hui Chen (0000-0003-3922-1866); Chun-Yin Huang (0000-0003-4988-8621); Ying-Hui Su (0000-0003-3995-2394); Ying-Wei Huang (0000-0002-4123-399X); Fu-Hsiung Chuang (0000-0002-8382-1247).

**Author contributions:** The first two authors made equal contributions; Lee HN, Chuang FH, Chen YK, and Chen HC contributed to the conception and design of the procedure; Lee HN and Chen YK wrote and edited the manuscript; Su YH and Huang YW contributed to cone-beam computed tomography imaging; Huang YH contributed to the reconstruction of three-dimensional pictures; Chuang FH and Chen YK supervised the study and revised the manuscript before submission; all authors read and approved the final manuscript.

**Supported by** a grant from the Kaohsiung Medical University, No. KMH106-6M52.

**Informed consent statement:** Written informed consent was obtained from the patient's parents for the publication of personal details and accompanying images in this manuscript.

**Conflict-of-interest statement:** The authors declare that they have no competing interests in relation to the present work.

**CARE Checklist (2016) statement:** The manuscript was prepared and

Hui-Na Lee, Cheng-Hui Chen, Ying-Hui Su, Ying-Wei Huang, Fu-Hsiung Chuang, Division of Conservative Dentistry, Dental Department, Kaohsiung Medical University Chung-Ho Memorial Hospital, Kaohsiung 80756, Taiwan

Hui-Na Lee, Dental Department, Kaohsiung Municipal CiJin Hospital, Kaohsiung 80756, Taiwan

Yuk-Kwan Chen, Division of Oral Pathology and Radiology, Dental Department, Kaohsiung Medical University Chung-Ho Memorial Hospital, Kaohsiung 80756, Taiwan

Yuk-Kwan Chen, Cheng-Hui Chen, Fu-Hsiung Chuang, School of Dentistry, Kaohsiung Medical University, Kaohsiung 80756, Taiwan

Yuk-Kwan Chen, Oral and Maxillofacial Radiology Center, Kaohsiung Medical University, Kaohsiung 80756, Taiwan

Chun-Yin Huang, Department of Nuclear Medicine, E-DA Hospital, Kaohsiung 80756, Taiwan

Ying-Wei Huang, Dental Department, Kaohsiung Municipal Hsiao Kang Hospital, Kaohsiung 80756, Taiwan

**Corresponding author:** Fu-Hsiung Chuang, PhD, Research Assistant Professor, Division of Conservative Dentistry, Dental Department, Kaohsiung Medical University Chung-Ho Memorial Hospital, No. 100, Tzyou 1st Rd, Kaohsiung 80756, Taiwan.

[nana1628@yahoo.com.tw](mailto:nana1628@yahoo.com.tw)

**Telephone:** +886-7-3121101

**Fax:** +886-7-3157024

### Abstract

#### BACKGROUND

Diverse presentations of dens invaginatus (DI) and root canal treatment with an immature open apex often pose challenges to dentists. Adequate treatment planning for DI is the main reason for successful approach, *i.e.*, we should consider the shape and depth of the concave folding, the condition of the original pulp, and the growth stage of the root formation.

#### CASE SUMMARY

A 9-year-old girl complained of severe pain of the right maxillary incisor (tooth 12) when chewing for two weeks. Following clinical and radiographic examinations, Oehlers type III DI of tooth 12, with an immature open apical foramen and a symptomatic periapical pathosis, was diagnosed. Cone-beam

revised according to the CARE Checklist (2016).

**Open-Access:** This article is an open-access article which was selected by an in-house editor and fully peer-reviewed by external reviewers. It is distributed in accordance with the Creative Commons Attribution Non Commercial (CC BY-NC 4.0) license, which permits others to distribute, remix, adapt, build upon this work non-commercially, and license their derivative works on different terms, provided the original work is properly cited and the use is non-commercial. See: <http://creativecommons.org/licenses/by-nc/4.0/>

**Manuscript source:** Unsolicited manuscript

**Received:** June 11, 2019

**Peer-review started:** June 19, 2019

**First decision:** August 1, 2019

**Revised:** August 7, 2019

**Accepted:** August 20, 2019

**Article in press:** August 20, 2019

**Published online:** September 26, 2019

**P-Reviewer:** Gorseta K

**S-Editor:** Zhang L

**L-Editor:** Wang TQ

**E-Editor:** Liu JH



computed tomography verified the specific spatial and stereoscopic data regarding the communication between the main root canal and pseudo root canal of the involved tooth. After removing the source of infection, a mineral trioxide aggregate was selected to fill and seal the pseudo root canal; additionally, pulp capping of the main canal was performed through the interconnections between the root canals in the middle segment to preserve pulp vitality and enable continual root formation and eventual root apex closure.

## CONCLUSION

We propose to conduct main root canal pulp capping for DI with communication between the main and pseudo root canals.

**Key words:** Conservative treatment; Dens invaginatus; Open apex; Cone-beam computed tomography; Case report

©The Author(s) 2019. Published by Baishideng Publishing Group Inc. All rights reserved.

**Core tip:** The present case report is the first paper describing a case of dens invaginatus with an apical lesion and communication between the main root canal and pseudo root canal managed using nonsurgical endodontic treatment of the infected pseudo root canal, and only employing pulp capping on the main root canal to retain pulp vitality, thus enabling continual root formation with closure of the open root apex.

**Citation:** Lee HN, Chen YK, Chen CH, Huang CY, Su YH, Huang YW, Chuang FH. Conservative pulp treatment for Oehlers type III dens invaginatus: A case report. *World J Clin Cases* 2019; 7(18): 2823-2830

**URL:** <https://www.wjgnet.com/2307-8960/full/v7/i18/2823.htm>

**DOI:** <https://dx.doi.org/10.12998/wjcc.v7.i18.2823>

## INTRODUCTION

Dens invaginatus (DI) is a rare dental malformation resulting from invagination of the tooth crown. In most cases, it occurs when the enamel organ invaginates into the surrounding dental papilla prior to its calcification<sup>[1]</sup>. Various terminologies have been used to describe this dental anomaly, including tooth inclusion, dens in dente, invaginated odontoma, dentoid in dente, and dilated composite odontoma<sup>[2]</sup>. The incidence of DI reportedly varies between 0.04% and 10%, and the most commonly affected tooth is the maxillary lateral incisor<sup>[3-5]</sup>. The Oehlers classification has widely been adopted to verify the extent of malformation due to tooth invagination<sup>[6]</sup>. With respect to the Oehlers classification, type I DI is the most frequent (65.9%), followed by type II (29.5%), with type III being the least common (4.6%)<sup>[7]</sup>.

Previously, Kramer<sup>[8]</sup> demonstrated that invagination plays a key role in causing the structural deformity that is observed in the enamel layer, thereby resulting in the underlying dentin layer being exposed. The structure of the dentin that surrounds the invagination is irregular, with connective tissue inclusions and communication towards the pulp. Without enamel, microbes spread easily *via* the dentin tubules, leading to pulpal infection.

The variable appearance of DI and its root canal treatment in an immature tooth are challenges often encountered by dentists. Adequate treatment planning and prognosis evaluations of DI should take into consideration the shape and depth of the concave folding, the condition of the original pulp, and the growth stage of the root formation<sup>[9]</sup>. Here, we report the case of a patient with type III DI in the right maxillary lateral incisor (tooth 12), with vital pulp, necrotic invagination, an open apex, a large periapical lesion, and communication between the main root canal and pseudo root canal, which was managed successfully using an innovative conservative approach, resulting in a shortened therapy procedure and maintenance of pulp vitality of the main root canal. To the best of our knowledge, the present case report is the first to describe a case of DI with an apical lesion and communication between the main root canal and pseudo root canal that was managed using nonsurgical endodontic treatment of the infected pseudo root canal and employing pulp capping on the main root canal to retain pulp vitality, thus enabling continual root formation



with closure of the open root apex.

## CASE PRESENTATION

### **Chief complaints**

A 9-year-old girl who complained of severe pain over tooth 12 during chewing for two weeks was referred to the Department of Conservative Dentistry of our Institution.

### **History of present illness**

The patient had fair oral hygiene.

### **History of past illness**

Neither a history of trauma nor a significant past dental and medical history was noted.

### **Physical examination**

Intraoral examination revealed a peg-shaped clinical crown of tooth 12 with a talon cusp, depression, and a pit on the occlusal side (Figure 1A and 1B) without intraoral swelling or a sinus tract. Severe tenderness on palpation and percussion of tooth 12 was noted.

### **Laboratory examinations**

The involved tooth 12 responded normally to thermal (cold) and electric pulp testing (Parkell pulp vitality tester, Farmingdale, NY, United States), and was free of caries and restoration; grade 1 tooth mobility and < 2 mm periodontal probing depths were also observed. Moreover, teeth 11 and 13 showed normal responses to both cold and electrical pulp sensitivity testing.

### **Imaging examinations**

A periapical radiograph of tooth 12 revealed a large elliptical space within the invagination; the invagination of dentin lined by enamel extended into the main canal space with spreading into the apical part of the tooth root. Thus, tooth 12 seemed to be associated with a large periapical radiolucent lesion around an immature root apex (Figure 2).

Cone-beam computed tomography (CBCT) (EPX-Impla; E-Woo Technology, Yongin, South Korea) revealed a type III invagination extending from the crown to the root apex, with an enlarged root canal space and communication with the main root canal in the middle part. A well-defined unilocular periapical radiolucent lesion measuring about 6 mm (mesio-distal) × 7 mm (labio-palatal) × 8 mm (cranio-caudal) was observed around the open apex of tooth 12 (Figure 3A, 3B, and 3C). The three-dimensional structure of the DI was reconstructed using OsiriX MD software (Figure 3D; Supplementary material).

## FINAL DIAGNOSIS

A diagnosis of Oehlers type III DI with pulp necrosis of the pseudo root canal and symptomatic apical periodontitis was rendered.

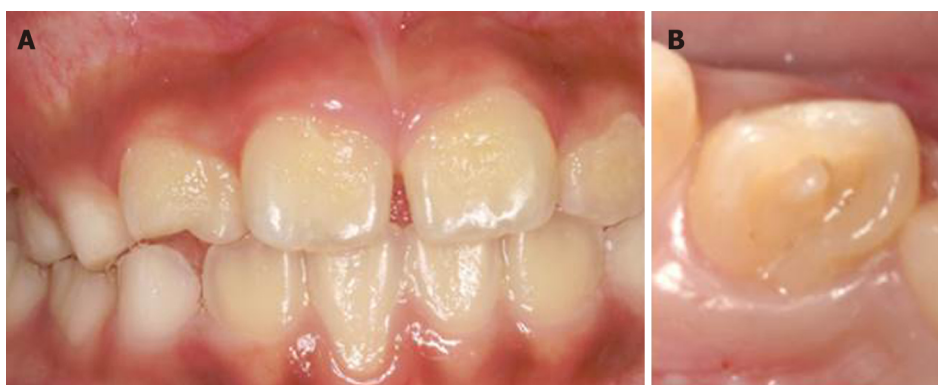## TREATMENT

After discussion with the patient and her parents, a treatment plan consisting of vital pulp therapy of the main root canal followed by nonsurgical endodontic treatment for the pseudo root canal of tooth 12 was suggested. Informed consent was obtained from the parents of the patient. The treatment was conducted in full accordance with the ethical principles of the World Medical Association Declaration of Helsinki.

The pseudo root canal is generally regarded as the usual site of origin of infection in DI<sup>[10]</sup>. In the present case, the central portion of the pulp was considered to be the pseudo root canal based on a periapical image of tooth 12 (Figure 4A), and the adjacent bilateral sides were the entrances to the main root canal. Therefore, the tooth chamber was opened at the central portion of the tooth to treat the pseudo root canal as an emergency measure to relieve the symptoms.

Local anesthesia with 2% lidocaine was administered around tooth 12 and the access cavity of the invagination was carefully prepared with rubber dam isolation. A





**Figure 1 Clinical examination.** A: The intraoral examination revealed normal soft tissue; B: Occlusal view shows a talon cusp and square-shaped crown.

surgical operating microscope (OPMI® pico, Carl Zeiss, Oberkochen, Germany) was used to explore the main root canal carefully to prevent any potential damage to the main root canal. Moreover, with respect to the information provided by CBCT imaging, the extent, position, and pulpal involvement of the invagination of the pseudo root canal of tooth 12 were accurately assessed (Figure 4B).

With the assistance of periapical radiographic imaging (Figure 4C) and an electronic apex locator, a 19-mm working length was confirmed when the patient visited the clinic for the second appointment. The pseudo root canal that appeared to be invaginated was instrumented with K-files of international standardization organization (ISO) size 40 (master apical file), which were then stepped back towards size 60. The pseudo root canal was irrigated well with 3% sodium hypochlorite solution after each instrumentation. Once the instrumentation was finished, pseudo root canal dressing was conducted with calcium hydroxide, and the entrance of the operated cavity was covered with 3-mm-thick Cavit (3M ESPE United States, Norristown, PA, United States) for half a month.

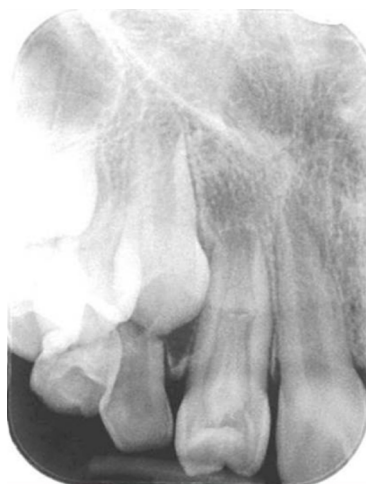The patient was completely asymptomatic upon the third appointment. The temporary restorative materials were removed under rubber dam isolation. Irrigation with 3% sodium hypochlorite solution, ISO size 30 stainless steel hand files, and passive ultrasonic irrigation (Obtura Spartan, Algonquin, IL, United States) were used to remove the calcium hydroxide paste. The tooth was examined under a microscope to ensure that no remnants of the paste remained.

Root canal filling of the pseudo root canal was subsequently performed, as the infection had been controlled successfully. Notably, the main root canal was still vital, with an open apex, and had a complicated structure. Considering the interconnections between the root canals in the middle segment, a mineral trioxide aggregate (MTA) (Dentsply Tulsa Dental, Tulsa, OK, United States), which has good bio-compatibility, was selected to fill and seal the pseudo root canal, and was used for pulp capping in the main root canal.

After a final irrigation with normal saline, paper points were used to dry the pseudo root canal. The MTA was mixed according to the manufacturer's instructions and condensed following the recommended steps<sup>[11]</sup> incrementally until the cemento-enamel junction was reached (Figure 4D and 4E). Moistened cotton was placed into the pulp chamber, and the access cavity was sealed with Cavit for an entire day to allow complete setting of the MTA. Tooth 12 was then restored with a composite resin (3M ESPE, St. Paul, MN, United States) at the next visit. Pulp capping of the main root canal with the MTA was completed to preserve pulp vitality.

## OUTCOME AND FOLLOW-UP

The patient was asymptomatic when followed a week later. Tooth 12 was not tender on percussion or palpation. A periapical radiograph of tooth 12 that was acquired after 6 mo revealed resolution of the periapical radiolucency. Additionally, an increase in the root wall thickness with a reduced root canal space was noted. At one year after pulp capping, the periapical area showed a normal bone density with a closed root apex (Figure 4F). Moreover, the tooth still responded normally to electric pulp testing and Laser Doppler Flowmetry, and the patient remained asymptomatic after follow-up for a further 3 years.



**Figure 2 Periapical radiograph.** The image shows a large elliptical space inside the invagination, and invagination of the dentin lined by enamel into the main canal space spreading into the apical part of the tooth root was observed. Tooth 12 appears to be associated with a large periapical radiolucent lesion around an immature root apex.

## DISCUSSION

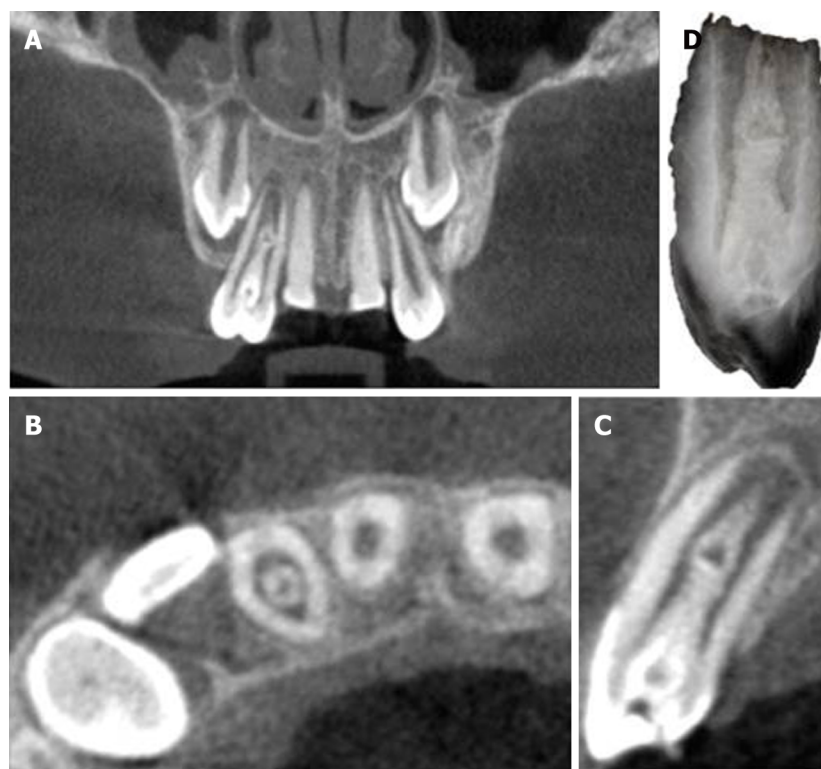
In concurrence with the study by Goel *et al.*<sup>[10]</sup>, the pseudo root canal of the DI in the current case was found to be the site of origin of infection, which may be due to the fact that the invagination acts as a region of stagnation for organic substances and provides a favorable surrounding for microbe proliferation. The invagination of enamel into the dental papilla results in a tunnel lined by dentin and enamel invaginating into the pulp<sup>[12]</sup>.

Teeth with DI are susceptible to early caries and subsequent pulp necrosis requiring root canal treatment. Reviewing the literature, we found that treatment options for DI include preventive sealing or filling of the invagination, root canal treatment<sup>[13,14]</sup>, endodontic periapical surgery<sup>[15]</sup>, intentional replantation, and extraction. In certain cases, endodontic treatment techniques may involve apexification, removal of the invagination from the root canal<sup>[16]</sup>, and obturation of the invagination alone while maintaining pulp vitality<sup>[17]</sup>.

The diagnosis of and root canal treatment for DI are challenging in view of the complicated root canal morphology. Due to the limitations of conventional radiographic imaging, it is difficult to clearly visualize the morphology of the root canal in DI, which in turn affects the treatment outcome. CBCT, as demonstrated in the present case, provides accurate three-dimensional images that enable assessment of the root canal morphology in DI, and helps the dentist to determine the grade of the pathology and the optimum treatment modality<sup>[18]</sup>.

In a previous study<sup>[19]</sup>, DI with an open apical foramen was treated using calcium hydroxide or an MTA to create a hard tissue barrier followed by placement of gutta-percha on the filling. Occasionally, dentists combine apical surgery with conventional root canal therapy, which still requires advanced techniques<sup>[20]</sup>. In a study by Yang *et al.*<sup>[17]</sup>, the pseudo root canal was filled with gutta-percha, but revascularization was employed for the necrotic main canal with an open apex to induce blood flow to the coronal portion and to reduce the surgical difficulty. Pulp regeneration therapy appeared to facilitate root development; however, based on an animal study, the apposition material-induced thickening of root walls may be of different nature dentin, cementum, or even bone<sup>[21]</sup>. Furthermore, this therapeutic modality has the potential drawbacks of involving relatively complicated procedures, as well as being time-consuming and expensive. In the present case, much of the real pulp tissue was preserved through pulp capping.

Recently, Ceyhanli *et al.*<sup>[22]</sup> preserved the main root canal vitality without applying any treatment, and non-surgical endodontic treatment was performed only on the invaginated canal of tooth 22 with type III DI and peri-invagination pathosis in a 17-year-old female patient. CBCT did not reveal intersection of the pseudo root canal with the main root canal. In comparison with the case of Ceyhanli *et al.*<sup>[22]</sup>, the DI in the current case was more complicated, presenting with not only the infected pseudo root canal, but also an open root apex. In the current case, we adopted conservative vital pulp therapy on the vital main root canal. MTA was selected to fill and seal the pseudo root canal, and for pulp capping of the main root canal through the interconnection between the root canals in the middle segment. Once the source of the

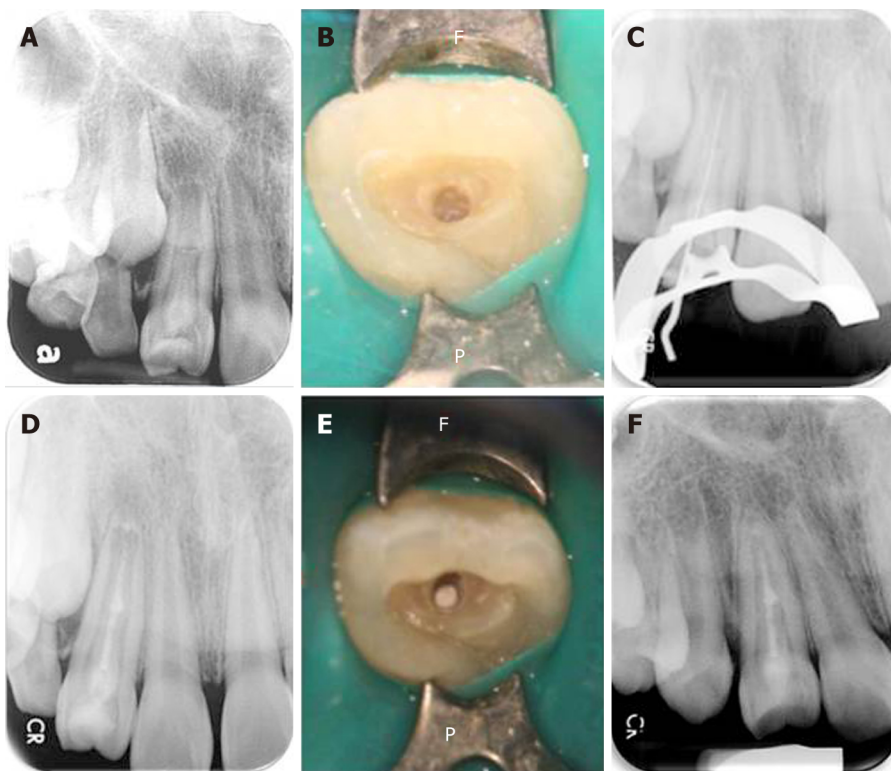


**Figure 3** Cone-beam computed tomography images. A: Coronal view shows a central bulge; B: Axial view shows the relative positions of the main root canal and pseudo root canal; C: Sagittal plane view indicates that the enlargement is connected with the main root canal; D: Reconstruction of the three-dimensional structure of the dens invaginatus.

infection is eliminated, the abundant blood supply of the main root canal from the open apical foramen, as well as the induction and formation mechanisms of the vital pulp, can facilitate root development. Therefore, appropriate conservative procedures, as shown in the current case, can be considered as an alternative management modality for complicated cases of DI with an open root apex and communication between the main root canal and pseudo root canal.

## CONCLUSION

Although the complicated internal structure of the root canal in DI hinders mechanical debridement, the use of CBCT for accurate diagnosis (as shown in our case, and in the case reported by Ceyhanli *et al*<sup>[22]</sup>), and treatment with copious chemical irrigation, ultrasound equipment, and intracanal medication can improve the outcome of debridement. Moreover, appropriate repair of the immature tooth using microscopic assistance and bio-compatible filling materials can maintain the dental pulp activity, and acceptable results can be achieved even in complicated DI cases.



**Figure 4 The operating process.** A: Pre-operative radiograph showing the presence of dens invaginatus associated with an open apex and a large periapical lesion. The middle part of the bulge was suspected to be connected to the main root canal; B: The position of the invagination was located under a microscope and access-opening was performed; C: A root ZX mini apex locator and a periapical radiograph were used to determine the working length before conducting complete debridement; D: Considering the interconnections between the root canals in the middle segment, a mineral trioxide aggregate (MTA) sealer was used to fill and seal the pseudo root canal and perform pulp capping in the main canal; E: The MTA filling as observed under the microscope; F: At the one-year follow-up, the apical lesion had healed well (the tooth wall had thickened and the apical foramen was closed). The tooth still responded normally to the pulp vitality test.

## ACKNOWLEDGEMENTS

We thank the staff of Kaohsiung Medical University Chung-Ho Memorial Hospital and Kaohsiung Municipal Cijin Hospital for their help and support during this case.

## REFERENCES

- 1 Alani A, Bishop K. Dens invaginatus. Part 1: classification, prevalence and aetiology. *Int Endod J* 2008; **41**: 1123-1136 [PMID: 19133103 DOI: 10.1111/j.1365-2591.2008.01468.x]
- 2 Hülsmann M. Dens invaginatus: aetiology, classification, prevalence, diagnosis, and treatment considerations. *Int Endod J* 1997; **30**: 79-90 [PMID: 10332241 DOI: 10.1046/j.1365-2591.1997.00065.x]
- 3 Hovland EJ, Block RM. Nonrecognition and subsequent endodontic treatment of dens invaginatus. *J Endod* 1977; **3**: 360-362 [PMID: 269901 DOI: 10.1016/S0099-2399(77)80067-8]
- 4 Ruprecht A, Batniji S, Sastry KA, el-Newehi E. The incidence of dental invagination. *J Pedod* 1986; **10**: 265-272 [PMID: 3459853]
- 5 Kirzioğlu Z, Ceyhan D. The prevalence of anterior teeth with dens invaginatus in the western Mediterranean region of Turkey. *Int Endod J* 2009; **42**: 727-734 [PMID: 19548935 DOI: 10.1111/j.1365-2591.2009.01579.x]
- 6 OEHLERS FA. Dens invaginatus (dilated composite odontome). I. Variations of the invagination process and associated anterior crown forms. *Oral Surg Oral Med Oral Pathol* 1957; **10**: 1204-18 contd [PMID: 13477660 DOI: 10.1016/0030-4220(57)90077-4]
- 7 Capar ID, Ertas H, Arslan H, Tarim Ertas E. A retrospective comparative study of cone-beam computed tomography versus rendered panoramic images in identifying the presence, types, and characteristics of dens invaginatus in a Turkish population. *J Endod* 2015; **41**: 473-478 [PMID: 25595467 DOI: 10.1016/j.joen.2014.12.001]
- 8 KRAMER IR. The pathology of pulp death in non-carious maxillary incisors with minor palatal invaginations. *Proc R Soc Med* 1953; **46**: 503-505 [PMID: 13074203 DOI: 10.1177/003591575304600705]
- 9 Forghani M, Moghim Farooji E, Abuchenari J, Bidar M, Eslami N. Conservative Treatment of an Invaginated Maxillary Lateral Incisor with a C-shaped Canal Using Cone-Beam Computed Tomography. *Iran Endod J* 2015; **10**: 281-283 [PMID: 26576164 DOI: 10.7508/iej.2015.04.014]
- 10 Goel S, Nawal RR, Talwar S. Management of Dens Invaginatus Type II Associated with Immature Apex and Large Periradicular Lesion Using Platelet-rich Fibrin and Biodentine. *J Endod* 2017; **43**: 1750-1755 [PMID: 28712634 DOI: 10.1016/j.joen.2017.04.005]

- 11 **Friedl CC**, Williamson AE, Dawson DV, Gomez MR, Liu W. Comparison of Mechanical and Indirect Ultrasonic Placement Technique on Mineral Trioxide Aggregate Retrofill Density in Simulated Root-end Surgery. *J Endod* 2016; **42**: 650-653 [PMID: [26898561](#) DOI: [10.1016/j.joen.2016.01.008](#)]
- 12 **Greenfeld RS**, Cambruzzi JV. Complexities of endodontic treatment of maxillary lateral incisors with anomalous root formation. *Oral Surg Oral Med Oral Pathol* 1986; **62**: 82-88 [PMID: [3460012](#) DOI: [10.1016/0030-4220\(86\)90075-7](#)]
- 13 **Tsurumachi T**. Endodontic treatment of an invaginated maxillary lateral incisor with a periradicular lesion and a healthy pulp. *Int Endod J* 2004; **37**: 717-723 [PMID: [15347298](#) DOI: [10.1111/j.1365-2591.2004.00863.x](#)]
- 14 **Rani N**, Sroa RB. Nonsurgical endodontic management of dens invaginatus with open apex: A case report. *J Conserv Dent* 2015; **18**: 492-495 [PMID: [26751206](#) DOI: [10.4103/0972-0707.168822](#)]
- 15 **Ozbas H**, Subay RK, Ordulu M. Surgical retreatment of an invaginated maxillary central incisor following overfilled endodontic treatment: a case report. *Eur J Dent* 2010; **4**: 324-328 [PMID: [20613922](#)]
- 16 **Girsch WJ**, McClammy TV. Microscopic removal of dens invaginatus. *J Endod* 2002; **28**: 336-339 [PMID: [12043878](#) DOI: [10.1097/00004770-200204000-00020](#)]
- 17 **Yang J**, Zhao Y, Qin M, Ge L. Pulp revascularization of immature dens invaginatus with periapical periodontitis. *J Endod* 2013; **39**: 288-292 [PMID: [23321248](#) DOI: [10.1016/j.joen.2012.10.017](#)]
- 18 **Sponchiado EC**, Ismail HA, Braga MR, de Carvalho FK, Simões CA. Maxillary central incisor with two root canals: a case report. *J Endod* 2006; **32**: 1002-1004 [PMID: [16982283](#) DOI: [10.1016/j.joen.2006.03.022](#)]
- 19 **Vidal K**, Martin G, Lozano O, Salas M, Trigueros J, Aguilar G. Apical Closure in Apexification: A Review and Case Report of Apexification Treatment of an Immature Permanent Tooth with Biodentine. *J Endod* 2016; **42**: 730-734 [PMID: [26994597](#) DOI: [10.1016/j.joen.2016.02.007](#)]
- 20 **Zoya A**, Ali S, Alam S, Tewari RK, Mishra SK, Kumar A, Andrabi SM. Double Dens Invaginatus with Multiple Canals in a Maxillary Central Incisor: Retreatment and Managing Complications. *J Endod* 2015; **41**: 1927-1932 [PMID: [26514867](#) DOI: [10.1016/j.joen.2015.08.017](#)]
- 21 **Namour M**, Theys S. Pulp revascularization of immature permanent teeth: a review of the literature and a proposal of a new clinical protocol. *ScientificWorldJournal* 2014; **2014**: 737503 [PMID: [25383384](#) DOI: [10.1155/2014/737503](#)]
- 22 **Ceyhanli KT**, Celik D, Altintas SH, Taşdemir T, S Sezgin O. Conservative treatment and follow-up of type III dens invaginatus using cone beam computed tomography. *J Oral Sci* 2014; **56**: 307-310 [PMID: [25500929](#) DOI: [10.2334/josnusd.56.307](#)]



Published By Baishideng Publishing Group Inc  
7041 Koll Center Parkway, Suite 160, Pleasanton, CA 94566, USA  
Telephone: +1-925-2238242  
E-mail: [bpgoffice@wjgnet.com](mailto:bpgoffice@wjgnet.com)  
Help Desk: <https://www.f6publishing.com/helpdesk>  
<https://www.wjgnet.com>

