

# World Journal of *Gastroenterology*

*World J Gastroenterol* 2019 September 28; 25(36): 5403-5577



**GUIDELINES**

- 5403** Chinese guidelines on management of hepatic encephalopathy in cirrhosis  
*Xu XY, Ding HG, Li WG, Jia JD, Wei L, Duan ZP, Liu YL, Ling-Hu EQ, Zhuang H, Hepatology CSO, Association CM*

**MINIREVIEWS**

- 5423** Sexual health and fertility for individuals with inflammatory bowel disease  
*Leenhardt R, Rivière P, Papazian P, Nion-Larmurier I, Girard G, Laharie D, Marteau P*

**ORIGINAL ARTICLE****Basic Study**

- 5434** High mobility group box-1 release from H<sub>2</sub>O<sub>2</sub>-injured hepatocytes due to sirt1 functional inhibition  
*Ye TJ, Lu YL, Yan XF, Hu XD, Wang XL*
- 5451** Zinc-α<sub>2</sub>-glycoprotein 1 attenuates non-alcoholic fatty liver disease by negatively regulating tumour necrosis factor-α  
*Liu T, Luo X, Li ZH, Wu JC, Luo SZ, Xu MY*
- 5469** *Clostridium butyricum* alleviates intestinal low-grade inflammation in TNBS-induced irritable bowel syndrome in mice by regulating functional status of lamina propria dendritic cells  
*Zhao Q, Yang WR, Wang XH, Li GQ, Xu LQ, Cui X, Liu Y, Zuo XL*
- 5483** CARMA3/NF-κB signaling contributes to tumorigenesis of hepatocellular carcinoma and is inhibited by sodium aescinate  
*Hou H, Li WX, Cui X, Zhou DC, Zhang B, Geng XP*

**Case Control Study**

- 5494** Laparoscopy-assisted pylorus-preserving gastrectomy for early gastric cancer: A retrospective study of long-term functional outcomes and quality of life  
*Eom BW, Park B, Yoon HM, Ryu KW, Kim YW*

**Retrospective Study**

- 5505** Application of single balloon enteroscopy-assisted therapeutic endoscopic retrograde cholangiopancreatography in patients after bilioenteric Roux-en-Y anastomosis: Experience of multi-disciplinary collaboration  
*Wu WG, Qin LC, Song XL, Zhao MN, Zhang WJ, Gu J, Weng H, Liu YB, Zhang Y, Qu CY, Xu LM, Wang XF*

- 5515** Diagnostic value of gamma-glutamyltransferase/aspartate aminotransferase ratio, protein induced by vitamin K absence or antagonist II, and alpha-fetoprotein in hepatitis B virus-related hepatocellular carcinoma

*Wang Q, Chen Q, Zhang X, Lu XL, Du Q, Zhu T, Zhang GY, Wang DS, Fan QM*

#### Clinical Trials Study

- 5530** Genomic profile concordance between pancreatic cyst fluid and neoplastic tissue
- Laquière AE, Lagarde A, Napoléon B, Bourdariat R, Atkinson A, Donatelli G, Pol B, Lecomte L, Curel L, Urena-Campos R, Helbert T, Valantin V, Mithieux F, Buono JP, Grandval P, Olschwang S*

#### Observational Study

- 5543** Evaluation and comparison of short chain fatty acids composition in gut diseases
- Niccolai E, Baldi S, Ricci F, Russo E, Nannini G, Menicatti M, Poli G, Taddei A, Bartolucci G, Calabrò AS, Stingo FC, Amedei A*

#### META-ANALYSIS

- 5559** Impact of small-for-size liver grafts on medium-term and long-term graft survival in living donor liver transplantation: A meta-analysis
- Ma KW, Wong KHC, Chan ACY, Cheung TT, Dai WC, Fung JYY, She WH, Lo CM, Chok KSH*

#### CASE REPORT

- 5569** Long-term growth of intrahepatic papillary neoplasms: A case report
- Hasebe T, Sawada K, Hayashi H, Nakajima S, Takahashi H, Hagiwara M, Imai K, Yuzawa S, Fujiya M, Furukawa H, Okumura T*

**ABOUT COVER**

Editorial board member of *World Journal of Gastroenterology*, Yasuhito Tanaka, MD, PhD, Professor, Department of Virology and Liver Unit, Nagoya City University Graduate School of Medical Sciences, Nagoya 467-8601, Japan

**AIMS AND SCOPE**

The primary aim of *World Journal of Gastroenterology* (WJG, *World J Gastroenterol*) is to provide scholars and readers from various fields of gastroenterology and hepatology with a platform to publish high-quality basic and clinical research articles and communicate their research findings online.

WJG mainly publishes articles reporting research results and findings obtained in the field of gastroenterology and hepatology and covering a wide range of topics including gastroenterology, hepatology, gastrointestinal endoscopy, gastrointestinal surgery, gastrointestinal oncology, and pediatric gastroenterology.

**INDEXING/ABSTRACTING**

The WJG is now indexed in Current Contents®/Clinical Medicine, Science Citation Index Expanded (also known as SciSearch®), Journal Citation Reports®, Index Medicus, MEDLINE, PubMed, PubMed Central, and Scopus. The 2019 edition of Journal Citation Report® cites the 2018 impact factor for WJG as 3.411 (5-year impact factor: 3.579), ranking WJG as 35<sup>th</sup> among 84 journals in gastroenterology and hepatology (quartile in category Q2). CiteScore (2018): 3.43.

**RESPONSIBLE EDITORS FOR THIS ISSUE**

Responsible Electronic Editor: Yan-Liang Zhang

Proofing Production Department Director: Xiang Li

**NAME OF JOURNAL**

*World Journal of Gastroenterology*

**ISSN**

ISSN 1007-9327 (print) ISSN 2219-2840 (online)

**LAUNCH DATE**

October 1, 1995

**FREQUENCY**

Weekly

**EDITORS-IN-CHIEF**

Subrata Ghosh, Andrzej S Tarnawski

**EDITORIAL BOARD MEMBERS**

<http://www.wjgnet.com/1007-9327/editorialboard.htm>

**EDITORIAL OFFICE**

Ze-Mao Gong, Director

**PUBLICATION DATE**

September 28, 2019

**COPYRIGHT**

© 2019 Baishideng Publishing Group Inc

**INSTRUCTIONS TO AUTHORS**

<https://www.wjgnet.com/bpg/gerinfo/204>

**GUIDELINES FOR ETHICS DOCUMENTS**

<https://www.wjgnet.com/bpg/GerInfo/287>

**GUIDELINES FOR NON-NATIVE SPEAKERS OF ENGLISH**

<https://www.wjgnet.com/bpg/gerinfo/240>

**PUBLICATION MISCONDUCT**

<https://www.wjgnet.com/bpg/gerinfo/208>

**ARTICLE PROCESSING CHARGE**

<https://www.wjgnet.com/bpg/gerinfo/242>

**STEPS FOR SUBMITTING MANUSCRIPTS**

<https://www.wjgnet.com/bpg/GerInfo/239>

**ONLINE SUBMISSION**

<https://www.f6publishing.com>





## Retrospective Study

# Application of single balloon enteroscopy-assisted therapeutic endoscopic retrograde cholangiopancreatography in patients after bilioenteric Roux-en-Y anastomosis: Experience of multi-disciplinary collaboration

Wen-Guang Wu, Lu-Cui Qin, Xiao-Ling Song, Ming-Ning Zhao, Wen-Jie Zhang, Jun Gu, Hao Weng, Ying-Bin Liu, Yi Zhang, Chun-Ying Qu, Lei-Ming Xu, Xue-Feng Wang

**ORCID number:** Wen-Guang Wu (0000-0001-8574-6247); Lu-Cui Qin (0000-0003-0670-9697); Xiao-Ling Song (0000-0001-7815-1851); Ming-Ning Zhao (0000-0002-3817-2989); Wen-Jie Zhang (0000-0001-8107-3647); Jun Gu (0000-0001-9821-889X); Hao Weng (0000-0002-7757-9546); Ying-Bin Liu (0000-0001-6110-0185); Yi Zhang (0000-0001-8540-0887); Chun-Ying Qu (0000-0003-1846-1924); Lei-Ming Xu (0000-0002-6735-4853); Xue-Feng Wang (0000-0001-9655-6609).

**Author contributions:** Wu WG, Qin LC, and Song XL contributed equally to this work; Wu WG, Qin LC, Zhao MN, and Wang XF contributed to the study concept and design; Qin LC, Song XL, Zhang WJ, Gu J, and Weng H contributed to data acquisition; Song XL, Zhang WJ, Gu J, and Weng H contributed to analysis and interpretation of the data; Wu WG, Zhao MN, Song XL, and Wang XF contributed to drafting of the manuscript; Wu WG, Qin LC, Zhao MN, Song XL, and Wang XF contributed to critical revision of the manuscript for important intellectual content; Gu J and Weng H analyzed the data; Liu YB, Zhang Y, Qu CY, and Xu LM contributed to administrative, technical, or material support; Wang XF supervised the study.

**Supported by** the National Natural Science Foundation of China, No.

**Wen-Guang Wu, Xiao-Ling Song, Ming-Ning Zhao, Wen-Jie Zhang, Jun Gu, Hao Weng, Ying-Bin Liu, Xue-Feng Wang**, Department of General Surgery and Laboratory of General Surgery, Xinhua Hospital Affiliated to Shanghai Jiao Tong University School of Medicine, Shanghai 200092, China

**Lu-Cui Qin**, Department of Operating Room, Xinhua Hospital Affiliated to Shanghai Jiao Tong University School of Medicine, Shanghai 200092, China

**Xiao-Ling Song, Ying-Bin Liu**, Shanghai Key Laboratory of Biliary Tract Disease Research, Shanghai 200092, China

**Yi Zhang, Chun-Ying Qu, Lei-Ming Xu**, Department of Gastroenterology, Xinhua Hospital Affiliated to Shanghai Jiao Tong University School of Medicine, Shanghai 200092, China

**Corresponding author:** Xue-Feng Wang, MD, Chief Doctor, Department of General Surgery and Laboratory of General Surgery, Xinhua Hospital Affiliated to Shanghai Jiao Tong University School of Medicine, No. 1665, Kongjiang Road, Shanghai 200092, China.

[wangxuefeng@xinhuaamed.com.cn](mailto:wangxuefeng@xinhuaamed.com.cn)

**Telephone:** +86-21-25077884

**Fax:** +86-21-25076880

## Abstract

### BACKGROUND

Bilioenteric Roux-en-Y anastomosis is one of the most complicated approaches for reconstructing the gastrointestinal tract, and endoscopic retrograde cholangiopancreatography (ERCP) is technically challenging in patients after bilioenteric Roux-en-Y anastomosis. The optimal endoscopic strategies for such cases remain unknown.

### AIM

To explore the feasibility and effectiveness of single balloon enteroscopy-assisted (SBE-assisted) therapeutic ERCP in patients after bilioenteric Roux-en-Y anastomosis based on multi-disciplinary collaboration between endoscopists and surgeons as well as report the experience from China.

### METHODS

31600075.

**Institutional review board**

**statement:** This study was approved by the Ethics Committee of the Xinhua Hospital Affiliated to Shanghai Jiao Tong University School of Medicine.

**Informed consent statement:**

Patients were not required to give informed consent to the study because the analysis used anonymous clinical data that were obtained after each patient agreed to treatment by written consent.

**Conflict-of-interest statement:** The authors declare no conflict of interest. The authors declare that they have nothing to disclose.

**Data sharing statement:** No additional data are available.

**Open-Access:** This is an open-access article that was selected by an in-house editor and fully peer-reviewed by external reviewers. It is distributed in accordance with the Creative Commons Attribution Non Commercial (CC BY-NC 4.0) license, which permits others to distribute, remix, adapt, build upon this work non-commercially, and license their derivative works on different terms, provided the original work is properly cited and the use is non-commercial. See: <http://creativecommons.org/licenses/by-nc/4.0/>

**Manuscript source:** Unsolicited manuscript

**Received:** June 24, 2019

**Peer-review started:** June 24, 2019

**First decision:** July 21, 2019

**Revised:** August 14, 2019

**Accepted:** August 24, 2019

**Article in press:** August 24, 2019

**Published online:** September 28, 2019

**P-Reviewer:** Katuchova J, Rungsakulkij N, Sperti C

**S-Editor:** Tang JZ

**L-Editor:** Wang TQ

**E-Editor:** Zhang YL



This is a single center retrospective study. All of the SBE-assisted therapeutic ERCP procedures were performed by the collaboration between endoscopists and surgeons. The operation time, success rate, and complication rate were calculated.

**RESULTS**

Forty-six patients received a total of 64 SBE-assisted therapeutic ERCP procedures, with successful scope intubation in 60 (93.8%) cases and successful diagnosis in 59 (92.2%). All successfully diagnosed cases received successful therapy. None of the cases had perforation or bleeding during or after operation, and no post-ERCP pancreatitis occurred.

**CONCLUSION**

Based on multi-disciplinary collaboration, SBE-assisted therapeutic ERCP in patients after bilioenteric Roux-en-Y anastomosis is relatively safe and effective and has a high success rate.

**Key words:** Bilioenteric Roux-en-Y anastomosis; Single balloon enteroscopy; Multi-disciplinary cooperation; Hepaticoduodenostomy; Pancreaticoduodenectomy

©The Author(s) 2019. Published by Baishideng Publishing Group Inc. All rights reserved.

**Core tip:** Bilioenteric Roux-en-Y anastomosis is one of the most complicated approaches for reconstructing the gastrointestinal tract. The change in the gastrointestinal anatomy, absence of the duodenal papilla, and angulation and adhesion of the small intestine, among others, make endoscopic retrograde cholangiopancreatography (ERCP) after bilioenteric Roux-en-Y anastomosis the most challenging operation. Based on multi-disciplinary collaboration, single balloon enteroscopy-assisted therapeutic ERCP in patients after bilioenteric Roux-en-Y anastomosis is relatively safe and effective and has a high success rates.

**Citation:** Wu WG, Qin LC, Song XL, Zhao MN, Zhang WJ, Gu J, Weng H, Liu YB, Zhang Y, Qu CY, Xu LM, Wang XF. Application of single balloon enteroscopy-assisted therapeutic endoscopic retrograde cholangiopancreatography in patients after bilioenteric Roux-en-Y anastomosis: Experience of multi-disciplinary collaboration. *World J Gastroenterol* 2019; 25(36): 5505-5514

**URL:** <https://www.wjgnet.com/1007-9327/full/v25/i36/5505.htm>

**DOI:** <https://dx.doi.org/10.3748/wjg.v25.i36.5505>

**INTRODUCTION**

Endoscopic retrograde cholangiopancreatography (ERCP) is a clinically important micro-invasive treatment for pancreatobiliary disease. For patients with normal anatomy, the ERCP success rate is generally more than 90%<sup>[1]</sup>. With the development and advancement of the ERCP technique, ERCP after upper gastrointestinal (GI) surgeries such as Bilioenteric Roux-en-Y anastomosis is now possible and has been performed clinically<sup>[2]</sup>. Bilioenteric Roux-en-Y anastomosis is one of the most complicated approaches for reconstructing the gastrointestinal tract. The change in the gastrointestinal anatomy, absence of the duodenal papilla, and angulation and adhesion of the small intestine, among others, make ERCP after bilioenteric Roux-en-Y anastomosis the most challenging operation. For these reasons, treatment with a conventional side-viewing duodenoscope is very difficult. More recently, single-balloon enteroscopy (SBE) has been used to improve the feasibility of ERCP after bilioenteric Roux-en-Y anastomosis<sup>[3-5]</sup>. Our center attempted ERCP treatment after re-construction surgery starting in 1998 and has gained some experience<sup>[6-9]</sup>. With the research at our center, this article aimed to explore the feasibility and effectiveness of SBE-assisted therapeutic ERCP in patients after bilioenteric Roux-en-Y anastomosis based on multi-disciplinary collaboration between endoscopists and surgeons and to report the experience from China.

## MATERIALS AND METHODS

### Patients

From March 2010 to May 2016, our general surgery department completed 64 cases of SBE-assisted therapeutic ERCP in 46 patients after bilioenteric Roux-en-Y anastomosis. The subjects included 27 males and 19 females with ages ranging from 11 years to 76 years. Their prior operation history included 18 cases of pancreaticoduodenectomy, 25 cases of bilioenteric Roux-en-Y anastomosis, and 1 case of total pancreatectomy. Two cases had undergone two prior operations, including 1 case of Billroth II gastroenterostomy + pancreaticoduodenectomy and 1 case of bilioenteric Roux-en-Y anastomosis + pancreaticoduodenectomy. The indications for ERCP included intrahepatic stones, anastomotic stricture of bilioenteric Roux-en-Y anastomosis, and foreign body remaining at the anastomotic site of a chododochojunostomy, among others (Table 1).

### Major devices

Olympus CV-260 central unit, SIF-260 small balloon enteroscope (working length 200 cm, outer diameter 9.2 mm, biopsy channel 2.8 mm) and ST-SB 1 single use overtube (working length 132 cm, outer diameter 13.2 mm, internal diameter 11 mm), and OBCU balloon control unit were used. Cotton sphincterotome (COOK, 320 cm length, United States), Glo-Tip ERCP catheter (COOK, 320 cm, United States), Tracer Metro Direct wireguide (COOK, 600 cm length, United States), OASIS stent introducer (COOK, 320 cm length, United States), 5 Fr pushing catheter (COOK, 320 length, United States), Quantum TTC biliary balloon dilator (COOK, 320 cm length, United States), Tri-EX triple lumen balloon extractor (Cook, 275 cm length, United States), and other conventional ERCP devices were also employed.

### Operation team task assignment and operating methods

The entire operation team included an endoscopist, a general surgeon, and nurse assistants (Figure 1). Before the operation, all team members got together and reviewed the patient's history, especially the prior history of upper GI surgeries. The general surgeon then drew the scope intubation schema of SBE-assisted ERCP, and all team members studied the drawing (Figure 2). The patient was placed in the prone position with airway intubation general anesthesia. SBE was operated by two operators; the endoscopist worked with the nurse to perform the operation. The process for slowly moving the scope forward included the use of a CO<sub>2</sub> supply, inflation scope and overtube, deflation and drag movements, which were repeated. During the operation, the general surgeon monitored the X-ray image to determine and guide the scope progress while searching for the bilioenteric Roux-en-Y anastomosis. The general surgeon completed the biliary duct cannulation, anastomosis dilation, stone extraction or biliary stent insertion, and subsequent ERCP operations (Figure 3). During the procedure, the enteroscope maneuver was performed by the endoscopist.

### Outcome definitions

Enteroscopy success was defined as accessing the biliary-enteric anastomosis. Diagnostic success was defined as obtaining a cholangiogram. ERCP success was defined as completion of the intended ERCP intervention<sup>[10]</sup>. ERCP-related adverse events were categorized using the ERCP consensus guidelines<sup>[11]</sup>.

## RESULTS

Forty-six patients received a total of 64 SBE-assisted ERCP procedures. Among them, 8 patients underwent the procedure twice, 2 patients underwent it 3 times, and 2 patients underwent it 4 times. Of the 64 procedures, 60 had successful endoscopic intubation with a successful scope intubation rate of 93.8%. Additionally, 59 resulted in a successful diagnosis with a successful diagnosis rate of 92.2%. Of all successful scope intubation cases, only 1 case had failure of bile duct cannulation because of anatomic stricture and 59 cases had successful ERCP with an ERCP success rate of 92.2%. All successfully diagnosed cases received successful therapy. None of the cases had perforation, bleeding during or after operation, or acute complications, such as post-operation pancreatitis (Table 2).

**Table 1** Baseline characteristics of study patients (*n* = 46)

Characteristic	Value
Age, yr, mean $\pm$ SD	72.1 $\pm$ 11.2
Male gender, <i>n</i> (%)	27 (58.7)
Indication for ERCP, <i>n</i> (%)	
Common bile duct stone	32 (69.6)
Benign biliary stricture	20 (43.5)
Pancreaticobiliary malignancy	6 (13.0)
Foreign body at the anastomotic site	10 (21.7)
Duration since bilioenteric Roux-en-Y anastomosis, <i>n</i> (%)	
$\leq$ 5 yr	
$>$ 5 yr	
Prior operation history	
Pancreatico-duodenectomy	18 (39.1%)
Bilioenteric Roux-en-Y anastomosis	25 (54.3%)
Total pancreatectomy	1 (2.2%)
Billroth II gastroenterostomy + pancreatico-duodenectomy	1 (2.2%)
Bilioenteric Roux-en-Y anastomosis + pancreatico-duodenectomy	1 (2.2%)

SD: Standard deviation; ERCP: Endoscopic retrograde cholangiopancreatography.

## DISCUSSION

In terms of a standardized type of ERCP after GI tract surgery for better classification and treatment, there is no current commonly accepted classification method in China or internationally. However, there is a basic consensus on the factors that need to be considered in classifying the type of ERCP after GI tract surgery. They are summarized as follows: (1) The type of GI tract reconstruction<sup>[12]</sup>, from the perspective of surgery, including Billroth I, Billroth II (including Braun anastomosis), total gastrectomy Roux-en-Y anastomosis, pancreaticoduodenectomy (including cholecystectomy), and choledochojejunostomy (Roux-en-Y anastomosis); (2) The presence of the native papilla is closely related to biliary cannulation; (3) Common bile duct stone extraction, biliary stent insertion, chole-dochojejunostomy anatomic stricture dilation, intrahepatic stone extraction, *etc.*<sup>[13]</sup>; and (4) Other factors, including the doctor's operation approach and specialty, among others, can have an influence. In other words, the more comprehensive the consideration, the more accurate the classification of factors that affect post-GI surgery ERCP, resulting in a higher success rate.

Our center started performing post-GI surgery ERCP in 1998, and it is one of the earliest centers to explore these techniques and methods in the field. With almost 20 years of experience, our center has established its own characteristics and specialties in post-GI surgery ERCP. From 2009 until now, our center has treated more than 300 cases of GI tract reconstruction, including Billroth I, Billroth II (including Braun), total gastrectomy Roux-en-Y anastomosis, pancreaticoduodenectomy, and choledochojejunostomy, and it is one of the centers with the highest volume of post-surgery ERCP cases.

Roux-en-Y bypass can present a significant challenge<sup>[14]</sup>. Because it is very rare in China, we did not cover it in our study. For post-gastrectomy patients who still have a native papilla structure, bile duct cannulation is needed in this type of post-surgery ERCP, which will affect the endoscope selection. Because native papilla cannulation of post-gastrectomy ERCP is difficult, our experience on this involves the use of a conventional side-viewing duodenoscope with an elevator as it has more advantages. By contrast, for choledochojejunostomy, directly cannulating the anastomosis is easier with a single balloon enteroscope.

The major biliary diseases of post-choledochojejunostomy patients include a foreign body at the anastomosis, anastomosis stricture, and intrahepatic stones<sup>[15]</sup>. This is very different from the post-gastrectomy (partial or total) patients. For post-gastrectomy patients, the major diseases are common bile duct stricture and stones<sup>[15]</sup>. In view of these differences, choledochojejunostomy is very different from other GI tract reconstructions in terms of the reconstruction route and ERCP operation characteristics. Therefore, in this report, we considered choledochojejunostomy as a





**Figure 1** The entire operation team, including the general surgeon (A), endoscopist (B), and nurse assistants (C).

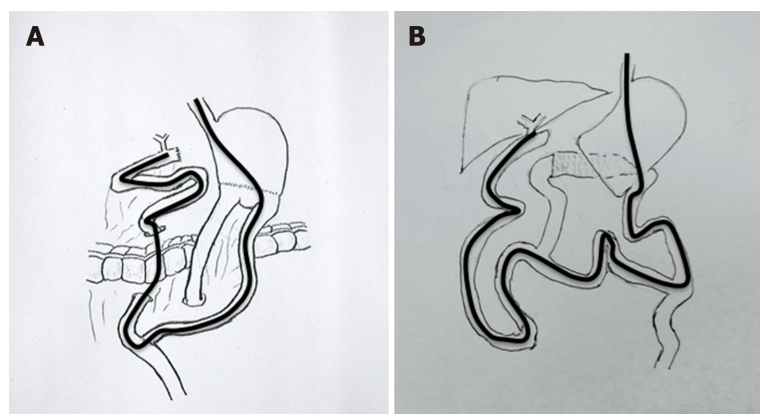
special type of upper GI tract reconstruction for discussion and then analyzed and attempted ERCP in this patient group with the aim of offering these patients minimally invasive treatments.

For post-gastrectomy ERCP operation, the use of a conventional side-viewing duodenoscope always has a higher success rate of biliary cannulation and therapy; however, the intubation rate is lower than for the forward-viewing scope<sup>[16]</sup>. For the side-viewing duodenoscope, there should be more focus on the success rate of scope intubation. We recommend the use of the “retrieval balloon-assisted enterography”<sup>[6-9]</sup> combined with X-ray imaging to guide the scope progress and effectively improve the scope intubation rate. When using the forward viewing enteroscope, the intubation rate is generally higher, but forward viewing scope cannulation with the normal trans papilla biliary cannulation remains very difficult. For a forward viewing endoscope, there should be more focus on improving the success rate of biliary cannulation and therapy<sup>[17]</sup>. We chose to use a single balloon enteroscope to assist ERCP. One reason is that the single balloon enteroscope is more slim and flexible than other scopes, and it has an overtube to assist with scope progress, which will have a higher scope intubation rate. Another reason is that intrahepatic stones often require the scope to enter the intrahepatic bile duct as well as relative procedures under direct monitoring. Therefore, a scope with a larger working channel is larger in diameter, which cannot go inside the intrahepatic bile ducts, making it unsuitable for stone clearance. At present, SBE-assisted ERCP compatible long length devices are under development and on sale. We use SBE to assist with post-pancreatic biliary surgery ERCP and have achieved satisfying results with a success rate above 90%. This result is superior to previous studies<sup>[10,18-22]</sup> (Table 3).

The post-choledochojunostomy ERCP operations in our center were all done with the collaboration of endoscopists and surgeons. The endoscopist operated the SBE intubation and relative endoscope maneuvers, while the surgeon was in charge of scope intubation guidance and relative treatments. The importance of this collaboration is one of the most important conclusions we have drawn from our work on post-GI tract reconstruction ERCP.

In addition, for treatment with post-choledochojunostomy ERCP, we try to push the tip of the enteroscope into the intrahepatic bile duct *via* the choledochojunostomy anastomosis, which allows for performance of the treatments under direct visualization. If there is an anastomosis stricture, we use balloon dilation to dilate the stricture and then let the scope enter the intrahepatic duct. Theoretically, performing enteroscopy *via* the anastomosis and entering the intrahepatic duct can allow for more direct, accurate, and comprehensive diagnosis as well as avoid missed diagnoses. Operations performed under these conditions, such as stone extraction under direct visualization, can be more accurate and avoid unnecessary injury. Large stones can also be removed after holmium laser lithotripsy under SBE direct visualization. Before completing the procedure, this approach can also directly visualize and confirm that the stones are all extracted and that there are no residual





**Figure 2 Schema of the operation procedure.** A: Billroth II gastroenterostomy and pancreaticoduodenectomy; B: Bilioenteric Roux-en-Y anastomosis and pancreaticoduodenectomy.

stones. If we only rely on X-ray, we cannot achieve the above goals. For this reason, we emphasize placing the enteroscope tip into the intrahepatic bile duct *via* the anastomosis and then performing treatment. This approach will be more comprehensive and effective and will reduce the need for repeated ERCPs after the operation.

The endoscopist is in charge of operating the enteroscope, while the surgeon is in charge of diagnosis and therapy. The enteroscope enters the choledochojejunostomy anastomosis and treats the disease under direct visualization. This is similar to the surgical choledochoscope maneuver. The surgeon is familiar with the anatomy of the intrahepatic duct and stone localization and extraction. As a result, in our opinion, surgeons will have a higher rate of success in performing the diagnosis and therapy. In view of this, SBE-assisted ERCP based on collaboration between the endoscopist and surgeon will be the first choice for patients after choledochojejunostomy.

SBE-assisted therapeutic ERCP is easier with a higher treatment success rate and lower complication rate than other endoscopic assisted operations. However, some limitations remain, including SBE-assisted ERCP compatible accessories that are awaiting further study and the metal stent delivery system that cannot go through the 2.8-mm working channel, *etc.* In view of this, there is progress on the development of a series of endoscopes and accessories<sup>[23]</sup>. This is systematic and complicated work, and true progress can only be made in medical practice. SBE-assisted ERCP based on the collaboration between an endoscopist and surgeon after choledochojejunostomy is relatively safe and effective and has a relatively high success rate. Although our results are encouraging for the support of SBE-assisted ERCP, further large prospective, multicenter studies to evaluate the efficacy of SBE-ERCP need to be conducted to confirm these findings<sup>[13]</sup>. However, ERCP after choledochojejunostomy and after upper GI tract surgery remains challenging. We are striving to make ERCP treatment in these patients safer, more effective, more standardized, easier to operate, and easier to generalize as a technique.

**Table 2 Clinical outcomes of endoscopic retrograde cholangiopancreatography in the study cohort**

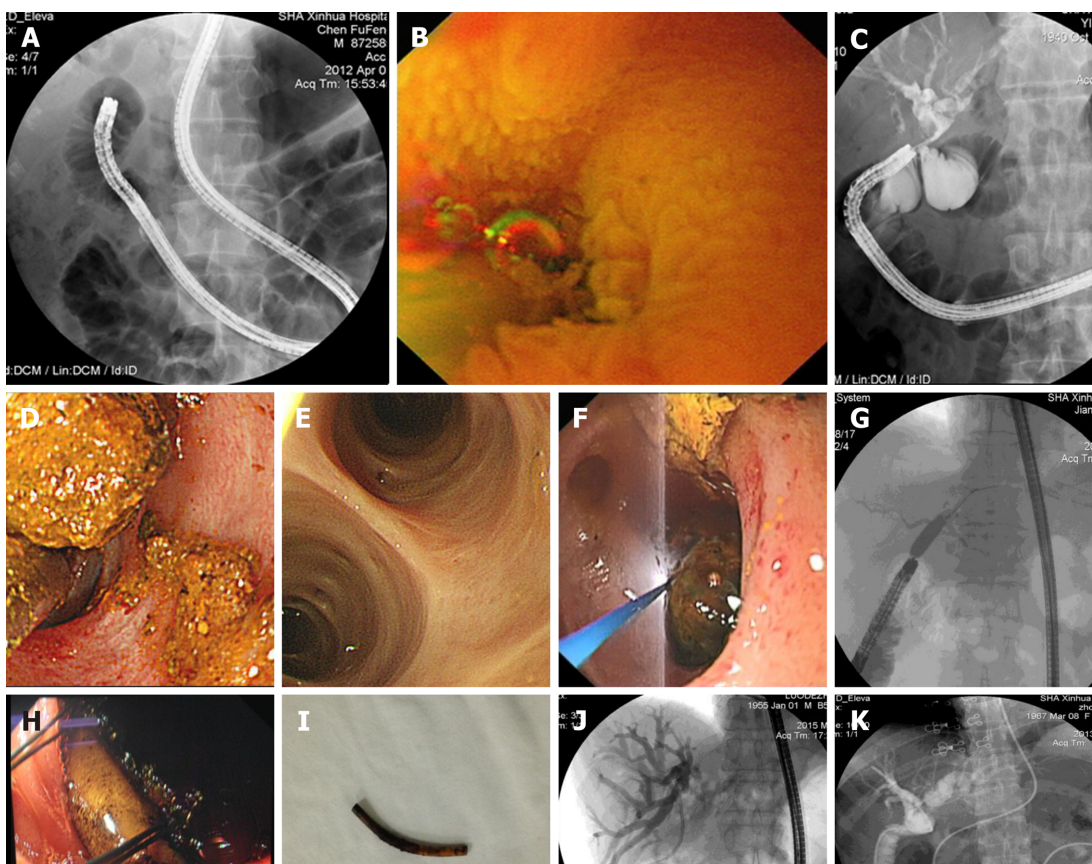
Outcome	No. of patients, n (%)
Technical success	
Enteroscopy success	60 (93.8)
Diagnostic success	59 (92.2)
ERCP success	59 (92.2)
Intervention	
Stone extraction	31(48.4)
Holmium laser lithotripsy	8 (12.5)
Anastomotic incision	10 (15.6)
Balloon dilation of stenotic anastomosis	19 (29.7)
ENBD	30 (46.8)
Biliary plastic stent placement and removal	6 (9.4)
Foreign body extraction	10 (15.6)
Reason for ERCP failure	
Failure to reach the papilla	4 (6.3)
Failure of selective bile duct cannulation	1 (1.6)
Failure of bile duct stone removal or ERBD insertion	0 (0)
Failure because of afferent loop perforation	0 (0)
Overall adverse events	0 (0)
Perforation	0 (0)
Pancreatitis	0 (0)
Bleeding	0 (0)

ERCP: Endoscopic retrograde cholangiopancreatography; ENBD: Endoscopic retrograde biliary drainage.

**Table 3 Summary of reports of endoscopic retrograde cholangiopancreatography using single-balloon enteroscopy technique in patients with Roux-en-Y anastomosis**

Author	Publication year	Number of procedures	Enteroscopy success rate	ERCP success rate	Complication rate
Dellon <i>et al</i> <sup>[18]</sup>	2009	4	75%	75%	0
Saleem <i>et al</i> <sup>[19]</sup>	2010	50	75%	66%	0
Shah <i>et al</i> <sup>[10]</sup>	2013	45	69%	60%	No data
Tomizawa <i>et al</i> <sup>[20]</sup>	2014	14	68%	50%	0
Soh <i>et al</i> <sup>[21]</sup>	2015	6	83.3%	50%	16.7%
Yane <i>et al</i> <sup>[22]</sup>	2016	183	91.8%	80.3%	No data

ERCP: Endoscopic retrograde cholangiopancreatography; SBE: Single-balloon enteroscopy.



**Figure 3 The operation procedure.** A: The endoscopist collaborated with the nurse to inflate the scope and overtube as well as deflate and move the equipment, which were repeated to slowly advance the scope forward; B: Locating the bilioenteric Roux-en-Y anastomosis (Endoscopic view); C: Completion of the biliary duct cannulation and cholangiogram, revealing intrahepatic bile duct stones; D: Intrahepatic bile duct stones were extracted successfully; E: Operations such as stone extraction under direct visualization can be more accurate. Before completing the procedure, visualizing and confirming that the stones are all extracted and that there are no residual stones are possible; F: Large stones can also be extracted after holmium laser lithotripsy under SBE direct visualization; G: Bilioenteric Roux-en-Y anastomotic stricture was treated by balloon dilatation; H: Foreign body at the anastomotic site (endoscopic view); I: The foreign body was extracted successfully; J: Bilioenteric Roux-en-Y anastomosis malignant stenosis was treated by balloon dilatation and stenting; K: Successful endoscopic nasobiliary drainage via a single balloon enteroscope.

## ARTICLE HIGHLIGHTS

### Research background

Bilioenteric Roux-en-Y anastomosis is one of the most complicated approaches for reconstructing the gastrointestinal tract, and endoscopic retrograde cholangiopancreatography (ERCP) is technically challenging in patients with bilioenteric Roux-en-Y anastomosis. The optimal endoscopic strategies for such cases remain unknown.

### Research motivation

The motivation of this research was to explore the feasibility and effectiveness of single balloon enteroscopy-assisted (SBE-assisted) therapeutic ERCP in patients after bilioenteric Roux-en-Y anastomosis based on multi-disciplinary collaboration between endoscopists and surgeons.

### Research objectives

To explore the feasibility and effectiveness of SBE-assisted therapeutic ERCP in patients after bilioenteric Roux-en-Y anastomosis based on multi-disciplinary collaboration between endoscopists and surgeons as well as report the experience from China.

### Research methods

This is a single center retrospective study. All of the SBE-assisted therapeutic ERCP procedures were performed by the collaboration between endoscopists and surgeons. The operation time, success rate, and complication rate were calculated.

### Research results

Forty-six patients received a total of 64 SBE-assisted therapeutic ERCP procedures, with successful scope intubation in 60 (93.8%) cases and successful diagnosis in 59 (92.2%). All successfully diagnosed cases received successful therapy. None of the cases had perforation or bleeding during or after operation, and no post-ERCP pancreatitis occurred.

### Research conclusions

Based on multi-disciplinary collaboration, SBE-assisted therapeutic ERCP in patients after bilioenteric Roux-en-Y anastomosis is relatively safe and effective and has a high success rates.

### Research perspectives

Our results are encouraging for the support of SBE-assisted ERCP, and further large prospective, and multicenter studies to evaluate the efficacy of SBE-ERCP need to be conducted to confirm these findings.

## ACKNOWLEDGEMENTS

We thank our endoscopy assistants, Lei Zang, Yan-Ming Duan, Yu-Feng Li, Li-Li Xu, Fei Shen, and Chao Ting, who assisted with the examinations and worked out the procedural standards for preparation, assistance, and post-processing of the procedure. They were invaluable for performing this study.

## REFERENCES

- 1 **Freeman ML**, Guda NM. ERCP cannulation: a review of reported techniques. *Gastrointest Endosc* 2005; **61**: 112-125
- 2 **Kurzynske FC**, Romagnuolo J, Brock AS. Success of single-balloon enteroscopy in patients with surgically altered anatomy. *Gastrointest Endosc* 2015; **82**: 319-324
- 3 **Azeem N**, Tabibian JH, Baron TH, Orhurhu V, Rosen CB, Petersen BT, Gostout CJ, Topazian MD, Levy MJ. Use of a single-balloon enteroscope compared with variable-stiffness colonoscopes for endoscopic retrograde cholangiography in liver transplant patients with Roux-en-Y biliary anastomosis. *Gastrointest Endosc* 2013; **77**: 568-577
- 4 **Skinner M**, Popa D, Neumann H, Wilcox CM, Mönkemüller K. ERCP with the overtube-assisted enteroscopy technique: a systematic review. *Endoscopy* 2014; **46**: 560-572
- 5 **Neumann H**, Fry LC, Meyer F, Malfertheiner P, Monkemüller K. Endoscopic retrograde cholangiopancreatography using the single balloon enteroscope technique in patients with Roux-en-Y anastomosis. *Digestion* 2009; **80**: 52-57
- 6 **Wu WG**, Zhang WJ, Gu J, Zhao MN, Zhuang M, Tao YJ, Liu YB, Wang XF. Retrieval-balloon-assisted enterography for ERCP after Billroth II gastroenterostomy and Braun anastomosis. *World J Gastroenterol* 2014; **20**: 10921-10926
- 7 **Wu WG**, Gu J, Zhang WJ, Zhao MN, Zhuang M, Tao YJ, Liu YB, Wang XF. ERCP for patients who have undergone Billroth II gastroenterostomy and Braun anastomosis. *World J Gastroenterol* 2014; **20**: 607-610
- 8 **Wu WG**, Mei JW, Zhao MN, Zhang WJ, Gu J, Tao YJ, Liu YB, Wang XF. Use of the Conventional Side-viewing Duodenoscope for Successful Endoscopic Retrograde Cholangiopancreatography in Postgastrectomy Patients. *J Clin Gastroenterol* 2016; **50**: 244-251
- 9 **Zhuang M**, Zhang W, Gu J, Gong W, Wang X. ERCP with retrieval balloon-assisted enterography using traditional duodenoscope in post-GI surgery patients. *Gastrointest Endosc* 2013; **77**: 315-316
- 10 **Shah RJ**, Smolkin M, Yen R, Ross A, Kozarek RA, Howell DA, Bakis G, Jonnalagadda SS, Al-Lehibi AA, Hardy A, Morgan DR, Sethi A, Stevens PD, Akerman PA, Thakkar SJ, Brauer BC. A multicenter, U.S. experience of single-balloon, double-balloon, and rotational overtube-assisted enteroscopy ERCP in patients with surgically altered pancreaticobiliary anatomy (with video). *Gastrointest Endosc* 2013; **77**: 593-600
- 11 **Cotton PB**, Lehman G, Vennes J, Geenen JE, Russell RC, Meyers WC, Liguory C, Nickl N. Endoscopic sphincterotomy complications and their management: an attempt at consensus. *Gastrointest Endosc* 1991; **37**: 383-393
- 12 **Moreels TG**. Altered anatomy: enteroscopy and ERCP procedure. *Best Pract Res Clin Gastroenterol* 2012; **26**: 347-357
- 13 **Inamdar S**, Slattery E, Sejpal DV, Miller LS, Pleskow DK, Berzin TM, Trindade AJ. Systematic review and meta-analysis of single-balloon enteroscopy-assisted ERCP in patients with surgically altered GI anatomy. *Gastrointest Endosc* 2015; **82**: 9-19
- 14 **Schreiner MA**, Chang L, Gluck M, Irani S, Gan SI, Brandabur JJ, Thirlby R, Moonka R, Kozarek RA, Ross AS. Laparoscopy-assisted versus balloon enteroscopy-assisted ERCP in bariatric post-Roux-en-Y gastric bypass patients. *Gastrointest Endosc* 2012; **75**: 748-756
- 15 **Park TY**, Kang JS, Song TJ, Lee SS, Lee H, Choi JS, Kim HJ, Jang JW. Outcomes of ERCP in Billroth II gastrectomy patients. *Gastrointest Endosc* 2016; **83**: 1193-1201
- 16 **Ki HS**, Park CH, Jun CH, Park SY, Kim HS, Choi SK, Rew JS. Feasibility of cap-assisted endoscopic retrograde cholangiopancreatography in patients with altered gastrointestinal anatomy. *Gut Liver* 2015; **9**: 109-112
- 17 **Cheng CL**, Liu NJ, Tang JH, Yu MC, Tsui YN, Hsu FY, Lee CS, Lin CH. Double-balloon enteroscopy for ERCP in patients with Billroth II anatomy: results of a large series of papillary large-balloon dilation for biliary stone removal. *Endosc Int Open* 2015; **3**: E216-E222
- 18 **Dellon ES**, Kohn GP, Morgan DR, Grimm IS. Endoscopic retrograde cholangiopancreatography with single-balloon enteroscopy is feasible in patients with a prior Roux-en-Y anastomosis. *Dig Dis Sci* 2009; **54**: 1798-1803
- 19 **Saleem A**, Baron TH, Gostout CJ, Topazian MD, Levy MJ, Petersen BT, Wong Kee Song LM. Endoscopic retrograde cholangiopancreatography using a single-balloon enteroscope in patients with altered Roux-en-Y anatomy. *Endoscopy* 2010; **42**: 656-660
- 20 **Tomizawa Y**, Sullivan CT, Gelrud A. Single balloon enteroscopy (SBE) assisted therapeutic endoscopic retrograde cholangiopancreatography (ERCP) in patients with roux-en-y anastomosis. *Dig Dis Sci* 2014; **59**: 465-470
- 21 **Soh JS**, Yang DH, Lee SS, Lee S, Bae J, Byeon JS, Myung SJ, Yang SK. Single Balloon Enteroscopy-

- Assisted Endoscopic Retrograde Cholangiopancreatography in Patients Who Underwent a Gastrectomy with Roux-en-Y Anastomosis: Six Cases from a Single Center. *Clin Endosc* 2015; **48**: 452-457
- 22 **Yane K**, Katanuma A, Maguchi H, Takahashi K, Kin T, Ikarashi S, Sano I, Yamazaki H, Kitagawa K, Yokoyama K, Koga H, Nagai K, Nojima M. Short-type single-balloon enteroscope-assisted ERCP in postsurgical altered anatomy: potential factors affecting procedural failure. *Endoscopy* 2017; **49**: 69-74
- 23 **Moreels TG**, Kouinche Madenko N, Taha A, Piessevaux H, Deprez PH. Therapeutic enteroscopy using a new single-balloon enteroscope: a case series. *Endosc Int Open* 2016; **4**: E918-E921





Published By Baishideng Publishing Group Inc  
7041 Koll Center Parkway, Suite 160, Pleasanton, CA 94566, USA  
Telephone: +1-925-2238242  
E-mail: [bpgoffice@wjgnet.com](mailto:bpgoffice@wjgnet.com)  
Help Desk: <http://www.f6publishing.com/helpdesk>  
<http://www.wjgnet.com>

