

World Journal of *Clinical Cases*

World J Clin Cases 2019 November 26; 7(22): 3683-3914



**REVIEW**

- 3683** Colorectal cancer: The epigenetic role of microbiome
Sabit H, Cevik E, Tombuloglu H

ORIGINAL ARTICLE**Case Control Study**

- 3698** Human podocyte injury in the early course of hypertensive renal injury
Sun D, Wang JJ, Wang W, Wang J, Wang LN, Yao L, Sun YH, Li ZL

Retrospective Cohort Study

- 3711** Relationship between acute hypercarbia and hyperkalaemia during surgery
Weinberg L, Russell A, Mackley L, Dunnachie C, Meyerov J, Tan C, Li M, Hu R, Karalapillai D

Retrospective Study

- 3718** Surgical treatment of patients with severe non-flail chest rib fractures
Zhang JP, Sun L, Li WQ, Wang YY, Li XZ, Liu Y
- 3728** Super-selective arterial embolization in the control of acute lower gastrointestinal hemorrhage
Ly LS, Gu JT
- 3734** End-stage liver disease score and future liver remnant volume predict post-hepatectomy liver failure in hepatocellular carcinoma
Kong FH, Miao XY, Zou H, Xiong L, Wen Y, Chen B, Liu X, Zhou JJ

Observational Study

- 3742** Treatment of hemorrhoids: A survey of surgical practice in Australia and New Zealand
Fowler GE, Siddiqui J, Zahid A, Young CJ
- 3751** Relationship between homocysteine level and prognosis of elderly patients with acute ischemic stroke treated by thrombolysis with recombinant tissue plasminogen activator
Li J, Zhou F, Wu FX

CASE REPORT

- 3757** Cystic fibrosis transmembrane conductance regulator functional evaluations in a G542X+/- IVS8Tn:T7/9 patient with acute recurrent pancreatitis
Caldrer S, Bergamini G, Sandri A, Vercellone S, Rodella L, Cerofolini A, Tomba F, Catalano F, Frulloni L, Buffelli M, Tridello G, de Jonge H, Assael BM, Sorio C, Melotti P

- 3765** Ulcerated intussuscepted jejunal lipoma-uncommon cause of obscure gastrointestinal bleeding: A case report
Cuciureanu T, Huiban L, Chiriac S, Singeap AM, Danciu M, Mihai F, Stanciu C, Trifan A, Vlad N
- 3772** Ultrasonographic evaluation of the effect of extracorporeal shock wave therapy on calcific tendinopathy of the rectus femoris tendon: A case report
Lee CH, Oh MK, Yoo JI
- 3778** Contrast-enhanced computed tomography findings of a huge perianal epidermoid cyst: A case report
Sun PM, Yang HM, Zhao Y, Yang JW, Yan HF, Liu JX, Sun HW, Cui Y
- 3784** Iatrogenic crystalline lens injury during intravitreal injection of triamcinolone acetonide: A report of two cases
Su J, Zheng LJ, Liu XQ
- 3792** Sagliker syndrome: A case report of a rare manifestation of uncontrolled secondary hyperparathyroidism in chronic renal failure
Yu Y, Zhu CF, Fu X, Xu H
- 3800** Pre-eclampsia with new-onset systemic lupus erythematosus during pregnancy: A case report
Huang PZ, Du PY, Han C, Xia J, Wang C, Li J, Xue FX
- 3807** Unilateral congenital scrotal agenesis with ipsilateral cryptorchidism: A case report
Fang Y, Lin J, Wang WW, Qiu J, Xie Y, Sang LP, Mo JC, Luo JH, Wei JH
- 3812** Metastatic infection caused by hypervirulent *Klebsiella pneumonia* and co-infection with *Cryptococcus meningitis*: A case report
Shi YF, Wang YK, Wang YH, Liu H, Shi XH, Li XJ, Wu BQ
- 3821** Allergic fungal rhinosinusitis accompanied by allergic bronchopulmonary aspergillosis: A case report and literature review
Cheng KJ, Zhou ML, Liu YC, Zhou SH
- 3832** Invasive aspergillosis presenting as hilar masses with stenosis of bronchus: A case report
Su SS, Zhou Y, Xu HY, Zhou LP, Chen CS, Li YP
- 3838** Retropharyngeal abscess presenting as acute airway obstruction in a 66-year-old woman: A case report
Lin J, Wu XM, Feng JX, Chen MF
- 3844** Thoracoscopic segmentectomy assisted by three-dimensional computed tomography bronchography and angiography for lung cancer in a patient living with situs inversus totalis: A case report
Wu YJ, Bao Y, Wang YL
- 3851** Single-lung transplantation for pulmonary alveolar microlithiasis: A case report
Ren XY, Fang XM, Chen JY, Ding H, Wang Y, Lu Q, Ming JL, Zhou LJ, Chen HW

- 3859** Respiratory failure and macrophage activation syndrome as an onset of systemic lupus erythematosus: A case report
Sun J, Wang JW, Wang R, Zhang H, Sun J
- 3866** Diagnosis of gastric duplication cyst by positron emission tomography/computed tomography: A case report
Hu YB, Gui HW
- 3872** Peritoneal cancer after bilateral mastectomy, hysterectomy, and bilateral salpingo-oophorectomy with a poor prognosis: A case report and review of the literature
Ma YN, Bu HL, Jin CJ, Wang X, Zhang YZ, Zhang H
- 3881** Apatinib for treatment of a pseudomyxoma peritonei patient after surgical treatment and hyperthermic intraperitoneal chemotherapy: A case report
Huang R, Shi XL, Wang YF, Yang F, Wang TT, Peng CX
- 3887** Novel frameshift mutation causes early termination of the thyroxine-binding globulin protein and complete thyroxine-binding globulin deficiency in a Chinese family: A case report
Dang PP, Xiao WW, Shan ZY, Xi Y, Wang RR, Yu XH, Teng WP, Teng XC
- 3895** Diffuse large B-cell lymphoma arising from follicular lymphoma with warthin's tumor of the parotid gland - immunophenotypic and genetic features: A case report
Wang CS, Chu X, Yang D, Ren L, Meng NL, Lv XX, Yun T, Cao YS
- 3904** Exogenous endophthalmitis caused by *Enterococcus casseliflavus*: A case report
Bao QD, Liu TX, Xie M, Tian X

LETTER TO THE EDITOR

- 3912** Microbial transglutaminase should be considered as an environmental inducer of celiac disease
Lerner A, Matthias T

ABOUT COVER

Editorial Board Member of *World Journal of Clinical Cases*, Ridvan Hamid Alimehmeti, MD, PhD, Associate Professor, Lecturer, Surgeon, Department of Neuroscience, University of Medicine, Tirana 1000, Albania

AIMS AND SCOPE

The primary aim of *World Journal of Clinical Cases* (WJCC, *World J Clin Cases*) is to provide scholars and readers from various fields of clinical medicine with a platform to publish high-quality clinical research articles and communicate their research findings online.

WJCC mainly publishes articles reporting research results and findings obtained in the field of clinical medicine and covering a wide range of topics, including case control studies, retrospective cohort studies, retrospective studies, clinical trials studies, observational studies, prospective studies, randomized controlled trials, randomized clinical trials, systematic reviews, meta-analysis, and case reports.

INDEXING/ABSTRACTING

The WJCC is now indexed in PubMed, PubMed Central, Science Citation Index Expanded (also known as SciSearch®), and Journal Citation Reports/Science Edition. The 2019 Edition of Journal Citation Reports cites the 2018 impact factor for WJCC as 1.153 (5-year impact factor: N/A), ranking WJCC as 99 among 160 journals in Medicine, General and Internal (quartile in category Q3).

RESPONSIBLE EDITORS FOR THIS ISSUE

Responsible Electronic Editor: Ji-Hong Liu

Proofing Production Department Director: Yun-Xiaojuan Wu

NAME OF JOURNAL

World Journal of Clinical Cases

ISSN

ISSN 2307-8960 (online)

LAUNCH DATE

April 16, 2013

FREQUENCY

Semimonthly

EDITORS-IN-CHIEF

Dennis A Bloomfield, Bao-Gan Peng, Sandro Vento

EDITORIAL BOARD MEMBERS

<https://www.wjnet.com/2307-8960/editorialboard.htm>

EDITORIAL OFFICE

Jin-Lei Wang, Director

PUBLICATION DATE

November 26, 2019

COPYRIGHT

© 2019 Baishideng Publishing Group Inc

INSTRUCTIONS TO AUTHORS

<https://www.wjnet.com/bpg/gerinfo/204>

GUIDELINES FOR ETHICS DOCUMENTS

<https://www.wjnet.com/bpg/GerInfo/287>

GUIDELINES FOR NON-NATIVE SPEAKERS OF ENGLISH

<https://www.wjnet.com/bpg/gerinfo/240>

PUBLICATION MISCONDUCT

<https://www.wjnet.com/bpg/gerinfo/208>

ARTICLE PROCESSING CHARGE

<https://www.wjnet.com/bpg/gerinfo/242>

STEPS FOR SUBMITTING MANUSCRIPTS

<https://www.wjnet.com/bpg/GerInfo/239>

ONLINE SUBMISSION

<https://www.f6publishing.com>



Single-lung transplantation for pulmonary alveolar microlithiasis: A case report

Xing-Yu Ren, Xiang-Ming Fang, Jing-Yu Chen, Hao Ding, Yan Wang, Qiu Lu, Jia-Lei Ming, Li-Juan Zhou, Hong-Wei Chen

ORCID number: Xing-Yu Ren (0000-0001-6122-6837); Xiang-Ming Fang (0000-0003-2961-0809); Jing-Yu Chen (0000-0002-2127-1788); Hao Ding (0000-0003-2866-0302); Yan Wang (0000-0002-5151-922X); Lu Qiu (0000-0001-5510-9589); Jia-Lei Ming (0000-0002-3536-4694); Li-Juan Zhou (0000-0001-5384-2971); Hong-Wei Chen (0000-0002-2028-2434).

Author contributions: Ren XY and Fang XM analyzed and interpreted the imaging findings, reviewed the literature, and contributed to manuscript drafting; Chen JY and Ding H were the patient's lung transplantation surgeons; Wang Y and Lu Q collected the relevant data; Ming JL and Zhou LJ reviewed the literature and contributed to manuscript drafting; Chen HW was responsible for the revision of the manuscript; all authors issued final approval for the version to be submitted.

Informed consent statement:

Informed consent was obtained from the patient included in the study.

Conflict-of-interest statement:

The authors declare that they have no conflicts of interest.

CARE Checklist (2016) statement:

The authors have read the CARE Checklist (2016), and the manuscript was prepared and revised according to the CARE Checklist (2016).

Open-Access: This article is an open-access article which was selected by an in-house editor and fully peer-reviewed by external

Xing-Yu Ren, Xiang-Ming Fang, Yan Wang, Qiu Lu, Jia-Lei Ming, Li-Juan Zhou, Hong-Wei Chen, Department of Radiology, Wuxi People's Hospital-Nanjing Medical University, Wuxi 214000, Jiangsu Province, China

Jing-Yu Chen, Hao Ding, Lung Transplantation Center, Wuxi People's Hospital-Nanjing Medical University, Wuxi 214000, Jiangsu Province, China

Corresponding author: Hong-Wei Chen, MD, Doctor, Professor, Department of Radiology, Wuxi People's Hospital-Nanjing Medical University, 299 Qingyang Road, Wuxi 214000, Jiangsu Province, China. chw6312@163.com

Telephone: +86-510-86830398

Abstract

BACKGROUND

Pulmonary alveolar microlithiasis (PAM) is a rare idiopathic lung disease characterized by the accumulation of innumerable microliths. Currently, effective therapeutics for PAM are not available, and the only treatment for end-stage lung disease is lung transplantation (LuTx). Further, there are few reports that focus on LuTx for the treatment of PAM, and the follow-up reports of postoperative imaging are even rarer.

CASE SUMMARY

A 52-year-old man presented to Shanghai Pulmonary Hospital in 2017 after experiencing shortness of breath and exacerbation. The patient was diagnosed with PAM and referred for single-LuTx (SLuTx) on March 14, 2018. Preoperative imaging results from a chest X-ray demonstrated bilateral, diffuse, symmetrical, sandstorm-like radiopaque micronodules, and pneumothorax and a computed tomography scan revealed minute, calcified military nodules in both lungs. We performed a left SLuTx, and intraoperative pathology was consistent with PAM. One week after surgery, a chest X-ray revealed slight exudation of the left lung, and one month later, the left transplanted lung exhibited good dilation, mild pulmonary perfusion injury with local infection, and left pleural effusion. Fiberoptic bronchoscopy revealed left hyperplastic granulation at the left bronchial anastomosis. Multiple sputum cultures suggested the presence of *Klebsiella pneumoniae* and *Acinetobacter baumannii*. The last follow-up was conducted in April 2019; the patient recovered well.

CONCLUSION

This case presents the imaging findings of a patient with PAM before and after

reviewers. It is distributed in accordance with the Creative Commons Attribution Non Commercial (CC BY-NC 4.0) license, which permits others to distribute, remix, adapt, build upon this work non-commercially, and license their derivative works on different terms, provided the original work is properly cited and the use is non-commercial. See: <http://creativecommons.org/licenses/by-nc/4.0/>

Manuscript source: Unsolicited manuscript

Received: June 16, 2019

Peer-review started: June 21, 2019

First decision: September 9, 2019

Revised: September 24, 2019

Accepted: October 5, 2019

Article in press: October 5, 2019

Published online: November 26, 2019

P-Reviewer: Salvadori M

S-Editor: Dou Y

L-Editor: Wang TQ

E-Editor: Liu JH



LuTx and confirms the effectiveness of LuTx for the treatment of this disease.

Key words: Pulmonary alveolar microlithiasis; Lung transplantation; Complications; Chest X-ray; Computed tomography; Case report

©The Author(s) 2019. Published by Baishideng Publishing Group Inc. All rights reserved.

Core tip: Pulmonary alveolar microlithiasis (PAM) is a rare idiopathic lung disease characterized by the accumulation of innumerable microliths. Currently, there are no effective therapeutic drugs for PAM, and the only treatment for end-stage lung disease is lung transplantation (LuTx). Here we present a rare case of alveolar microlithiasis transplantation. This case highlights the importance of imaging findings of PAM before and after LuTx and confirms the effectiveness of LuTx for the treatment of PAM.

Citation: Ren XY, Fang XM, Chen JY, Ding H, Wang Y, Lu Q, Ming JL, Zhou LJ, Chen HW. Single-lung transplantation for pulmonary alveolar microlithiasis: A case report. *World J Clin Cases* 2019; 7(22): 3851-3858

URL: <https://www.wjgnet.com/2307-8960/full/v7/i22/3851.htm>

DOI: <https://dx.doi.org/10.12998/wjcc.v7.i22.3851>

INTRODUCTION

Pulmonary alveolar microlithiasis (PAM) is a rare idiopathic lung disease characterized by the accumulation of innumerable microliths that consist primarily of calcium and phosphorus in pulmonary alveoli^[1]. PAM was first described by an Italian scientist in 1868, and more than 1000 cases have been reported worldwide^[2]. Currently, there is no medical therapy available to alter the progression of PAM definitively, and lung transplantation (LuTx) is usually performed when patients are diagnosed with end-stage lung disease^[3]. Here, we report a successful case of left single-LuTx (SLuTx) in a patient with PAM for the first time in China.

CASE PRESENTATION

Chief complaints

A 52-year-old man (weight, 55 kg; height, 172 cm) was referred for a LuTx after experiencing shortness of breath with chest tightness for 4 years and exacerbation for 10 d.

History of present illness

The patient coughed and expectorated since childhood and experienced chest tightness and shortness of breath that gradually increased after exercise since 2014. He was diagnosed with PAM by using fiberoptic bronchoscopy at Shanghai Pulmonary Hospital in 2017. The patient had three instances of pneumothorax in the left lung over a period of 6 months and received poor treatment. On March 14, 2018, the patient was evaluated for LuTx at Wuxi People's Hospital.

History of past illness

The patient's past medical history was unremarkable.

Personal and family history

The patient's brother experienced similar symptoms, although he had not been diagnosed at a hospital.

Physical examination

Both lungs had low respiratory sounds and slightly moist rales.

Laboratory examinations

The results of liver and heart function tests were as follows: Albumin, 34.5 g/L (normal range: 35.0-53.0 g/L); lactic dehydrogenase, 246.0 U/L (normal range: 109.0-245.0 U/L); and globulin, 35.8 g/L (normal range: 17.0-33.5 g/L). Immunological

parameters were as follows: Immunoglobulin A, 5.7 g/L (normal range: 0.7-5.0 g/L); immunoglobulin M, 3.03 g/L (normal range: 0.4-2.8 g/L); and complement C3, 786.0 mg/L (normal range: 790.0-1520.0). Tumor indices were as follows: CA125: 249.5 U/mL (normal range: < 35.0 U/mL) and C-reactive protein, 17.3 mg/L (normal range: 0-8.0 mg/L).

Imaging examinations

A preoperative chest X-ray demonstrated bilateral, diffuse, symmetrical, sandstorm-like radiopaque micronodules and pneumothorax, and a chest computed tomography (CT) scan revealed decreased diffuse transmittance and calcified minute miliary nodules in both lungs (Figure 1A-C). The clinical symptoms and imaging results were consistent PAM. After discussion and approval by the hospital ethics committee, the patient was placed on the waiting list for LuTx.

FINAL DIAGNOSIS

Intraoperative pathology revealed the accumulation of calcium salts in the alveoli (Figure 2). A final diagnosis of PAM was established.

TREATMENT

On April 9, 2018, the lung from a 28-year-old donor (weight, 70 kg; height, 175 cm) became available for our patient. The donor was in good health and pronounced brain dead following intracerebral hemorrhage. The donor's close relatives agreed to donate his organs. The patient's and donor's ABO and Rh blood groups were the same, their body type and chest circumference matched, and panel reactive antibody and human leukocyte antigen were negative. The donor's lung was cut off according to the standard protocol, preserved with raffinose-low potassium dextran solution, and transported.

We performed a left SLuTx with extracorporeal membrane oxygenation (ECMO). During this procedure, few adhesions were noted in the left side of the chest. We observed diffuse consolidation of the left lung, and it had a firm, sandy texture. Intraoperative blood loss was 1600 mL, and transfusion of 1600 mL of blood was performed. The cooling time for the supply lung was 7.5 h.

After the operation, the patient was transferred to the intensive care unit (ICU). Postoperative intubation time was 3 d, and ECMO was removed 2 d later due to hypoxia. After 5 d, he was transferred from the ICU to the general ward for further treatment.

OUTCOME AND FOLLOW-UP

One week after surgery, a chest X-ray showed slight exudation of the left lung (Figure 3A), and one month later, the left transplanted lung showed good dilation, mild pulmonary perfusion injury with local infection (Figure 3B), and left pleural effusion (Figure 3C). Fiberoptic bronchoscopy revealed obstruction of the left bronchial anastomosis caused by hyperplastic granulation and the accumulation of yellow and white sticky moss. Multiple sputum cultures suggested the presence of *Klebsiella pneumoniae* and *Acinetobacter baumannii*. The patient was discharged from the hospital in a stable condition after treatment. In September, anastomotic stenosis was improved after bronchoscopic balloon dilatations were performed three times (Figure 3D). The last follow-up was conducted in April 2019, and the patient recovered well (Figure 4).

DISCUSSION

PAM is an autosomal recessive disease caused by mutations in the *SLC34A2* gene, which lead to defects in the sodium phosphate-IIb cotransporter protein. These defects prevent the clearance of phosphate and calcium phosphate deposits from the extracellular fluid by alveolar type II epithelial cells^[4]. PAM has a familial genetic tendency, and familial cases account for about 30%-50% of all cases. Additionally, there is a slight predominance among males^[5]. Previous studies (Table 1) reported that five patients mentioned their family history in the literature, one of whom had a family history, and our patient stated that his brother had similar symptoms but had

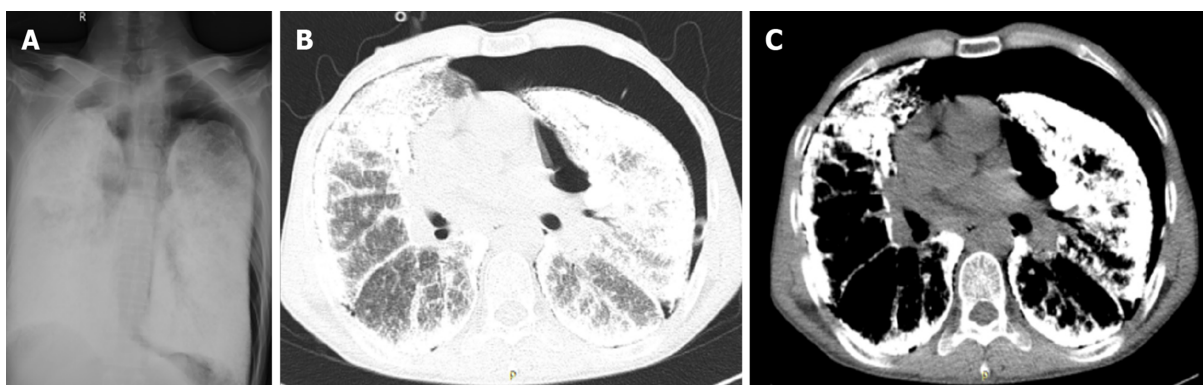

Figure 1 Preoperative imaging results suggestive of pulmonary alveolar microlithiasis. A: Chest X-ray image showing bilateral, diffuse, symmetrical, sandstorm-like radiopaque micronodules and pneumothorax; B: Chest computed tomography (CT; pulmonary window) image showing decreased diffuse transmittance; C: Chest CT (mediastinal window) image showing calcified, minute miliary nodules in both lungs.

not been diagnosed in hospital.

Some patients may be asymptomatic initially; however, as the disease progresses, both lungs become fibrotic, which may lead to restrictive ventilatory disorder and respiratory failure^[6]. Our patient coughed and expectorated since childhood, experienced shortness of breath for four years prior to his diagnosis, and gradually received medical treatment. The patient's symptoms were consistent with the clinical manifestations of PAM.

The typical picture of PAM on a chest X-ray is sand-like, calcific micronodules that diffusely infiltrating both lungs, especially the middle and lower zones, and this is called "sandstorm lung". The increased calcific density in lower zones is due to the larger surface area and greater thickness. While PAM is progressing, extensive microliths may cause obscuration of the mediastinal and diaphragmatic silhouette. Additionally, bullous emphysema may also be observed at the anterior margin or apex. Moreover, chest CT scans show thickening of the lobular septae with a distribution of microliths along the septae and around the centrilobular distal bronchioles. This is called "crazy paving" pattern^[1,3,7]. Our patient had high-density micronodules in both lungs and repeated unhealed left pneumothorax, which were consistent with typical imaging manifestations.

Although the use of disphosphonates has been promoted for the treatment of PAM, there are mixed results associated with this treatment^[3]. Currently, LuTx is an effective treatment for patients with end-stage PAM. However, owing to the small number of cases and lack of prognostic factors around the world, there are currently no guidelines for LuTx timing^[8]. Based on our experience, LuTx is needed to be considered when respiratory failure, pneumothorax, or acute exacerbations occur and the patient requires long-term oxygen therapy. Table 1 summarizes the information from existing case reports of PAM. The mean age of 18 patients with PAM was 48.1 ± 11.9 years, which is similar to the age of the patient in the current study. Further, only four patients (Table 1) received SLuTx, for which the patient's condition and lung imaging findings needed to be considered. Previous studies have reported that bilateral lung replacements are more effective than SLuTx because unilateral replacements may lead to shunting of blood through the underventilated native lung^[9]. However, other studies have demonstrated that patients who received SLuTx had no evidence of recurrence in the transplanted lung^[10,11,12]; therefore, a study that implements a longer follow-up period after SLuTx in patients with PAM should be conducted. Because our patient had acute pulmonary edema and acute left heart failure during the operation, and the left pneumothorax was unhealed before the surgery, the surgeon chose single LuTx finally. Further, recurrence was not observed during the first year after the operation.

Complications after LuTx are the main cause of death of patients undergoing transplantation. Infections are the second (18.7%) and main (36.3%) causes of death, respectively, from 30 days to 1 year after operation^[13]. From the cases that we reviewed, two patients died from infections at 11 days (sepsis, $n = 1/18$) and 3 mo ($n = 1/18$) after operation, respectively. Other postoperative complications, including anastomotic stenosis, acute rejection, and reperfusion edema, occurred in 14 survival cases (Table 1). Some complications are associated with different imaging features. For example, infections are characterized by diffuse ground glass opacities, localized atelectasis or consolidation, small intrapulmonary nodules, peri-bronchovascular interstitial thickening, and pleural effusions. Acute rejection is characterized by

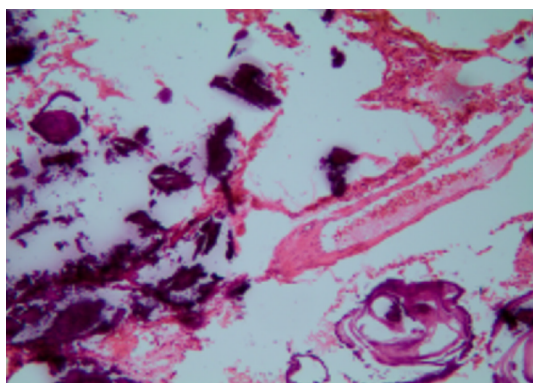


Figure 2 Intraoperative pathology showing large amounts of calcium salts in the alveoli (magnification, $\times 100$).

diffuse ground glass opacities, consolidation, septal thickening, and pleural effusions. Bronchial stenosis refers to a narrowing of the bronchus in the CT. Based on these imaging features, our patient was diagnosed with local infection and stenosis.

CONCLUSION

The patient in this study was preoperatively diagnosed with PAM based on fiberoptic bronchoscopy biopsy, and imaging findings, such as the “sandstorm lung” from chest X-ray scans and the “crazy paving” pattern from chest CT scans, supported the diagnosis. In addition, our results demonstrated that LuTx is an effective treatment for patients with end-stage PAM. Further, the prevention of postoperative complications is important in order to improve the prognosis of patients who have received transplantations.

Table 1 Summary of case reports related to lung transplantation in patients with pulmonary alveolar microlithiasis

Ref.	Yr	Age	Family history	Double/Single LuTx	Complications	Outcome
Bonnette <i>et al</i> ^[14]	1992	46	NR	Double	No	Alive, NR
Stamatis <i>et al</i> ^[11]	1993	32	YES	Double	Major bleeding	Alive, 18 m
Raffa <i>et al</i> ^[15]	1996	48	NO	Single	Acute rejection, anastomotic stenosis	Alive, 12 m
Edelman <i>et al</i> ^[16]	1997	56	NO	Double	Major bleeding	Dead, POD 5
		35	NR		No	Alive, 32 m
Jackson <i>et al</i> ^[12]	2001	53	NR	Single	No	Alive, 90 m
Coulibaly <i>et al</i> ^[17]	2009	43	NR	Double	Infection	Dead, 3 m
Shadmehr <i>et al</i> ^[18]	2009	32	NR	Single	Hemodynamically instable, reperfusion edema	Dead, NR
Shigemura <i>et al</i> ^[19]	2010	63	NR	Double	No	Alive, 16 m
Samano <i>et al</i> ^[20]	2010	47	NO	Double	Reperfusion syndrome, shock	Alive, 12 m
Borrelli <i>et al</i> ^[21]	2014	64	NR	Single	NR	Alive, 60 m
Güçyetmez <i>et al</i> ^[22]	2014	52	NR	Double	NR	Alive, 12 m
Klikovits <i>et al</i> ^[9]	2016	32	NR	Double	PGD, Sepsis	Dead, 11 d
		52			Reperfusion-edema	Alive, 74 d
		34			No	Alive, 67 d
		52			No	Alive, 35 d
		52			Atrial fibrillation	Alive, 29 d
Delic <i>et al</i> ^[23]	2016	73	NO	Double	NR	Alive, NR

NR: Not reported; PGD: Primary graft dysfunction; POD: Postoperative day.

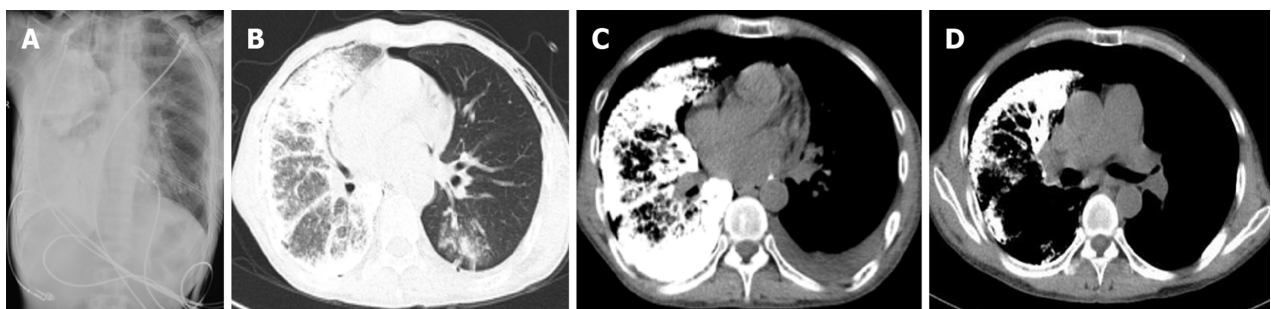


Figure 3 Postoperative imaging. A: Postoperative chest radiograph (1 wk after surgery) revealing slight exudation in the left lung; B: High-resolution computed tomography (CT) image showing good dilation of the left transplanted lung, with mild pulmonary perfusion injury and local infection; C: CT image showing left-sided pleural effusion; D: CT image showing a left-sided main bronchial stricture.

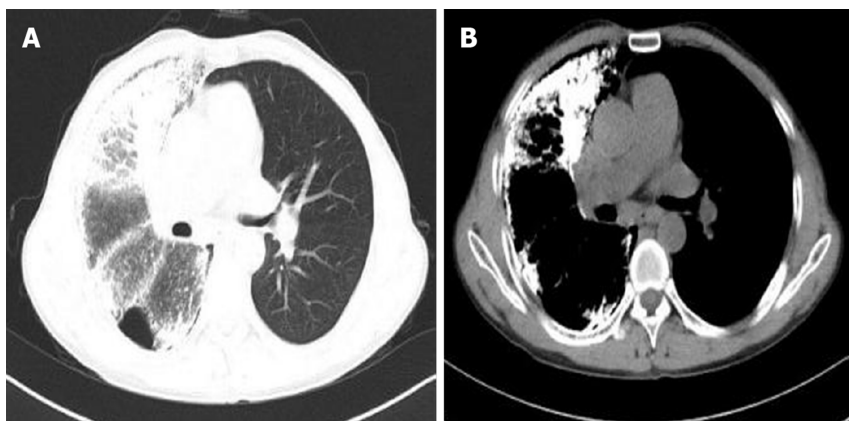


Figure 4 Postoperative imaging. A and B: Chest computed tomography images acquired at the last follow-up visit in April 2019 indicate a good recovery.

ACKNOWLEDGEMENTS

I would like to express gratitude to my colleagues who provided me with references and information on time.

REFERENCES

- 1 Saito A, McCormack FX. Pulmonary Alveolar Microlithiasis. *Clin Chest Med* 2016; **37**: 441-448 [PMID: 27514591 DOI: 10.1016/j.ccm.2016.04.007]
- 2 Castellana G, Carone D, Castellana M. Microlithiasis of Seminal Vesicles and Severe Oligoasthenospermia in Pulmonary Alveolar Microlithiasis (PAM): Report of An Unusual Sporadic Case. *Int J Fertil Steril* 2015; **9**: 137-140 [PMID: 25918602]
- 3 Castellana G, Castellana G, Gentile M, Castellana R, Resta O. Pulmonary alveolar microlithiasis: review of the 1022 cases reported worldwide. *Eur Respir Rev* 2015; **24**: 607-620 [PMID: 26621975 DOI: 10.1183/16000617.0036-2015]
- 4 Dogan OT, Ozsahin SL, Gul E, Arslan S, Koksall B, Berk S, Ozdemir O, Akkurt I. A frame-shift mutation in the SLC34A2 gene in three patients with pulmonary alveolar microlithiasis in an inbred family. *Intern Med* 2010; **49**: 45-49 [PMID: 20046000 DOI: 10.2169/internalmedicine.49.2702]
- 5 Jönsson ÅL, Simonsen U, Hilberg O, Bendstrup E. Pulmonary alveolar microlithiasis: two case reports and review of the literature. *Eur Respir Rev* 2012; **21**: 249-256 [PMID: 22941890 DOI: 10.1183/09059180.00009411]
- 6 Mariotta S, Ricci A, Papale M, De Clementi F, Sposato B, Guidi L, Mannino F. Pulmonary alveolar microlithiasis: report on 576 cases published in the literature. *Sarcoidosis Vasc Diffuse Lung Dis* 2004; **21**: 173-181 [PMID: 15554073]
- 7 Gasparetto EL, Tazoniero P, Escuissato DL, Marchiori E, Frare E Silva RL, Sakamoto D. Pulmonary alveolar microlithiasis presenting with crazy-paving pattern on high resolution CT. *Br J Radiol* 2004; **77**: 974-976 [PMID: 15507428 DOI: 10.1259/bjr/96331922]
- 8 Weill D, Benden C, Corris PA, Dark JH, Davis RD, Keshavjee S, Lederer DJ, Mulligan MJ, Patterson GA, Singer LG, Snell GI, Verleden GM, Zamora MR, Glanville AR. A consensus document for the selection of lung transplant candidates: 2014--an update from the Pulmonary Transplantation Council of the International Society for Heart and Lung Transplantation. *J Heart Lung Transplant* 2015; **34**: 1-15 [PMID: 25085497 DOI: 10.1016/j.healun.2014.06.014]
- 9 Klikovits T, Slama A, Hoetzenecker K, Waseda R, Lambers C, Murakoezy G, Jaksch P, Aigner C, Taghavi S, Klepetko W, Lang G, Hoda MA. A rare indication for lung transplantation - pulmonary alveolar microlithiasis: institutional experience of five consecutive cases. *Clin Transplant* 2016; **30**: 429-434 [PMID: 26841075 DOI: 10.1111/ctr.12705]
- 10 Gomes Neto A, Monteiro Nogueira AS, Lopes De Medeiros I, Fernandes Viana De Araujo R, Carvalho Santos R, Sampaio Viana CM, Moreira Batista Aguiar F, Gomes Catunda L, Araújo Aragão L, Fava Alencar R. Single- and Double-Lung Transplantation: Results of an Initial Experience of 39 Cases in Ceará (Northeast Brazil). *Transplant Proc* 2018; **50**: 815-818 [PMID: 29661444 DOI: 10.1016/j.transproceed.2018.02.024]
- 11 Stamatis G, Zerkowski HR, Doetsch N, Greschuchna D, Konietzko N, Reidemeister JC. Sequential bilateral lung transplantation for pulmonary alveolar microlithiasis. *Ann Thorac Surg* 1993; **56**: 972-975 [PMID: 8215680 DOI: 10.1016/0003-4975(93)90370-W]
- 12 Jackson KB, Modry DL, Halenar J, L'abbe J, Winton TL, Lien DC. Single lung transplantation for pulmonary alveolar microlithiasis. *J Heart Lung Transplant* 2001; **20**: 226 [PMID: 11250426 DOI: 10.1016/S1053-2498(00)00500-3]
- 13 Khush KK, Cherikh WS, Chambers DC, Goldfarb S, Hayes D, Kucheryavaya AY, Levvey BJ, Meiser B, Rossano JW, Stehlik J; International Society for Heart and Lung Transplantation. The International Thoracic Organ Transplant Registry of the International Society for Heart and Lung Transplantation: Thirty-fifth Adult Heart Transplantation Report-2018; Focus Theme: Multiorgan Transplantation. *J Heart Lung Transplant* 2018; **37**: 1155-1168 [PMID: 30293612 DOI: 10.1016/j.healun.2018.07.022]
- 14 Bonnette P, Bisson A, el Kadi NB, Colchen A, Leroy M, Fischler M, Loirat P, Caubarere I. Bilateral single lung transplantation. Complications and results in 14 patients. *Eur J Cardiothorac Surg* 1992; **6**: 550-554 [PMID: 1389238 DOI: 10.1016/1010-7940(92)90007-k]
- 15 Raffa H, El-Dakhkhny M, Al-Ibrahim K, Mansour MS. Single lung transplantation for alveolar microlithiasis: the first clinical report. *Saudi J Kidney Dis Transpl* 1996; **7**: 189-193 [PMID: 18417939]
- 16 Edelman JD, Bavaria J, Kaiser LR, Litzky LA, Palevsky HI, Kotloff RM. Bilateral sequential lung transplantation for pulmonary alveolar microlithiasis. *Chest* 1997; **112**: 1140-1144 [PMID: 9377936 DOI: 10.1378/chest.112.4.1140]
- 17 Coulibaly B, Fernandez C, Reynaud-Gaubert M, D'Journo X, Daddoli C, Taséi AM. [Alveolar microlithiasis with severe interstitial fibrosis leading to lung transplantation]. *Ann Pathol* 2009; **29**: 241-244 [PMID: 19619834 DOI: 10.1016/j.annpat.2009.02.015]
- 18 Shadmehr MB, Arab M, Pejhan S, Daneshvar A, Javaherzadeh N, Abbasi A, Ahmadi ZH, Radpay B, Dabir S, Parsa T, Mohammadi F, Mansoori SD, Tabarsi P, Amiri MV, Marjani M, Kashani BS, Najafzadeh K, Shafaghhi S, Ghorbani F, Masjedi MR, Velayati AA. Eight years of lung transplantation: experience of the National Research Institute of Tuberculosis and Lung Diseases. *Transplant Proc* 2009; **41**: 2887-2889 [PMID: 19765464 DOI: 10.1016/j.transproceed.2009.07.016]
- 19 Shigemura N, Bermudez C, Hattler BG, Johnson B, Crespo M, Pilewski J, Toyoda Y. Lung transplantation for pulmonary alveolar microlithiasis. *J Thorac Cardiovasc Surg* 2010; **139**: e50-e52 [PMID: 19660326 DOI: 10.1016/j.jtcvs.2008.07.066]
- 20 Samano MN, Waisberg DR, Canzian M, Campos SV, Pêgo-Fernandes PM, Jatene FB. Lung transplantation for pulmonary alveolar microlithiasis: a case report. *Clinics (Sao Paulo)* 2010; **65**: 233-236 [PMID: 20186308 DOI: 10.1590/S1807-59322010000200016]
- 21 Borrelli R, Fossi A, Volterrani L, Voltolini L. Right single-lung transplantation for pulmonary alveolar microlithiasis. *Eur J Cardiothorac Surg* 2014; **45**: e40 [PMID: 24258203 DOI: 10.1093/ejcts/ezt531]
- 22 Güçyetmez B, Ogan A, Cimet Ayyıldız A, Yalçın Güder B, Klepetko W. Lung transplantation in an intensive care patient with pulmonary alveolar microlithiasis - a case report. *F1000Res* 2014; **3**: 118

- [PMID: 25165536 DOI: 10.12688/f1000research.4035.1]
- 23 **Delic JA**, Fuhrman CR, Trejo Bittar HE. Pulmonary Alveolar Microlithiasis: AIRP Best Cases in Radiologic-Pathologic Correlation. *Radiographics* 2016; **36**: 1334-1338 [PMID: 27618319 DOI: 10.1148/rg.2016150259]



Published By Baishideng Publishing Group Inc
7041 Koll Center Parkway, Suite 160, Pleasanton, CA 94566, USA
Telephone: +1-925-2238242
E-mail: bpgoffice@wjgnet.com
Help Desk: <https://www.f6publishing.com/helpdesk>
<https://www.wjgnet.com>

